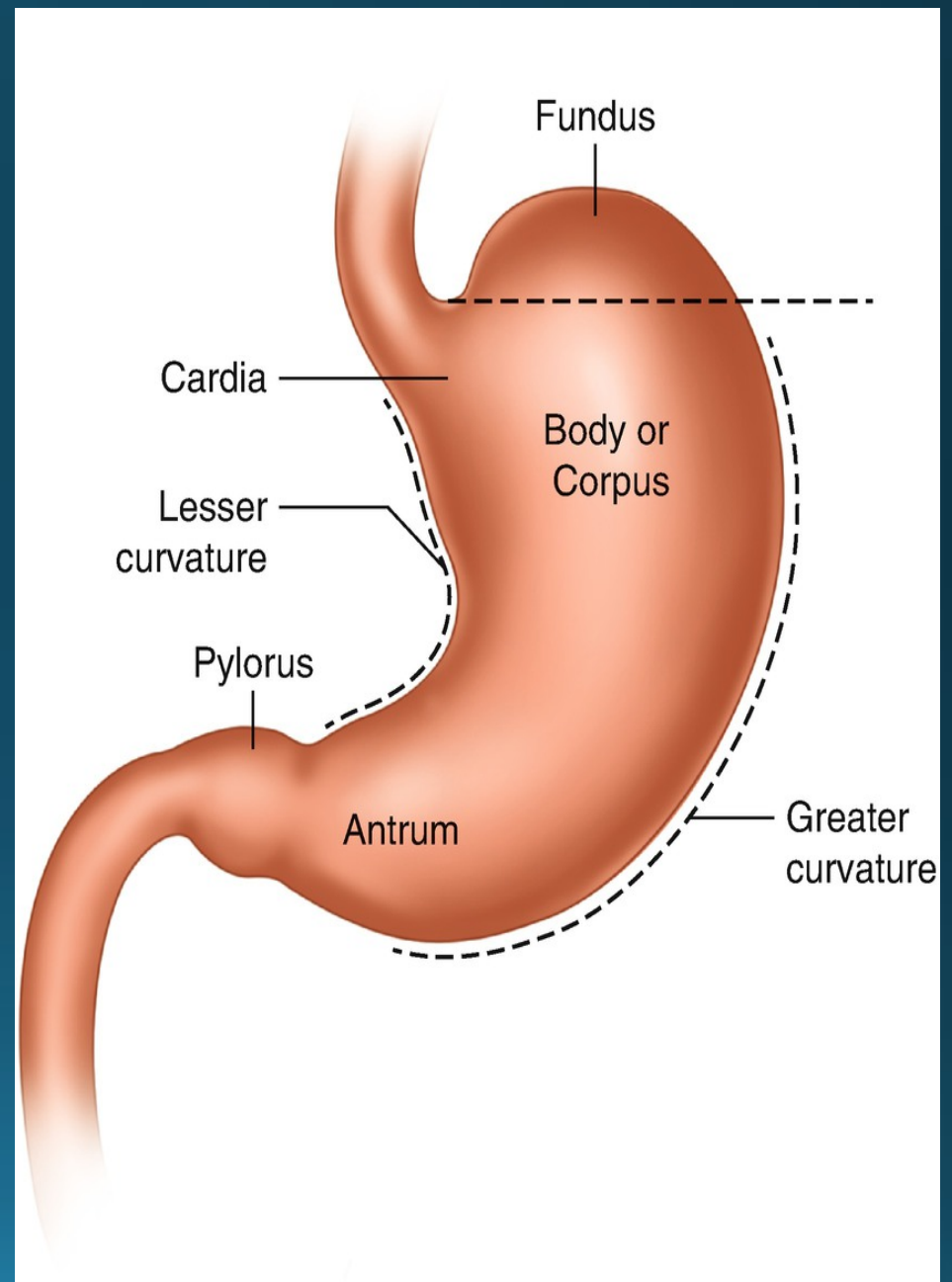
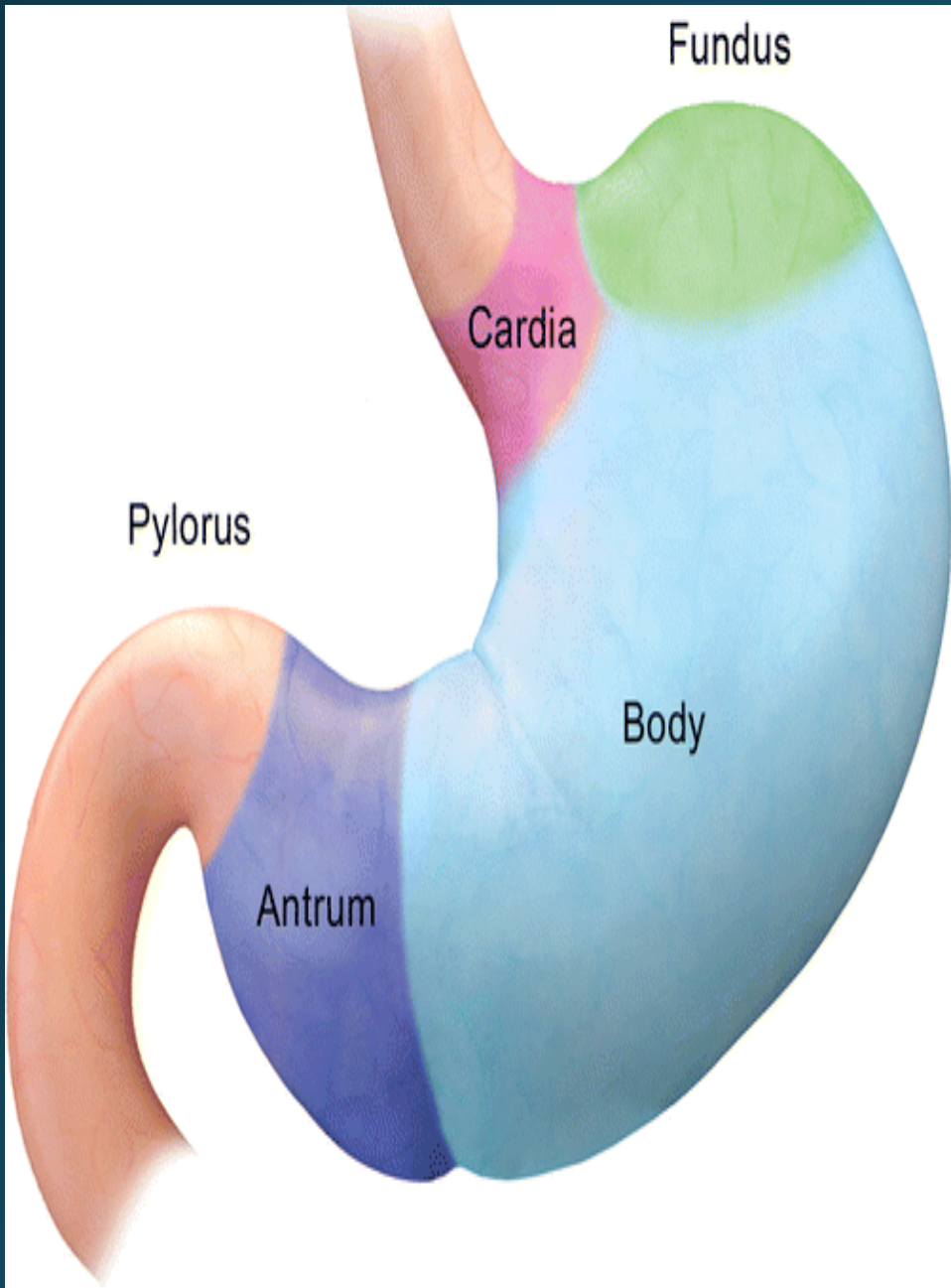


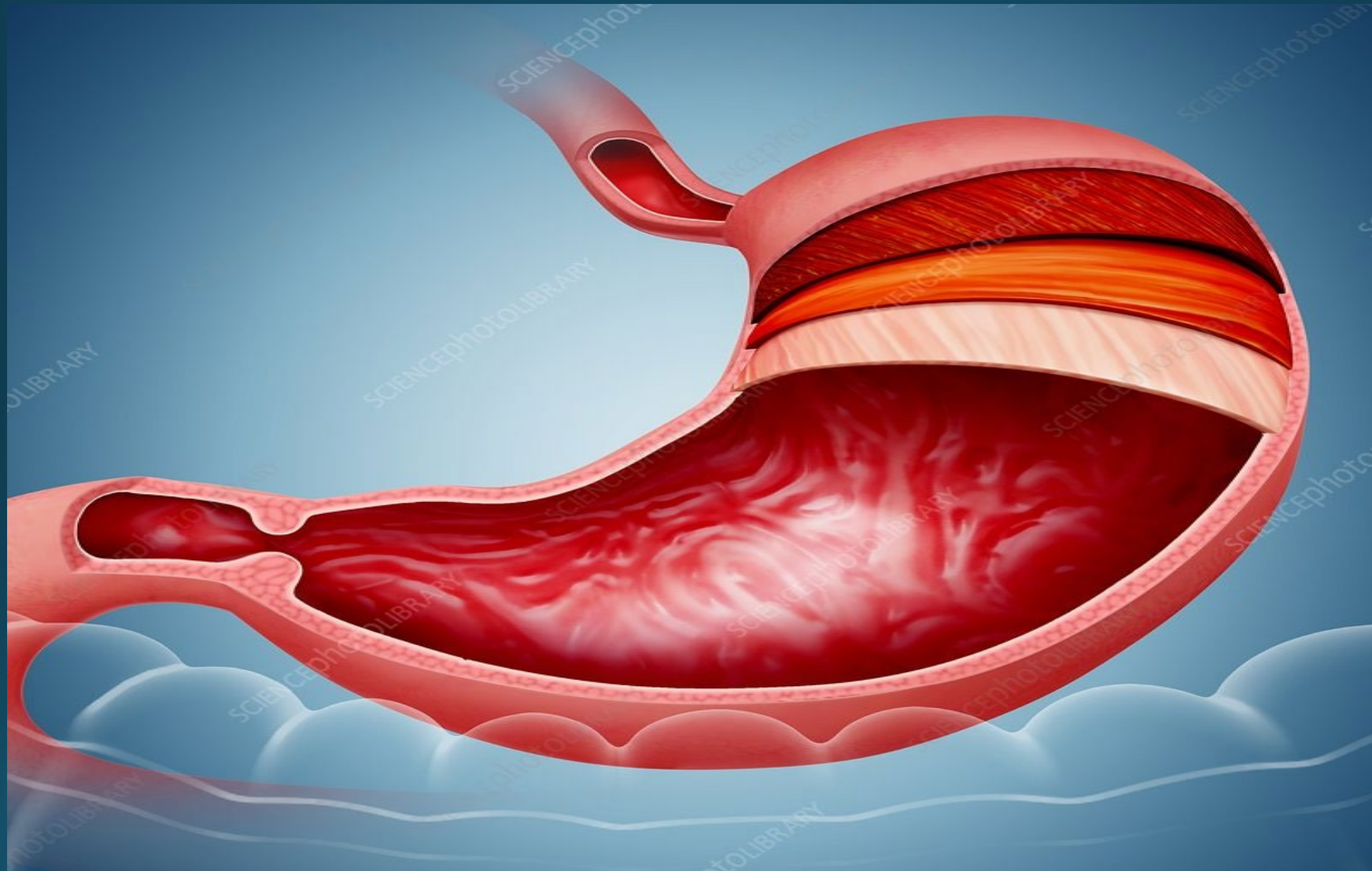
GASTROTOMY

BY

ASST. PROF. DR. BASSIM KADHIM

BASRA UNIV. VET. COLLEGE





Ligaments :

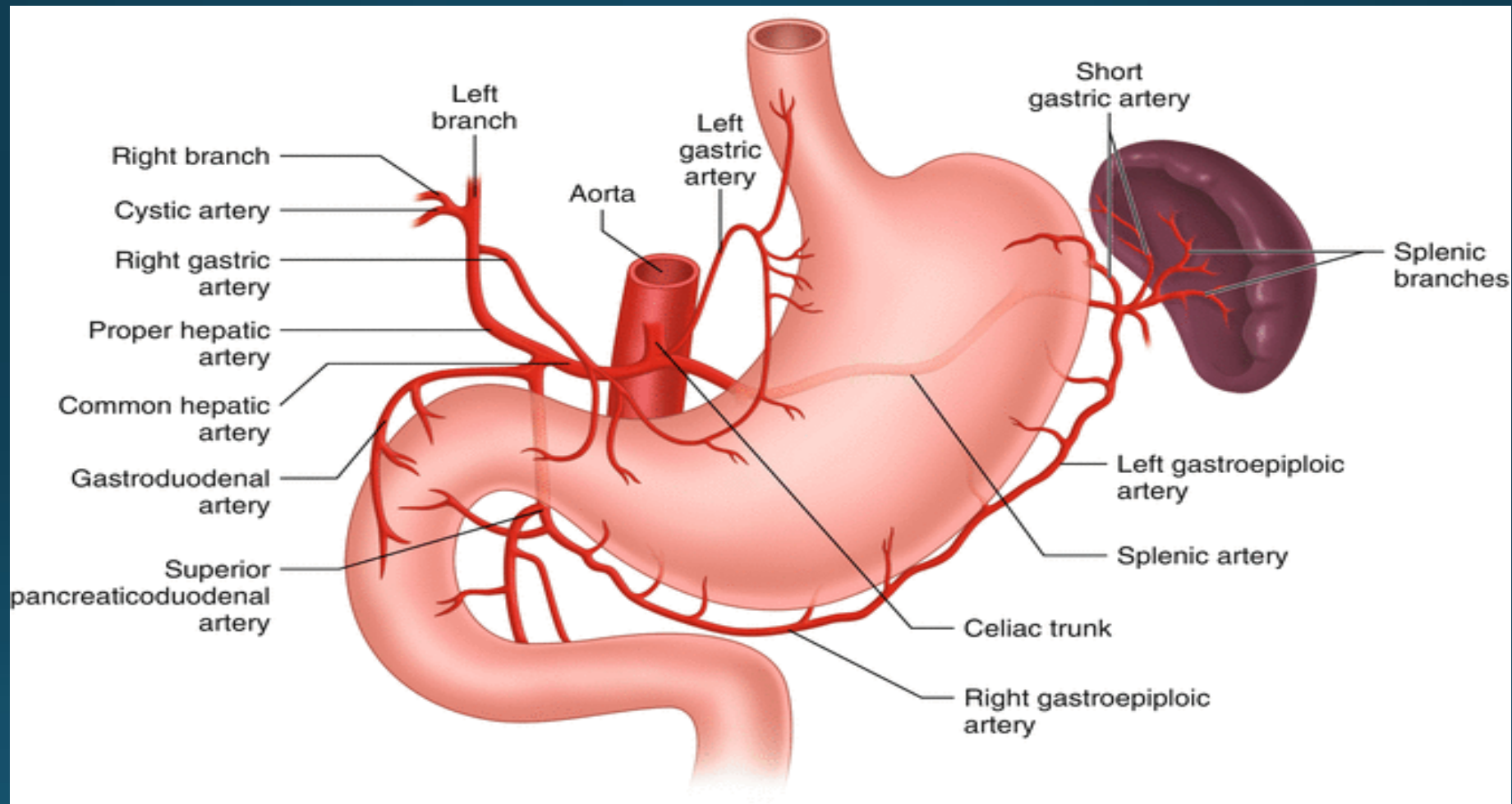
- Lesser curvature :

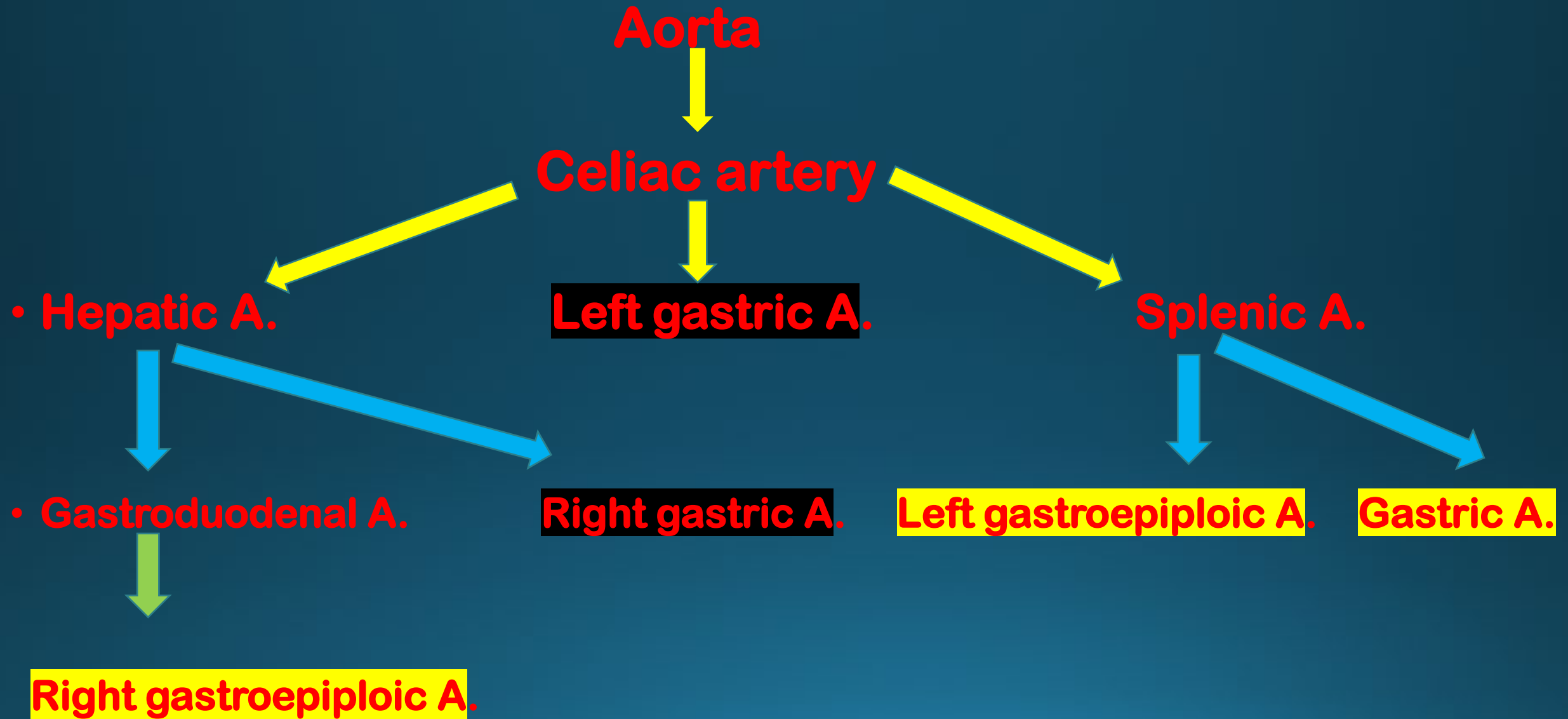
- 1- lesser omentum
- 2- gastrohepatic lig.
- 3- hepatoduodenal lig.

Greater curvature :

- 1- greater omentum .
- 2- gastrophrenic lig.
- 3- gastrosplenic lig.

BLOOD SUPPLY



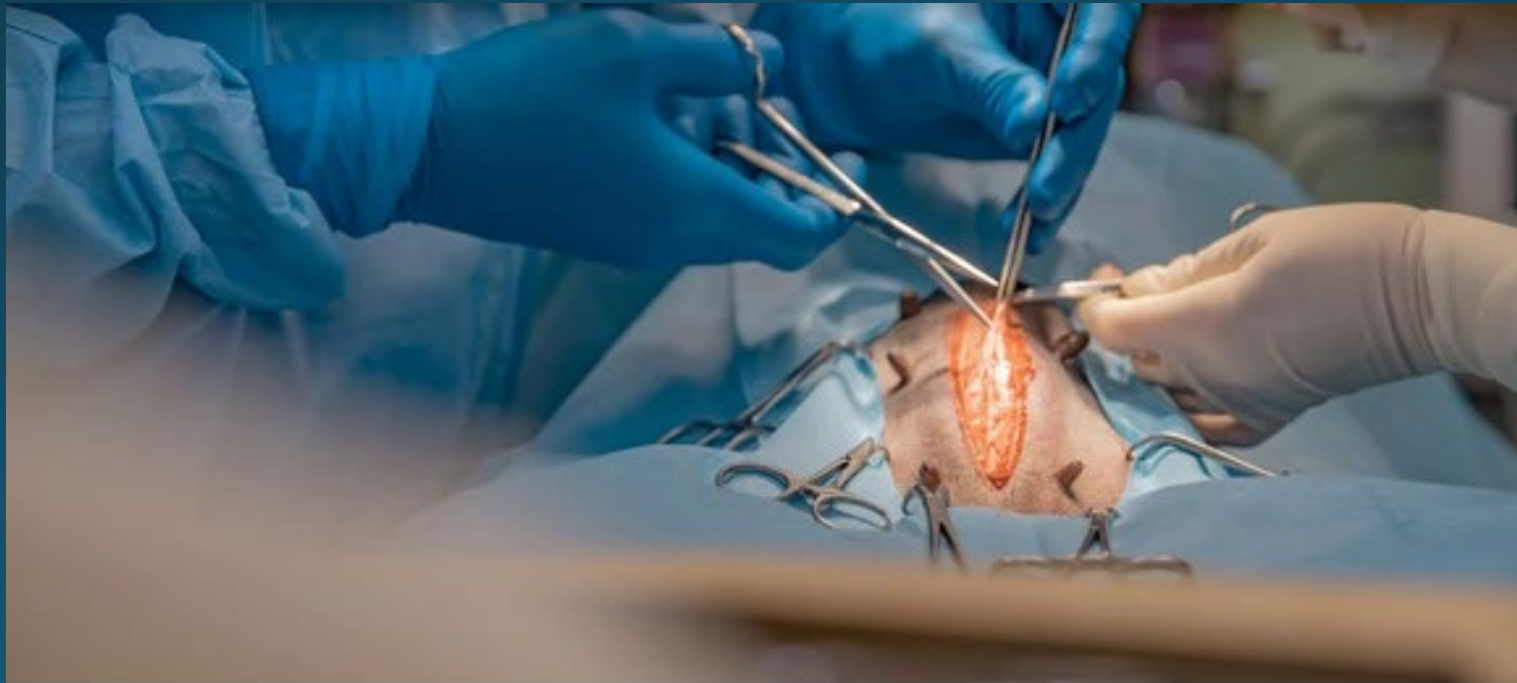


- **Nerve supply :**

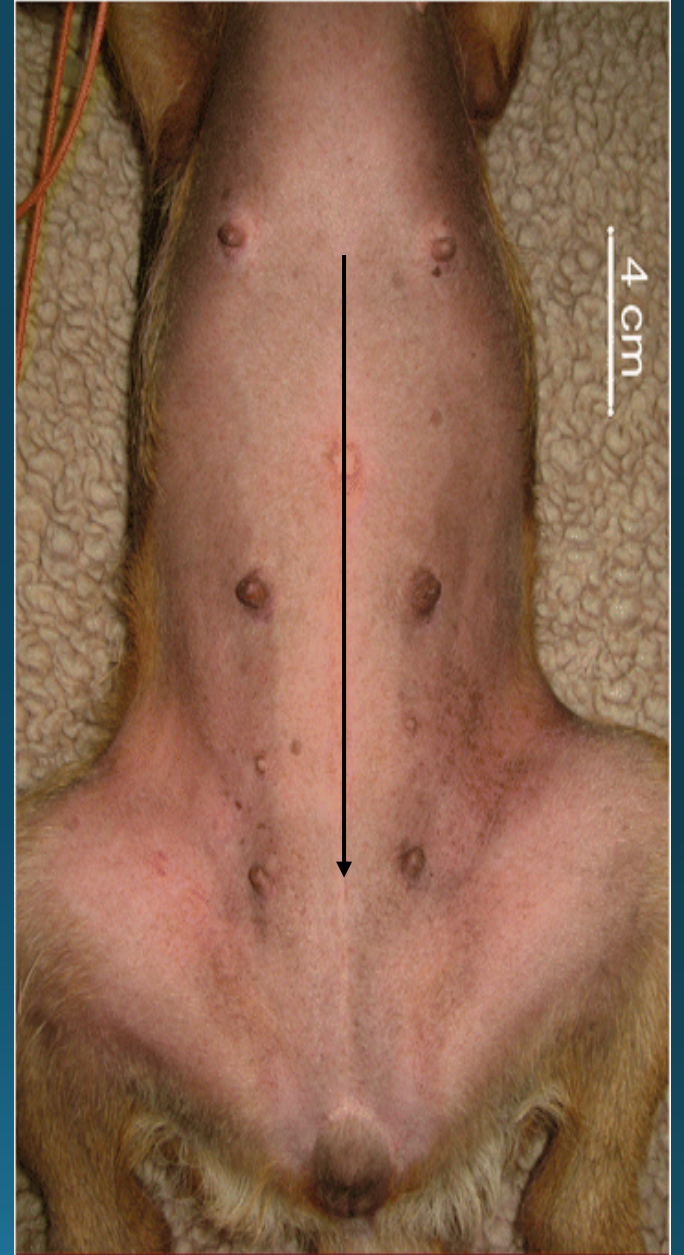
- **Vagus nerve ...** (parasympathetic nerve ,motor n.)

- **Splanchnic nerve.....** (sympathetic nerve , inhibitors n.)

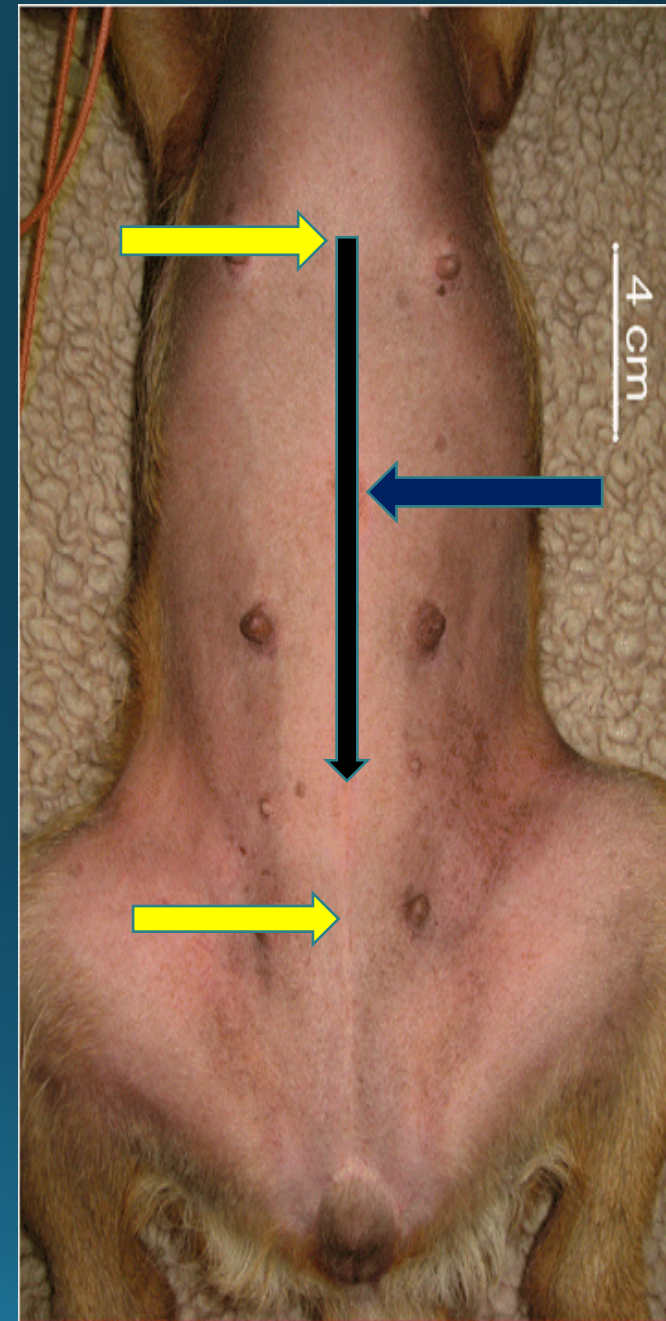
•Surgical principles...



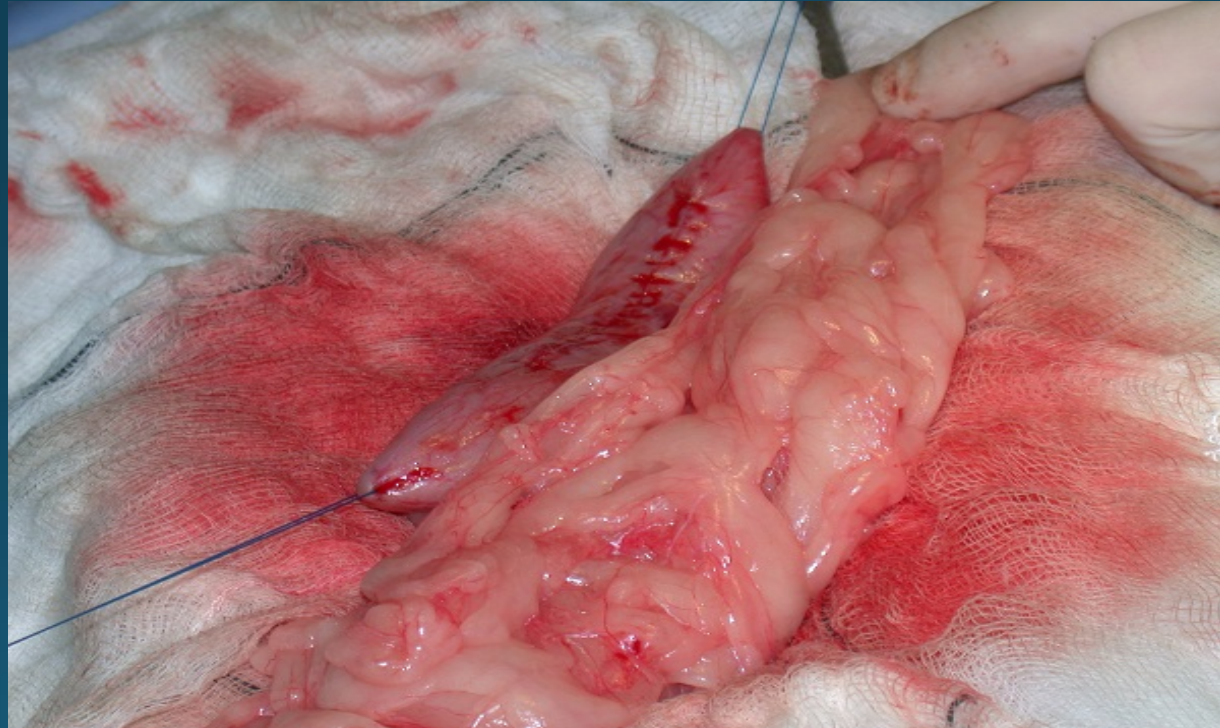
The most common approach is through a ventral midline celiotomy .



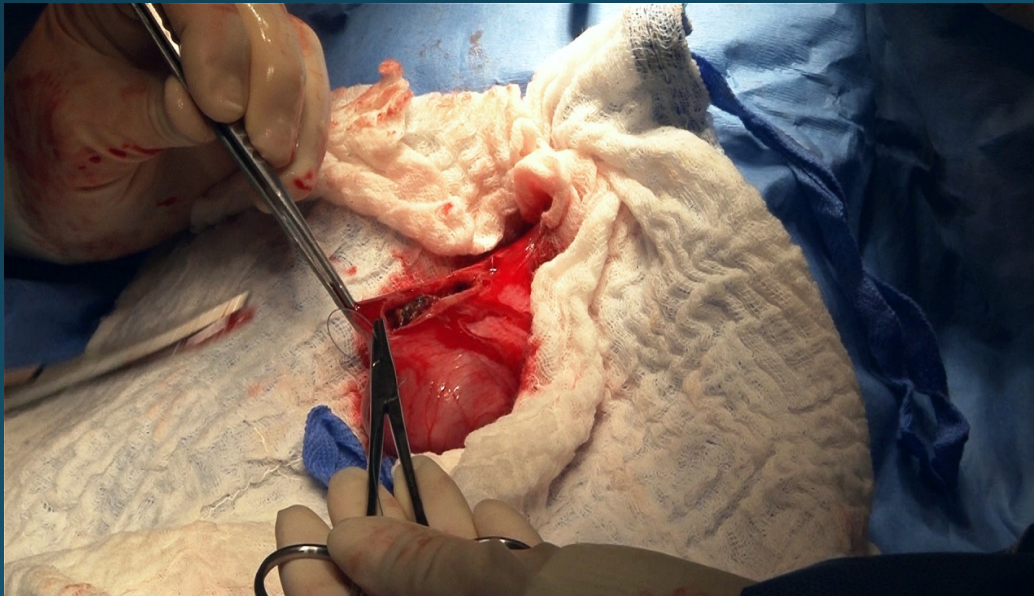
the incision extend between
xiphoid cartilage and the
midway
between umbilicus and the
pubis.



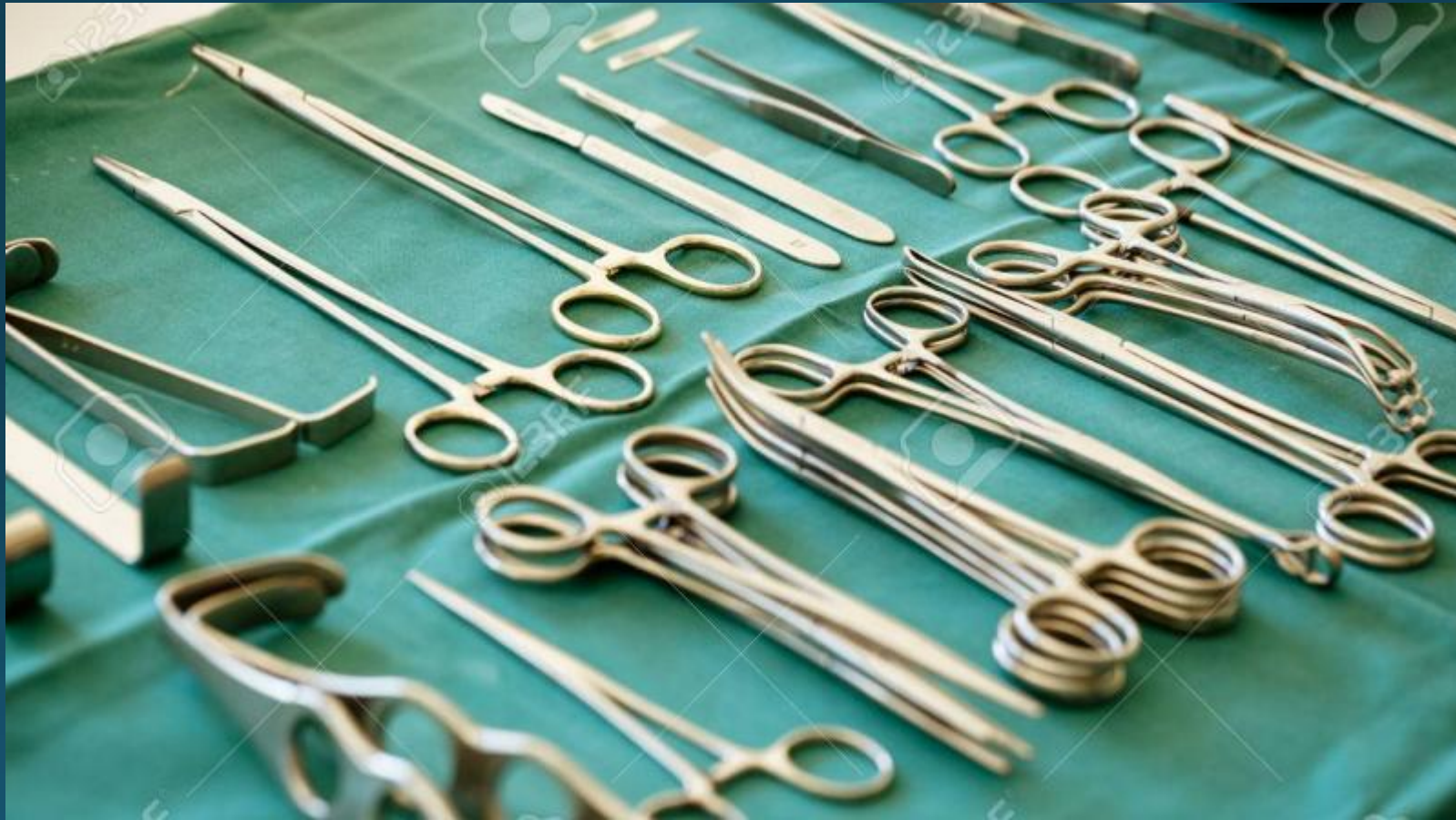Placement stay sutures.....



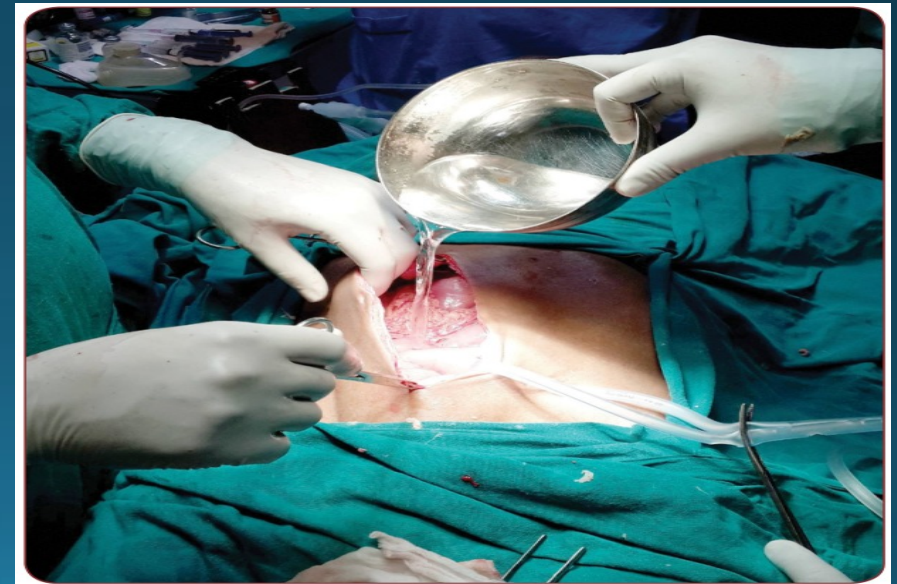
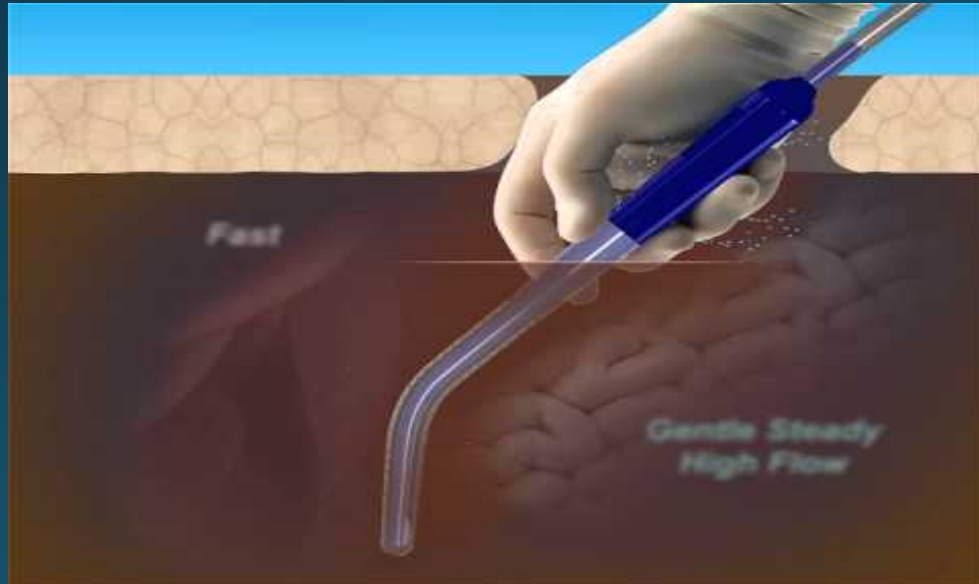
use laparotomy sponges

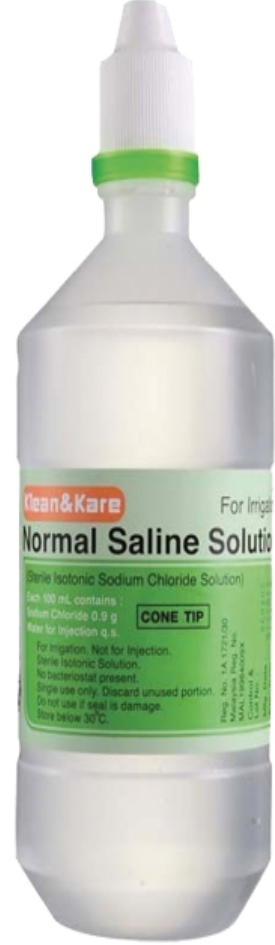
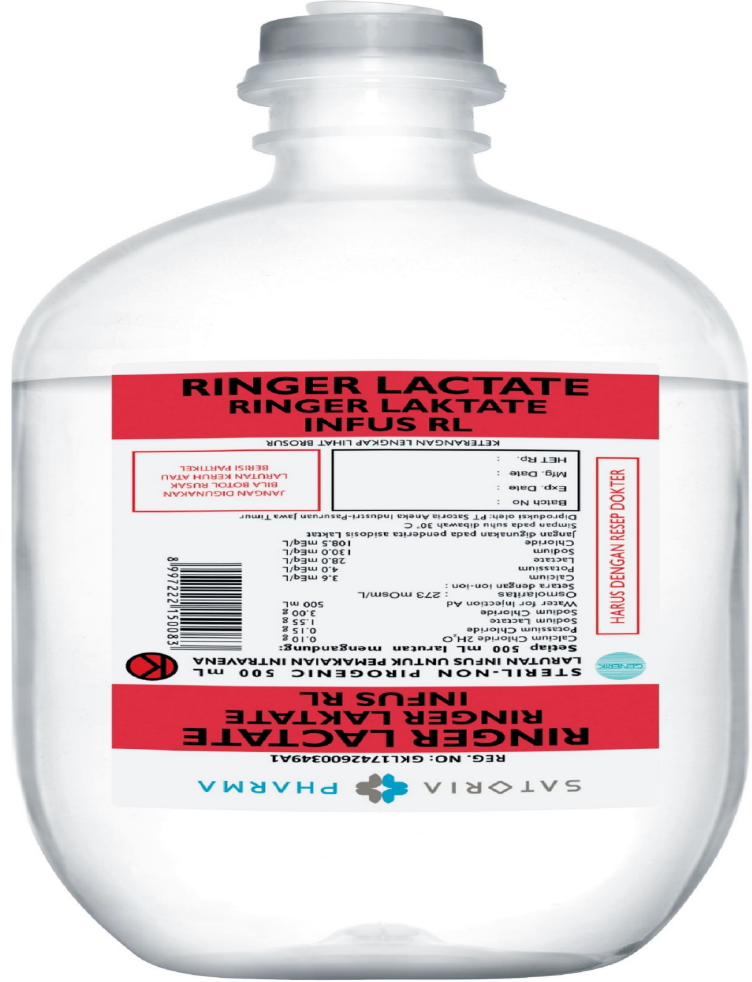
Clean the instrument..



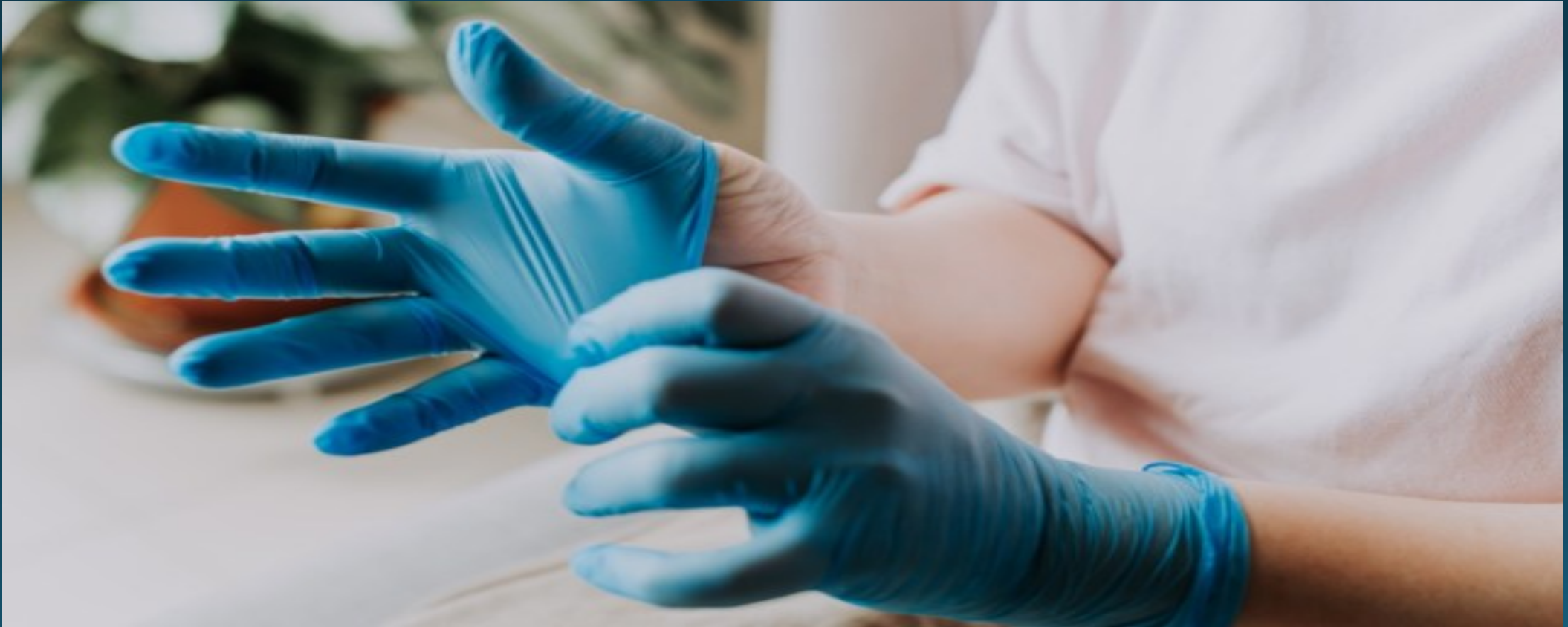post procedure intraperitoneal irrigation



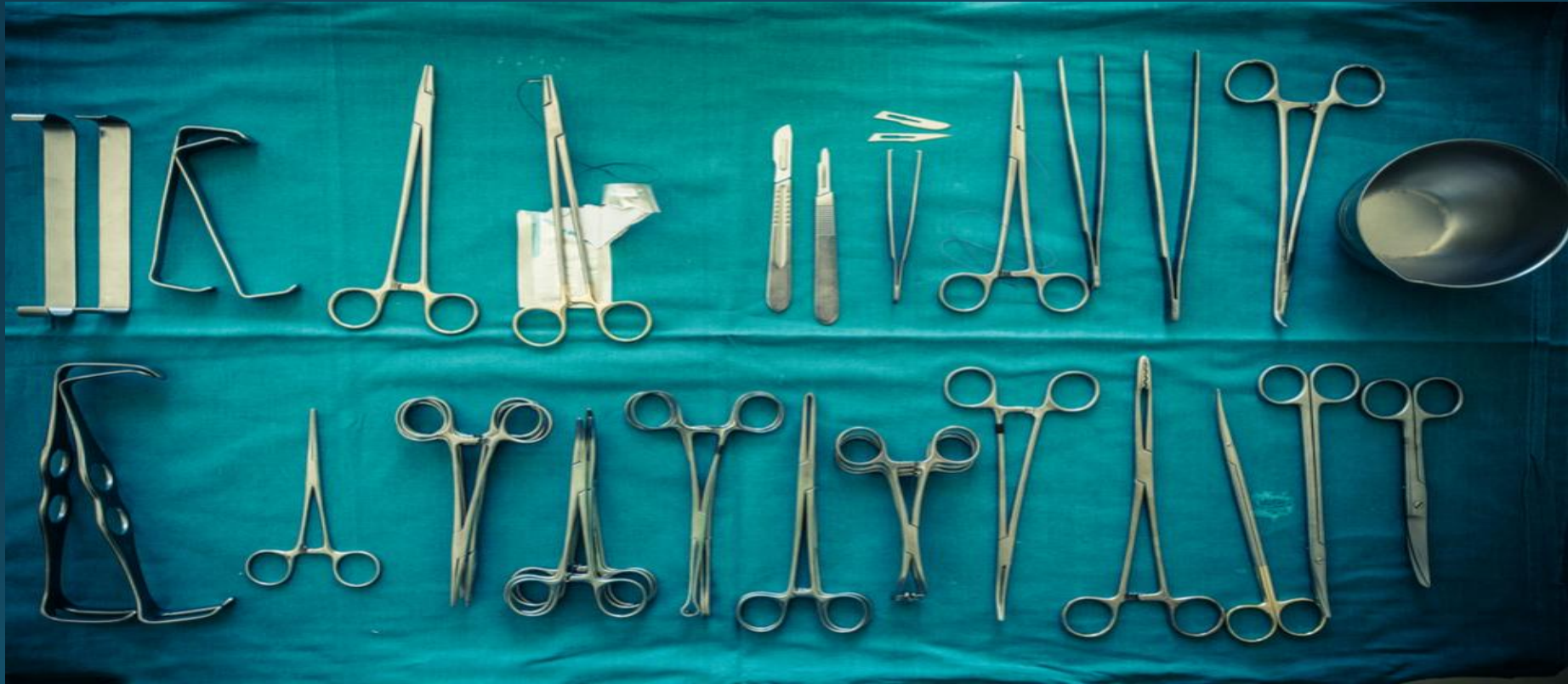

- **with 37-39 °C**..... warmer than it may result in significant vasodilation and hypotension as well as increase risk of adhesion formation While cooler fluid exacerbate hypothermia

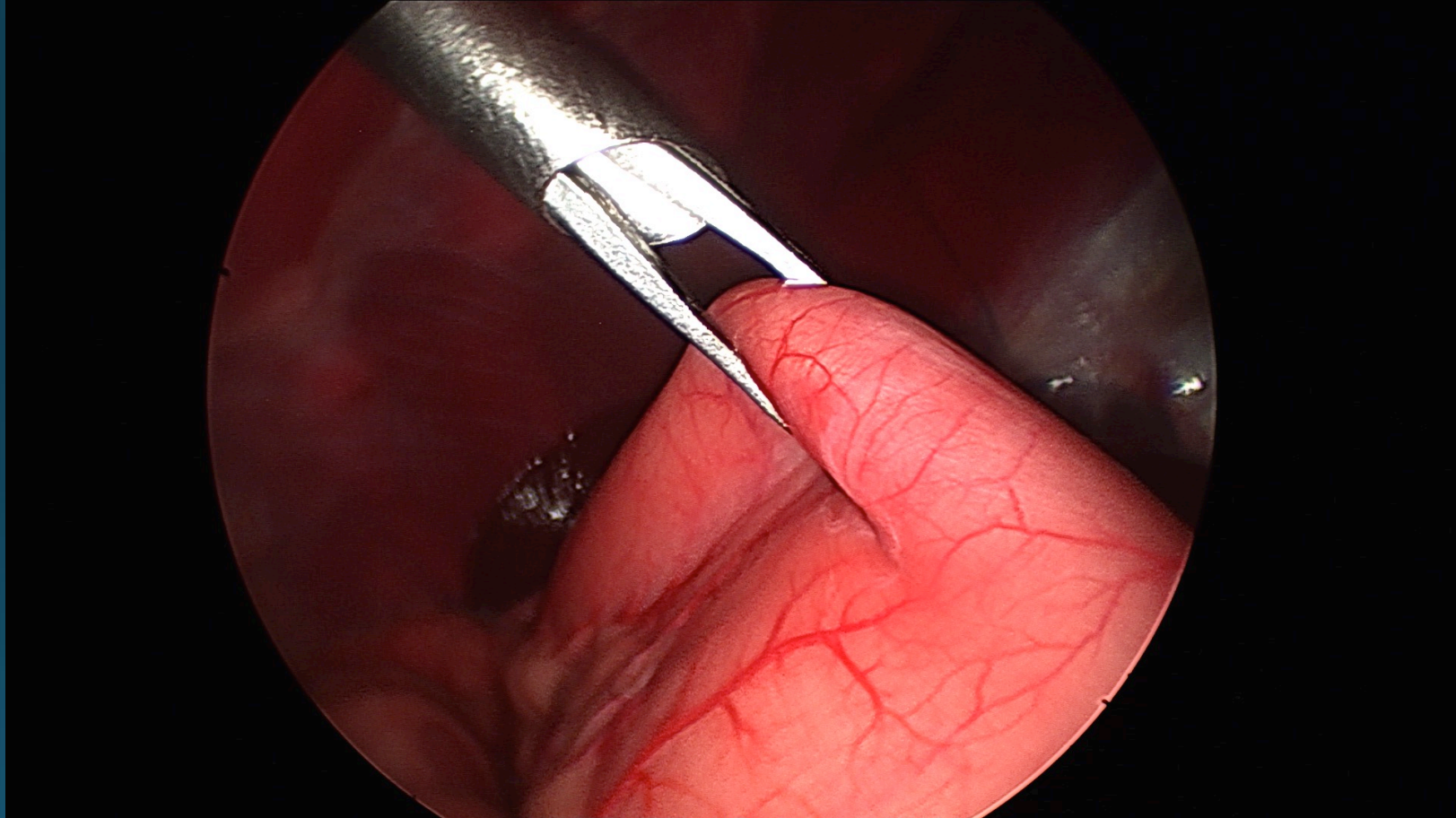
**After gross contamination is
eliminated
the gloves are changed**



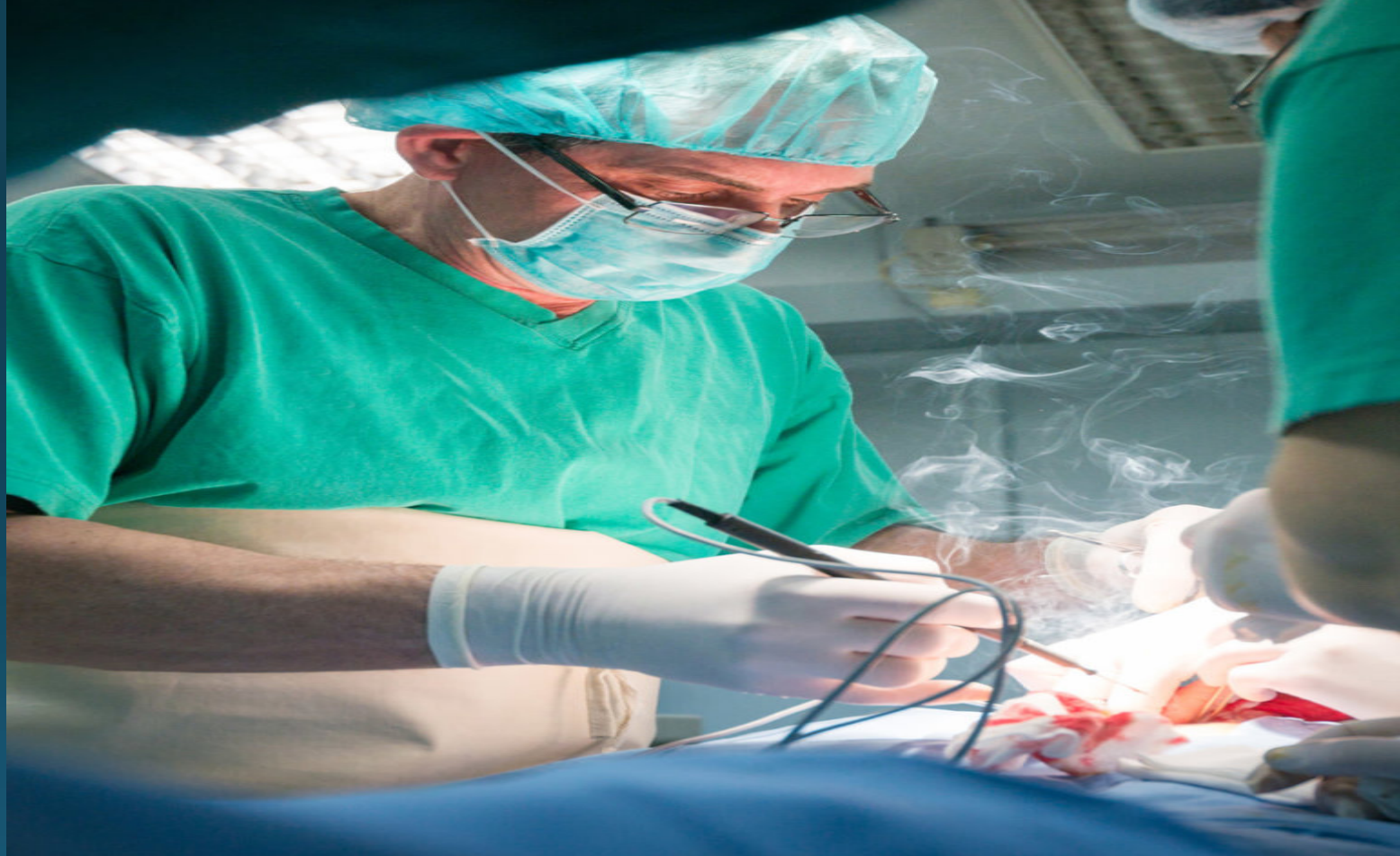clean instrument are used for closure.



Grasping instruments must avoided



Electrocautery is used sparingly.

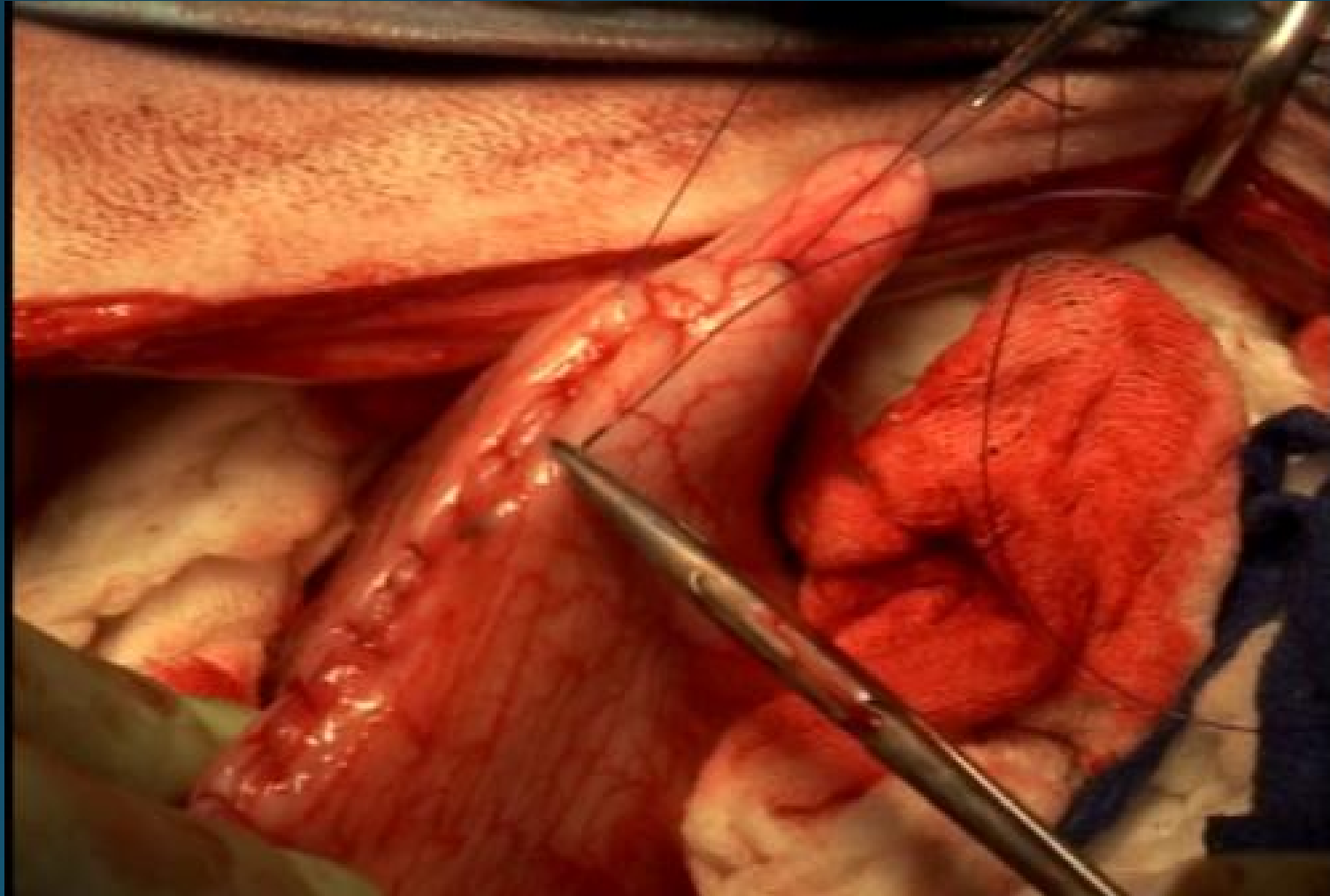


**Surgical gloves should be freed
from talc and starch.**

It result in adhesion



Two -layer closure of stomach has two benefits.



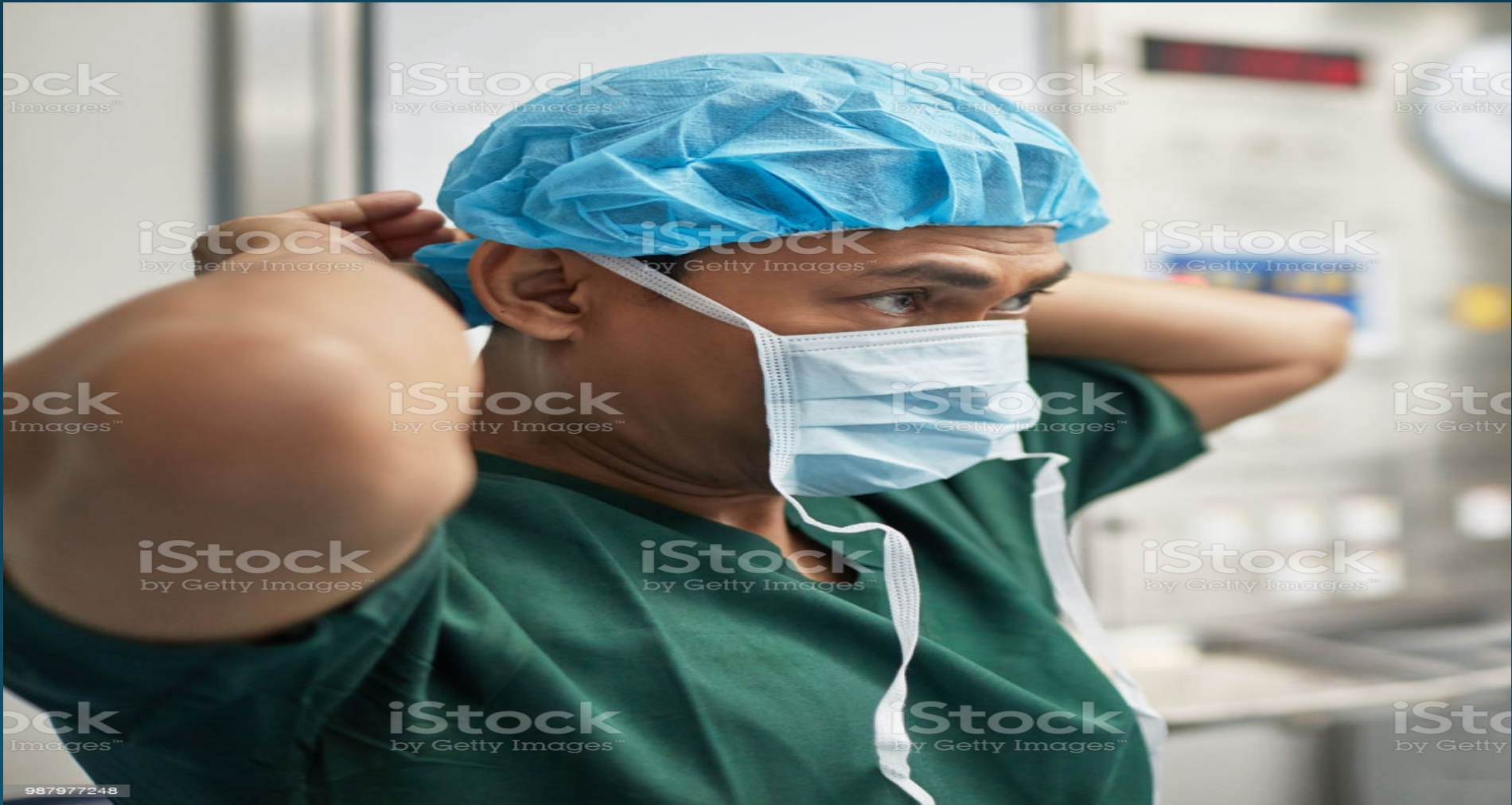- **What Are the Indications for Performing a Gastrotomy**

Foreign objects ,

Tumors ,

Ulcer.

- Surgeon preparation



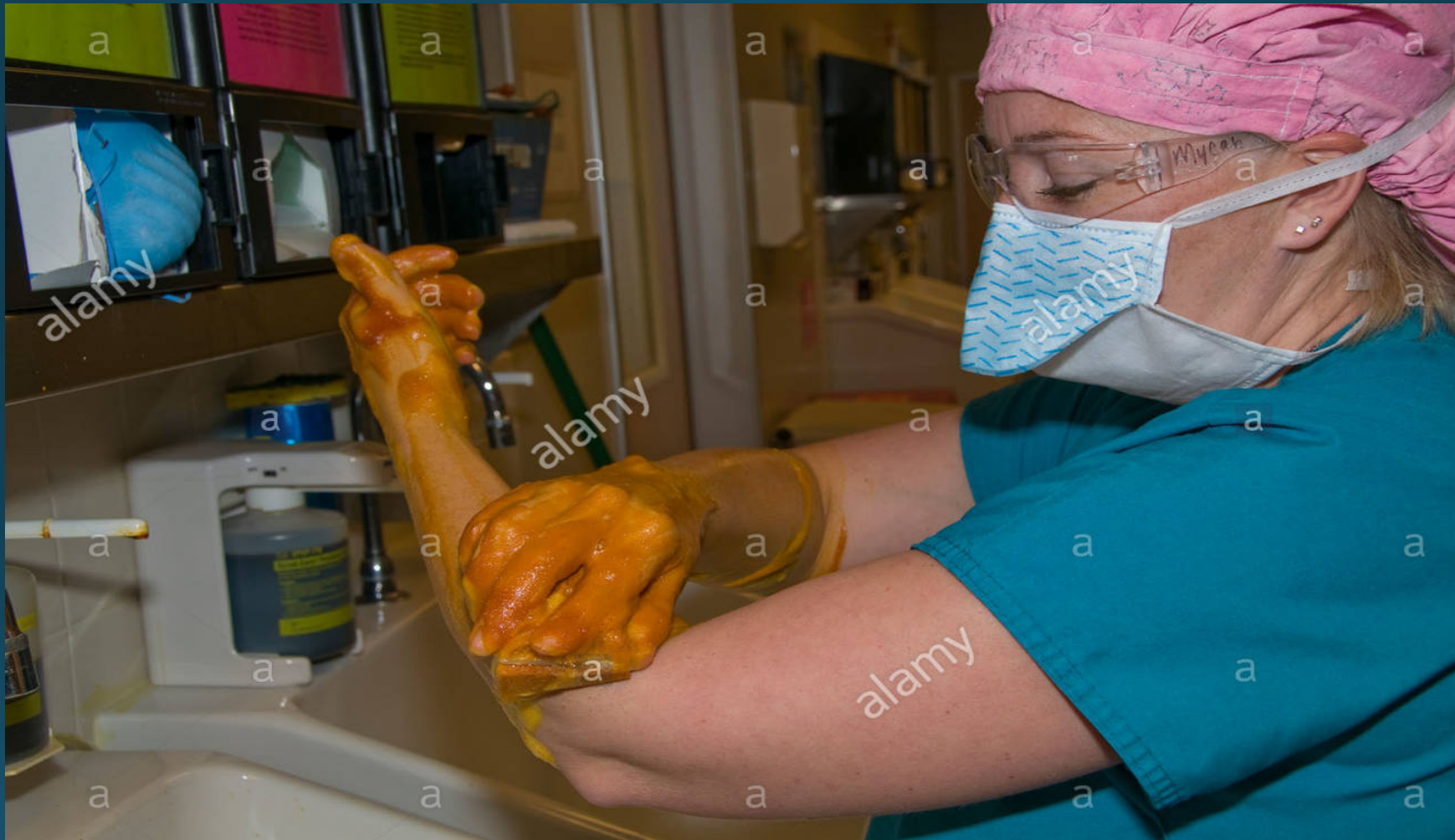987977248

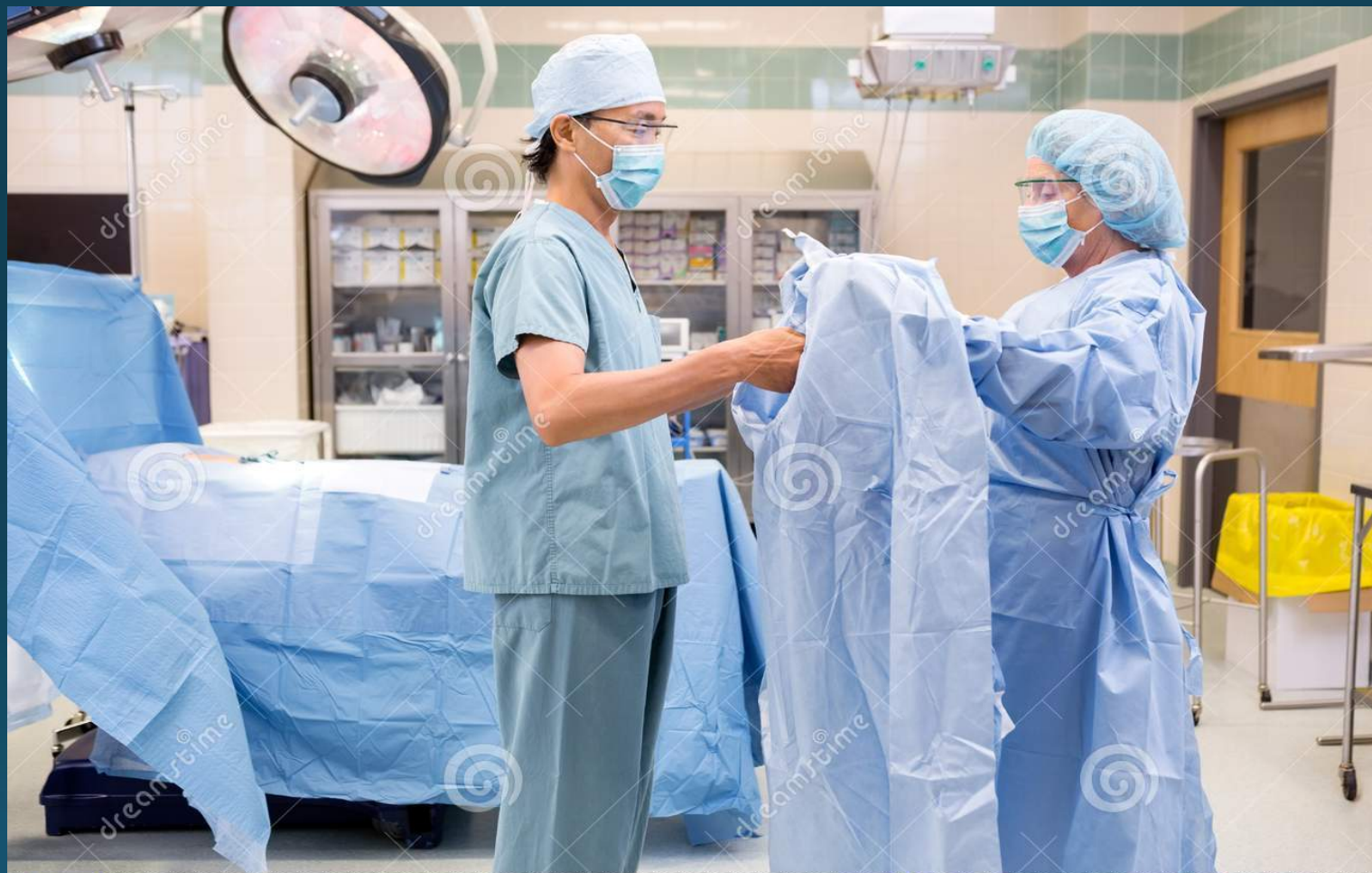

shutterstock

IMAGE ID: 1610648407
www.shutterstock.com





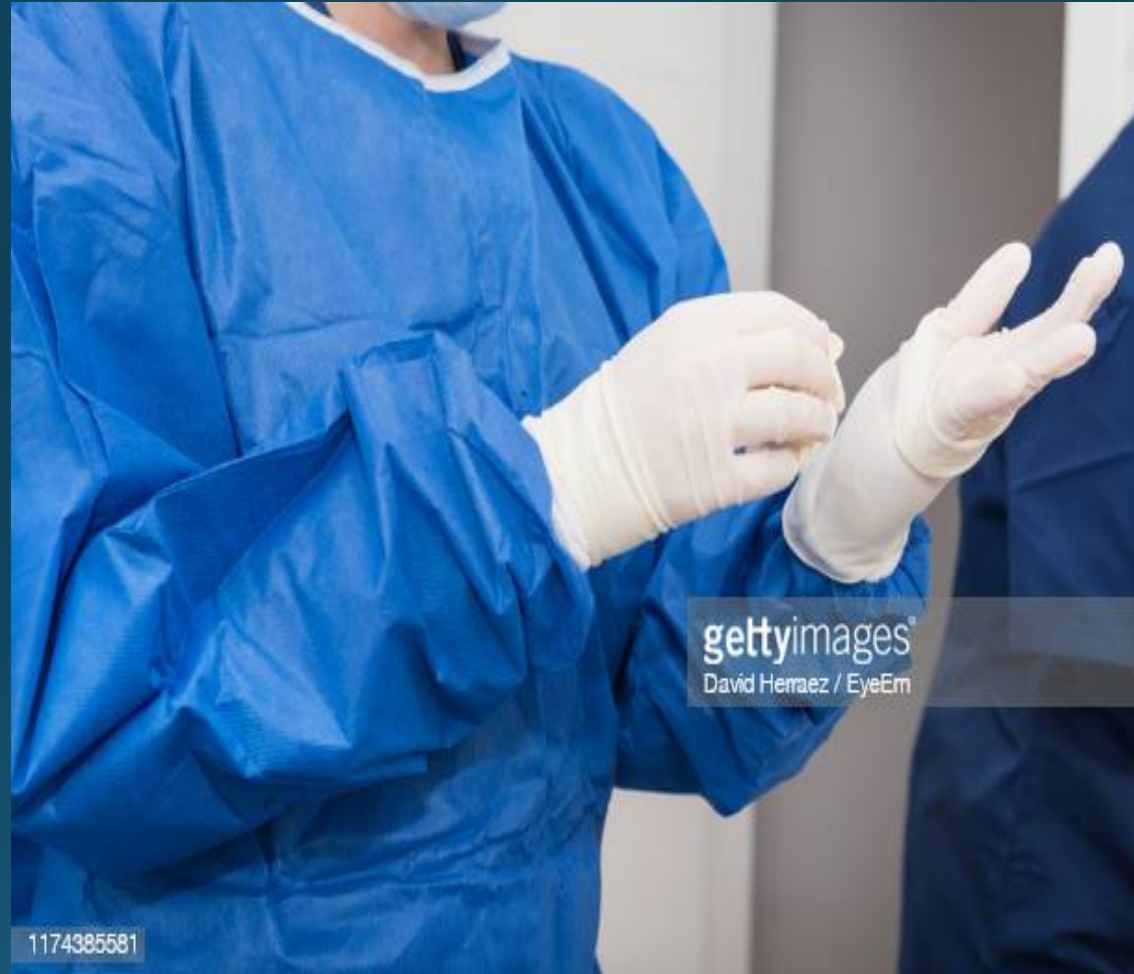

Download from
Dreamstime.com

This watermarked comp image is for previewing purposes only.

ID 36579551

© Tyler Olson | Dreamstime.com

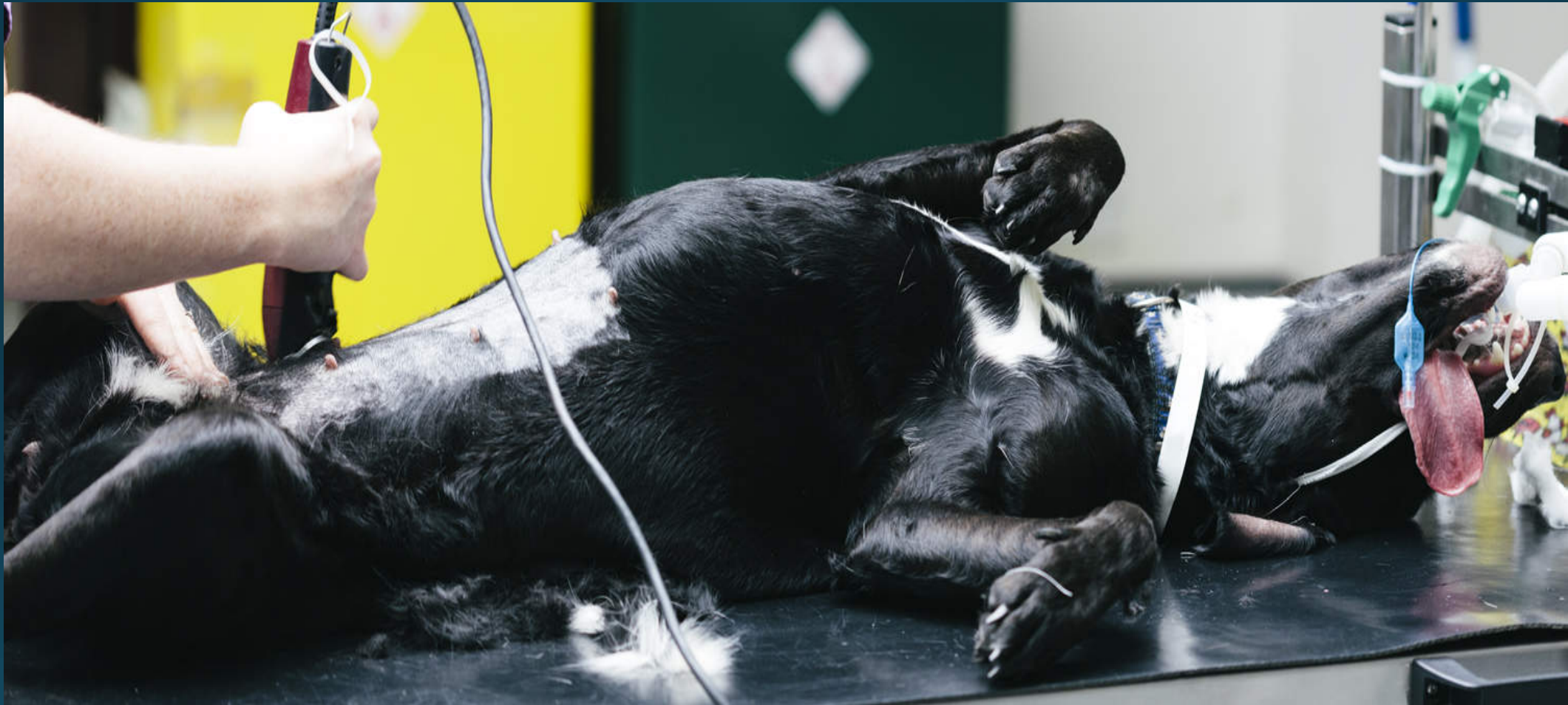

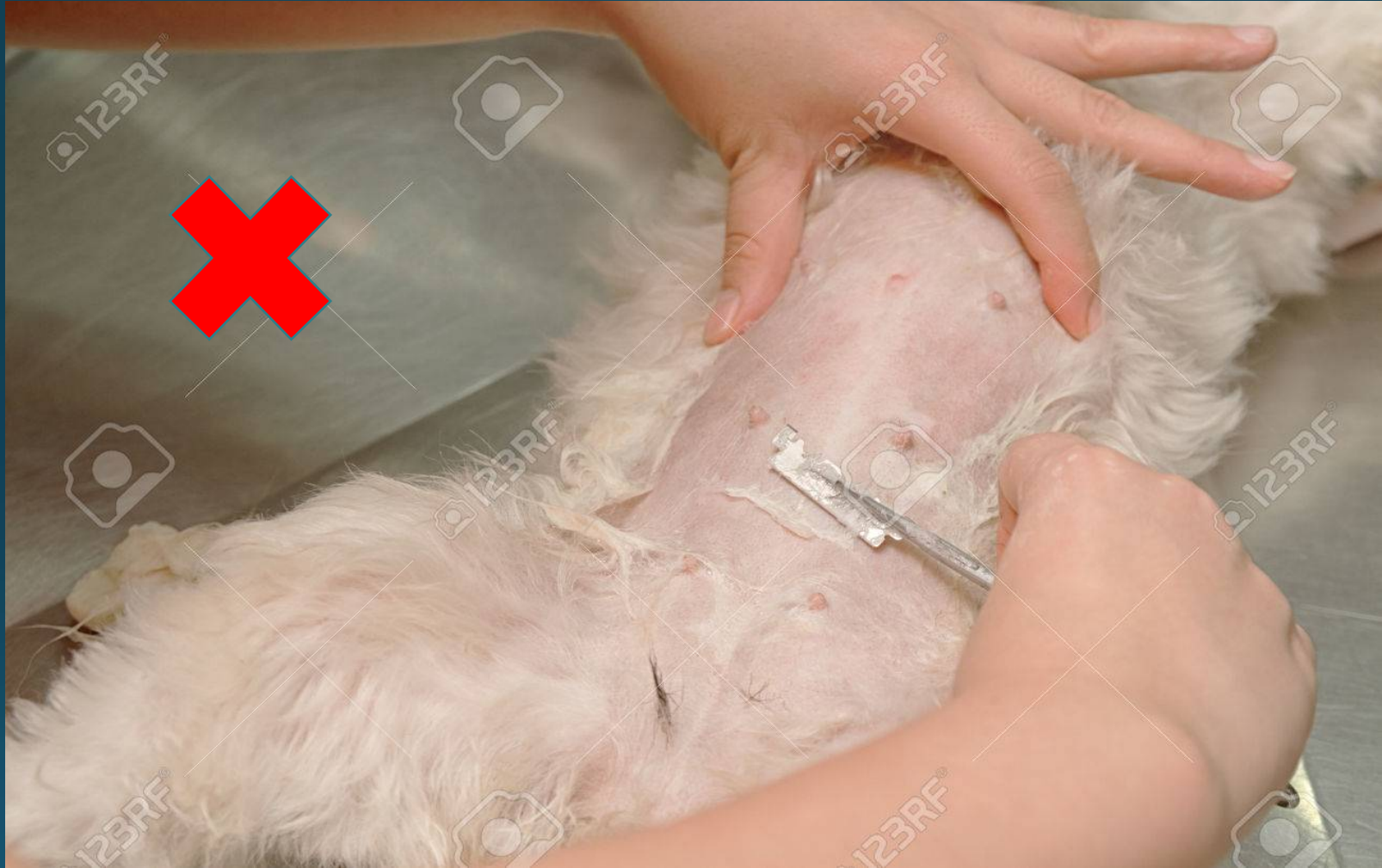gettyimages®
David Herrera / EyeEm

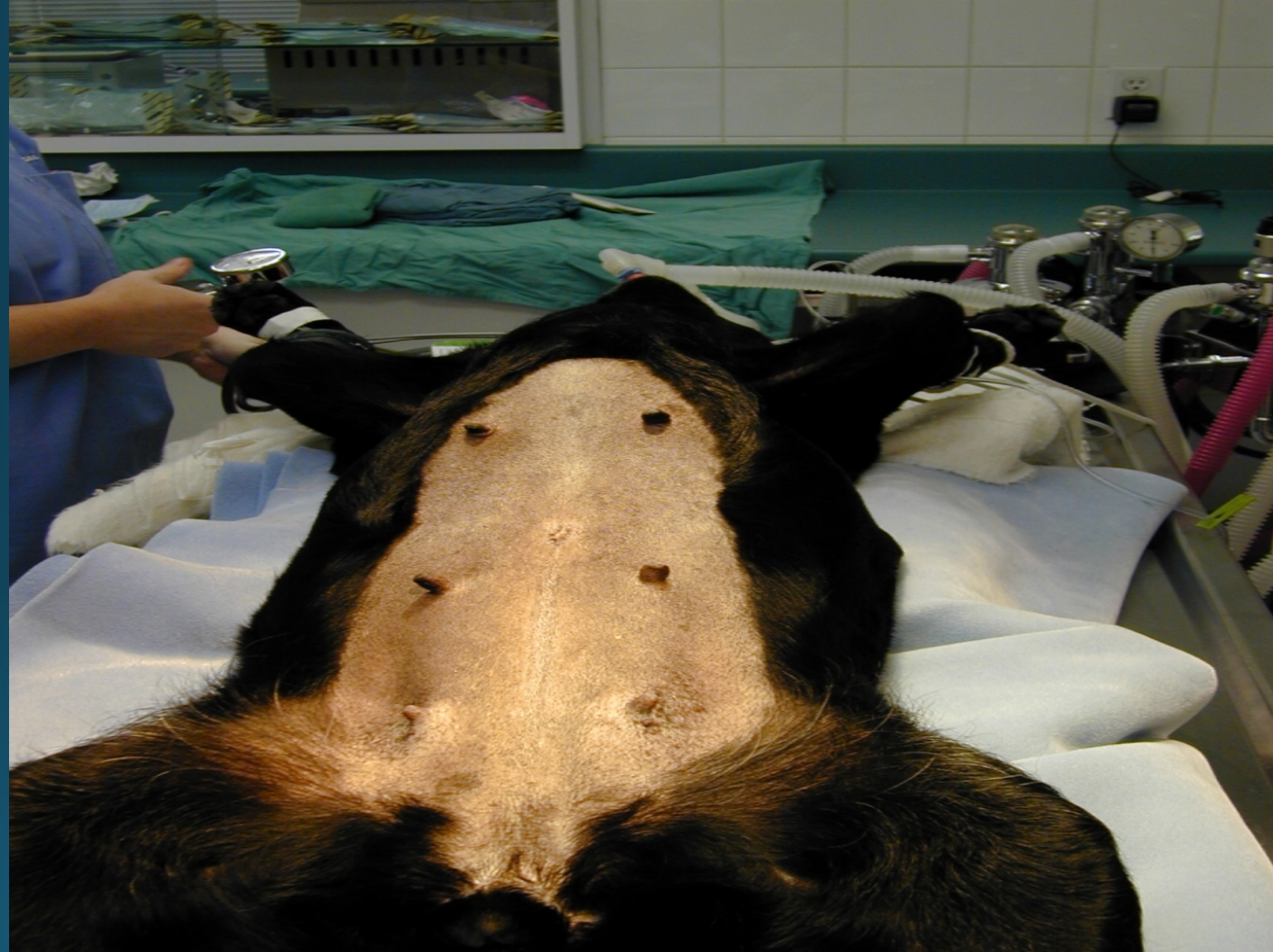1174385581

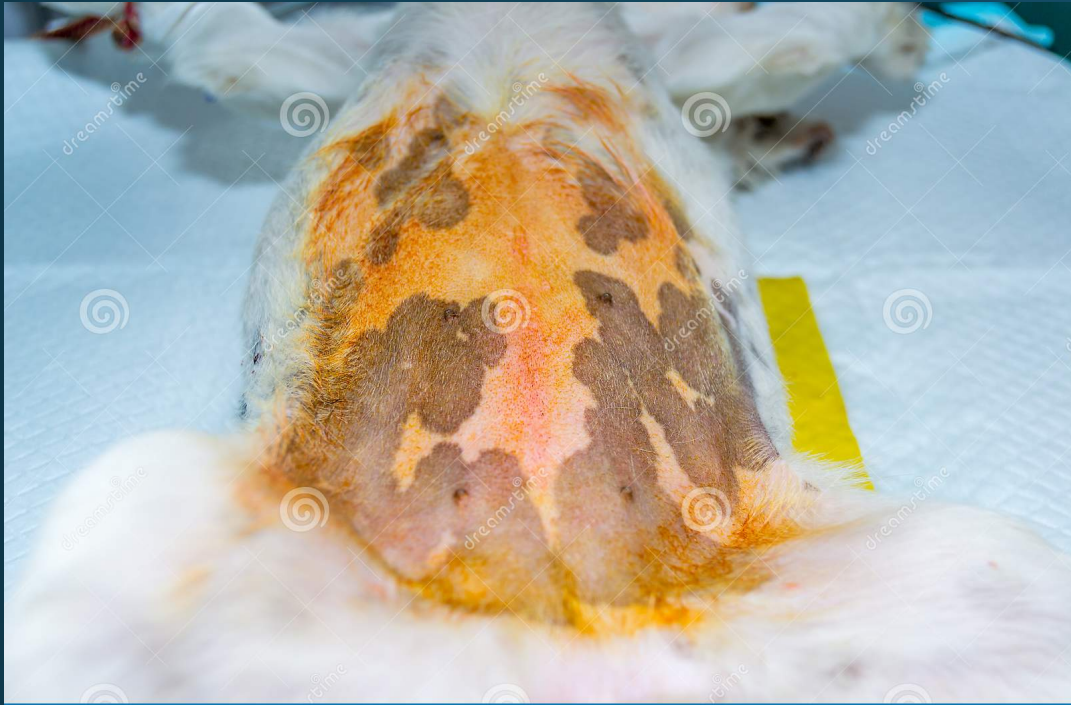

- **Patient preparation**



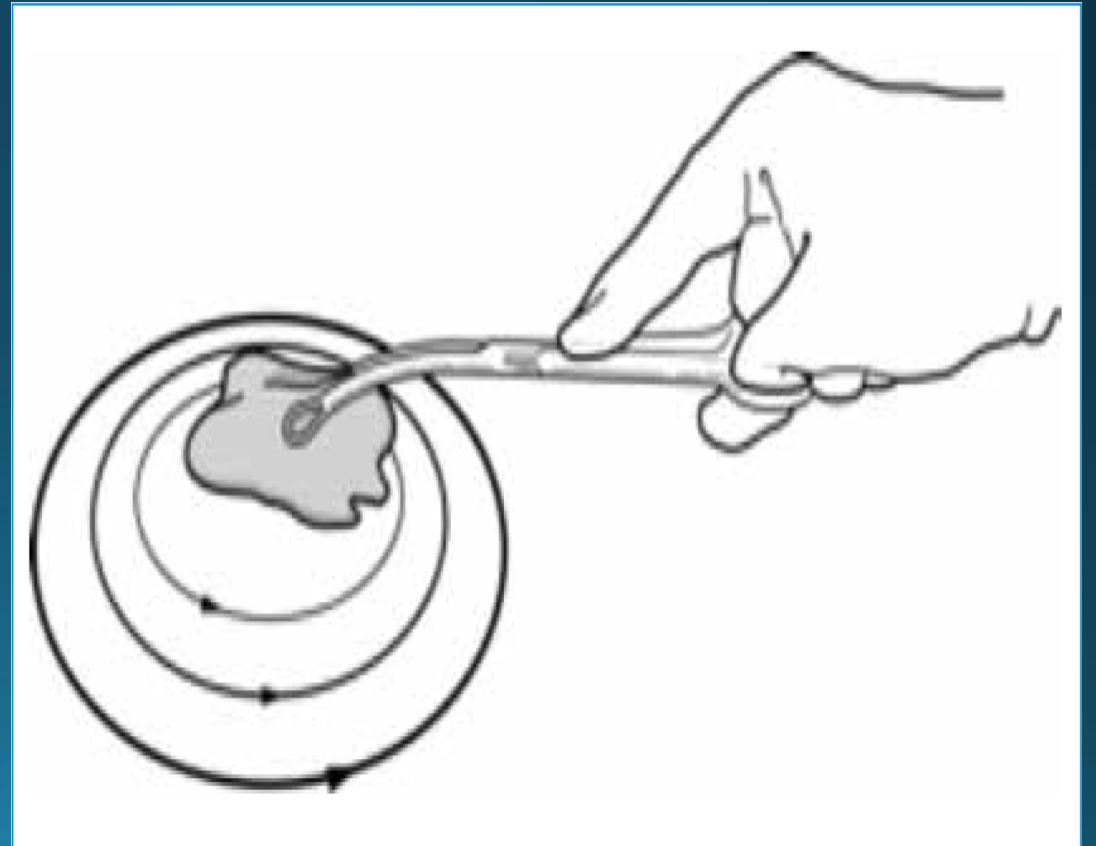


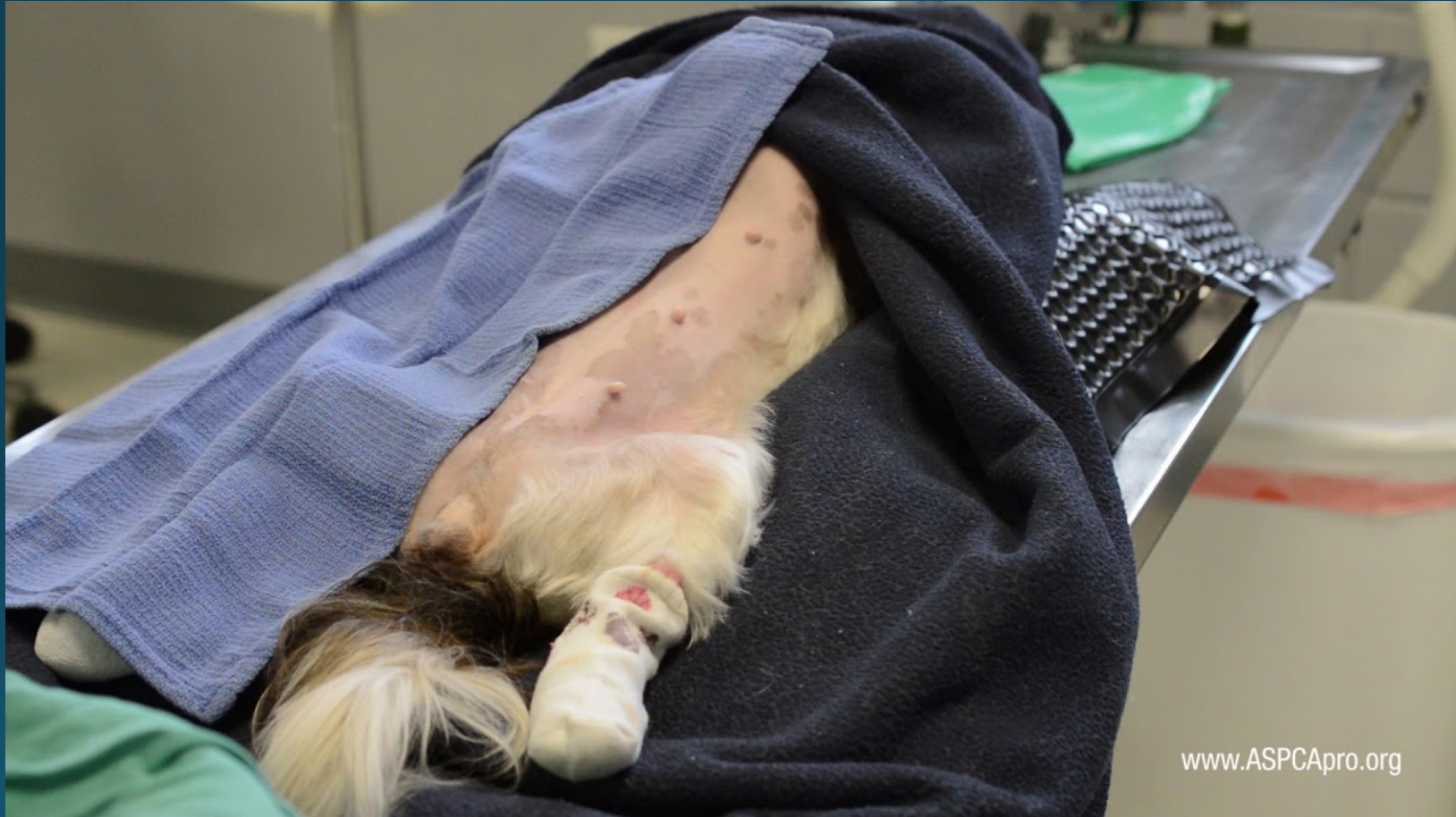



© dreamstime.com

ID 132275440 © Todoreangabriel





www.ASPCApro.org





