

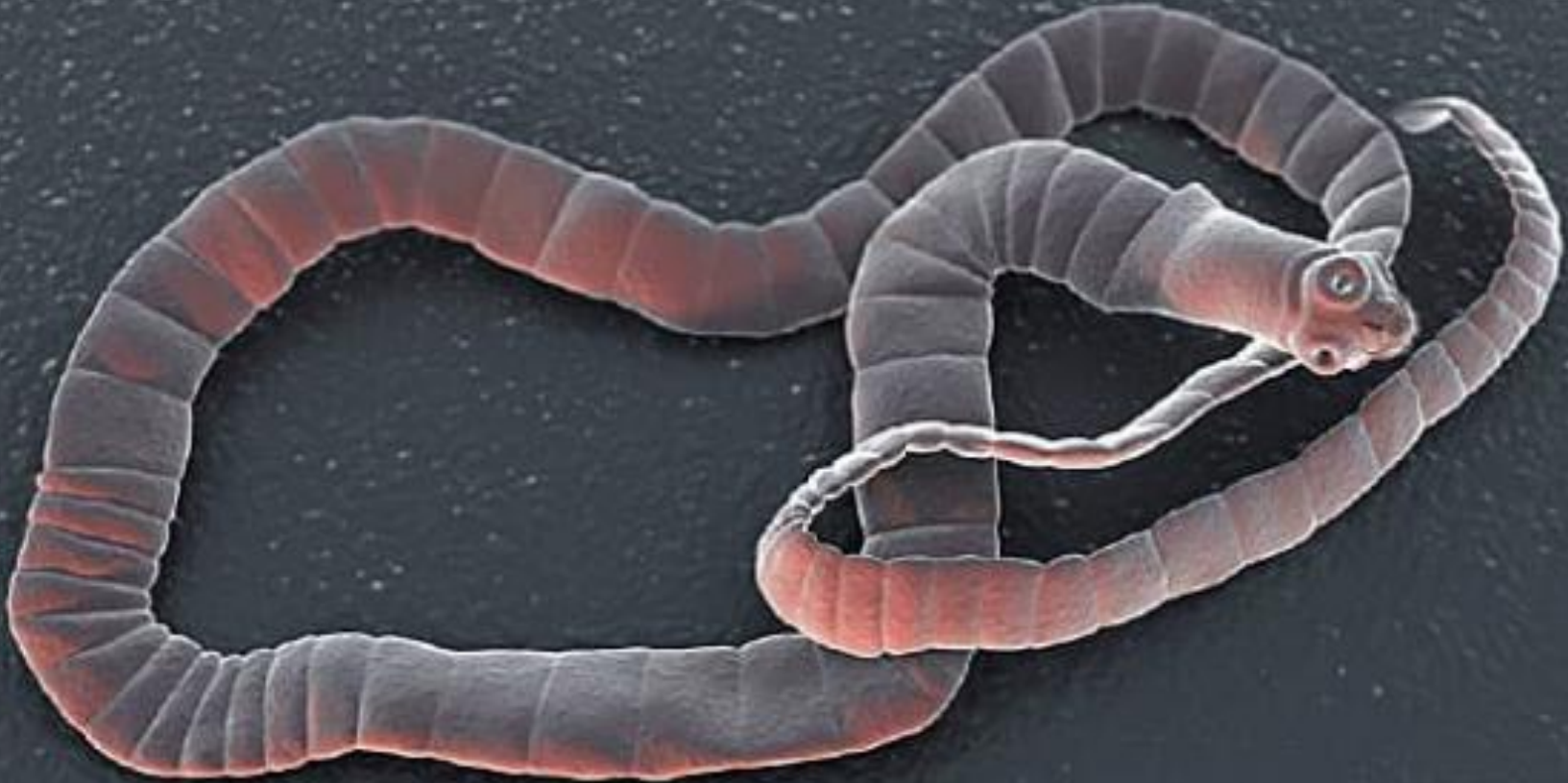جامعة البصرة
كلية التربية \القرنة \قسم علوم الحياة

• أ.د. علي ضرب شعبان

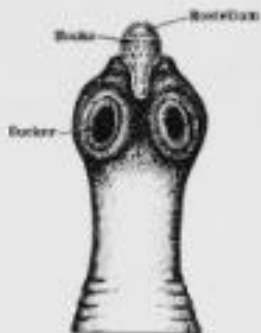
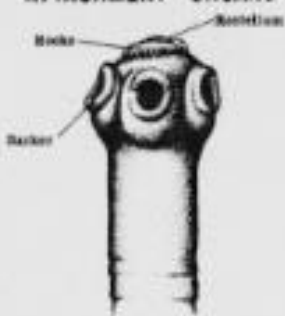
• الطفيليات

Platyhelminthes •

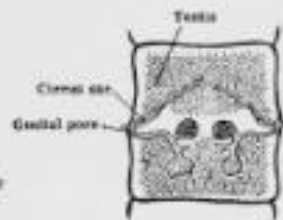
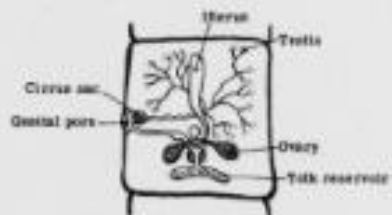
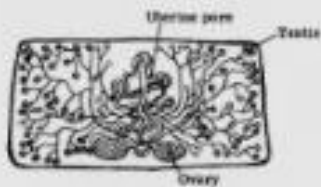
Class :Cestoda




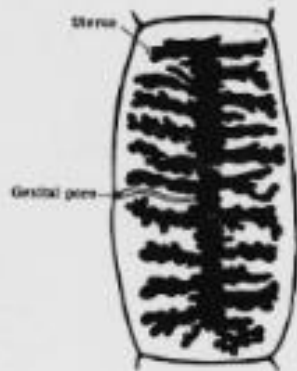
ATTACHMENT ORGANS



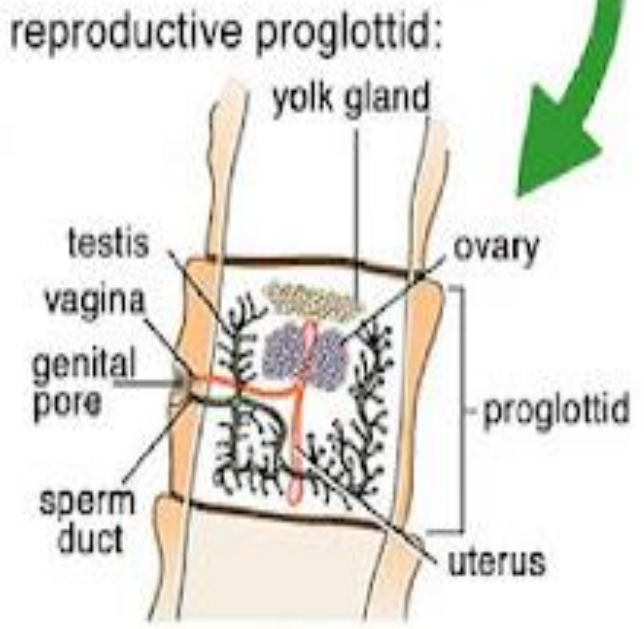
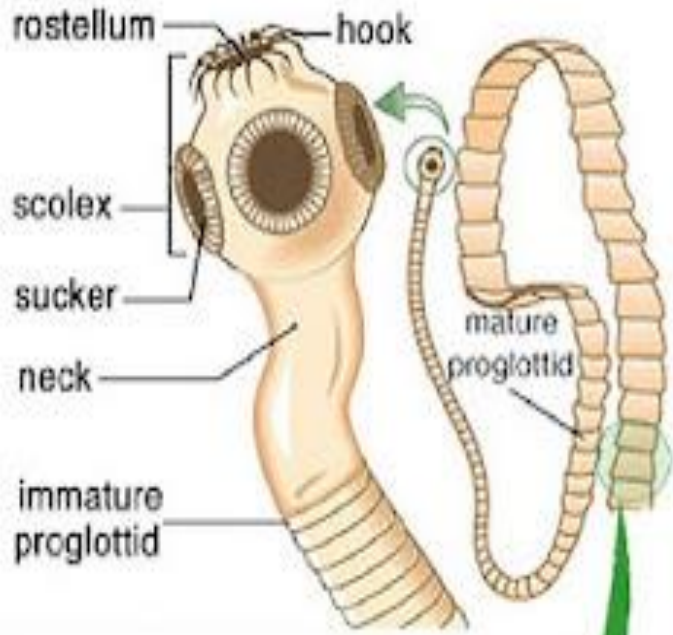
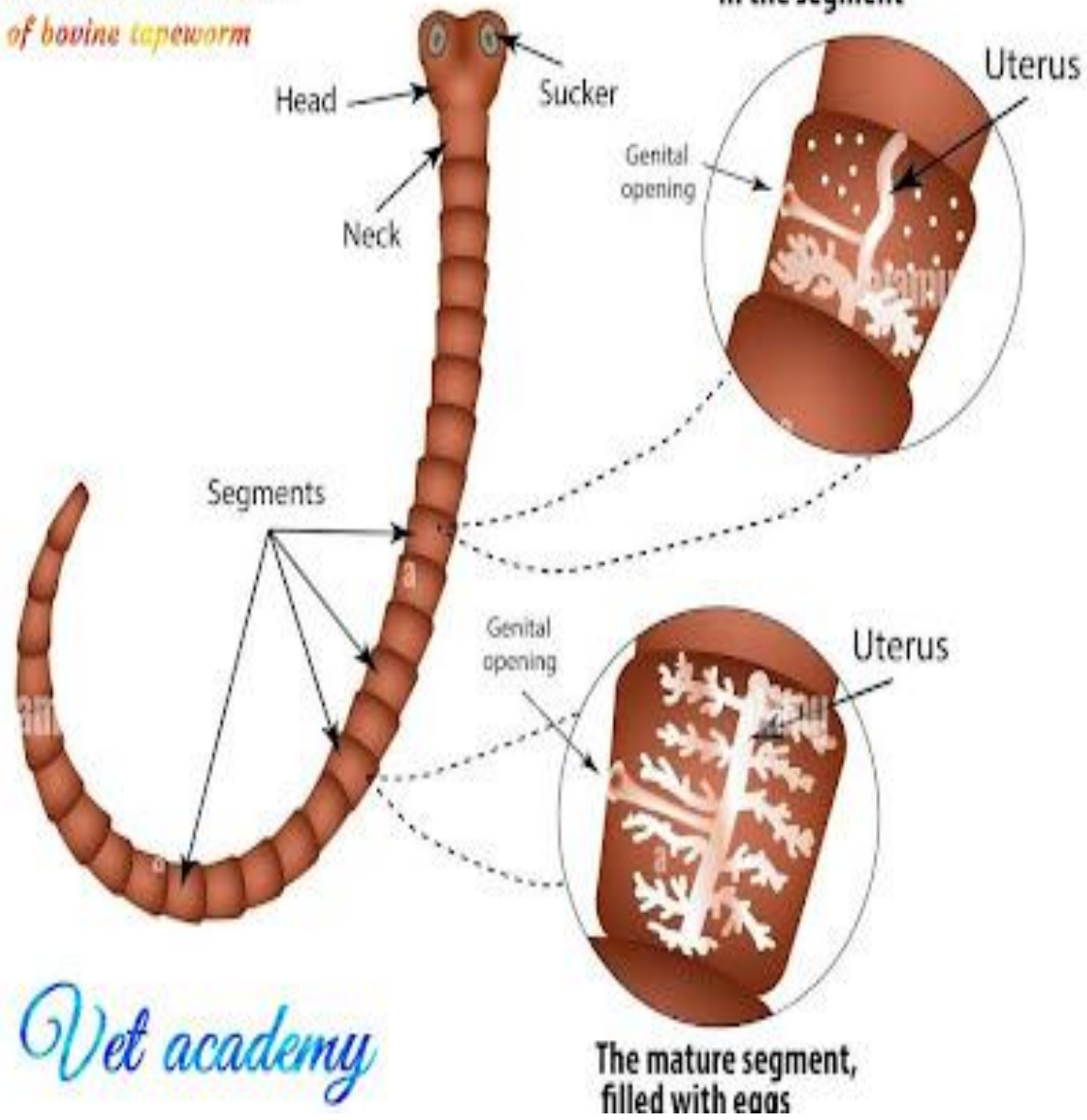
REPRODUCTIVE SYSTEM

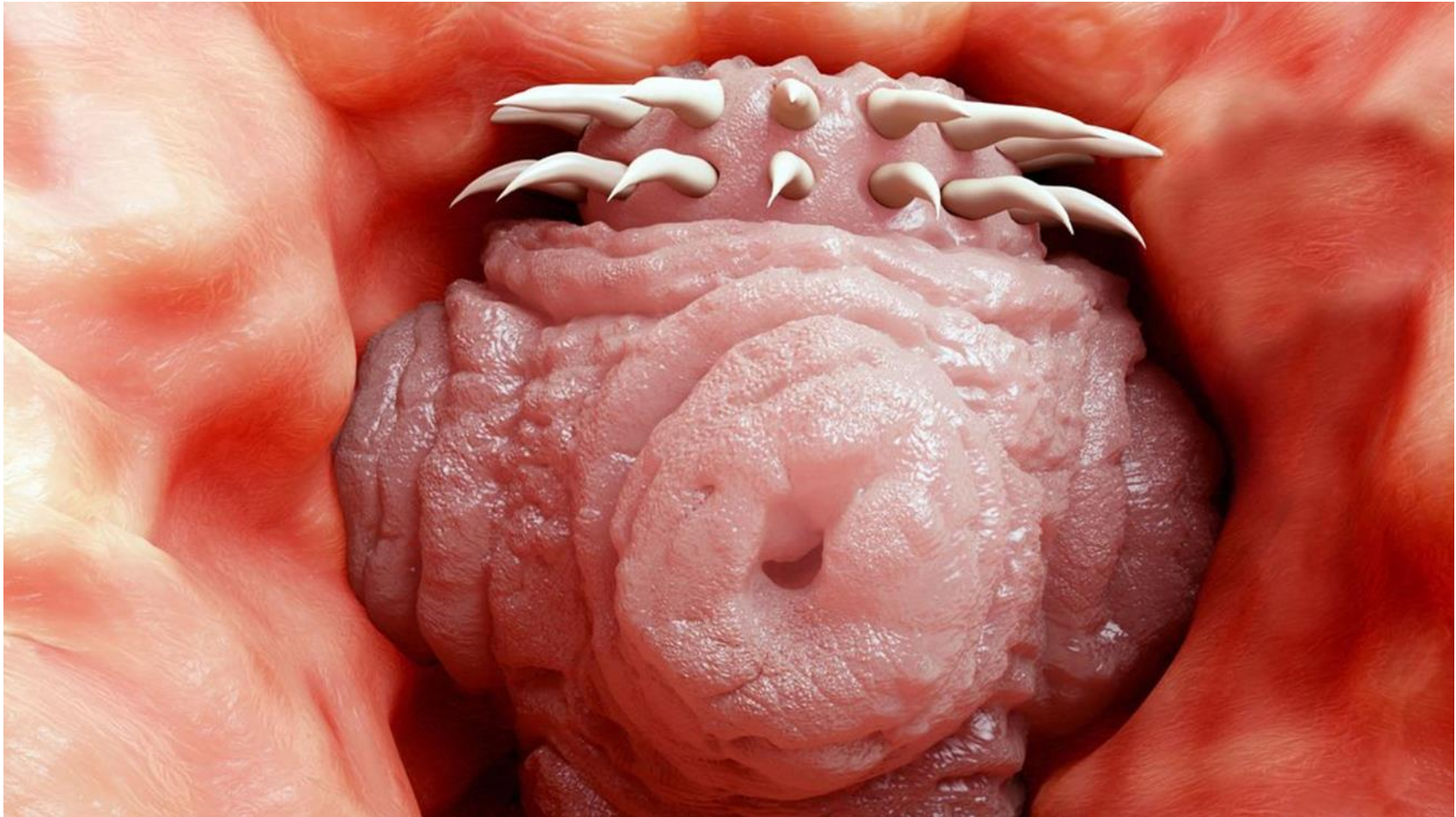


GRAVID PROGLOTTIDES



The structure of the reproductive organs of bovine tapeworm





Pseudophyllidean pattern

Cyclophyllidean pattern

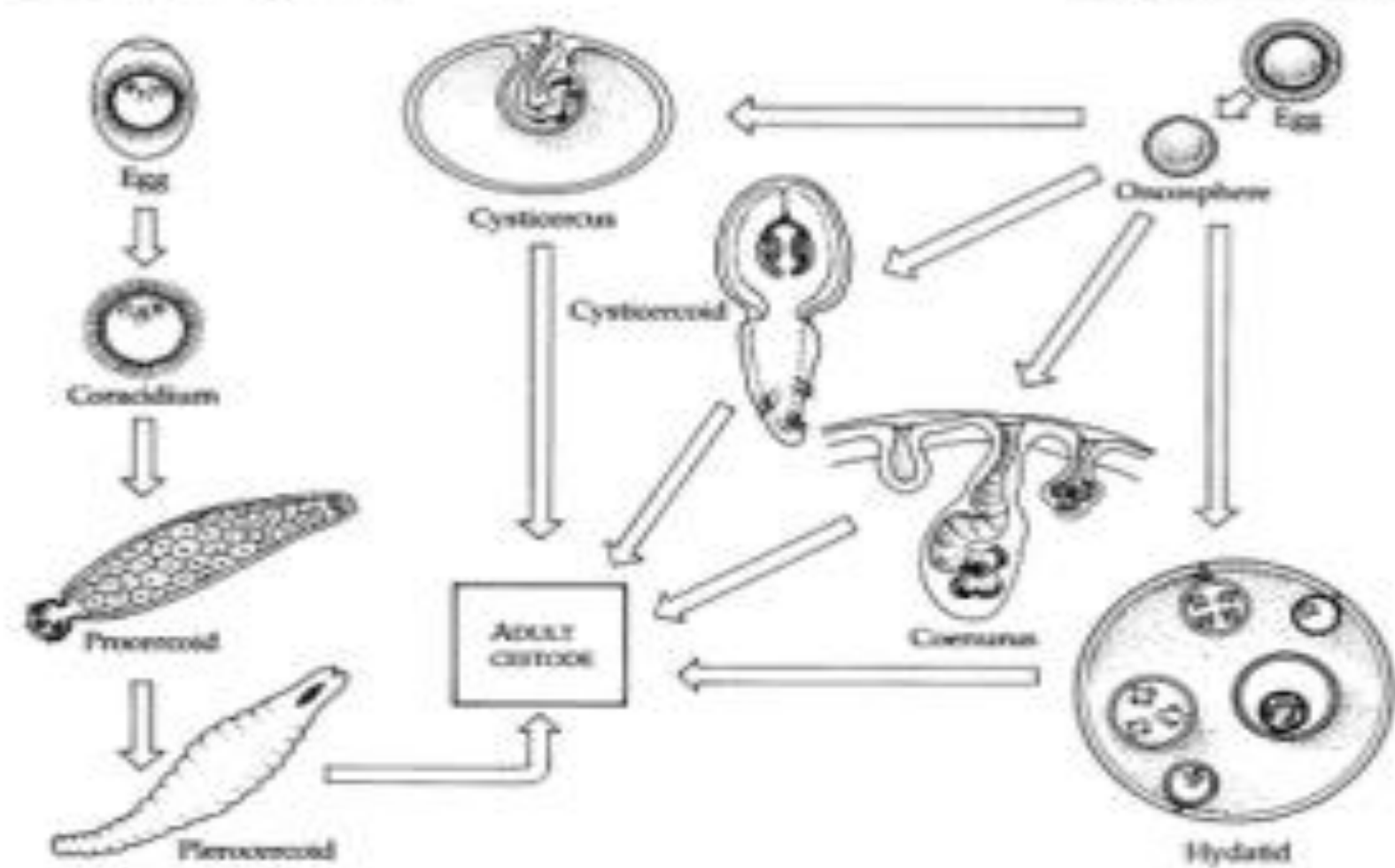
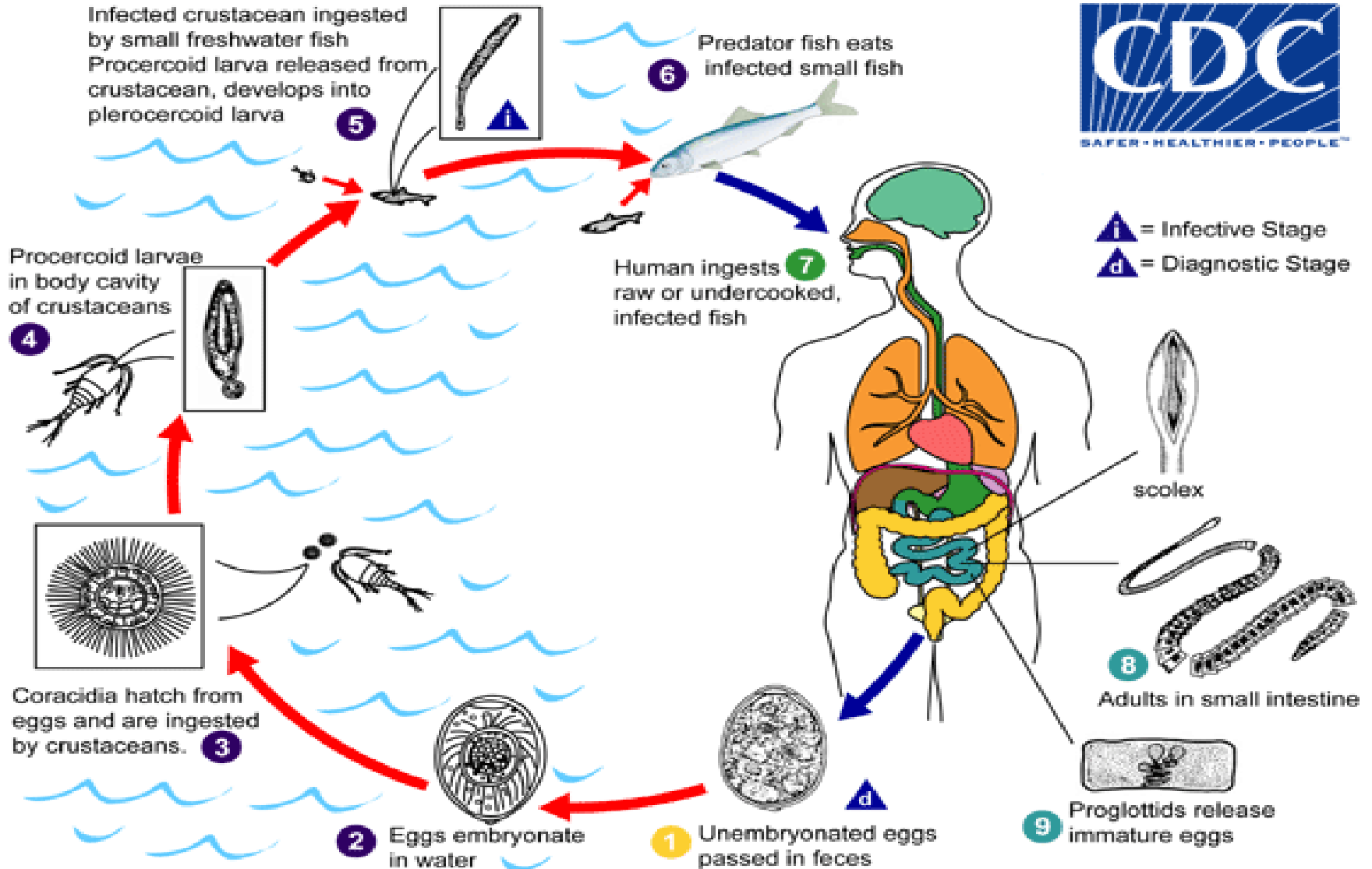
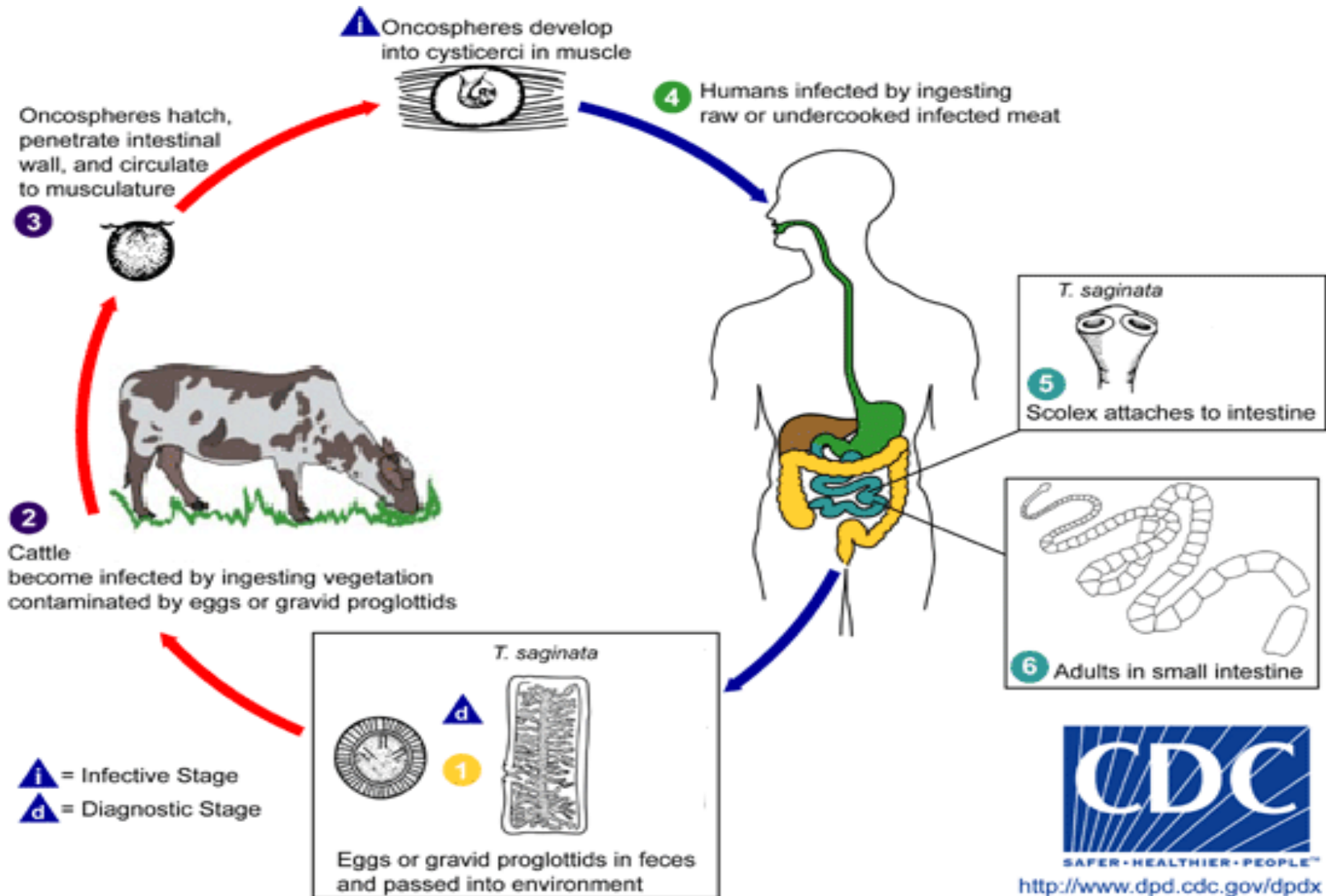


FIGURE 12-32 Life cycle patterns of tapeworms that infect humans.

Dihpyllobothrium latum life cycle



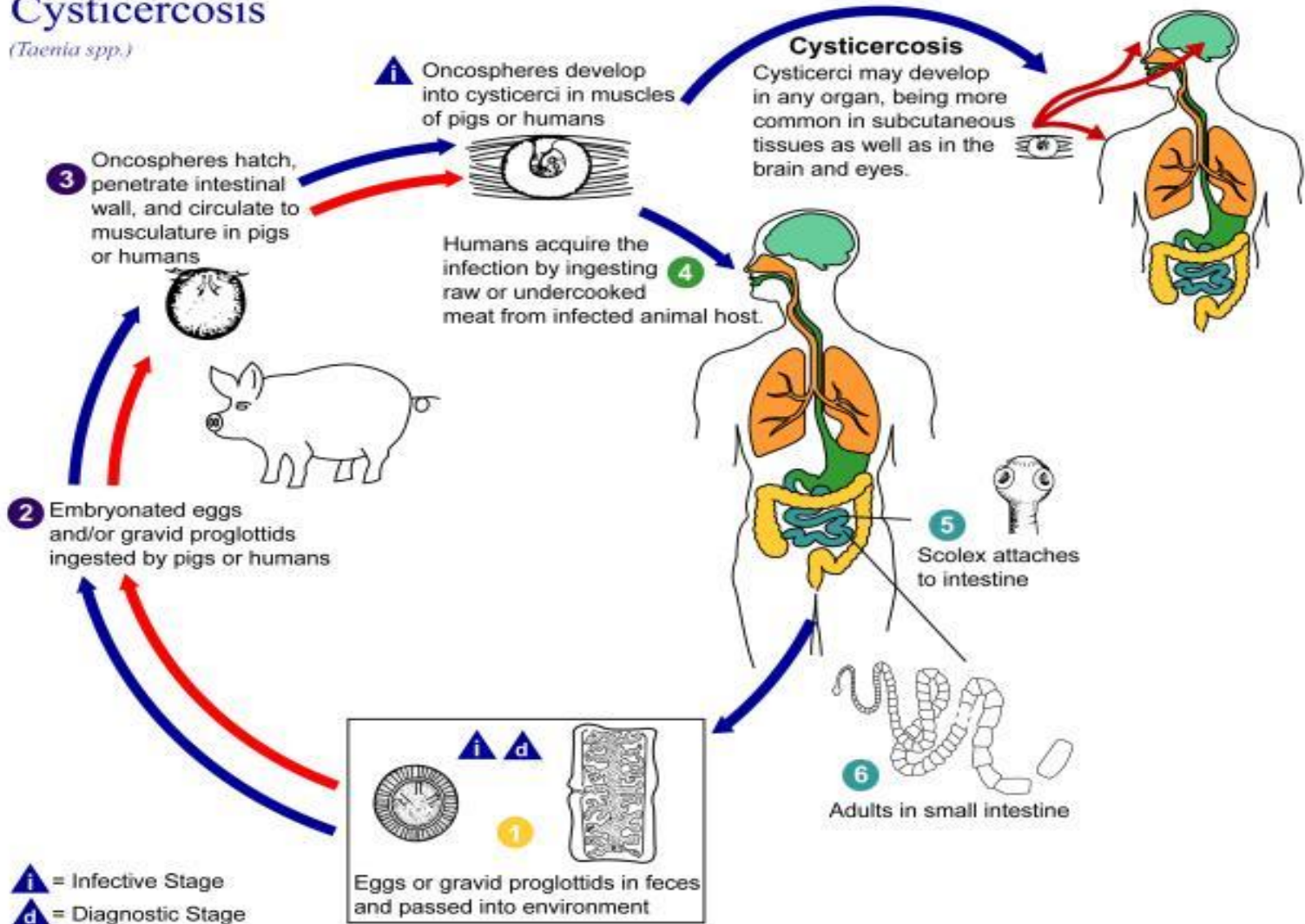
Taenia saginata life cycle



Taenia solium life cycle diagram

Cysticercosis

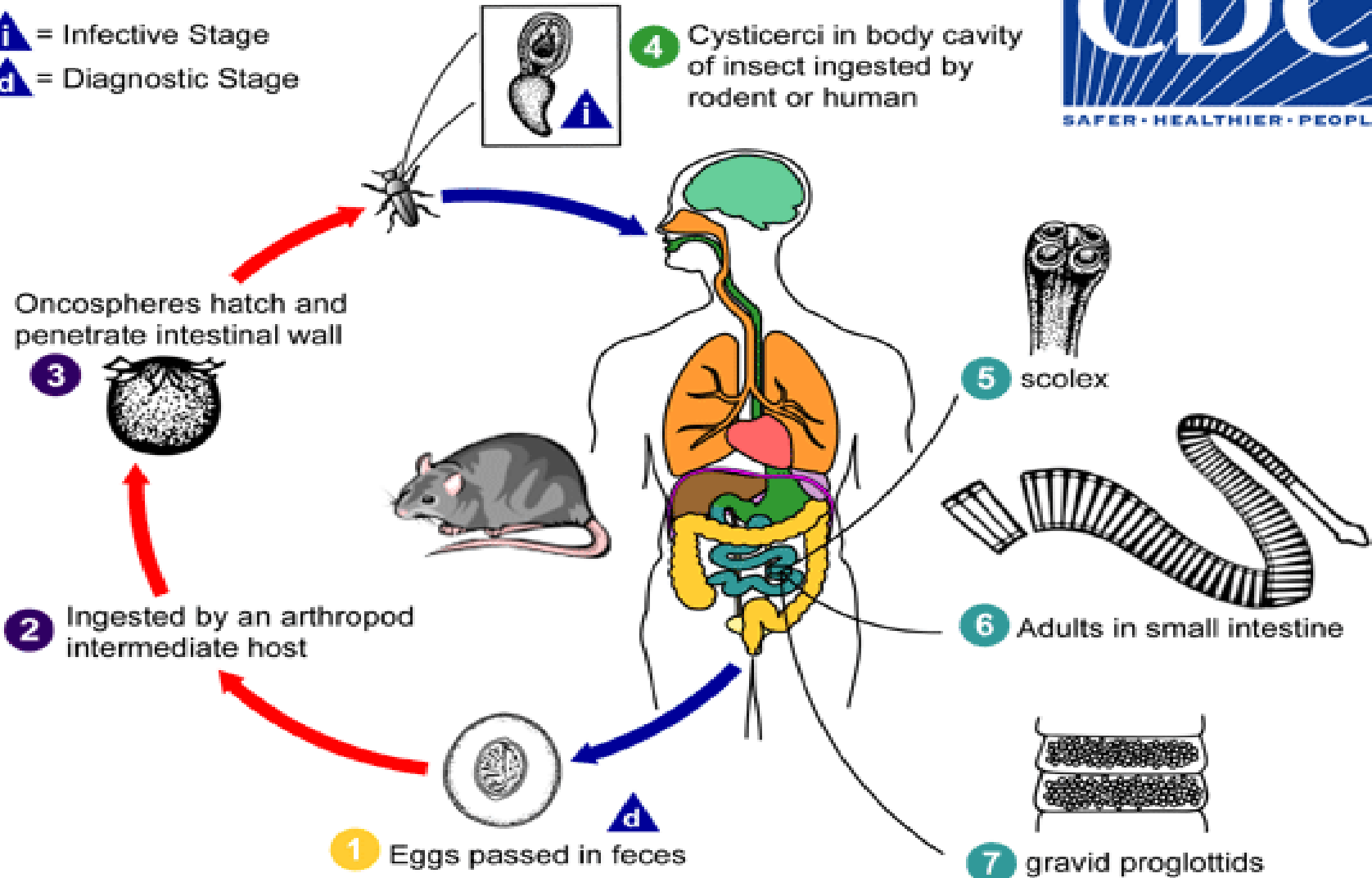
(*Taenia spp.*)



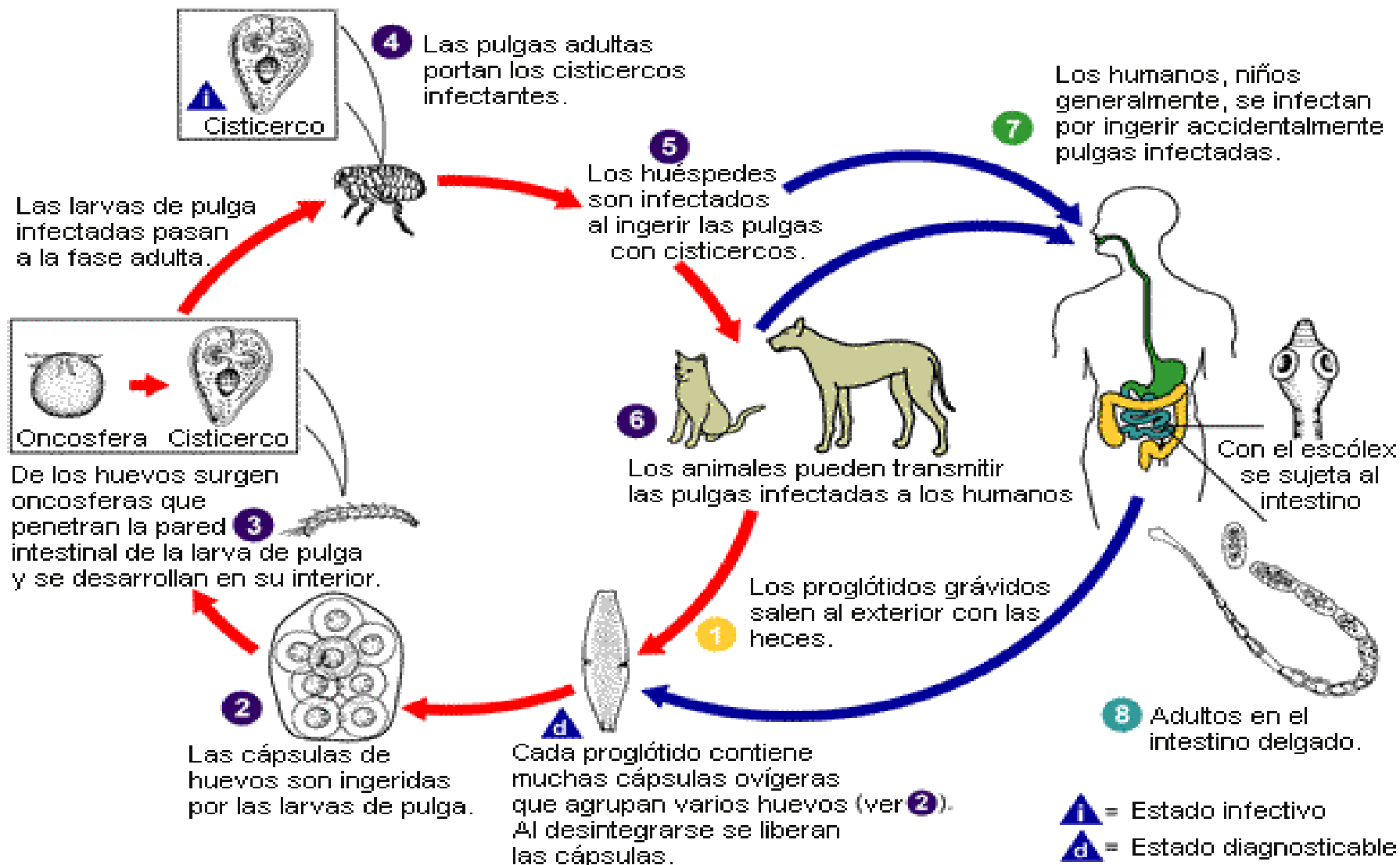
Hymenolepis nana



i = Infective Stage
d = Diagnostic Stage



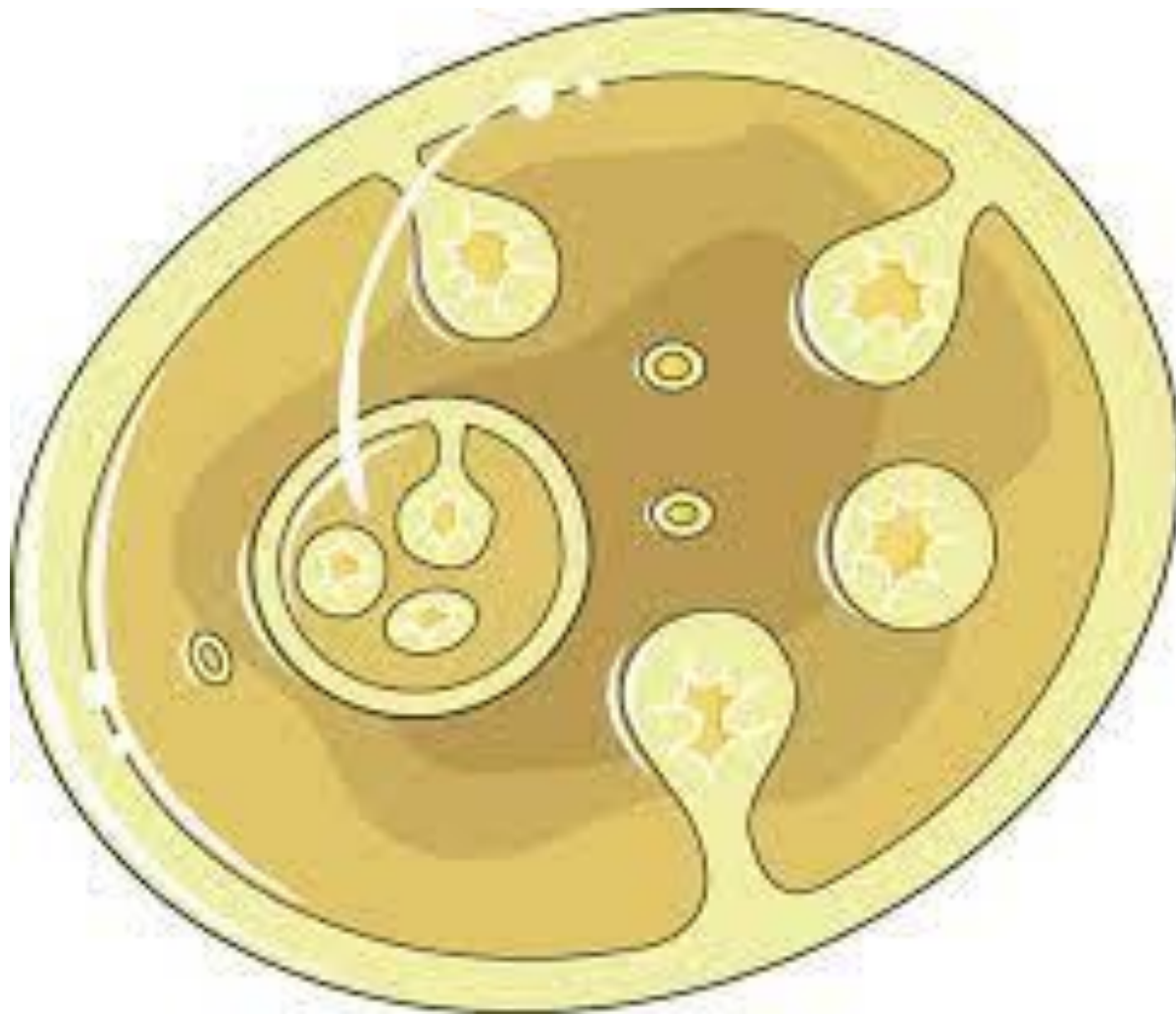
Dipylidium caninum

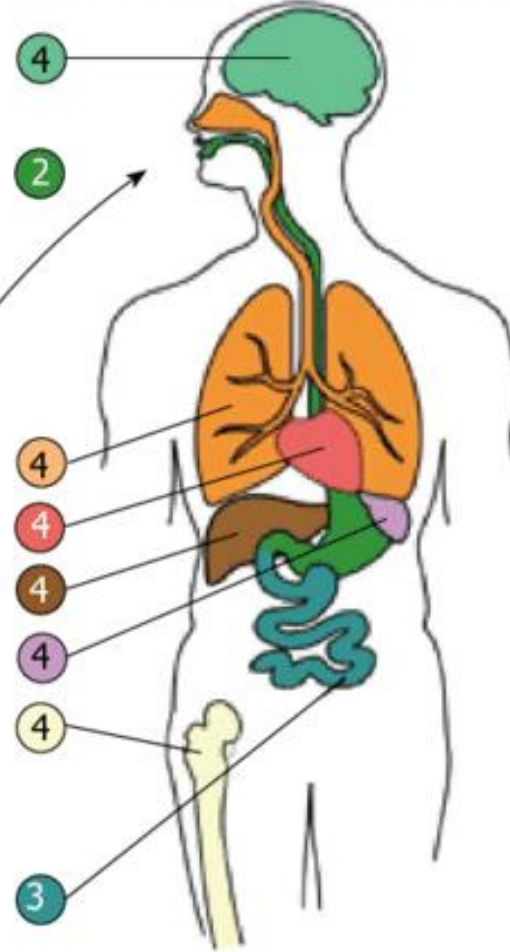
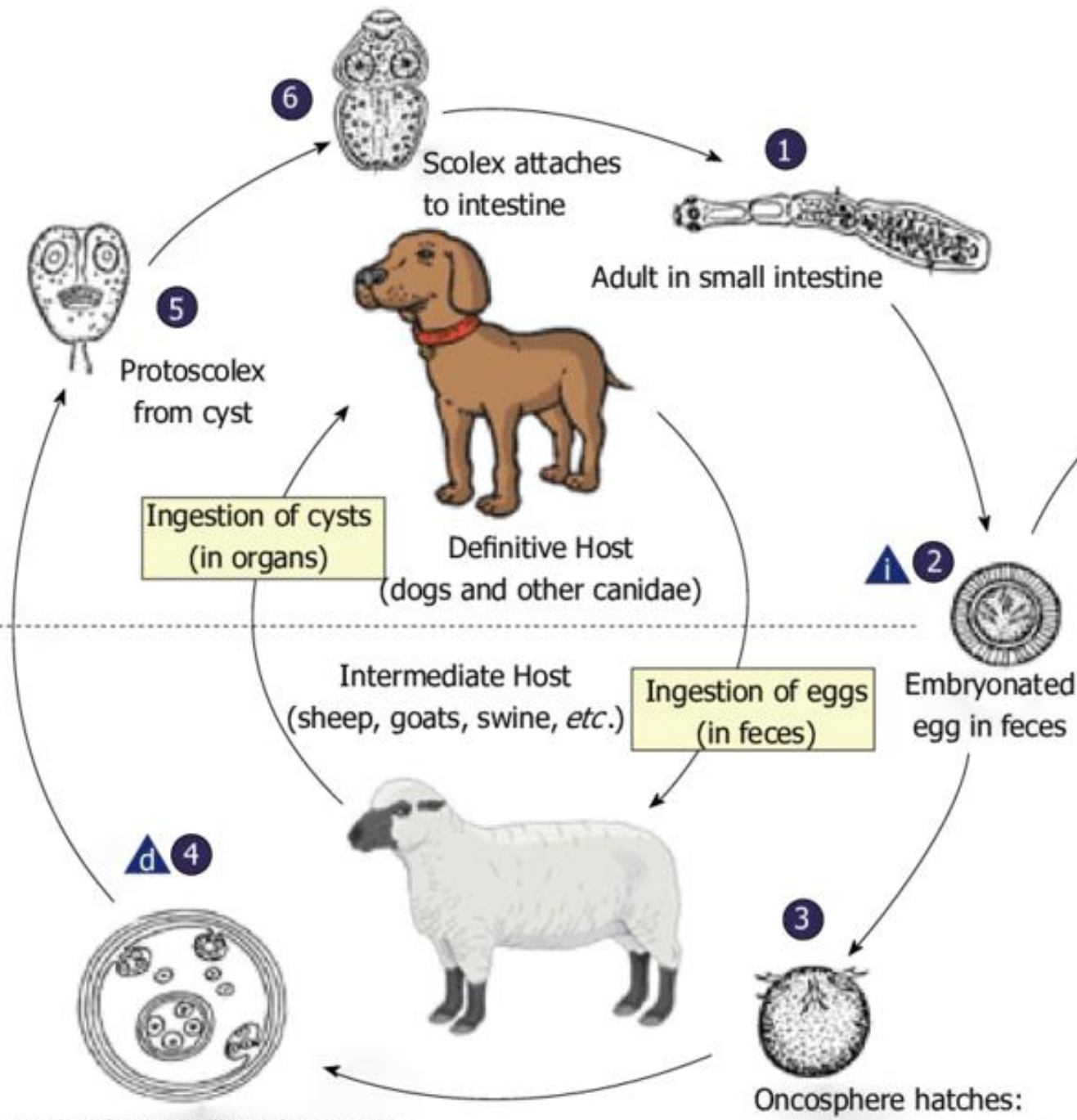


Echinococcus granulosus



الكيس المائي





i = Infective stage
d = Diagnostic stage

Hydatid cyst in liver, lungs, etc.

Oncosphere hatches: penetrates intestinal wall

اليرقة المثانية لدودة الخنزير الشريطية

T.solium Cysticercus

- Heteroinfection
- External autoinfection
- Internal autoinfection

• الأعراض