



University of Basrah
College of Dentistry, Department of
Oral Diagnosis

HUSSEIH SH. AL-ESSA

B.D.S., M.Sc. (oral medicine)

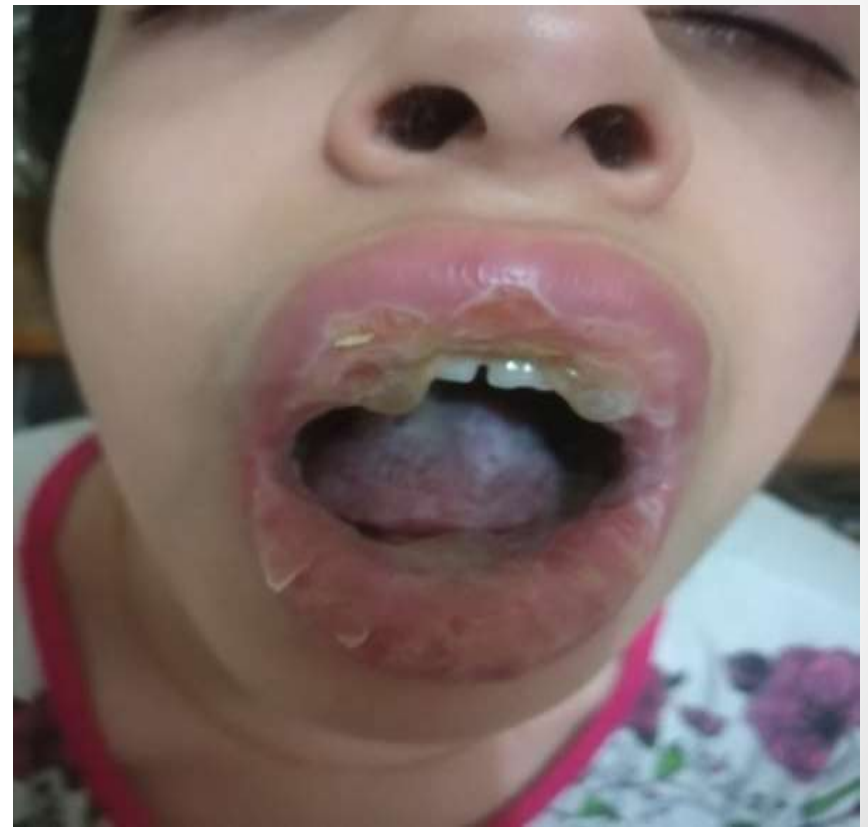husseinalessa97@gmail.com

Cases Presentation

Case Presentation

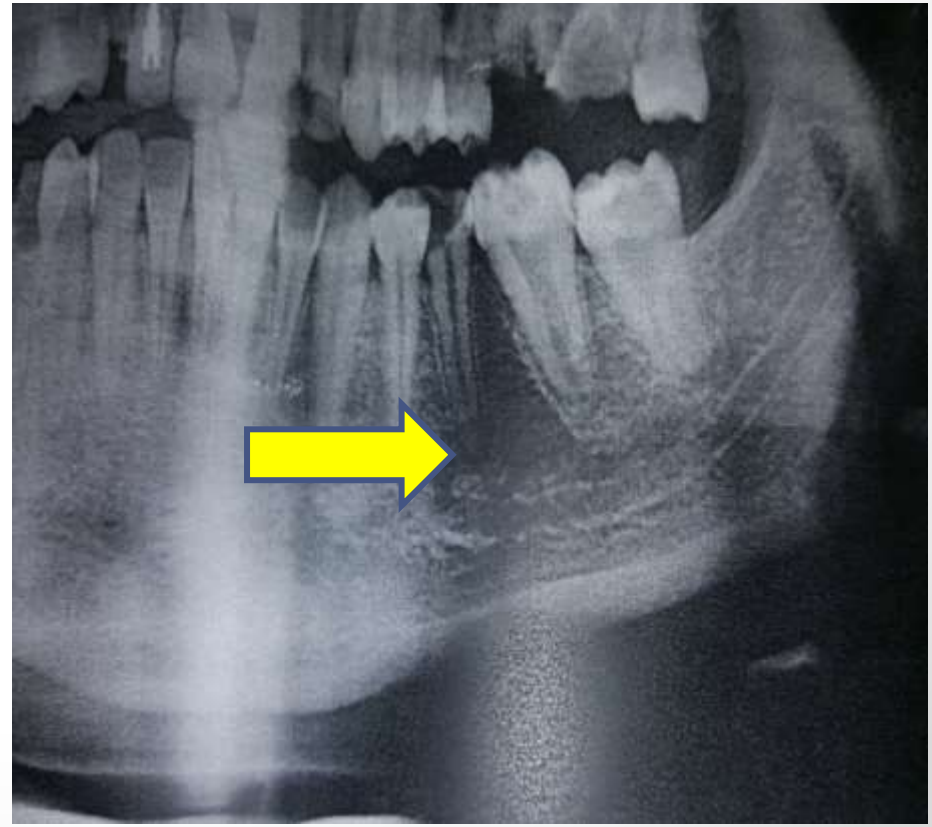
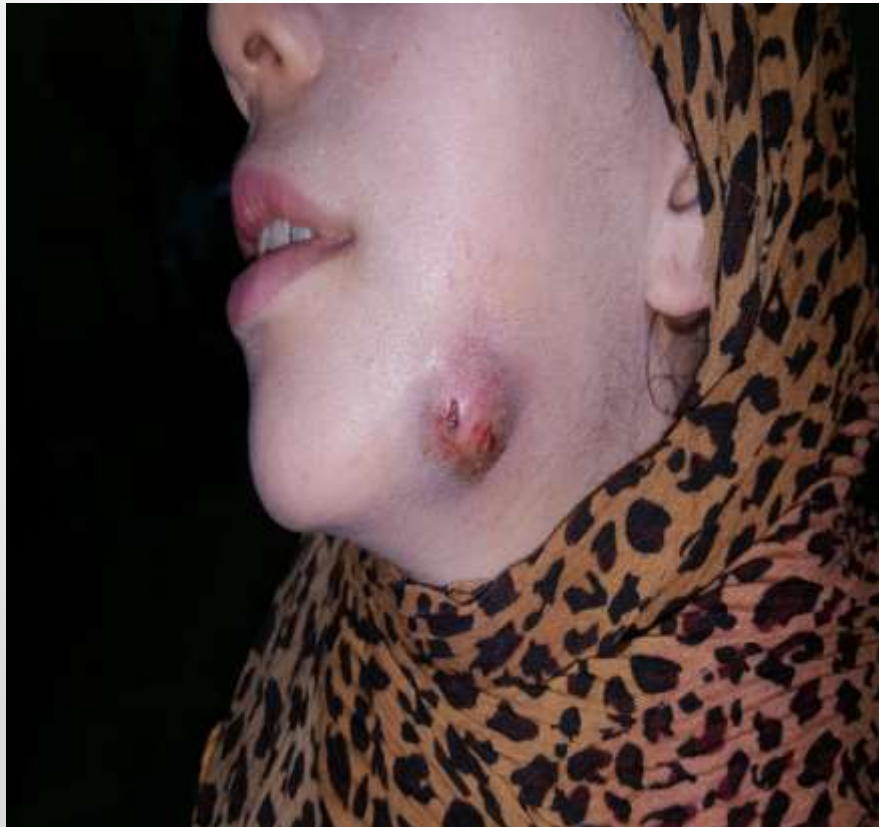- 16 year female patient, presented with extensive lip and oral ulceration, 5 days duration with moderate fever and cervical lymphadenopathy, patient with bad odor and difficult to swallowing. No response to antibiotic therapy:

- 1) D.D
- 2) Lines of Treatment



Case Presentation

32 years old female patient presented with recurrent facial swelling , mild fever and tenderness extraorally and intraorally, patient wear poorly non hygienic sharp fixed bridge from 34 to 44.
How to manage this case in ideal clinical sequences ?



THANK YOU