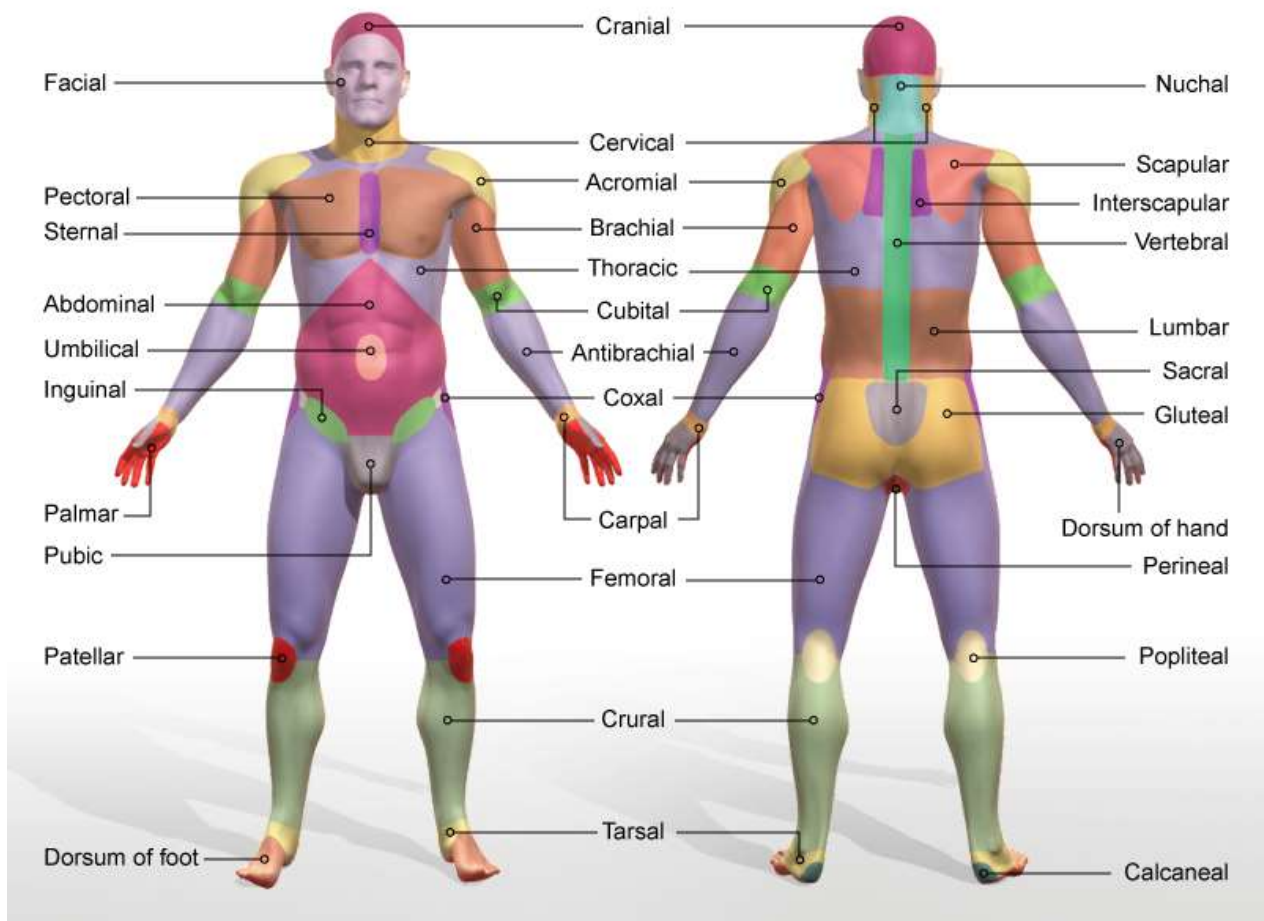

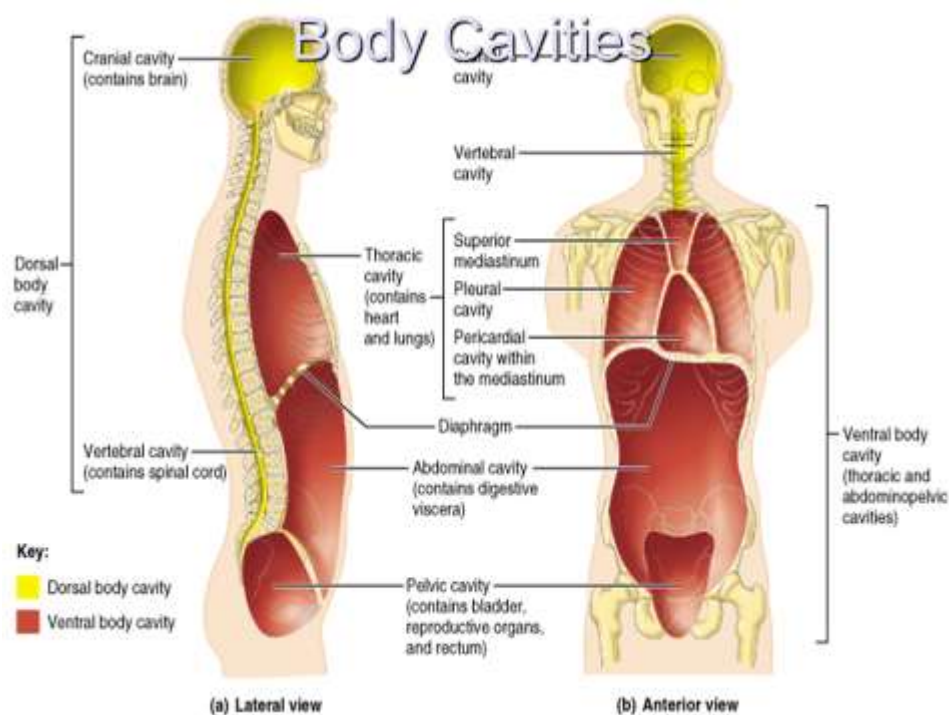
<b>Axial regions</b>	<b>Description (pertaining to)</b>
Cephalic	Head
Frontal	Forehead
Facial	Face
Occipital	Back of the head
Orbital	Eye cavity
Buccal	Cheek
Thoracic	Chest
Sternal	Sternum
Umbilical	Navel (belly button)
Inguinal	Groin
Pubic	Mons pubis (pubic bone)
Genital	Reproductive organs
Perineal	Perineum
Dorsum	Back
Vertebral	Spinal column
Cervical	Neck
Thoracic	Middle of the back
Lumbar	Lower back
Sacral	Sacrum

<b>Appendicular regions</b>	<b>Description (pertaining to)</b>
<b>Upper limb</b>	
Pectoral	Chest
Clavicular	Clavicles
Acromial	Acromion of the shoulder
Scapular	Scapula
Interscapular	Between the two scapulae
Axillary	Armpit
Brachial	Arm
Antebrachial	Forearm
Cubital	Elbow
Carpal	Wrist
Digits	Fingers
Pollicis	Thumb
Palmar	Palm of the hand

<b>Lower Limb</b>	
Gluteal	Buttocks
Coxal	Hip
Femoral	Thigh
Patellar	Front of the knee
Popliteal	Back of the knee
Crural	Leg
Tarsal	Ankle
Calcaneal	Heel
Pedal	Foot
Plantar	Sole of the foot

# Body Cavities

- **Dorsal cavity** protects the nervous system, and is divided into two subdivisions
  - **Cranial cavity** is within the skull and encases the brain
  - **Vertebral cavity** runs within the vertebral column and encases the spinal cord
- **Ventral cavity** houses the internal organs (viscera), and is divided into two subdivisions: **thoracic** and **abdominopelvic**

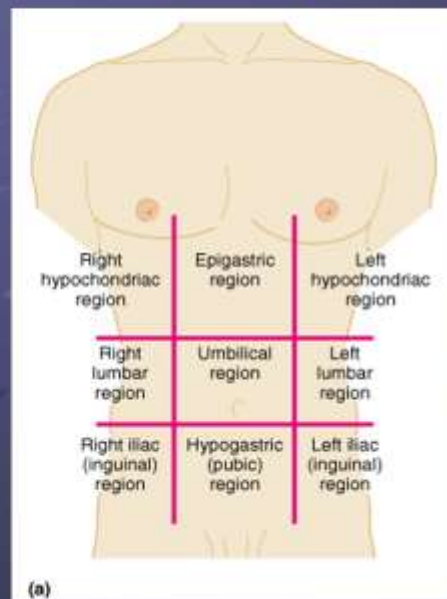


## Other Body Cavities

- **Oral and digestive** – mouth and cavities of the digestive organs
- **Nasal** – located within and posterior to the nose
- **Orbital** – house the eyes
- **Middle ear** – contain bones (ossicles) that transmit sound vibrations
- **Synovial** – joint cavities

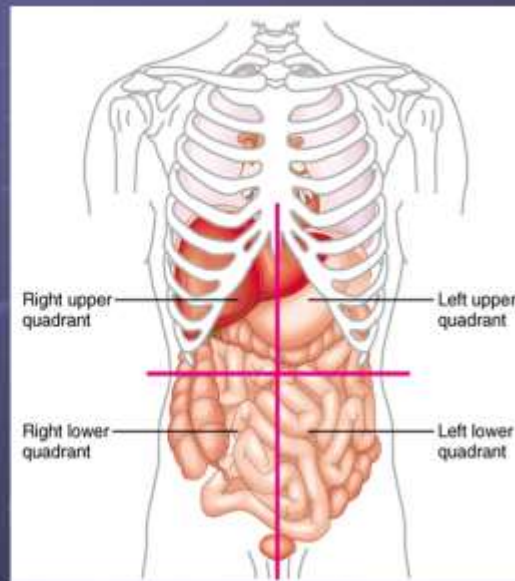
## Abdominopelvic Regions

- Umbilical
- Epigastric
- Hypogastric
- Right and left iliac or inguinal
- Right and left lumbar
- Right and left hypochondriac



# Abdominopelvic Quadrants

- Right upper
- Left upper
- Right lower
- Left lower



# Nine Regions of Abdomen

