

Lecture Notes for Muscles of the Head and Neck

Humans have well developed facial musculature that allows for a variety of complex facial expressions needed for non-verbal communications. Since we are social animals this is a necessity. Animals that are not social have less need for facial expressions and do not have well developed facial muscles.

1) Muscles of Facial Expression

The muscles of facial expression are located in a superficial position on the scalp, face and neck. These muscles all originate on the bones of the skull or in the fascia and insert into the skin. They are innervated by the facial cranial nerve (Cranial nerve VII). The locations and points of attachment are such that when contracted, they cause movements of the skin around the eyes, nose or mouth. Muscles of the face move skin rather than a joint when they contract. The nerves of the face are located right under the skin and are vulnerable to trauma. The pattern of innervation of the facial muscles becomes apparent in stroke victims and in a condition known as Bell's Palsy, which is the paralysis of the facial cranial nerve.

There are 2 types of muscles of the face which function in opposing ways. **Sphincter** muscles are circular shaped muscles which close orifices of the body. **Dilators** have the opposite effect- they open orifices.

The muscles of the face can be divided into several groups. These are muscles of the scalp, muscles of the eye, nose and mouth and muscles of mastication (chewing)

Muscles of the scalp

The **frontalis muscle** located on the forehead wrinkles the forehead and raises the eyebrows wrinkling the skin horizontally. It draws the scalp anteriorly. The occipitalis draws the posterior of the scalp. The occipitalis and frontalis are connected by a sheet of fascia called the **galea aponeurotica**. They can be considered separate muscles or part of a larger group known as the **Oczipitofrontalis muscle**. In conjunction with the temporoparietalis muscle above the ear the occipitofrontalis is referred to as the **Epicranius** muscle group.

The **temporalis muscle** elevates and retracts the mandible.

The **auricular muscles (anterior, posterior and superior)** sit above the temporalis and encircle the external ear (pinna). They are vestigial, since we are no longer able to rotate our ears as other mammals do. If you can wiggle your ears, the auricular muscles are responsible for that feat.

Muscles of the eye

Around the eye, the **Obicularis oculi** closes the eye and the **levator palpebrae superioris** opens the eye.

The **corrugator muscle** above the eyebrow is responsible for frowning (vertical furrows above the glabella). Frowning is a result of the eyebrows coming together.

Muscles of the mouth

Around the mouth, the **obicularis oris** closes the mouth and several muscles (**zygomaticus major, levator labii superioris, depressor labii inferioris, mentalis and risorius**) radiate out from the lips to open the mouth. At the corners of the mouth there is a small area of muscle attachment (a fibromuscular condensation) known as the **Modiolus**. Six muscles of the mouth attach to the modiolus. (Zygomaticus major, levator angulis oris, risorius, depressor anguli oris, buccinator and obicularis oris)

The cheek is made up of the **buccinator muscle** which functions in whistling, blowing, sucking and chewing. The **risorius muscle** is responsible for drawing the angle of the mouth laterally.

The muscles that radiate upward from the mouth (**levator labii superiorus, levator anguli oris**) are responsible for elevating the upper lips.

Zygomaticus major and minor are responsible for retracting the corners of the mouth in a smile or grimace.

Risorius which radiates from the mouth laterally, pulls the corners of the mouth laterally.

Obicularis oris closes and purses the mouth.

Depressor anguli oris depresses the corners of the mouth

Depressor labii inferioris depresses the lower lip

Buccinator compresses the cheeks

Mentalis protrudes the lower lip

Muscles of the nose

The **nasalis muscle** which sits over the nose is responsible for flaring and compressing the nostrils- another action that is somewhat subdued in humans.

The **procerus muscle** located above the bridge of the nose (glabella) is responsible for creating horizontal wrinkles at the bridge of the nose.

Facial expressions

Most human expressions are variations of the basic set of expressions that are universal: **joy, sadness, anger, fear, disgust & surprise**. These expressions involve multiple muscles acting together and are to a certain degree involuntary. Actions such as sneezing, coughing yawning and vomiting are involuntary reflexes and require that the eyes are shut. This reflex action prevents the possible rupture of small vessels in the eyes.

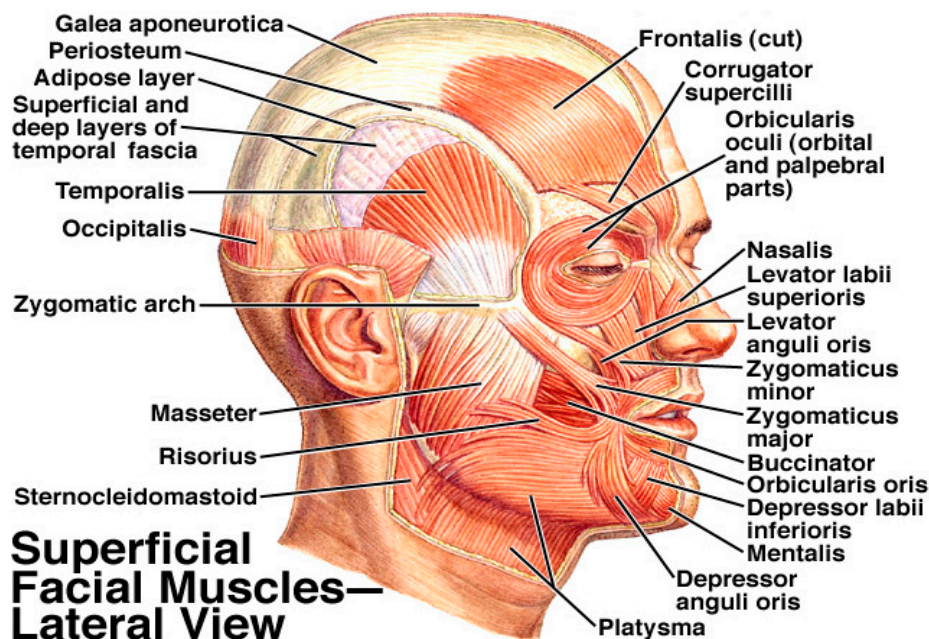
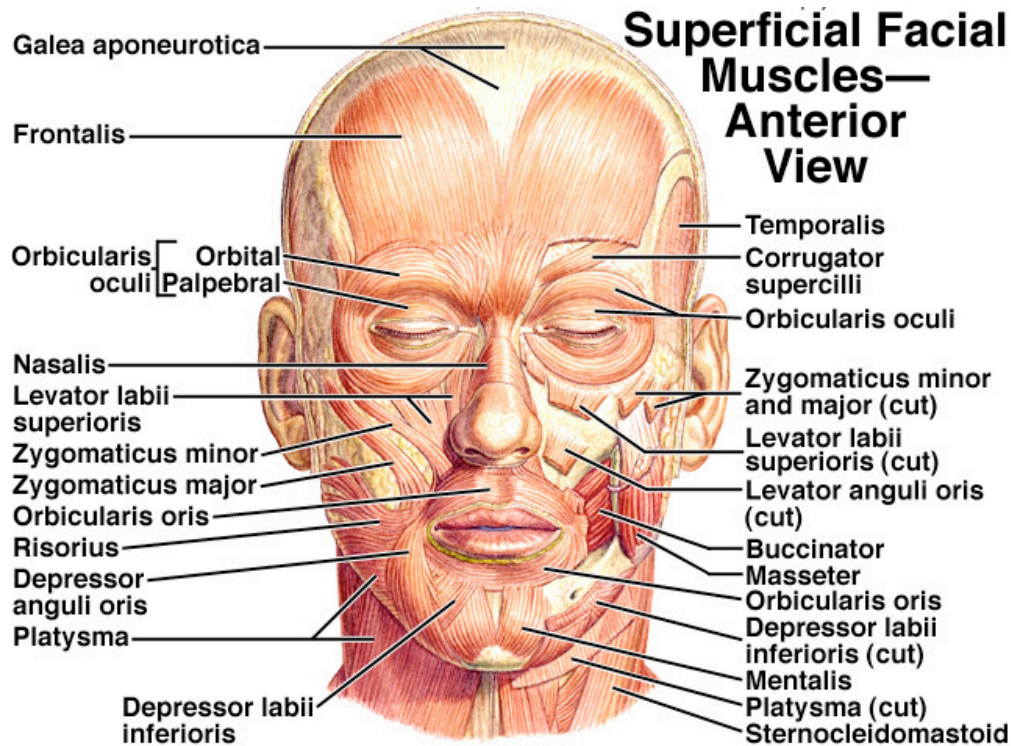
Joy: Smiling and laughing involves action of the zygomaticus, labii superioris, buccinator and risorius to produce a smile and the obicularis oculi which narrows or closes the eyes.

Sadness also involves the obicularis oculi particularly if crying as well as depressor muscles of the mouth and lip which tend to depress the corners of the mouth.

Anger can involve corrugator and procerus muscles (frowning). Obicularis oris, depressor labii inferioris tensing of the lips and mouth, masseter in clenching of the jaw. Curling of the upper lip (snarling) sometimes occurs. This is due to the action of the levator labii superioris. Snarling reveals the canines which is also seen in other mammals.

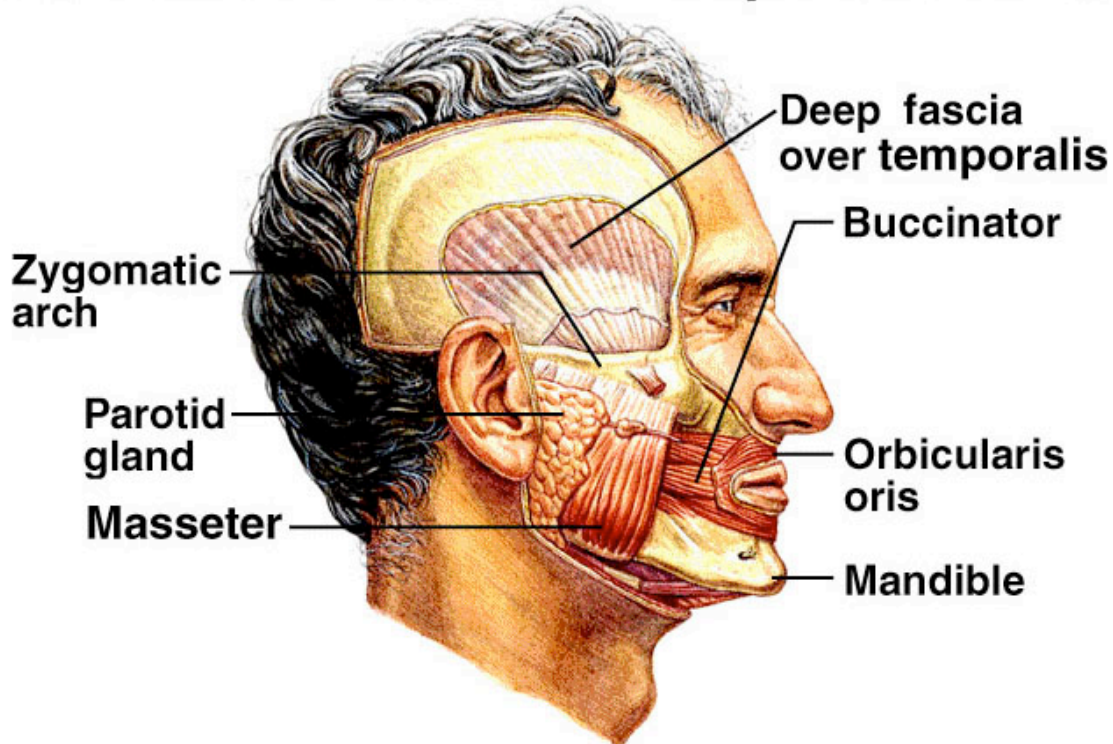
Fear and surprise both involve frontalis in raising of the eyebrows. Also involved are the levator palpebrae superioris in the action of opening the eyes wide. The muscles of the mouth (obicularis oris, buccinator, risorius and mentalis) are involved in the opening of the mouth seen in both surprise and fear. In the case of fear, screaming may involve the muscles of the jaw as well.

Disgust involves muscles surrounding the mouth and chin in pulling the lips together and downward and also puckering and pursing the lips. Also involved are the orbicularis oculi and the corrugator and procerus muscles in frowning and wrinkling the nose. The nasalis may be involved in that action as well.



2) Muscles of Mastication (chewing)

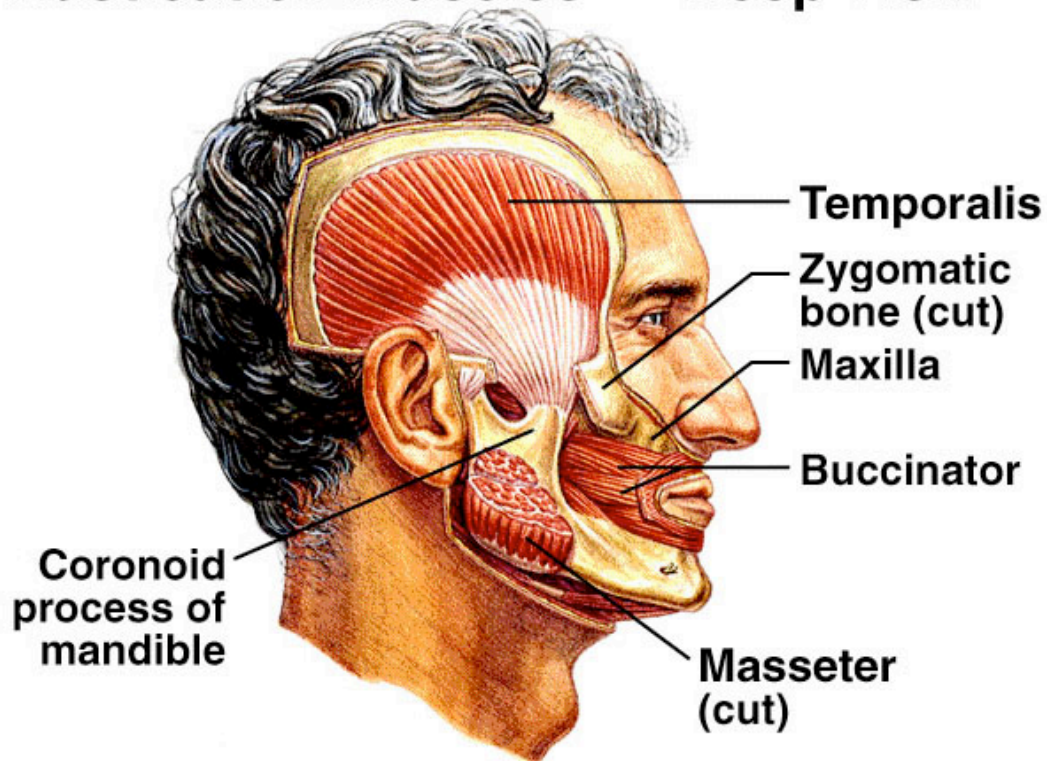
Mastication Muscles — Superficial View



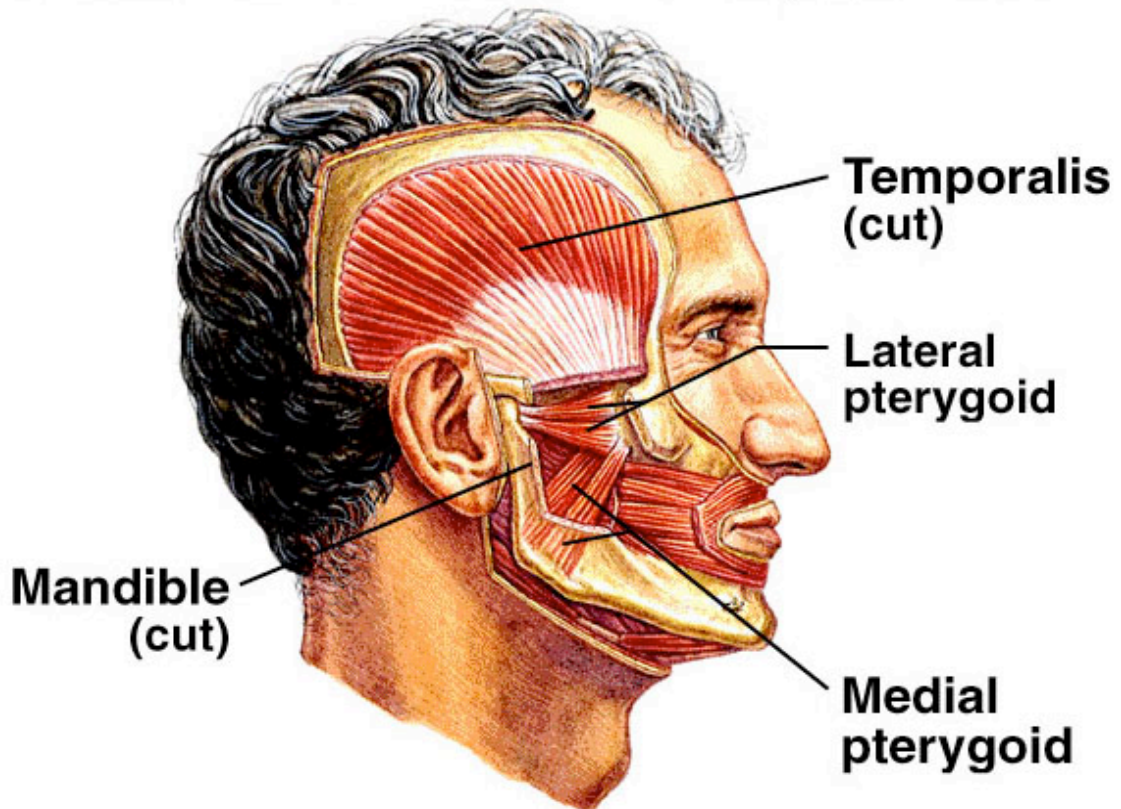
The muscles that are responsible for mastication (chewing) are the **temporalis**, the **masseter** and the **pterygoids (lateral and medial)**.

The **temporalis** elevates and retracts the mandible. The **masseter** elevates the mandible as well. The **medial pterygoid** elevates the mandible and moves it laterally. The **lateral pterygoid** protracts the mandible. These actions allow the teeth to grind food.

Mastication Muscles — Deep View



Mastication Muscles — Deepest View



3) Muscles of the tongue:

The tongue has both **intrinsic** and **extrinsic** muscles to control movement of the tongue in eating, speaking and swallowing. Intrinsic muscles are located within the tongue and are responsible for its mobility and changing shape. The extrinsic muscles originate on structures outside the tongue and insert into it to cause large movements. The **4 paired extrinsic muscles** are the **genioglossus, styloglossus, hyoglossus and palatoglossus**. These muscles are innervated by Cranial Nerve XII- the hypoglossal nerve.

TABLE 9.6 Extrinsic Tongue Muscles*

Muscle	Origin	Insertion	Action
Genioglossus	Mental spine of mandible	Undersurface of tongue	Depresses and protracts tongue
Styloglossus	Styloid process of temporal bone	Lateral side and undersurface of tongue	Elevates and retracts tongue
Hyoglossus	Body of hyoid bone	Side of tongue	Depresses sides of tongue
Palatoglossus	Soft palate	Side of tongue	Elevates posterior tongue; constricts fauces (opening from oral cavity to pharynx)

*Each of the extrinsic tongue muscles is innervated by the hypoglossal nerve.

genioglossus: L. *geneion*, chin; *glossus*, tongue

Extrinsic Muscles — Tongue and Neck

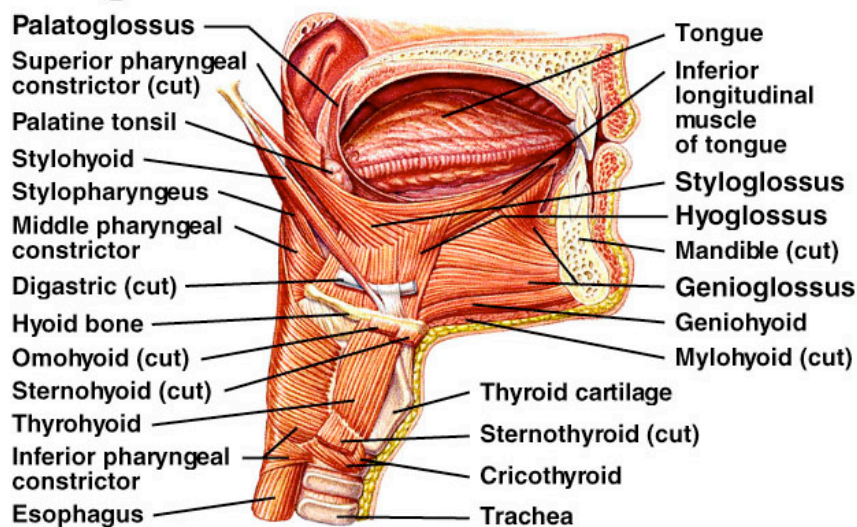
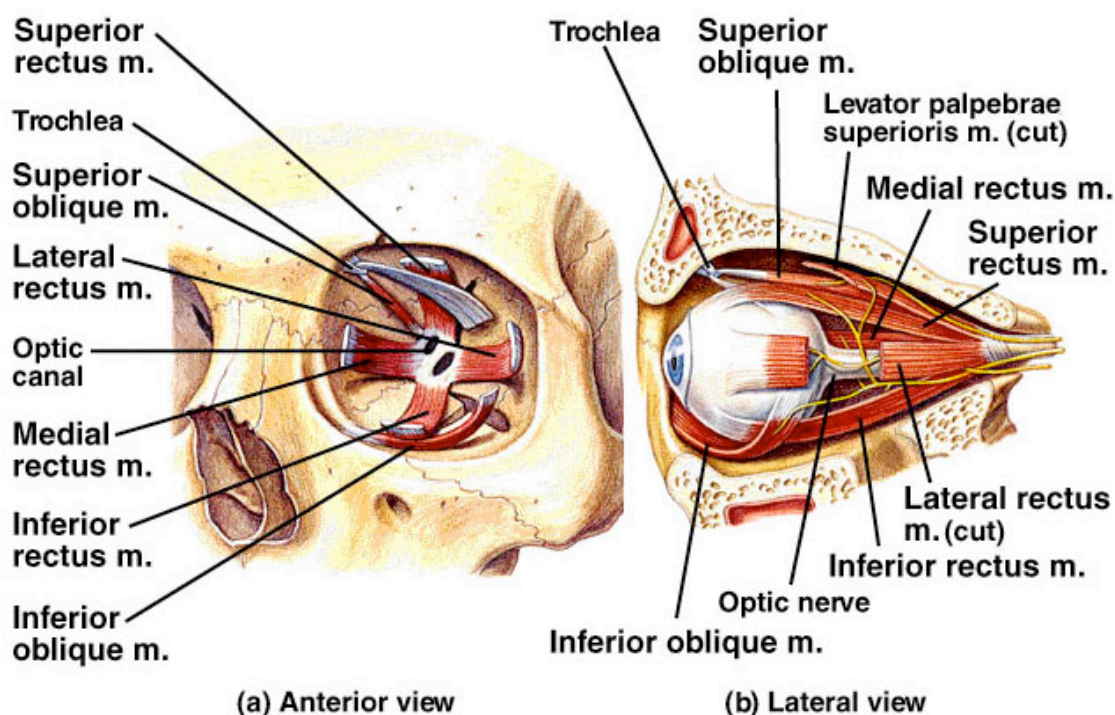


TABLE 9.5 Ocular Muscles

Muscle	Cranial Nerve Innervation	Movement of eyeball
Lateral rectus	Abducens	Lateral
Medial rectus	Oculomotor	Medial
Superior rectus	Oculomotor	Superior and medial
Inferior rectus	Oculomotor	Inferior and medial
Inferior oblique	Oculomotor	Superior and lateral
Superior oblique	Trochlear	Inferior and lateral

Extrinsic Ocular Muscles



4) Muscles of the Eye

Movement of the eyeball is controlled by 6 extrinsic ocular muscles.

Four **rectus muscles** move the eyeball in the direction indicated by their names (**superior, inferior, lateral and medial.**)

Two **oblique muscles (superior & inferior)** rotate the eyeball on its axis.

5) Muscles of the Neck

Muscles of the neck either support and move the head or are attached to structures within the neck region such as the hyoid bone and the larynx.

The **posterior muscles** of the neck include the **sternocleidomastoid, trapezius, splenius capitus, semispinalis capitus and longissimus capitus.**

The **sternocleidomastoid muscle** originates on the sternum and clavicle and inserts on the mastoid process of the temporal bone. When contracted on one side it turns the head sideways in the other direction. When both sides contract, it pulls the head forward and down. The **sternocleidomastoid** is covered by a sheet like muscle called the **platysma** which is a muscle of facial expression.

The **trapezius** extends over the neck but is considered a superficial muscle of the back.

The **Splenius capitus** is a broad muscle deep to the trapezius. It originates in the ligamentum nuchae and the spinous processes of the 7th cervical and first 3 thoracic vertebrae. It inserts on the back of the skull below the superior nuchal line and on the mastoid process of the temporal bone. Contraction on one side causes the head to rotate and extend to one side. Contraction together causes extension of the head at the neck. Maximum contraction causes hyperextension of the neck and head.

The **semispinalis capitus muscle** extends upward from the 7th cervical and the first 6 thoracic vertebrae to insert on the occipital bone. When the muscles contract together they extend the head at the neck (along with the splenius capitus). If one of the muscles acts alone the head is rotated to the side.

The **longissimus capitus** originates from the processes of the lower 4 cervical and upper 5 thoracic vertebrae to insert on the mastoid process of the temporal bone. This muscle extends the head at the neck, bends it to the side or rotates it slightly.

TABLE 9.7 Neck Muscles

Muscle	Origin	Insertion	Action	Innervation
Sternocleidomastoid	Sternum and clavicle	Mastoid process of temporal bone	Rotation of head; flexes neck	Accessory n.
Digastric	Inferior border of mandible and mastoid process of temporal bone	Hyoid bone	Opens mouth; elevates hyoid bone	Trigeminal n. (ant. belly); facial n. (post. belly)
Mylohyoid	Inferior border of mandible	Body of hyoid bone and median raphe	Elevates hyoid bone and floor of mouth	Trigeminal n.
Geniohyoid	Medial surface of mandible at chin	Body of hyoid bone	Elevates hyoid bone	Spinal n. (C1)
Stylohyoid	Styloid process of temporal bone	Body of hyoid bone	Elevates and retracts tongue	Facial n.
Sternohyoid	Manubrium	Body of hyoid bone	Depresses hyoid bone	Spinal nn. (C1-C3)
Sternothyroid	Manubrium	Thyroid cartilage	Depresses thyroid cartilage	Spinal nn. (C1-C3)
Thyrohyoid	Thyroid cartilage	Great cornu of hyoid bone	Depresses hyoid bone; elevates larynx	Spinal nn. (C1-C3)
Omohyoid	Superior border of scapula	Body of hyoid bone	Depresses hyoid bone	Spinal nn. (C1-C3)

digastric: L. *di*, two; Gk. *gaster*, belly
 mylohyoid: Gk. *mylos*, akin to; *hyooides*, pertaining to hyoid bone
 omohyoid: Gk. *omos*, shoulder

Suprahyoid muscles: These muscles are located above the hyoid bone.

The **digastric** which is double bellied and has 2 origins acts to open the mouth and elevate the hyoid bone.

The **myohyoid** forms the floor of the mouth. It aids in swallowing by forcing food towards the back of the mouth.

The stylohyoid extends from the styloid process of the skull to the hyoid bone, which it elevates as it contracts. This acts to elevate the base of the tongue.

Infrahyoid muscles: These are located below the hyoid bone. They are named on the basis of the origin and insertion.

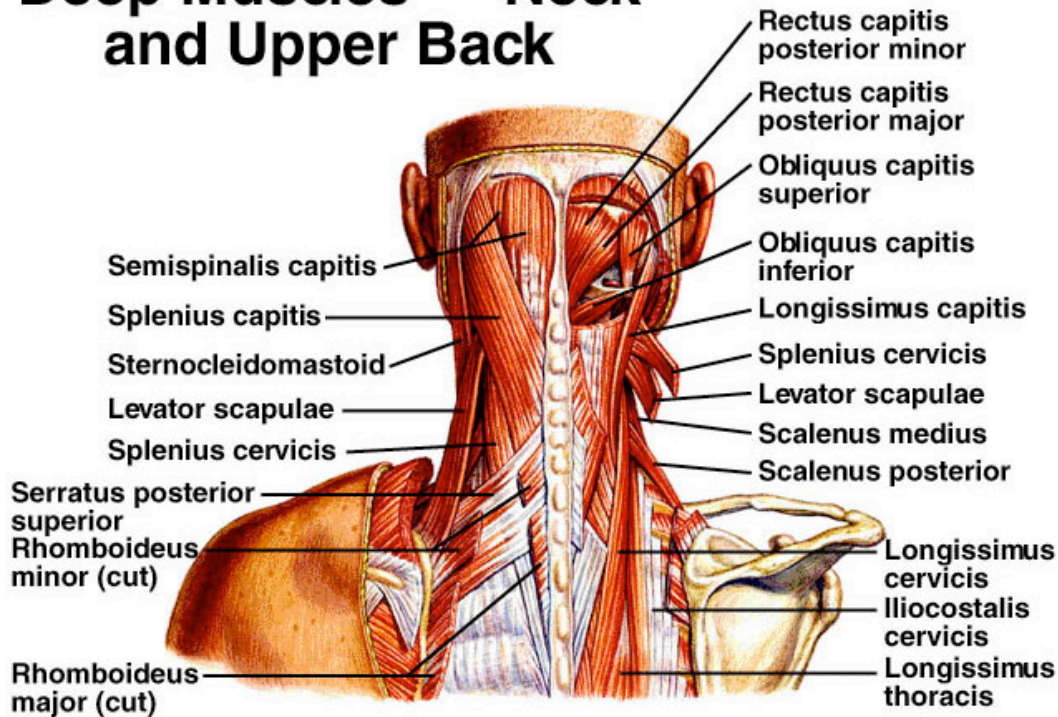
Sternohyoid-depresses the hyoid bone

Sternothyroid- pulls the larynx downward

Thyrohyoid- elevates the larynx and lowers the hyoid.

Omohyoid- depresses the hyoid bone

Deep Muscles — Neck and Upper Back



Neck Muscles—Anterior and Lateral View

