المرحلة الخامسة -جراحة الفم

الفصل الدراسي الأول

Management of Dentoalveolar Fractures

المدرس سندس عبد الودود الجزائري
فرع جراحة الفم والوجه والفكين
كلية طب الأسنان
جامعة البصرة

Objectives

اهداف المحاضرة

- To know the causes and classification of dentoalveolar fractures.
- Management of the dentoalveolar fractures.
- How to manage soft tissue injures.

Management of Dentoalveolar Fractures

- Dental injuries are very frequent, and world statistics show that such injuries **affect approximately half of the population in the course of a life time.**

- Craniomaxillofacial fractures are less common but in **about half of the cases they are combined with traumatic dental injuries.**

- Healing of traumatic dental injuries is complex since three types of **tissue have to heal as a unit, namely, pulp, periodontal ligament and supporting bone.**

- Isolated dentoalveolar trauma has a peak incidence in the **age group 9-12** due to the high degree of activity and poor judgment of this age group and ***affects mainly the central upper incisors.***

- A smaller peak is in the **age group of 2-3 years**. This is primarily **due to falls and undeveloped motor coordination**.

- The main focus of this lecture in permanent dentition.

Management of Dentoalveolar Fractures

Causes :

1- Traffic Accident.
2- Falls.
3- Fight and assault.
3- During Epileptic seizures.
4- Sport injuries.
5- Others.

Diagnosis

1. History
2. Clinical examination
3. Vitality test
4. Radiographic Examination

Management of Dentoalveolar Fractures

History of the incident : Obtain thorough

1. history of the patient and the traumatic incident.
2. Preinjury data such as biographic, demographic, past medical history
3. time of incident
4. location of incident
5. loss of consciousness,

6. The mechanism of injury given in the history and the soft tissue defect alerts the surgeon to suspect underlying hard-tissue damage, such as to the maxilla, the mandible, the temporomandibular joint (TMJ),and alveolar fractures.

Management of Dentoalveolar Fractures

Maxillofacial Examination

For medicolegal purposes, consider preoperative photographs prior to invasive treatment.

Include the following in the patient examination :

- Extraoral soft tissue
- Intraoral soft tissue
- Jaws and alveolar bone
- Teeth (displacement and mobility)
- Percussion and pulp testing

NOTE: Ensure that the patient is cleaned extraorally with a mild antiseptic soap, And be carful when remove the debris or foreign bodies from injury sites to avoid complication.

Consider tetanus prophylaxis, depending on previous immunization compliance and wound presentation.

Management of Dentoalveolar Fractures

NOTE: Prior to any intraoral manipulations, in initial radiographic studies (in the pediatric patient, knowledge of the deciduous tooth root to the permanent tooth bud position).

The chance of further damage could be effect both the future eruption and the morphology of the developing permanent tooth

Approach intraoral soft tissue examination with caution.

1. Carefully manipulate and handle traumatized tissues to avoid further complication.
2. Depending on the mechanism of injury, bone or tooth fragments may have penetrated soft tissue.
3. The lips, the floor of the mouth, and the tongue regions are all areas at risk for penetrating or secondary injury and thus should be inspected accordingly.
4. Closely inspect hematoma formation or ecchymosis.
5. Buccal mucosal lacerations should raise the suspicion for Stenson's duct injuries.
6. Account for all fractured or missing teeth and restorations or assume they were swallowed, aspirated, or lodged within adjacent structures.
7. Similarly, arrange for radiographic evaluation of the maxillary and nasal sinuses prior to further treatment.

Management of Dentoalveolar Fractures

Vitality test

- Mechanical stimulation
  - Dental probe
  - Cavityprepping with drills
- Thermal test
  - Heated gutta-percha
  - Ice
  - Ethyl chloride
  - Carbon dioxide snow
- Electric pulp testers
- Laser Doppler flowmetry (LDF),a relatively new pulp testing apparatus, has shown promise. A laser beam, which is directed at the coronal-labial aspect of the pulp, is scattered by pulp blood cells that in turn produce a Doppler frequency shift.

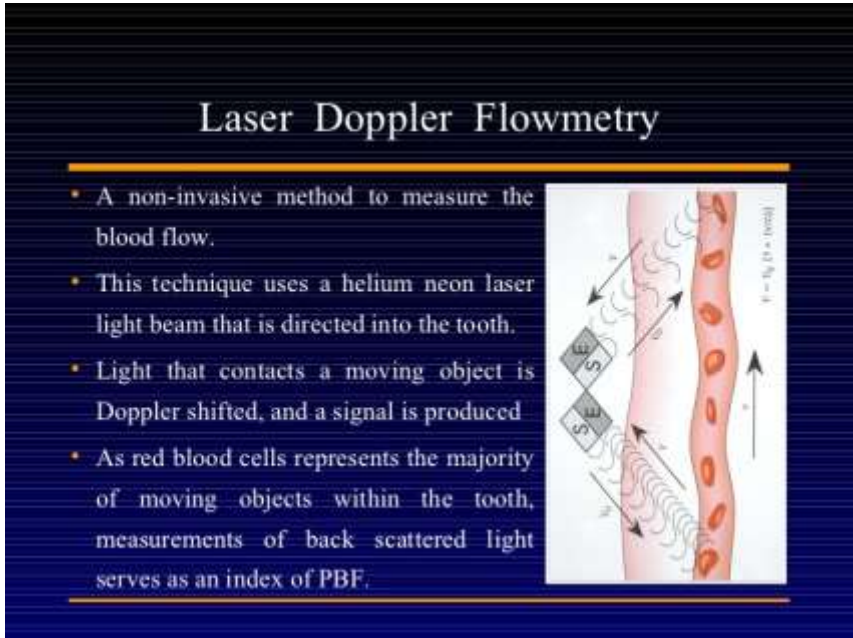

- In cases wherein electrometric tests were negative and LDF displayed vascular perfusion, the LDF accuracy of pulp vitality reached 100%

Management of Dentoalveolar Fractures

classification of dentoalveolar injuries

The most commonly used simple and comprehensive classification of dentoalveolar injuries is one that was developed by Andreasen and originally adopted by the World Health Organization system

1) Dental tissues and pulp

A. Crown infraction (ie,a craze line or crack in the tooth without loss of tooth substance)
B. Crown fracture that is confined to enamel, or enamel and dentin, with no root exposure (uncomplicated)
C. Crown fracture producing a pulp exposure (complicated)
D. Fracture involving the enamel, dentin,and cementum without pulp exposure (uncomplicated crown root fracture)
E. Fracture involving the enamel, dentin, and cementum with pulp exposure (complicated crown-root fracture)
F. Root fracture involving the dentin and cementum and producing a pulp exposure (root fracture)

Management of Dentoalveolar Fractures

2) Injuries to periodontal tissues are divided into six categories

Concussion: defined as an injury to the periodontium producing sensitivity to percussion without loosening or displacement of the tooth

Subluxation: the tooth is loosened but not displaced

Luxation (ie, lateral, intrusion, and extrusion) dislocation, or partial avulsion: the tooth is displaced without an accompanying comminution or fracture of the alveolar socket

Injuries to the supporting bone

1. Comminution of the alveolar housing, often occurring with an intrusive or lateral luxation
2. Fracture of a single wall of an alveolus
3. Fracture of the alveolar process, en bloc, in a patient having teeth but without the fracture line necessarily extending through a tooth socket
4. D. Fracture involving the main body of the mandible or maxilla

5. Exarticulations (Avulsions)
6. Categories of injuries to the gingival or oral mucosa area include the following: (Abrasion, Contusion & Laceration)

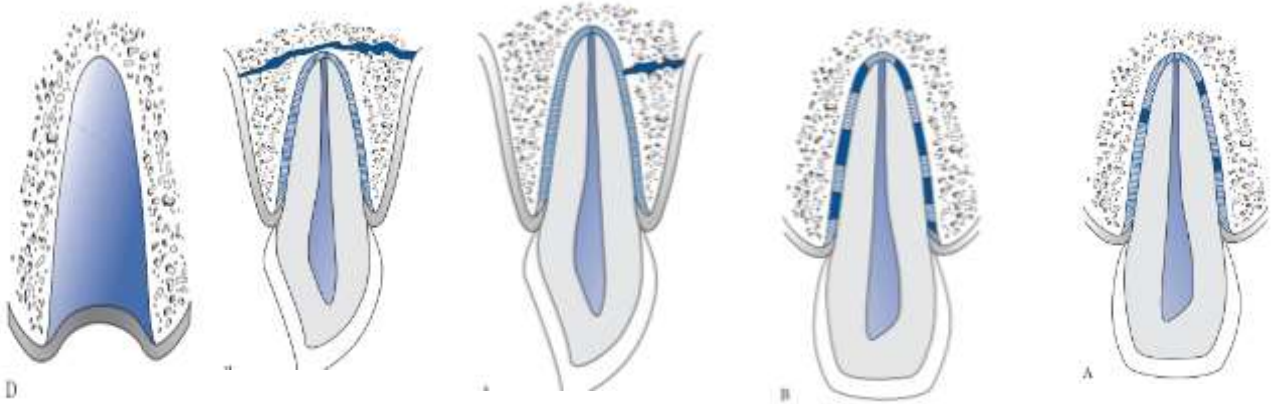

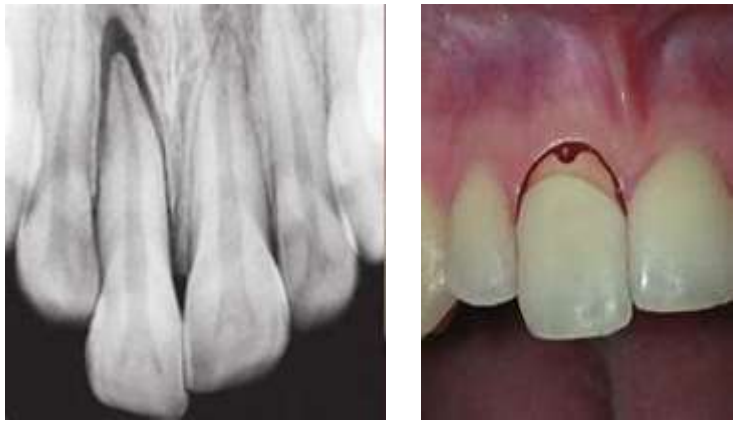

Management of Dentoalveolar Fractures

A- a crack of the enamel without loss of tooth structure.

Do not require immediate treatment.

Fracture of enamel only smoothing the sharp edge

regular vitality test perform pulp testing immediately after the injury and again in 6 to 8 weeks and radiography

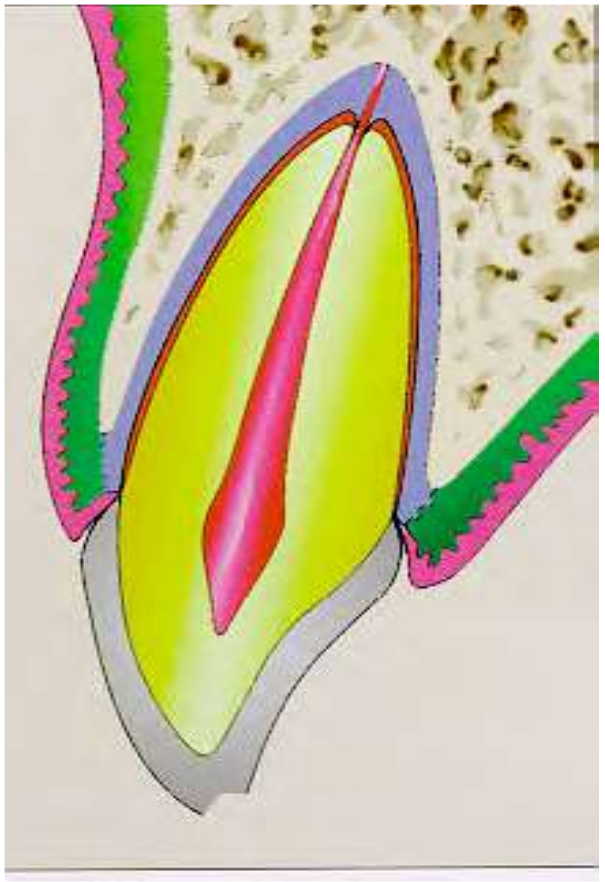

Management of Dentoalveolar Fractures

B-Crown Fracture without Pulp Involvement

Immediate treatment of the crown is required to:

1) protect the pulp
2) restore the aesthetics and function.

Cover the expose of the dentine by a composite resin restoration or MTA (mineral trioxide aggregate) than:

A- Reattachment of tooth fragment.
B- Acid-etch composite resin restoration

Management of Dentoalveolar Fractures

C- Crown Fracture with Pulp Involvement

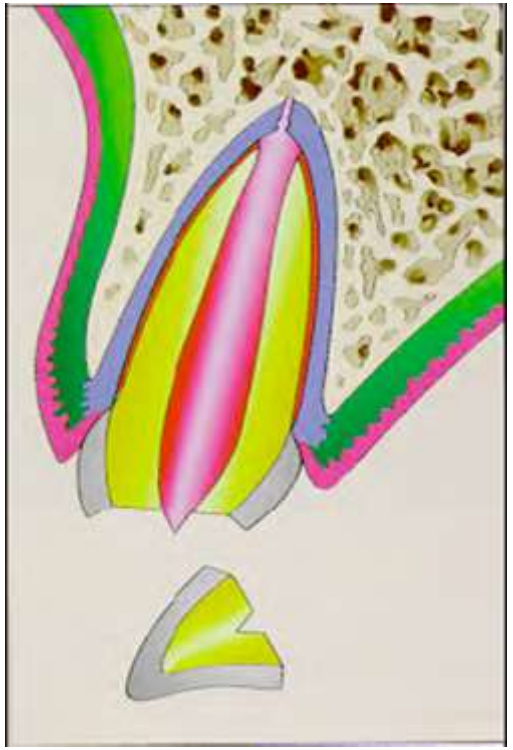

The treatment depends on many factors such as:

1) vitality of the exposed pulp.
2) Size of the exposure.
3) Time elapsed since the exposure.
4) Degree of root maturation.
5) Restorability of the fractured crown.

The main objective of treatment is to maintain the vitality of the tooth.

Management of Dentoalveolar Fractures

Small exposure				Large exposure			
Early		Late		Early		Late	
Open	Close	open	closed	open	closed	open	Closed
Direct pulp capping		Pulpotomy Later pulpectomy	pulpectomy	Pulpotomy Later pulpectomy	pulpectomy	Apexification	pulpectomy

Management of Dentoalveolar Fractures

D- Fracture involving the enamel, dentin, and cementum without pulp exposure or with pulp exposure

Treatment usually involve removing the loose fragment .

1- tooth can be extruded orthodontically
2- crown lengthening to gain access to placement of restoration.

E-Fracture involving the enamel, dentin, and cementum with pulp exposure

Treatment usually involve removing the loose fragment .

1- Root canal filling
2- placement of restoration.
3- Extraction

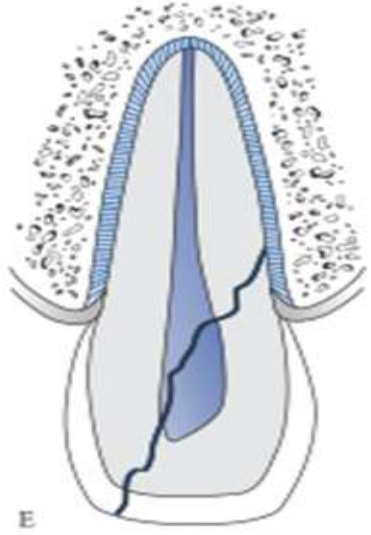

dental tissue and pulp. A, Crown infraction

F- Root Fracture

When the fracture occur near the apical 1/3, the prognosis is more favourable than the middle or cervical 1/3 because :

1) more alveolar support

2) immobilization of the tooth is much easier

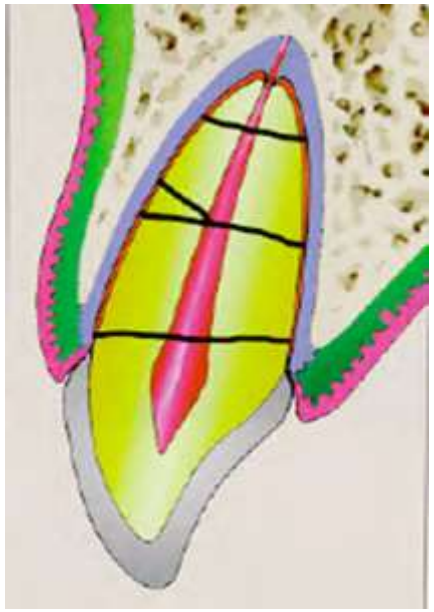

Treatment of root fracture depends upon :

1) Condition of the pulp

2) amount of mobility or the level of the fracture line

Management of Dentoalveolar Fractures

(A) apical 1/3 root fracture

1) reduction , splinting the tooth for 12 weeks

2) The tooth should be checked periodically for vitality and radiograph.

(B) middle 1/3 root fracture :

1) reduction , splinting the tooth

2) The patient recall 2-3 months , checked the vitality & radiograph

3) If the tooth non vital and no healing the following treatment is performed:
   a) R C T of both fragments
   b) Intraradicular pin to stabilize both segments

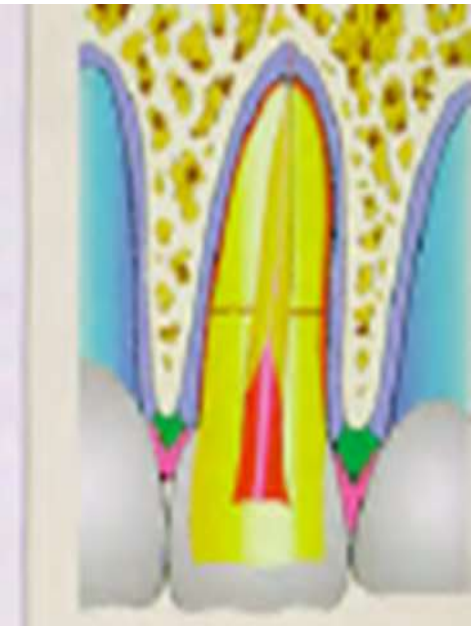

Management of Dentoalveolar Fractures

(C) cervical 1/3 root fracture :

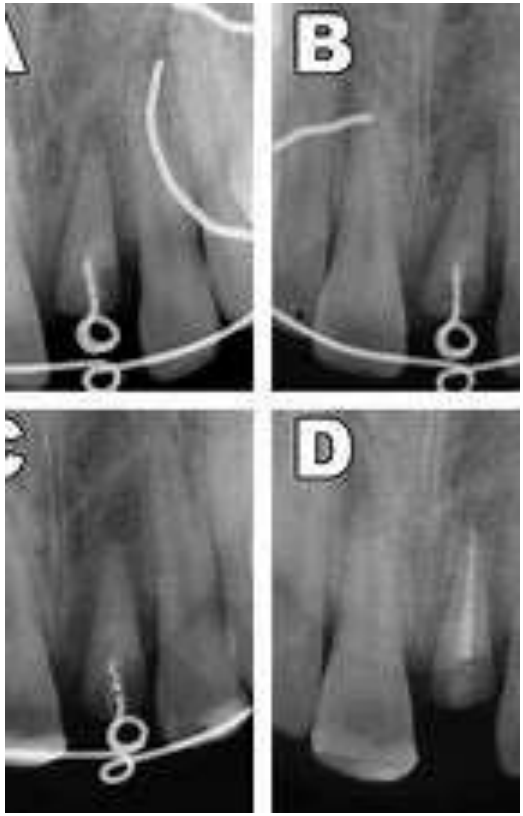

1) Reduction , splinting the tooth 12 weeks
2) Recall the patient periodically and checked the vitality and radiograph
3) If there is radiolucent and pulp necrosis the following treatment is performed
    a) extraction the tooth
    b) removed the apical fragment and endoosseous implant placed
    c) orthodontic extrusion
    d) if the fracture is 1-2mm infrabony remove the coronal segment and osteoplasty to expose the root


TO BE
CONTINUE