



Endodontics

Lec.5

د. فرح عبد الرزاق

Radiography in Endodontics:

There are many applications of radiographs in endodontics including:

- 1) Aid in the diagnosis and localization of hard tissue alteration of the tooth (sclerosis and resorption) and periradicular structures.
- 2) Determine the number, location, size, shape and direction of roots and root canals.
- 3) Estimate and confirm the length of root canals prior to instrumentation.
- 4) Determine the relative position of structures in facial or lingual dimensions.
- 5) Confirm the position and adaptation of the filling points.
- 6) Assess the outcome of root canal treatment

Working length determination of Teeth:

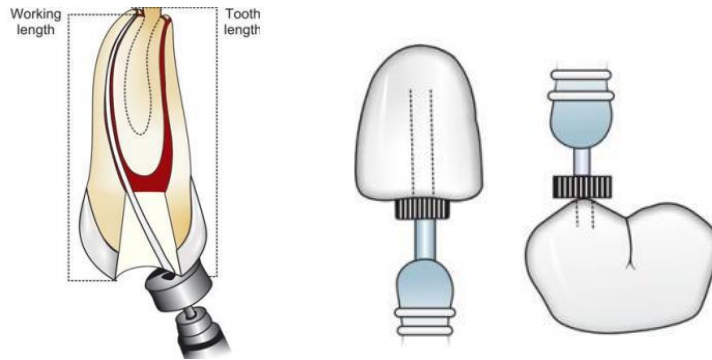
Determination of an accurate working length is one of the most critical steps of endodontic therapy. The cleaning, shaping and obturation of the root canal system cannot be accomplished accurately unless working length is determined precisely. According to endodontic glossary working length is defined as “the distance from a coronal reference point to a point at which canal preparation and obturation should terminate”.

Objective of the working length

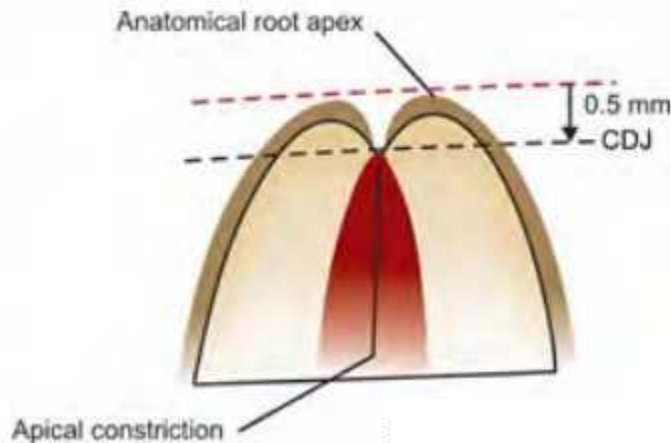
To establish the length of the tooth at which the canal preparation and subsequent obturation are to be completed. The apical end of the root canal is the CDJ, which is usually 0.5-1mm short of the radiographic apex. Sometimes the apical foramen is laterally positioned so it would be more than 1 mm from the radiographic apex.

Reference point: It is the site on the incisal edge or occlusal surface from which measurements are made. Usually it's the highest point on the incisal edge in anterior teeth & the tip of the cusp in posterior teeth. It should be:

- 1) Stable
- 2) Easily visualized during preparation
- 3) Not changing during or between appointments.



Cementodentinal junction: It is the junction between the cementum and dentin in the apical constriction of the tooth. It is the most apical point of the working length. The root canal preparation should be limited to this junction and form a constriction to prevent over instrumentation and over obturation.



Consequences of over-extended working length

- Perforation through apical construction
- Over instrumentation
- Overfilling of root canal
- Increased incidence of postoperative pain
- Prolonged healing period
- Lower success rate due to incomplete regeneration of cementum, periodontal ligament and alveolar bone.

Consequences of working short of actual working length

- Incomplete cleaning and instrumentation of the canal
- Persistent discomfort due to presence of pulpal remnants
- Underfilling of the root canal
- Incomplete apical seal
- Apical leakage which supports existence of viable bacteria, this further leads to poor healing and periradicular lesion.

Different Methods Of Working Length Determination:

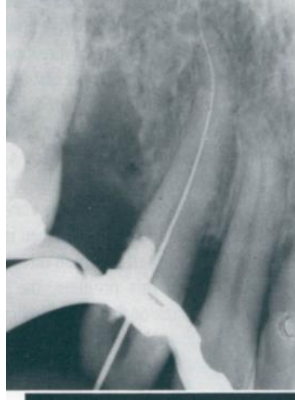Various methods for determining working length include using average root lengths from anatomic studies, preoperative radiographs, tactile sensation, etc these methods do not give the accurate length of the canal . Other common methods include working length radiograph, electronic apex locators which give the accurate length of canal.

1. Radiographic Method Of Working Length Determination:

Procedure of Working Length determination

- 1- Examine preoperative radiograph & estimate the length of the tooth.
- 2- Know the average length of each tooth.
- 3- Place the file selected to be the correct initial width into the canal with it's rubber stopper set at the estimated working length.
- 4- Radiograph the tooth to verify the position of the instrument.
- 5- Readjust the file length according to the radiograph result.

Results are either fit, too long, or too short.



Notes:

- * Bisecting technique in x-ray can't measure the exact length of the tooth. The parallel technique is more accurate.
- * The radiographs should be repeated in the following stages of treatment to check the working length.
- * Initial size: It is the first instrument used to fit the working length & has slight resistance.
- * If the radiograph results are too long e.g. 3mm. long, here we have to subtract 4 mm. & take another radiograph.
- * If the radiograph results are too short e.g. 3mm. short, here we have to add 2mm. & then take another radiograph.

When two superimposed canals are present (for example buccal and palatal canals of maxillary premolar, mesial canals of mandibular molar)

One should take following steps:

- a. Take two individual radiographs with instrument placed in each canal.
- b. Take radiograph at different angulations, usually 20° to 40° at horizontal angulation.
- c. Insert two different instruments, e.g. K file in one canal, H file/ reamer in other canal and take radiograph at different angulations.
- d. Apply **SLOB** rule, that is expose tooth from mesial or distal horizontal angle, canal which moves to **Same** direction, is **Lingual** where as canal which moves to **Opposite** direction is **Buccal**.

2. Electronic Apex Locators:

Radiographs are often misinterpreted because of difficulty in distinguishing the radicular anatomy and pathosis from normal structures. Electronic apex locators (EAL) are used for determining working length as an adjunct to radiography. They are basically used to locate the apical constriction or cementodentinal junction or the apical foramen, and not the radiographic apex.

