

THE USE OF CONE-BEAM COMPUTED TOMOGRAPHY TO ASSESS THE RELATIONSHIP OF THE ROOTS OF THE PREMOLARS AND MOLARS OF THE MAXILLA RELATIVE TO THE MAXILLARY SINUSES WHEN PLANNING DENTAL TREATMENT

Aqeel Al-Saedi ¹, Bahaa Al-Bakhakh ², Riad Al-Taee ²

1 - College of Dentistry, University of Basrah. Basrah, Iraq.

2 - College of Dentistry, Al-Maaqal University. Basrah, Iraq.

Purpose. This study aimed to evaluate the relationship between the roots of the maxillary posterior teeth and the maxillary sinus (MS) and to analyze the vertical relationship and vertical linear measurements (VLM) between the root tips of the maxillary posterior teeth and MS.

Materials and Methods. Cone-beam computed tomography images of 148 patients were evaluated (62 men, 86 women). A total of 1052 teeth were examined (518 maxillary premolars, 534 maxillary molars). The relationship between root tips and the maxillary sinus floor was classified into four types according to the classification of Jung and Cho. The vertical linear distance was measured, and the distribution of relationship types by age group was evaluated.

Results. Most single-rooted maxillary premolars (98.1%) showed a type 0 relationship with the maxillary sinus floor for the maxillary first premolars versus 69.5% for the maxillary second premolars. In the buccal roots of the double-rooted maxillary first premolars, 98.7% were type 0. In contrast, 50% of the maxillary second premolars were type 0. Type 0 was the most common in the palatal roots of the maxillary first premolars (92%) and the maxillary second premolars (45.8%). Among the maxillary first molars, type 0 was the most common, appearing in 43.3%, 39.8%, and 38.6% of the mesiobuccal, distobuccal, and palatal roots, respectively. At 50%, type 0 was the most common in single-rooted and double-rooted maxillary second molars. Type 1 was the most common in the mesiobuccal (48.1%) and distobuccal (45.5%) roots, whereas type 0 was the most common in the palatal roots (39.7%). Type 0 was significantly more common ($P < 0.001$) in maxillary molar roots in the older age group (>45 years).

Conclusions. Most of maxillary premolars (MP), maxillary first molars (MFM), and palatal roots (BR) of the maxillary second molars (MSM) are separate from the maxillary sinus floor (MSF) (type 0), whereas most of the mesiobuccal and distobuccal roots of the maxillary second molars are in contact with the sinus floor (type 1). MM measurements are more similar to the MSF than the MP with a shorter vertical distance from the BR of the MSM. The distance between the roots of the MM molars and the MSF raise significantly with increase age.

Keywords: cone-beam computed tomography, maxillary molars, maxillary premolars, maxillary sinus, maxillary sinus floor.

Corresponding author: Aqeel Ibrahim Lazim Al-Saedi, e-mail: Medicalresearch10@yahoo.com

For citation: Aqeel Al-Saedi, Bahaa Al-Bakhakh, Riad Al-Taee. The use of cone-beam computed tomography to assess the relationship of the roots of the premolars and molars of the maxilla relative to the maxillary sinuses when planning dental treatment. REJR 2024; 14(1):55-69. DOI: 10.21569/2222-7415-2024-14-1-55-69.

Received: 06.11.23

Accepted: 20.11.23

ИСПОЛЬЗОВАНИЕ КОНУСНО-ЛУЧЕВОЙ КОМПЬЮТЕРНОЙ ТОМОГРАФИИ ДЛЯ ОЦЕНКИ СООТНОШЕНИЯ КОРНЕЙ ПРЕМОЛЯРОВ И МОЛЯРОВ ВЕРХНЕЙ ЧЕЛЮСТИ К ВЕРХНЕЧЕЛЮСТНОМУ СИНУСУ ПРИ ПЛАНИРОВАНИИ СТОМАТОЛОГИЧЕСКОГО ЛЕЧЕНИЯ

Акиль Аль-Саеди¹, Бахаа Аль-Бах², Риад Аль-Таи²

1 - Стоматологический колледж, Университет Басры. г. Басра, Ирак.

2 - Стоматологический колледж, Университет Аль-Маакаль. г. Басра, Ирак.

Цель исследования. Оценить взаимосвязь между корнями зубов верхней челюсти и верхнечелюстным синусом, а также проанализировать вертикальную взаимосвязь и вертикальные линейные измерения между корнями зубов верхней челюсти и синусом.

Материалы и методы. Были проанализированы изображения конусно-лучевой компьютерной томографии 148 пациентов (62 мужчины, 86 женщин). Всего было обследовано 1052 зуба (518 премоляров верхней челюсти, 534 моляра верхней челюсти). Взаимосвязь между верхушками корней зубов и дном верхнечелюстного синуса была разделена на четыре типа в соответствии с классификацией Jung и Cho. Было измерено вертикальное линейное расстояние и оценено распределение типов взаимосвязи по возрастным группам.

Результаты. Большинство однокорневых премоляров верхней челюсти (98,1%) показали связь типа 0 с дном верхнечелюстного синуса для первых премоляров верхней челюсти по сравнению с 69,5% для вторых премоляров верхней челюсти. В щечных корнях двукорневых первых премоляров верхней челюсти в 98,7% был выявлен тип 0. Напротив, 50% вторых премоляров верхней челюсти определялись как тип 0. Тип 0 был наиболее распространенным в небных корнях первых премоляров верхней челюсти (92%) и вторых премолярах верхней челюсти (45,8%). Среди первых моляров верхней челюсти тип 0 был наиболее распространенным, появляясь у 43,3%, 39,8% и 38,6% мезиобуккальных, дистобуккальных и небных корней соответственно. В 50% случаев тип 0 был наиболее распространенным среди однокорневых и двукорневых вторых моляров верхней челюсти. Тип 1 был наиболее распространенным в мезиобуккальных (48,1%) и дистобуккальных (45,5%) корнях, тогда как тип 0 был наиболее распространенным в небных корнях (39,7%). Тип 0 достоверно чаще встречался ($P < 0,001$) в корнях моляров верхней челюсти в старшей возрастной группе (>45 лет).

Выводы. Большинство премоляров верхней челюсти, первых моляров верхней челюсти и небных корней вторых моляров верхней челюсти отделены от дна верхнечелюстного синуса (тип 0), тогда как большинство мезиобуккальных и дистобуккальных корней вторых моляров верхней челюсти соприкасаются с дном синуса (тип 1). Измерения в области моляров верхней челюсти больше относятся ко дну верхнечелюстного синуса, чем к премолярам верхней челюсти, с меньшим вертикальным расстоянием от небных корней вторых моляров верхней челюсти. Расстояние между корнями моляров и вторых моляров верхней челюсти значительно увеличивается с возрастом.

Ключевые слова: конусно-лучевая компьютерная томография, моляры верхней челюсти, премоляры верхней челюсти, верхнечелюстной синус, дно верхнечелюстного синуса.

Контактный автор: Акиль Ибрагим Лазим Аль-Саеди, e-mail: Medicalresearch10@yahoo.com

Для цитирования: Акиль Аль-Саеди, Бахаа Аль-Бах, Риад Аль-Таи. Использование конусно-лучевой компьютерной томографии для оценки соотношения корней премоляров и моляров верхней челюсти к верхнечелюстному синусу при планировании стоматологического лечения. REJR 2024; 14(1):55-69. DOI: 10.21569/2222-7415-2024-14-1-55-69.

Статья получена: 06.11.23

Статья принята: 20.11.23

Introduction.

The maxillary sinus (MS), the largest air sinus in the body of the maxilla, varies in shape, size, and position between individuals as well as between sides of the same individual. Its dimensions can also differ by sex and ethnicity. The inferior wall of the MS is curved and extends between adjacent roots in approximately half of the population [1]. MS sizes vary between patients with a sinus floor extending between adjacent teeth or between individual roots in approximately 50% of the population [2].

Dentists who perform clinical procedures in the posterior maxilla should be aware of the degree of root protrusion into the sinus floor. The percentage of teeth approaching or penetrating the sinus varies widely among the examined samples and study settings [3].

The root tips of the maxillary molars (MM) are generally closer to the sinus floor than those of the premolars. An inverse relationship is found between the thickness of the bone buccolingually and that of the bone lying superior to the apex of the teeth [4].

The clinical introduction of cone beam computed tomography (CBCT) for diagnosis and planning has improved treatment approaches [5]. Studies that used CT scanning are even more accurate than cadaveric studies [1].

Compared with multispiral computed tomography (MSCT), CBCT has lower radiation, higher resolution, and a shorter scanning time by which can produce three-dimensional images of the oral and maxillofacial regions by evaluate the relationship between the apex of the maxillary roots and the MS [6]. When the roots project laterally or medially over the MS, the use of panoramic images will lead to misinterpretation and the root will appear to be in the sinus; therefore, CBCT should be considered to assess the risk associated with oral surgery in the maxillary posterior tooth area [7].

Conventional radiographic exams are commonly used in the study of the anatomical relationship between maxillary posterior teeth and MS. However, these exams have limitations that may jeopardize this analysis [1-3, 8, 9]. Periapical radiographs could not determine the the risk of perforation of the maxillary sinus floor (MSF) during periapical surgery [8]. The limitation resulting from the two-dimensional images prevents the correct interpretation of the periapical lesions relationship to the MSF [9]. Periapical and panoramic radiographs offer little accuracy to the morphometric analysis of the relationship of bone structures with teeth [10]. The clinical application of cone beam computed tomography (CBCT) as an aid in the

diagnosis and planning has contributed to establish effective therapeutic protocols [11-13]. The importance of CBCT scans in the analysis of the morphological characteristics of the MS and its relationship with the roots of the maxillary posterior teeth has been shown.

Most abnormalities of the MS were reportedly associated with at least one maxillary posterior tooth with a periapical lesion [8].

Sinusitis may result from the spread of a periapical or periodontal infection to the MS or from iatrogenic perforation of the sinus [9].

Therefore, assessing the relationship between the roots of the posterior teeth and the MSF is crucial before planning any dental treatment procedure in the posterior maxilla to avoid procedural complications [10].

Few studies have evaluated the relationship between maxillary posterior teeth and MS in the Iraqi population, therefore, the present study aimed to analyze the vertical relationship and vertical linear measurements (VLM) between the root tips of the maxillary posterior teeth and MS [8, 11, 12].

Materials and methods.

This study was approved by the Ethical Review Committee of the College of Dentistry, University of Basrah, and performed in accordance with the Code of Ethics of the World Medical Association (Declaration of Helsinki). CBCT images of 148 patients (62 men, 86 women) were evaluated, and these images were requested for many clinical purposes, including oral surgery, orthodontics, endodontics, and implants from 15/6/2018 to 1/2/2020. The age range was 18–63 years (average age, 32.1 years).

In this study, 1052 teeth were examined, including 518 maxillary premolars (262 maxillary first premolars [MFP] vs. 256 maxillary second premolars [MSP]) and 534 MM (254 maxillary first molars [MFM] vs. 280 maxillary second molar [MSM]).

The exclusion criteria were as follows: history of trauma/orthodontic treatment of the maxillary arch; pathology affecting MS size, shape, and/or appearance; history of surgical procedures in the posterior maxilla; presence of radiographic or periapical pathology signs around one or more of the apices of the included teeth; maxillary posterior teeth with developmental anomalies that could interfere with CBCT image interpretation; presence of root canal filling, root resorption, fracture, or open apex in any of the included teeth; and images with artifacts related to technique affecting the interpretation.

The CBCT images were obtained using a Gendex (GXDP -7000) CBCT machine (Germany) operating at 90 kV and 10 mA with a scan

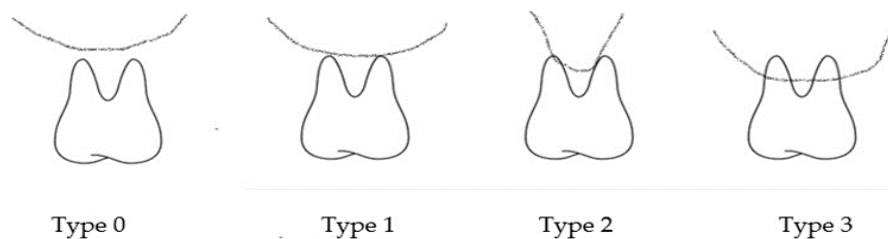


Fig. 1 (Рис. 1)

Fig. 1. Classification Jung and Cho of vertical relationship of maxillary sinus floor and maxillary posterior teeth [13].

Рис. 1. Схема. Классификация Jung и Cho вертикального соотношения дна верхнечелюстного синуса и зубов верхней челюсти [13].

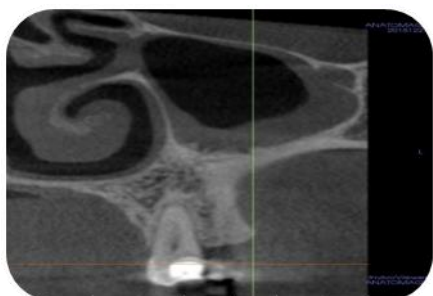

Fig. 2 а (Рис. 2 а)

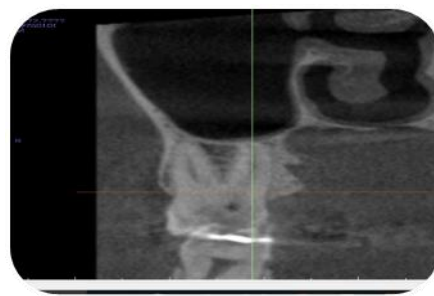


Fig. 2 б (Рис. 2 б)

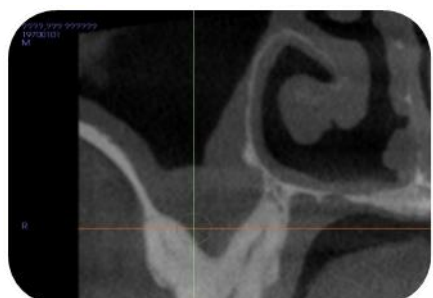

Fig. 2 с (Рис. 2 в)

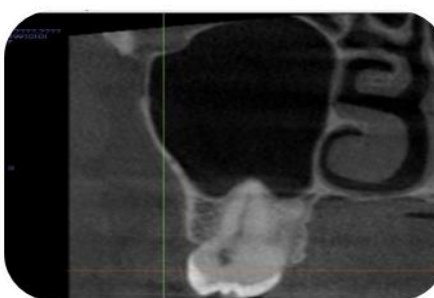


Fig. 2 д (Рис. 2 г)

Fig. 2. Types of relationship between roots of maxillary posterior teeth and inferior wall of maxillary sinus as appeared in coronal section of CBCT. а - type 0; б - type 1; с - type 2; д - type 3.

а – Type 0: the root is separated from the inferior wall of the MS,

б – Type 1: the root contacts the inferior wall of the MS,

с – Type 2: the root projects laterally (tangential) to the inferior wall of the MS without protruding into the sinus,

д – Type 3: the root protrudes into the inferior wall of the MS.

Рис. 2. Типы взаимоотношений между корнями зубов верхней челюсти и нижней стенкой верхнечелюстного синуса, определяемые на корональном срезе при КЛКТ. а – тип 0; б – тип 1; с – тип 2; д – тип 3.

а – Тип 0: корень отделен от нижней стенки верхнечелюстного синуса,

б – Тип 1: корень соприкасается с нижней стенкой верхнечелюстного синуса,

с – Тип 2: корень выступает латерально (по касательной) к нижней стенке верхнечелюстного синуса, не выступая в полость синуса,

д – тип 3: корень пролабирует нижнюю стенку верхнечелюстного синуса.

time of 13 s. The image dimensions used were 400.400.300 IJK, the image size (field of view) was 80.0×80.0×60.0 mm, while the image resolution was 0.20×0.20×0.20 mm. The minimum slice thickness was 0.25 mm, the slice interval was 1 mm, and the detector resolution was 200 μm. The scans were performed according to the manufacturer's instructions. All CBCT examinations were performed by an oral radiologist with more than 12 years of experience according to the ALARA principle.

The CBCT images were analyzed using an inbuilt software (GxPicture™) (Invivo5 dental

viewer application version 2.0.1) running on a 64-bit Windows 10 system. All images were analyzed using a Lenovo LCD screen (17 inches) with a resolution of 1920 × 1080 pixels in a dark room. Image contrast and brightness were adjusted during the examination using the software's image processing tools to obtain the optimal visualization condition. To determine the exact positions of the root apex and maxillary antrum floor, the examiners scrolled through the axial, coronal, and sagittal views. The CBCT images were independently evaluated by a professional oral radiologist, a maxilla

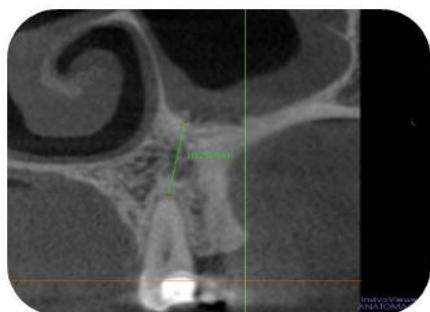


Fig. 3 a (Рис. 3 а)

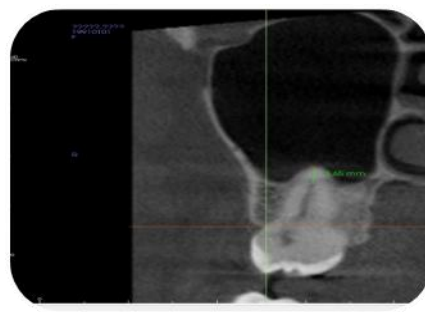


Fig. 3 b (Рис. 3 б)

Fig. 3. Vertical linear measurement between roots of maxillary posterior teeth and inferior wall of maxillary sinus as appeared in coronal section of CBCT.

a – positive linear measurement,

b – negative linear measurement.

Рис. 3. КЛКТ, корональный срез. Вертикальное линейное измерение между корнями зубов верхней челюсти и нижней стенкой верхнечелюстного синуса.

а – положительное линейное измерение,

б – отрицательное линейное измерение.

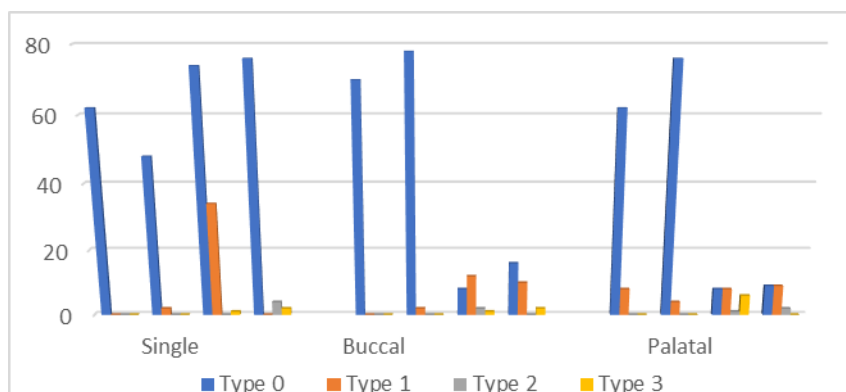


Fig. 4 (Рис. 4)

Fig. 4. Diagram.

Frequency of type of relationship between roots apices of maxillary premolars and maxillary sinus floor.

Рис. 4. Диаграмма.

Частота типов взаимосвязи между вершущками корней премоляров верхней челюсти и дном верхнечелюстного синуса.

Table №1. Frequency of type of relationship between roots apices of maxillary premolars and maxillary sinus floor.						
	Root	Tooth	Type 0	Type 1	Type 2	Type 3
	Single	17	2(50%)	2(50%)	0	0
		27	2(50%)	2(50%)	0	0
		Total	4(50%)	4(50%)	0	0
	Mesiobuccal	16	58 (42.6%)	24 (22%)	38 (28%)	10 (7.4%)
		26	52 (41.9%)	22(17.7%)	42 (33.9%)	8 (6.5%)
		Total	110(43.3%)	46(18.1%)	80(31.5%)	18(7.1%)
		17	22 (16.2%)	64 (47.1%)	6 (4.4%)	44 (32.3%)
		27	20 (15.6%)	56 (43.7%)	18 (14.1%)	34 (26.6%)
		Total	42(15.9%)	120(45.5%)	24(9%)	78(29.6%)
	Distobuccal	16	53 (40.8)	25 (19.2%)	39 (30%)	13 (10%)
		26	51 (41.1%)	27 (21.8%)	37 (29.8%)	9 (7.3%)
		Total	104(39.8%)	52(20.4%)	76(30.8%)	22(9%)
		17	30 (23.1%)	60 (46.1%)	16 (12.3%)	24 (18.5%)
		27	32 (25.8%)	62 (50%)	10 (8.1%)	20 (16.1%)
		Total	62(24.4%)	122(48.1%)	26(10.2%)	44(17.3%)
	Palatal	16	50 (38.5%)	15 (11.5%)	44 (33.8%)	21 (16.2%)
		26	48 (38.7%)	25 (20.2%)	25(20.2%)	26 (20.9%)
		Total	98(38.6%)	40(15.7%)	69(27.2%)	47(18.5%)
		17	48 (35.3%)	34 (25%)	44 (32.4%)	10 (7.3%)
		27	52 (40.6%)	44 (34.4%)	24 (18.8%)	8 (6.2%)
		Total	100(37.9%)	78(29.5%)	68(25.8%)	18(6.8%)

Table №2. Frequency of type of relationship between roots apices of single and multirooted maxillary molars and maxillary sinus floor.

Root	Tooth	Type 0	Type 1	Type2	Type 3
Buccal	17	2 (50%)	2 (50%)	0	0
	27	2 (50%)	2 (50%)	0	0
	Total	4(50%)	4(50%)	0	0
palatal	17	2 (50%)	2 (50%)	0	0
	27	2 (50%)	2 (50%)	0	0
	Total	4(50%)	4(50%)	0	0

facial surgeon, and an endodontist. The obtained data were compared, checked and assessed by the examiners at the same time to obtain consensus in their radiographic findings. A second reading was performed after 1 month using approximately 20% of the images selected randomly to assess intraobserver reliability and this time frame is due to waiting list and / or crowded patients attending to the center.

The included teeth were evaluated on axial, coronal, and sagittal views to determine the

relationship between the root apex and the MSF, the decision was reported according to the coronal section, and the type of each was classified according to Jung and Cho classification [13] as shown in Figure 1.

Linear measurements of the vertical distance between the root apex and the inferior wall of the MS were obtained using a linear measurement tool built in the Invivo5 dental viewer software as seen on the coronal and sagittal views. When the measured distance differed between the two planes (coronal and sagittal), the shortest value was dependent. The measurement was identified as positive when the root apex lies away from or below the inferior wall of the MS (Fig. 3a), while the measurement was identified as negative when the root apex protruded into or above the inferior wall of the MS (Fig. 3b).

Statistics were recorded for the type of relationship between the maxillary posterior root apex and the inferior wall of the MS on both sides of the maxilla, patient sex, and age. Sinus relationship types among the different age groups were assessed using the chi-square test. Intraobserver reliability was analyzed us

ing Cohen's kappa test. SPSS for Windows software (ver. 22.0) was used to conduct the statistical analyses.

Results.

The kappa value for intra-examiner agreement was 0.91, while those for inter-examiner agreement were 0.821 and 0.852 for the first and second assessments, respectively. There was good intra- and inter-examiner agreement.

As seen in Table №1 and Figure 4, the vast majority of MFP roots in the case of single-rooted teeth were classified as having a type 0 relationship with MSF (98.1%). For MSP, type 0 was the most common but at a slightly lower ratio (69.5%). For the buccal roots (BR) of the double-rooted MFP, type 0 had an incidence of 98.7%. For MSP, type 0 accounted for only 50% of the total. Type 0 was the most common in the palatal roots of the MFP (92%) and MSP (45.8%).

Table №2 shows that, for single-rooted MSM, the most common relationship was type 1 (45.6%). For the mesial BR (MBR) in multi-rooted MM, type 0 was the most common MFM (41.4%), while for MSM, type 1 was dominant (45.5%). In the distal BR (DBR), type 0 was the most common in the MFM (39.8%), while type 1 was more common in the MSM (48.1%).

For the palatal root (PR), type 0 was the most common in the first and second molars (38.3% vs. 37.9%, respectively) (Fig. 5).

As shown in Table №3, in the double-rooted MSM, type 0 and type 1 occurred at equal frequencies (50% vs. 50%).

Table №4 shows that type 0 was the most common for almost all age groups in the maxillary first and second premolars.

Table №5 shows that type 0 occurred at a

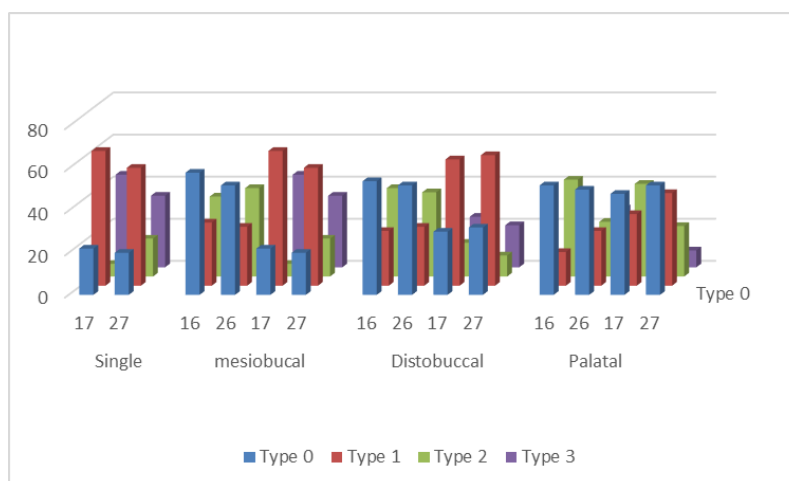


Fig. 5 (Рис. 5)

Fig. 5. Diagram.

Frequency of type of relationship between roots apices of single and multirooted maxillary molars and maxillary sinus floor.

Рис. 5. Диаграмма.

Частота типов взаимосвязи между верхушками корней однокорневых и многокорневых моляров верхней челюсти и дном верхнечелюстного синуса.

Table №3. Frequency of type of relationship between root apices of double rooted maxillary second molars and maxillary sinus floor.

Root	Tooth	Type 0	Type 1	Type2	Type 3
Buccal	17	2 (50%)	2 (50%)	0	0
	27	2 (50%)	2 (50%)	0	0
	Total	4(50%)	4(50%)	0	0
palatal	17	2 (50%)	2 (50%)	0	0
	27	2 (50%)	2 (50%)	0	0
	Total	4(50%)	4(50%)	0	0

higher frequency in the older age group (>45 years) for the MFM and MSM but to a lesser extent.

Table №6 shows that the longest VLM between the MP roots and MSF occurred for the MFP (range, 0–18.96 mm), while the MSP was closest to the MSF (range, -3.65 to 12.77 mm).

As shown in Table №7, the MBR of the MSM had the shortest distance to the MSF, while the MBR of the MFM and the PR of the MSM had the longest distance to the MSF.

In double-rooted MSM, the BR was closer to the MSF than the PR (Table №8).

Discussion.

The apices of the maxillary posterior teeth lie in close proximity to or within the sinus. Therefore, surgical and nonsurgical endodontic procedures in this area could lead to perforation of the inferior recess of an MS [4].

It is important to evaluate the relationship between the roots of the maxillary posterior teeth and the MSF when planning dental or surgical procedures to avoid related procedural complications [14].

Using CBCT could improve accuracy in diagnosing roots protruding into the sinus as

Table №4. Distribution of type of relationship between roots apices of maxillary premolars and maxillary sinus floor according to age.								
Root	Tooth	Age	Type 0	Type 1	Type 2	Type 3	Total	P-Value*
Single	First premolar	<30	76(98.7%)	1(1.3%)	0	0	77	0.529
		30-45	18(94.7%)	1(5.6%)	0	0	19	
		>45	16(100%)	0	0	0	16	
	Second premolar	<30	83(61.5%)	47(34.8%)	3(2.2%)	2(1.5%)	135	0.110
		30-45	30(78.9%)	7(18.5%)	1(2.6%)	0	38	
		>45	27(81.8%)	6(18.2%)	0	0	33	
Buccal	First premolar	<30	79(97.5%)	2(2.5%)	0	0	81	0.702
		30-45	41(100%)	0	0	0	41	
		>45	28(100%)	0	0	0	28	
	Second premolar	<30	16(47%)	16(47%)	2(6%)	0	34	0.522
		30-45	8(57.1%)	6(42.9%)	0	0	14	
		>45	2(100%)	0	0	0	2	
Palatal	First premolar	<30	75(92.6%)	6(7.4%)	0	0	81	0.088
		30-45	35(85.4%)	6(14.6)	0	0	41	
		>45	28(100%)	0	0	0	28	
	Second premolar	<30	14(41.2%)	16(47.1%)	0(0%)	4(11.7%)	34	0.345
		30-45	8(57.1%)	4(28.6%)	0(0%)	2(14.3%)	14	
		>45	2(100%)				2	

*Chi-squared t test

Table №5. Distribution of type of relationship between roots apices of single and multirooted maxillary molars and maxillary sinus floor according to age.

Root	Tooth	Age	Type 0	Type 1	Type 2	Type 3	Total	P-Value*
Single	Second molar	<30	2(3.33%)	4(66.67%)	0	0	6	----
		30-45	2(100%)	0	0	0	2	
		>45	0	0	0	0	0	
Mesiobuccal	First molar	<30	45(29.8%)	31(20.5%)	61(40.4%)	14(9.3%)	151	<0.001
		30-45	36(60%)	11(18.3%)	11(18.3%)	2(3.4%)	60	
		>45	29(67.4%)	4(9.3%)	8(18.6%)	2(4.7%)	43	
	Second molar	<30	15(9.4%)	63(39.4%)	16(10%)	66(41.2%)	160	<0.001
		30-45	16(24.2%)	38(57.5%)	4(6.1%)	8(12.2%)	66	
		>45	11(29%)	19(50%)	4(10.5%)	4(10.5%)	38	
Distobuccal	First molar	<30	37(24.5%)	37(24.5%)	55(36.4%)	22(14.6%)	151	<0.001
		30-45	36(60%)	11(18.3%)	13(21.7%)	0(0%)	60	
		>45	31(72.1%)	4(9.3%)	8(18.6%)	0(0%)	43	
	Second molar	<30	27(16.9%)	77(48.1%)	24(15%)	32(20%)	160	<0.001
		30-45	18(27.3%)	42(63.77%)	1(1.5%)	5(7.5%)	66	
		>45	21(55.3%)	13(34.2%)	4(10.5%)	0(0%)	38	
Palatal	First molar	<30	39(25.8%)	21(13.9%)	52(34.5%)	39(25.8%)	151	<0.001
		30-45	34(56.6%)	12(20%)	7(11.7%)	7(11.7%)	60	
		>45	27(62.8%)	4(9.3%)	10(23.3%)	2(4.6%)	43	
	Second molar	<30	51(31.9%)	39(24.4%)	56(35%)	14(8.7%)	160	<0.001
		30-45	26(39.4%)	34(51.5%)	4(6.1%)	2(3%)	66	
		>45	23(60.5%)	5(13.1%)	8(21.1%)	2(5.3%)	38	

*Chi-squared t test

Table №6. Linear measurements between the apices of maxillary premolars and the floor of the maxillary sinus.

Root	Tooth	No.	Mean	SD	Min.	Max.
single	14	62	8.39	2.80	1.70	13.43
	24	50	7.50	3.51	0.00	12.83
	15	108	3.17	2.86	0.00	8.6
	25	108	3.71	3.45	-2.94	11.11
Buccal	14	70	8.24	3.76	0.60	15.97
	24	80	7.49	3.37	0.00	14.68
	15	22	3.13	4.59	0.00	12.77
	25	28	2.04	2.1	0.00	6.18
Palatal	14	70	6.84	4.66	0.00	16.66
	24	80	7.02	4.16	0.00	18.96
	15	22	2.11	5.00	-3.65	12.19
	25	28	1.67	2.06	0.00	6.47

was reported by Roque-Torres et al., who found that, of 819 roots seen to protrude into the sinus on panoramic radiography, only 80 had the same position on CBCT; similar findings were reported by Shakhwan et al. upon comparing panoramic radiography to CT [11, 15].

The relationship between the root apex and the MSF could be interpreted differently between the coronal and sagittal planes on CBCT, so a root may be protruding inside the sinus on one plane but actually be in contact with or away from the sinus; in such cases, the root will be only be classified as protruding into the sinus when it demonstrates protrusion on all planes on the CBCT images [16]. However, although the root appears to protrude into the sinus in only one plane, it should be classified as a high-risk factor for odontogenic sinus infection and/or sinus floor perforation during surgical procedures. Similarly, the mean distance between the root apex and the MSF differed when measured on the coronal and sagittal planes. Therefore, the distance between the root apex and the MSF should be measured on

coronal and sagittal CBCT images, and the shortest value is selected as the final measurement [16, 17]. This was dependent on VLM in the present study.

In the present study, most of the MP roots were separated from the MS floor (type 0) (Table 1). This result was similar to that of previous reports [4, 14, 18, 19]. The appearance of type 0 was reportedly more commonly in the MFP (98.1%) than in MSP (70.4%); this finding supports what was reported by most previous studies [5, 20-22].

In our study, the MM was reportedly similar to the MSF with a shorter vertical distance from the MBR of the MSM (Table 2). In single-rooted MSM, we found that type 1 occurred more commonly than other types (45.6%), while for the MBR of multirooted MM (type 0) appeared more commonly in MFM (41.4%) meanwhile (type 1) was the most common in the MSM (45.5%). The same finding was reported for DBR, for which type 0 accounted for 39.8% of the MFM and type 1 accounted for 49.1% of the MSM. For PR, type 0 appeared more com-

Table №7. Linear measurements between the apices of single and multirooted maxillary molars and the floor of the maxillary sinus.

Root	Tooth	No.	Mean	SD	Min.	Max.
Single	17	4	0.90	1.045	0	1.81
	27	4	0.9	1.125	0	1.95
Mesiobuccal	16	136	1.64	2.866	-6.10	11.6
	26	130	1.55	2.885	-2.96	11.52
	17	123	-0.30	2.451	-5.89	7.48
	27	124	-0.09	2.332	-4.71	7.67
Distobuccal	16	136	1.42	2.874	-4.30	13.1
	26	130	1.49	2.696	-3.10	11.31
	17	132	0.57	2.566	-3.94	9.20
	27	124	0.59	2.663	-5.04	10.99
Palatal	16	136	1.00	2.883	-6.90	9.11
	26	130	1.09	3.336	-4.91	8.99
	17	132	1.41	2.965	-3.51	10.56
	27	128	1.68	3.175	-5.05	15.73

monly in both molars (38.3% and 37.9% of the MFM and MSM, respectively), which is consistent with the findings of many previous studies [6, 21-24]. For double-rooted MSM, only type 0 and type 1 occurred equally in the buccal and palatal roots.

In the present study, type 0, where the root apices are located away from the MSF, increased in occurrence with increasing age (Tables 4 and 5), indicating a significant decrease in sinus size in older age groups ($P < 0.001$) for all MM roots but no significant difference in MP roots, which could be related to the fact that most MP roots already had a type 0 relationship with MS and other types occurred at low frequencies. This finding supports the findings of Tang et al. of a Chinese population and those of other researchers [6, 19, 23, 25].

The longest mean VLM in the MP was reported for the single-rooted MFP (8.39 ± 2.80 mm and 7.50 ± 3.51 mm), followed by the BR of the double-rooted MFP, while a shorter distance was seen in the PR. The shortest distance in the MP was between the PR of the MSP and the MSF (right, 2.11 ± 5.00 mm; left, 1.67 ± 2.06

mm) (Table 6); these measurements are in line with what was reported by many preceding studies [6, 14, 19, 20, 26].

The VLM in the MM was much lower than that reported for the premolars, as mentioned above; the shortest distance was found between the MBR of the MSM and the MSF (right, -0.30 ± 2.451 mm; left, -0.09 ± 2.332 mm), followed by the DBR of the MSM (right, 0.57 ± 2.566 mm; left, 0.59 ± 2.663 mm). This finding was also reported by many previous studies, while other researchers reported that the DBR of the MSM had the shortest mean distance to the MSF as well as racial differences that may be related to the use of panoramic radiography instead of CBCT [4, 20, 27-29].

According to the measurements recorded in the present study, it is logical to state that in cases of type 0, when the root apex is below the MSF, it is relatively safe to perform dental procedures such as nonsurgical endodontic treatment with a low risk of periapical infection spread to the MS, although surgical procedures should be carefully performed, particularly in

Table №8. Vertical linear measurements between the apices of double rooted maxillary second molars and the floor of the maxillary sinus.

Root	Tooth	No.	Mean	SD	Min.	Max.
Buccal	17	4	0	0	0	0
	27	4	0	0	0	0
Palatal	17	4	1.13	1.304	0	2.26
	27	4	0.355	0.409	0	0.71

the MM. Other types (I, II, and III), in which the roots are either in contact with or protruding inside the MS, had a higher probability of inducing odontogenic sinus infection with an obvious risk of MSF perforation during periapical surgery, indicating the need for a professional analysis of CBCT images prior to any surgical procedure in this anatomical region. This conclusion was also emphasized by Tang et al [17].

Serova and co-authors concluded that in dental implantation procedures, it is very important to have a proper diagnosis before taking a step on doing any operations, as the success rate of these depend on the quality of investigation methods. With the advent of CT, quantitative and qualitative analyses of bone can be conducted for implant placement, it rapidly cover an extended anatomic region with reduced patient motion. With the advent of software used in CT, a 3D model can be obtained and the construction of a surgical template is possible. Imaging in dental implantation is required during all the stages of implant placement, as in preoperative planning, intraoperative control and postoperative follow-up [30]. In addition several previous studies supporting these conclusions like [31, 32].

The results of the present study could provide a research base of the relationship of the maxillary posterior teeth to the MS to the VLM between the roots and the MSF in the southern Iraqi population, which might be of clinical value for dentistry practitioners and dental surgeons.

Conclusions.

We recommend CBCT for evaluating the relationship between the roots of the posterior teeth and the MSF when planning surgical and nonsurgical procedures in the posterior maxilla. Most of maxillary premolars (MP), maxillary first molars (MFM), and palatal roots (BR) of the maxillary second molars (MSM) are sepa-

rate from the maxillary sinus floor (MSF) (type 0), whereas most of the mesiobuccal and distobuccal roots of the maxillary second molars are in contact with the sinus floor (type 1). MM measurements are more similar to the MSF than the MP with a shorter vertical distance from the BR of the MSM. The distance between the roots of the MM molars and the MSF raise significantly with increase age.

Author Contributions.

“Conceptualization, Aqeel Ibrahim Lazim Al-Saedi. and Riad AL-Taee; methodology, Aqeel Ibrahim Lazim Al-Saedi; software Aqeel Ibrahim Lazim Al-Saedi; validation, Aqeel Ibrahim Lazim Al-Saedi, Riad AL-Taee and Bahaa AL-Bakhakh; formal analysis, Aqeel Ibrahim Lazim Al-Saedi; investigation, Saedi, Riad AL-Taee and Bahaa AL-Bakhakh.; resources, Aqeel Ibrahim Lazim Al-Saedi; data curation, Aqeel Ibrahim Lazim Al-Saedi; writing—original draft preparation, Aqeel Ibrahim Lazim Al-Saedi; writing—review and editing, Riad AL-Taee; visualization, Aqeel Ibrahim Lazim Al-Saedi, Riad AL-Taee and Bahaa AL-Bakhakh; supervision Aqeel Ibrahim Lazim Al-Saedi; project administration, Aqeel Ibrahim Lazim Al-Saedi; funding acquisition, none All authors have read and agreed to the published version of the manuscript.”

Funding.

This research received no external funding.

Acknowledgments.

The current article is available as a preprint according to the following link: <https://assets.researchsquare.com/files/rs-503766/v1/794a1d63-f726-4222-82f0-8f0ae2579ac2.pdf?c=1631883079>

Conflicts of Interest.

The authors declare no conflict of interest.

References:

1. Souza A, Rajagopal K, Ankolekar V, Souza AS, Kotian S. Anatomy of maxillary sinus and its ostium: A radiological study using computed tomography. *CHRISMED J Heal Res*. 2016; 3(1):37. doi:10.4103/2348-3334.172397
2. Hauman CHJ, Chandler NP, Tong DC. Endodontic implications of the maxillary sinus: A review. *Int Endod J*. 2002; 35(2):127-141. doi:10.1046/j.0143-2885.2001.00524.x
3. Mattar E, Hammad L, Faden A, Khalil H. Relation of maxillary teeth to the maxillary sinus in normal Saudi individuals living in Riyadh. *Biosci Biotechnol Res Asia*. 2010;7(2):695-700.
4. Eberhardt JA, Torabinejad M, Christiansen EL. A computed tomographic study of the distances between the maxillary sinus floor and the apices of the maxillary posterior teeth. *Oral Surgery, Oral Med Oral Pathol*. 1992; 73(3):345-347. Doi: 10.1016/0030-4220(92)90133-B
5. Estrela C, Nunes CABCM, Guedes OA, et al. Study of anatomical relationship between posterior teeth and maxillary sinus floor in a subpopulation of the Brazilian central region using cone-beam computed tomography – Part 2. *Braz Dent J*. 2016; 27(1):9-15. Doi: 10.1590/0103-6440201600679
6. Gu Y, Sun C, Wu D, Zhu Q, Leng D, Zhou Y. Evaluation of the relationship between maxillary posterior teeth and the maxillary sinus floor using cone-beam computed tomography. *BMC Oral Health*. 2018; 18(1):1-7. Doi: 10.1186/s12903-018-0626-z
7. Kirkham-Ali K, La M, Sher J, Sholapurkar A. Comparison of cone-beam computed tomography and panoramic imaging in assessing the relationship between posterior maxillary tooth roots and the maxillary sinus: A systematic review. *J Invest Clin Dent*. 2019; 10(3):e12402. doi:10.1111/jicd.12402
8. Hussein ZA, Al-Nakib LH. Assessment of the Relationship between Maxillary Sinus Floor and Maxillary Posterior Teeth Root Apices Using Spiral CT scan. *J Baghdad Coll Dent*. 2017; 25(3):80-86. Doi: 10.12816/0015001
9. Nunes CABCM, Guedes OA, Alencar AHG, Peters OA, Estrela CRA, Estrela C. Evaluation of Periapical Lesions and Their Association with Maxillary Sinus Abnormalities on Cone-beam Computed Tomographic Images. *J Endod*. 2016; 42(1). doi:10.1016/j.joen.2015.09.014
10. Anter, E., Helaly, Y., & Samir, W. (2019). Assessment of Proximity of Maxillary Molars Roots to the Maxillary Sinus Floor in a Sample from the Egyptian Population using Cone-beam Computed Tomography (Hospital Based Study). *Egyptian Dental Journal*, 65(4-October (Oral Medicine, X-Ray, Oral Biology & Oral Pathology)), 3427-3438.
11. Shakhawan, M., Falah, A., Kawa A. The Relation of Maxillary Posterior Teeth Roots to the Maxillary Sinus Floor Using Panoramic and Computed Tomography Imaging in a Sample of Kurdish People Key words. *Tikrit J Dent Sci*. 2012; 1:81-88.
12. Evaluation of Maxillary Molars Roots Relation to Maxillary Sinus Floor by using Cone Beam Computed Tomography. *IAI-Kurwi, Hiba Abdul Azez; Areej Najm; Noor Allawi; Abbas International J Sci Res*. 2018; 7(10):784-786. Doi: 10.21275/ART20191877
13. Jung Y-H, Cho B-H. Comparison of panoramic radiography and cone beam computed tomography for assessing the relationship between the maxillary sinus floor and maxillary molars. *Imaging Sci Dent*. 2009; 39(2):69-73.
14. Fry R, Patidar D, Goyal S, Malhotra A. Proximity of maxillary posterior teeth roots to maxillary sinus and adjacent structures using Denta scan ®. *Indian J Dent*. 2016; 7(3):126. doi:10.4103/0975-962x.189339
15. Gurbuz O, Ersen A, Dikmen B, Gumustas B, Gundogar M. The Prevalence and Distribution of the Dental Anomalies in the Turkish Population. *J Anat Soc India*. 2019; 68:46-51. doi:10.4103/JASI.JASI
16. Kang SH, Kim BS, Kim Y. Proximity of posterior teeth to the maxillary sinus and buccal bone thickness: A biometric assessment using cone-beam computed tomography. *J Endod*. 2015; 41(11). doi:10.1016/j.joen.2015.08.011
17. Tang L, Xu L, Liu H. A Retrospective Study on the Relationship between Maxillary Posterior Teeth and Maxillary Sinus Floor Using Cone-beam Computed Tomographic Images. *J Anat Soc India*. 2020; 86(253):9.
18. Estrela C, Nunes CABCM, Guedes OA, et al. Study of anatomical relationship between posterior teeth and maxillary sinus floor in a subpopulation of the Brazilian central region using cone-beam computed tomography – Part 2. *Braz Dent J*. 2016; 27(1). Doi: 10.1590/0103-6440201600679
19. Ok E, Güngör E, Çolak M, Altunsoy M, Nur BG, Ağlarci OS. Evaluation of the relationship between the maxillary posterior teeth and the sinus floor using cone-beam computed tomography. *Surg Radiol Anat*. 2014; 36(9):907-914. Doi: 10.1007/s00276-014-1317-3
20. Yoshimine SI, Nishihara K, Nozoe E, Yoshimine M, Nakamura N. Topographic analysis of maxillary premolars and molars and maxillary sinus using cone beam computed tomography. *Implant Dent*. 2012; 21(6):528-535. doi:10.1097/ID.0b013e31827464fc
21. Hu X, Lei L, Cui M, Huang Z, Zhang X. Anatomical analysis of periapical bone of maxillary posterior teeth: a cone beam computed tomography study. *J Int Med Res*. 2019; 47(10):4701-4710. Doi: 10.1177/0300060519860960
22. Shokri A, Lari S, Yousefi F, Hashemi L. Assessment of the relationship between the maxillary sinus floor and maxillary posterior teeth roots using cone beam computed tomography. *J Contemp Dent Pract*. 2015; 15(5):618-622. Doi: 10.5005/jp-journals-10024-1589
23. Tian XM, Qian L, Xin XZ, Wei B, Gong Y. An analysis of the proximity of maxillary posterior teeth to the maxillary sinus using cone-beam computed tomography. *J Endod*. 2016; 42(3). doi:10.1016/j.joen.2015.10.017
24. Zhang X, Li Y, Zhang Y, et al. Investigating the anatomical relationship between the maxillary molars and the sinus floor in a Chinese population using cone-beam computed tomography. *BMC Oral Health*. 2019; 19(1):1-8. Doi: 10.1186/s12903-019-0969-0
25. Săndulescu M, Ciuluvică R, Didilescu A, Rusu M, Georgescu C. Morphometric analysis of the relationships between the maxillary first molar and maxillary sinus floor. *Open J Stomatol*. 2012; 02(04):352-357. doi:10.4236/ojst.2012.24060
26. Roque-Torres GD, Ramirez-Sotelo LR, de Almeida SM, Ambrosano GMB, Bóscolo FN. 2D and 3D imaging of the

relationship between maxillary sinus and posterior teeth. *Brazilian J Oral Sci.* 2015; 14(2):141-148. Doi: 10.1590/1677-3225v14n2a09

27. Razumova, S., Brago, A., Howijieh, A., Manvelyan, A., Barakat, H., & Baykulova, M. (2019). Evaluation of the relationship between the maxillary sinus floor and the root apices of the maxillary posterior teeth using cone-beam computed tomographic scanning. *Journal of Conservative Dentistry: JCD*, 22(2), 139.

28. Kilic C, Kamburoglu K, Yuksel SP, Ozen T. An Assessment of the Relationship between the Maxillary Sinus Floor and the Maxillary Posterior Teeth Root Tips Using Dental Cone-beam Computerized Tomography. *Eur J Dent.* 2010; 4(4):462-467.

<http://www.ncbi.nlm.nih.gov/pubmed/20922167><http://www.pubmedcentral.nih.gov/articlerender.fcgi?artid=PMC2948741>.

29. Gowrisankar C, Thanmayi P, Suprabath P, Balla H. Correlation of Maxillary Sinus to the Roots of Maxillary Posterior Teeth and a Review of Literature. *Int J Sci Res.* 2017; 6(1):506-515. Doi: 10.21275/art20164130.

30. Serova N.S., Sokkar A., Pavlova O.Yu., Medhat A. Radiology in dental implantation. *Russian Electronic Journal of Radiology.* 2021; 11 (1): 43-62.

31. Tarasenko S.V., Serova N.S., Znamenskaya Y.P. Cone-beam computed tomography as a method for evaluating the regeneration of the wells of removed teeth after augmentation. *REJR* 2020; 10(3):26-35. DOI:10.21569/2222-7415-2020-10-3-26-35.

32. Tarasenko S.V., Serova N.S., Shamanaeva L.S., Zagorskij S.V., Diachkova E.Yu. Analysis of dynamic changing of radiological picture of periapical odontogenic processes of the jaws after different methods of dental treatment. *Russian Electronic Journal of Radiology.* 2019; 9 (1): 27-33.