

# Adolescents are more sensitive than adults to the effects of radio frequency Waves: A Histopathological study in Mice

Rawaa S. Al-Mayyahi<sup>1\*</sup> and Wa'il A. Godaymi Al-Tumah<sup>2</sup>

<sup>1</sup>Department of Clinical Laboratory Science, College of Pharmacy, University of Basrah, Iraq

<sup>2</sup>Department of Physics, College of Science, University of Basrah, Basrah, Iraq

(Received 8 February, 2020; accepted 1 November, 2020)

## ABSTRACT

Increasing use of technological devices such as mobile phones and radar equipment has raised concerns about the possible harmful effects caused by exposure to radio frequency waves emitted from these devices. This study was conducted to evaluate the effect of radio frequency exposure on brain histopathology of male mice in two different age groups. A total of 18 healthy male albino mice were used in this study. They were classified into three groups: Control group (unexposed group) and experimental groups include adolescent group (postnatal day 21) and adult group (postnatal day 60) which were exposed to 10 GHz frequency with 60 mW power for 2 h per day for 4 weeks. Histologic findings show that exposure of male mice to radio frequency waves caused severe histopathological alterations in the brain leading to brain necrosis. Severity of histopathological alterations was associated with the age of mice as the alterations were more prominent in adolescent group compare with adult group. However, further molecular and cellular studies are needed to clarify the exact mechanism of radio frequency wave exposure on the brain.

**Key words :** Brain histopathology, Radio frequency waves, Adolescent mice, Adult mice.

## Introduction

Technological devices such as mobile phones, communication devices, and radar equipment are globally used in the environment (Komaki *et al.*, 2014). However, radio frequency waves of these devices are one of the most important risk factors that have adverse effects on human biological systems (Hardell and Sage, 2008; Bae *et al.*, 2013). It was found that radio frequency radiation below 10 GHz (to 1 MHz) can penetrate living tissues and generate heat resulting in tissue damage (Eghlidospour *et al.*, 2015). Therefore, there is growing concerns about the safety and health in the use of such devices in both adolescents and adults. Interestingly, holding

mobile phones closely to the head might result in radio frequency exposure to the head structures and functions; therefore, nervous system is affected by radio frequency waves (Odaci, Bas and Kaplan, 2008; Bas *et al.*, 2009). Furthermore, it was observed that the brain tissue absorbed largest amount of radio frequency energy and this absorption was found to be 24 times higher than in lung. As a result, brain function and structure can be more affected by these waves (Racuciu, Creanga and Miclaus, 2006). Several *in vivo* and *in vitro* experiments have been widely used to investigate the potential detrimental effects of radio frequency waves on biological systems (Balassa *et al.*, 2013; Al-Mayyahi, Al-Tumah and Ahmed, 2020; Al-Mayyahi, Al-Tumah and

Mohammed, 2020). In particular, the effects of radio frequency waves on the healthy central nervous system have been studied with regard to hearing perception, balance, learning and memory function, blood-brain barrier integrity, oxidative stress, neural cell survival and result in neurological changes and neurotoxicity in neuronal tissues (Kumlin *et al.*, 2007; Marino *et al.*, 2011; Klose *et al.*, 2014; Schneider and Stangassinger, 2014). All of these experiments show that brain and nerve cells are very sensitive and responsive to radio frequency waves. However, the effects of radio frequency are a current debate and still a controversial issue due to contradictory findings in different experiments. The variation in the results is due to difference in field intensity, exposure duration and variations between species in different experiments (Eghlidospour *et al.*, 2015; Lameth *et al.*, 2017; Samiee and Samiee, 2017). Also, few studies have been performed to compare the adverse effects of radio frequency on adolescent and adult brain. Therefore, this study was designed to investigate whether a 2 h whole-body exposure to 10 GHz frequency with 60 mW power of radio frequency waves could induce histopathological changes in adolescent or adult mice brain.

## Materials and Methods

### Animals care

Eighteen male albino mice were obtained from animal facilities of Veterinary College / Basrah University, (Basrah, Iraq). The mice were housed in animal center at College of Sciences, University of Basrah and they were kept in a 12 h light–dark cycles. The animals had free access to food and water during the experimental time. All animals were approved by the Animal Research Ethical Committee of Basrah University.

### Experimental design and the exposure system

Mice were assigned into three groups (six mice per group): Control-unexposed group, Experimental groups: These groups were classified into two groups according to their age: adolescent group (postnatal day 21) and adult group (postnatal day 60). Both experimental groups were exposed to 10 GHz frequency with 60 mW power for 2 h per day for 4 weeks. The radio frequency waves were generated from microwave system with horn antenna (AT 3000 waveguide system, Atten electronics CO.

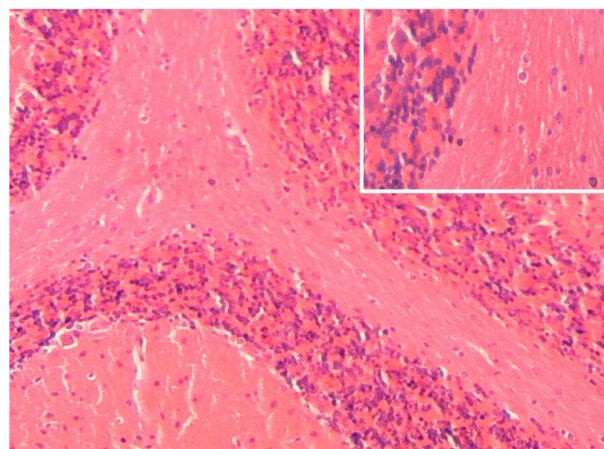
LTD, China). The horn antenna of the microwave system was oriented to the middle of the mice cage to generate an equal distribution of the radio frequency radiation. At the last four week, all animals were anesthetized by chloroform and then were sacrificed.

### Brain histopathological evaluation

For histological evaluation, brains were rapidly removed from each mouse after anaesthesia. All brain samples were fixed in formalin solution (10% w/v concentration) in room temperature then processed for paraffin embedding. Sections of thickness 5  $\mu$ m were cut. Slides were stained by standard haematoxylin and eosin (H&E). All of the stained slides were viewed and photographed using a light microscope at different magnifications.

## Results

The histological examinations showed that radio frequency exerts adverse effects on the brain tissue of both exposed groups. H&E-stained sections of brain tissue in the unexposed mice as control group showed normal brain tissue with intact neurons and neuroglia Fig. 1. Photomicrographs of exposed groups are shown in Fig. 2 and 3. As shown in these figures, brain damage increased in the adolescent group compared with adult group. The brain histopathological alterations in mice of young age included necrotic neurons, spongiosis or cavitation, nonspecific reactive alteration in neuroglial cells (gliosis) in response to brain damage, thrombosis



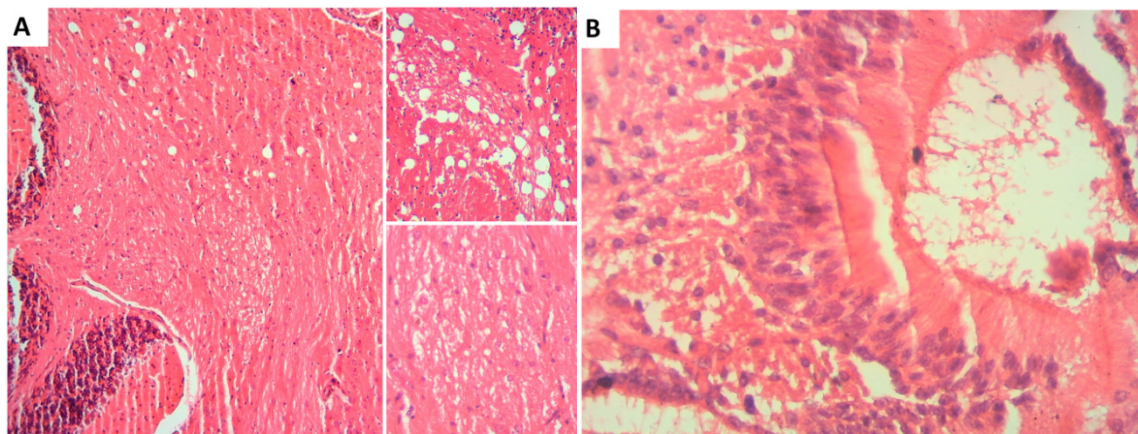
**Fig. 1.** Histological sections of mice brain tissue of control group showing normal brain tissue with intact neurons. Main and inset images were stained with H&E, x100 and x400, respectively.

and infiltration of lymphocytes Fig. 2. Adult exposed group also showed cavitation, scattered area of haemorrhage, infiltration of lymphocytes, degeneration and loss of brain tissue. Interestingly, the results of histopathology indicate the changes were more severe in adolescent group compared with adult group Fig. 3.

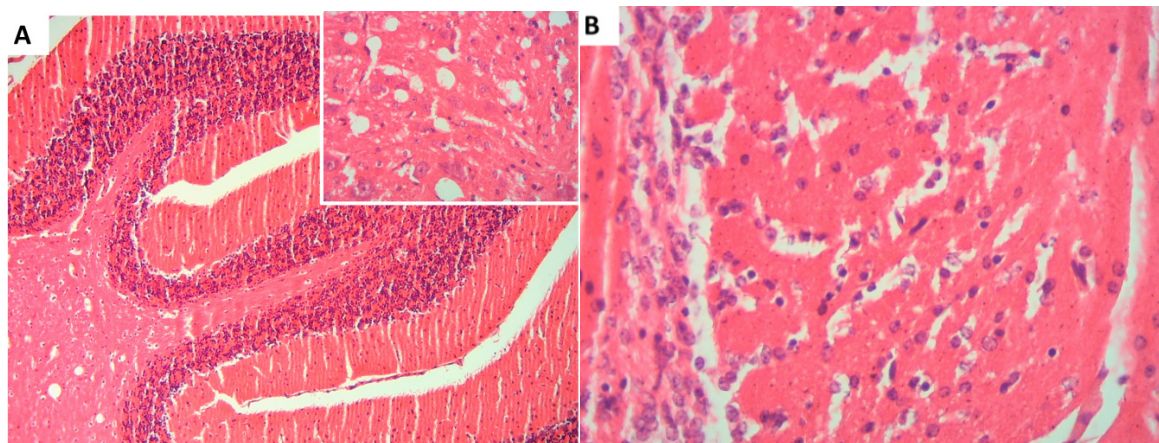
## Discussion

Findings of the present study show that exposure of male albino mice to radio frequency caused severe histopathological alterations in the brain at 10 GHz frequency with 60 mW power, which lead to more histopathological changes in brain of young age of mice compare with adult group. Radio frequency is

largely used in radar applications such as military and marine radars, air traffic control radars, and weather forecasting (Dawoud, 2003; Singh and Kapoor, 2015). Indeed, intensity of radio frequency and duration of exposure were key parameters in stimulation of brain injury. The present findings observed that most severe brain damage was in adolescent group compared with adult group therefore, the severity of brain lesions may be associated with the age of animals. The histological evaluation of the present study observed that the number of neuroglia (microglia and astrocytes) increases following radio frequency exposure. Microglia and astrocytes widely distribute in various regions of brain and play an important role in pathogenesis of neurodegenerative diseases (Maragakis and



**Fig. 2.** Histopathological alterations of mice brain tissue of adolescent group. A) Histological section showing spongiosis, gliosis and infiltration of lymphocytic cells in the brain. B) Histological section showing thrombus in the brain. Main and inset images were stained with H&E, x100 and x400, respectively.



**Fig. 3.** Histopathological alterations of mice brain tissue of adult group. A) Histological section showing cavitation, haemorrhage in the brain. B) Histological section showing degeneration and loss of brain tissue. Main and inset images were stained with H&E, x100 and x400, respectively.

Rothstein, 2006; Lull and Block, 2010). It was reported that astrocytic vesicle motility was raised after exposure to radio frequency (Gölfert *et al.*, 2001). In vivo experiments have observed that numbers of apoptotic cell were increased after exposure to radio frequency in chicken and mouse embryo brain while, the percentage of neural stem cells that differentiated into neurons was decreased (Lahijani, Bigdeli and Kalantary, 2011; Eghlidospour *et al.*, 2017). The mechanism for deleterious effects of radio frequency waves on nervous system is not fully characterised, however changes in heat shock protein synthesis and/or oxidative stress may be responsible for the mechanisms underlying radio frequency effects. It was found that the formation of stress proteins are involved in the radio frequency mechanisms. Due to the cellular stress and macromolecules damage that caused by the harmful effects of radio frequency, stress heat shock proteins are synthesis. The second proposed mechanism could be associated with oxidants and antioxidants processes. It was found that these two processes can be affected by environmental factors such as radio frequency (Martínez-Sámano *et al.*, 2012). The brain has high metabolic rate and has a large content of polyunsaturated fatty acids. Also, it consumes a lot of oxygen to generate high level of reactive oxygen species therefore brain become very sensitive to oxidative stress (Ito, Gong and Michikawa, 2013). Previous studies demonstrated that radio frequency exposure can cause oxidative stress in the cerebellum of mice and that increase the formation of the free radical content as a result of lipid oxidative damage in the brain (Akdag *et al.*, 2010; Chu *et al.*, 2011). Oxidative stress can cause several neurological diseases such as Parkinsonism and Alzheimer's disease (Ito, Gong and Michikawa, 2013).

## Conclusion

In conclusion, radio frequency waves emitted by X band radar frequency has adverse effects on the male albino mice brain and can lead to several histopathological alterations which can lead to brain necrosis. Severity of changes was associated with the animal age as the adolescent group has more effects compare with adult group. Although several studies have reported brain histopathological alterations following radio frequency exposures, the underlying mechanisms have not been fully understood. Future molecular and cellular experiments

will benefit greatly to elucidate exact mechanism behind the adverse effects of radio frequency on the nervous system.

## References

- Akdag, M. Z. 2010. Effects of Extremely Low-Frequency Magnetic Field on Caspase Activities and Oxidative Stress Values in Rat Brain Effects of Extremely Low-Frequency Magnetic Field on Caspase Activities and Oxidative Stress Values in Rat Brain', (February). doi: 10.1007/s12011-010-8615-3.
- Al-Mayyahi, R. S., Al-Tumah, W. A. G. and Mohammed, M. A. 2020. Histological and Haematological Alterations in Female Mice after Exposure to Electromagnetic Fields. *Pakistan Journal of Biological Sciences*. 23(3) : 398–405. doi: 10.3923/pjbs.2020.Research.
- Al-Mayyahi, R. S., Al-Tumah, W. A. G. and Ahmed, Z. A. 2020. The Effects of X Band Radar Frequency Exposure on Mice Testis and Kidney. *Pollution Research*. 39(February Suppl.) : 142–148.
- Bae, J. E. 2013. Electromagnetic field-induced converse cell growth during a long-term observation. *International Journal of Radiation Biology*. 89(12) : 1035–1044. doi: 10.3109/09553002.2013.825063.
- Balassa, T. 2013. Changes in synaptic efficacy in rat brain slices following extremely low-frequency magnetic field exposure at embryonic and early postnatal age. *International Journal of Developmental Neuroscience*. *International Society for Developmental Neuroscience*. 31(8) : 724–730. doi: 10.1016/j.ijdevneu.2013.08.004.
- Bas, O. 2009. Chronic prenatal exposure to the 900 megahertz electromagnetic field induces pyramidal cell loss in the hippocampus of newborn rats. *Toxicology and Industrial Health*. 25(6) : 377–384. doi: 10.1177/0748233709106442.
- Chu, L. Y. 2011. Extremely low frequency magnetic field induces oxidative stress in mouse cerebellum. pp. 415–421. doi: 10.4149/gpb.
- Dawoud, M. M. 2003. High Frequency Radiation and Human Exposure. *Omni*, (October), pp. 1–7.
- Eghlidospour, M. 2015. New Horizons in Enhancing the Proliferation and Differentiation of Neural Stem Cells Using Stimulatory Effects of the Short Time Exposure to Radiofrequency Radiation. *Journal of Biomedical Physics & Engineering*. 5(3) : 95–104. Available at: <http://www.pubmedcentral.nih.gov/articlerender.fcgi?artid=4576878&tool=pmcentrez&rendertype=abstract>.
- Eghlidospour, M. 2017. Effects of radiofrequency exposure emitted from a GSM mobile phone on proliferation, differentiation, and apoptosis of neural stem cells. *Anatomy & Cell Biology*. 50 (2) : 115–123. doi: 10.5115/acb.2017.50.2.115.
- Gölfert, F. 2001. Extremely Low Frequency Electromagnetic Fields and Heat Shock Can Increase

- Microvesicle Motility in Astrocytes. *Bioelectromagnetics*. 22 : 71–78. doi: 10.1023/A.
- Hardell, L. and Sage, C. 2008. Biological effects from electromagnetic field exposure and public exposure standards. *Biomedicine & Pharmacotherapy*. 62 : 104–109. doi: 10.1016/j.biopha.2007.12.004.
- Ito, J., Gong, J. and Michikawa, M. 2013. Alzheimer's Disease and Parkinsonism Oxidative Stress and FGF-1 Release from Astrocytes. 3(5). doi: 10.4172/2161-0460.1000133.
- Klose, M. 2014. Effects of Early-Onset Radiofrequency Electromagnetic Field Exposure (GSM 900 MHz) on Behavior and Memory in Rats. *Radiation Research*. 182 (4) : 435–447. doi: 10.1667/rr13695.1.
- Komaki, A. 2014. Effects of exposure to an extremely low frequency electromagnetic field on hippocampal long-term potentiation in rat. *Brain Research. Elsevier*. 1564, pp. 1–8. doi: 10.1016/j.brainres.2014.03.041.
- Kumlin, T. 2007. Mobile Phone Radiation and the Developing Brain: Behavioral and Morphological Effects in Juvenile Rats. *Radiation Research*. 168(4) : 471–479. doi: 10.1667/RR1002.1.
- Lahijani, M. S., Bigdeli, M. and Kalantary, S. 2011. Effects of sinusoidal electromagnetic fields on histopathology and structures of brains of preincubated white leghorn chicken embryos. *Electromagnetic Biology and Medicine*. 30(3) : 146–157. doi: 10.3109/15368378.2011.596250.
- Lameth, J. 2017. Acute Neuroinflammation Promotes Cell Responses to 1800 MHz GSM Electromagnetic Fields in the Rat Cerebral Cortex. *Neurotoxicity Research. Neurotoxicity Research*. 32(3) : 444–459. doi: 10.1007/s12640-017-9756-3.
- Lull, M. E. and Block, M. L. 2010. Microglial Activation and Chronic Neurodegeneration. *Neurotherapeutics*. 7(4): pp. 354–365. doi: 10.1016/j.nurt.2010.05.014.
- Maragakis, N. J. and Rothstein, J. D. 2006. Mechanisms of Disease: Astrocytes in neurodegenerative disease. *Nature Clinical Practice Neurology*. 2(12) : 679–689. doi: 10.1038/ncpneuro0355.
- Marino, C. 2011. Are the young more sensitive than adults to the effects of radiofrequency fields? An examination of relevant data from cellular and animal studies. *Progress in Biophysics and Molecular Biology*. Elsevier Ltd, 107(3) : 374–385. doi: 10.1016/j.pbiomolbio.2011.09.002.
- Martínez-Sámano, J. 2012. Effect of Acute Extremely Low Frequency Electromagnetic Field Exposure on the Antioxidant Status and Lipid Levels in Rat Brain', *Archives of Medical Research*. 43(3) : 183–189. doi: 10.1016/j.arcmed.2012.04.003.
- Odaci, E., Bas, O. and Kaplan, S. 2008. Effects of prenatal exposure to a 900 MHz electromagnetic field on the dentate gyrus of rats: A stereological and histopathological study. *Brain Research. Elsevier B.V.*, 1238, pp. 224–229. doi: 10.1016/j.brainres.2008.08.013.
- Racuciu, M., Creanga, D. E. and Miclaus, S. 2006. The absorption of electromagnetic energy in body tissues. *Anale Stiintifice Ale Universitatii. "Al. I. Cuza" Iasi. Tomul II, s. Biofizică, Fizicămedicală și Fizicamedicului*, pp. 9–14.
- Samiee, F. and Samiee, K. 2017. Effect of extremely low frequency electromagnetic field on brain histopathology of Caspian Sea *Cyprinus carpio*. *Electromagnetic Biology and Medicine*. 36(1) : 31–38. doi: 10.3109/15368378.2016.1144064.
- Schneider, J. and Stangassinger, M. 2014. Nonthermal effects of lifelong high-frequency electromagnetic field exposure on social memory performance in rats. *Behavioral Neuroscience*. 128(5) : 633–637. doi: 10.1037/a0037299.
- Singh, S. and Kapoor, N. 2015. Occupational EMF exposure from radar at X and Ku frequency band and plasma catecholamine levels. *Bioelectromagnetics*. 36(6): 444–450. doi: 10.1002/bem.21925.