



## SHORT-TERM EFFECTS OF THE ANTI-ASTHMATIC DRUG, MONTELUKAST, IN FEMALE RATS

Manal N. Al-Hayder<sup>1</sup>, Zahra A. Almiah<sup>2</sup>, Rawaa S. Al-Mayyahi<sup>3\*</sup> and Qasim A. Hussein<sup>4</sup>

<sup>1</sup>Department of Pharmacology and Toxicology, College of Pharmacy, University of Basrah, Iraq

<sup>2</sup>Department of Basra Health, Basrah, Iraq

<sup>3</sup>Department of Clinical Laboratory Science, College of Pharmacy, University of Basrah, Basrah, Iraq

<sup>4</sup>Basrah General Hospital, Basrah, Iraq

*Asthma is a chronic disease affecting more than 300 million people worldwide. Rising asthma rates have fuelled a demand for more effort to focus on the possible effects of anti-asthma therapies. Montelukast, a leukotriene receptor antagonist was shown to be an essential mediator of asthma. It has a dual mechanism of action, acting as a bronchodilator and anti-inflammatory. However, such therapy is associated with harmful effects. This study aimed to determine the short term effects following montelukast treatment. A total of twenty female rats were assigned into two equal groups. The control group received vehicle 0.2 ml of saline solution (0.9%), while the treated group received 10 mg/kg/day of montelukast diluted in saline solution 0.9% for five consecutive days. The haematological, biochemical and histopathological analyses were studied. There were no significant differences in haematological analysis and liver enzymes compared with control group. However, there were significant reductions in the levels of total cholesterol, triglyceride and high density lipoprotein compared with control group. Also, several histopathological alterations in rat liver tissues and kidney following montelukast treatment were observed. In conclusion, montelukast has harmful effects even after short treatment periods.*

**Keywords:** Montelukast, Haematology, Histopathology, Lipid profile, Cholesterol, Triglyceride

### INTRODUCTION

Several medications, such as sodium cromoglycate, theophylline, and glucocorticoids, are used to treat asthma. Montelukast, (MTK) a new anti-inflammatory medication, that directly interferes with leukotriene synthesis and/or reception (leukotriene receptor antagonists)<sup>1</sup>. Several mediators have been known as crucial players in mucus hyper secretion such as leukotrienes, acetylcholine, histamine, tachykinins and platelet activating factor<sup>2</sup>. The high susceptibility of MTK is due to its role in improving the recruitment of eosinophils and the vascular permeability in asthmatic patient.

Therefore, it is commonly and efficiently used in treating many conditions including respiratory disorders and allergic rhinitis<sup>3</sup>. Interestingly, number of researches have revealed the anti-inflammatory, antioxidant and anti-apoptotic features of MTK<sup>4&5</sup>. Also, the useful impact of MTK has documented in various investigational of liver damage models<sup>6-8</sup>. Despite these effects, many side effects have been recorded for this drug such as gastrointestinal disturbances, headache, sleep disorders, rashes, eosinophilia, neuropathy with a potential increase in suicidal behavior and aggression, agitation, dream abnormalities, anxiousness, tremor, hallucinations, depression, irritability, and restlessness in

addition hardly Churg Strauss syndrome<sup>9</sup>. Epidemiological researches have shown that people with asthma had higher levels of inflammatory biomarkers and a higher risk of cardiovascular disease<sup>10-15</sup>. Allayee *et al.* showed a clinical pilot study for the effects of MTK and theophylline on cardiovascular disease (CVD) hazard aspects, such as biomarkers of lipid and inflammation. Their findings prove a drop the levels of C-reactive protein, other than decreased levels of all lipids parameters in people receiving MTK compared to that in placebo. Although the decline of HDL levels, their findings propose a reduction in CVD-associated inflammatory and lipid parameters in the asthmatic patient group taking MTK<sup>16</sup>. Although much research on the long-term effects of MTK is available in the literature, the short-term impact of MTK is still unclear and not fully explained. In order to address this need, the current study goals to investigate the short term effects of MTK on body weight, blood parameters, lipid profile, some of liver enzymes and histopathological alterations in several organs in female rats.

## MATERIALS AND METHODS

### Animals

Twenty female albino rats of nine weeks age and weighing 100g – 120 g were obtained from animal center of Veterinary College / Basrah University. The care and use of experimental animals used in the current study were approved by the ethical committee of Basrah University for animal research. The animals were housed under controlled conditions and adapted for two weeks prior the beginning of the experiment. Then the animals were distributed to two groups: control, treated with vehicle 0.2 ml of saline solution 0.9%. While the other group treated with 10 mg/kg/day of MTK (Pioneer Co. for pharmaceutical industries-Iraq) diluted in saline solution 0.9% administered by intraperitoneal injection (0.2 ml) for five consecutive days<sup>17</sup>.

### Evaluation of the body and relative organs weight

At the beginning and end of the experiment, the body weights were reported. For relative weight analysis, livers, lungs,

kidneys, hearts, thymus glands and ovaries were properly separated and weighed on an analytical balance using the formula:

$$\text{organ weight (g)/animal weight (g) X 100}$$

### Hematological analysis

On the sixth day from the start of the experiment, we used chloroform to anesthetize the rats; cardiac puncture was used to collect blood samples in tubes have ethylenediaminetetraacetic acid. A complete blood picture was estimated by flow- cytometry using SYSMEX XT-2000i (Hoffman la Roche, Japan).

### Biochemical analysis

In order to obtain the serum to perform all biochemical tests from the blood drained from rats, it must be transferred to tubes without anticoagulant then we carry out a separation process for them using centrifuge (Genex, Florida, USA) at 4000 rpm for 20 min. To measure the levels of aspartate and alanine aminotransferases, triglycerides, high-density lipoprotein, and total cholesterol, the analytical commercial kits (JOURILABS, Ethiopia) were used; the Friedwald formula Gebrie *et al.* was used to measure the low- and very low density lipoproteins concentrations<sup>18</sup>.

### Histological analysis

Following dissection, liver, kidney and lung were carefully removed then preserved in 10% neutral formalin. All the removed organs were dehydrated and cleared. Afterward, they were fixed in paraffin and the paraffin block was sectioned at the thickness of 5 $\mu$ m. All the histological slides were stained with haematoxylin and eosin (H&E) for histopathological evaluation using a light microscope equipped with a digital camera (LCD light microscope)<sup>19</sup>.

### Statistical analysis

Research data were analyzed using Graph Pad Prism 5 for windows (San Diego, CA, USA). The statistical comparisons were analyzed using one-way analysis of variance (ANOVA), Bonferroni's multiple comparison tests (MCT) and Student's t-test. The results were reported as Mean  $\pm$  Standard Error of

Mean (SEM) and considered significant when P-values < 0.05.

## RESULTS AND DISCUSSION

### Results

#### Effect of MTK on body and relative organs weight

The current findings observed that there were no statistically significant differences in the body weights and relative organs including liver, lung, kidney, thymus gland and ovary of MTK group as compared with untreated group (Fig. 1).

#### Hematological evaluation

Haematological analysis was studied to measure the short-term effects of MTK on

hematological parameters in female rats. Results of the CBC analysis did not show any significant differences in blood parameters (Fig. 2).

### Biochemical evaluation

#### Effect of MTK on serum parameters of liver damage

The levels of specific liver enzymes such as ALT and AST that change in hepatic conditions and toxic damage in liver cells were estimated. The current findings revealed that serum levels of studied liver enzymes had not shown any significant differences in MTK group compared with untreated group (Fig. 3).

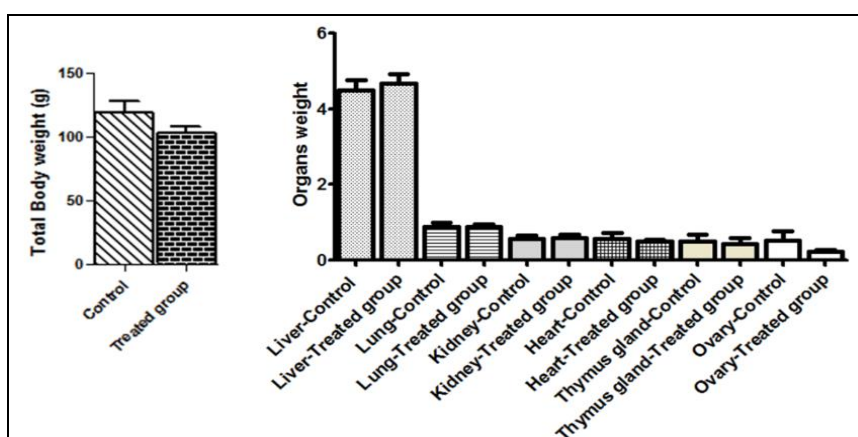


Fig. 1: Effect of MTK on body weight and relative organs weight.

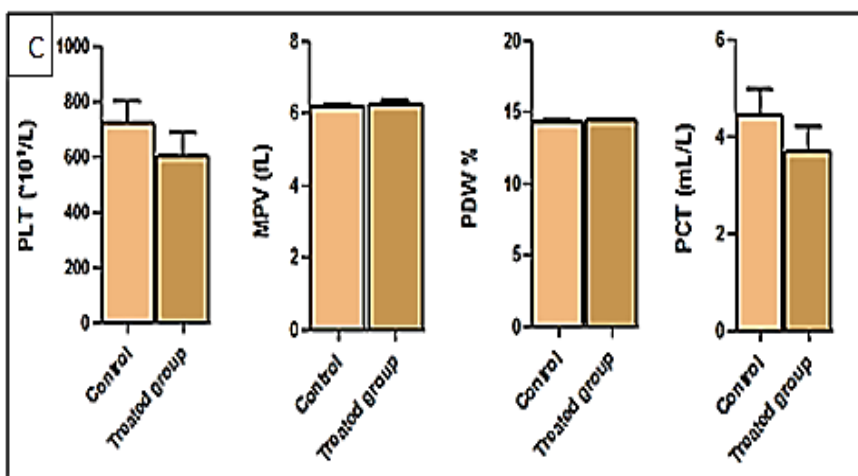
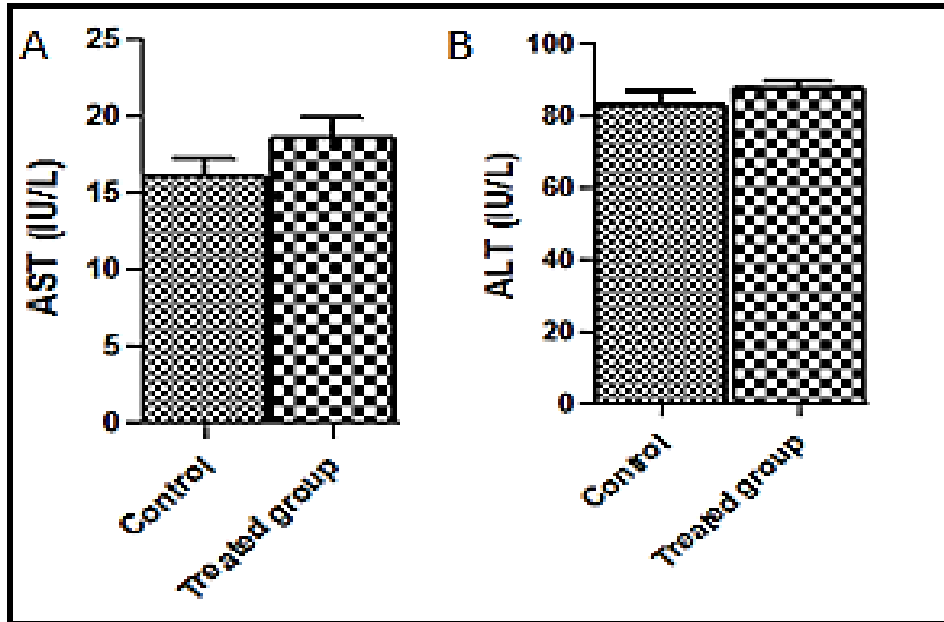


Fig. 2: Effect of MTK on hematological biomarkers. The graphs (A) represent the white blood cells parameters (WBCs, lymphocytes, Monocytes & Granulocytes percent), the graphs (B) represent red blood cells parameters (RBCs, HGB, PCV, MCV, MCH & MCHC) and the graphs (C) represent platelets parameters (PLT, MPV, PDW & PCT). No significance; one-way ANOVA, Bonferroni's post-test with error bars representing SEM.

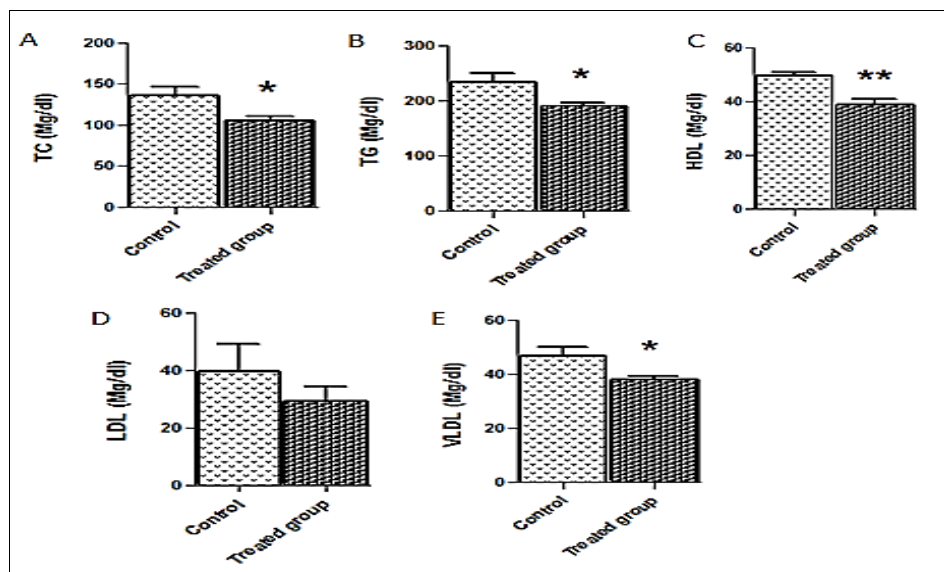


**Fig. 3: Effect of MTK on serum biomarkers of liver damage.** The graphs show, (A) aspartate aminotransferase activity (AST) and (B) alanine aminotransferase activity (ALT). There were no significant differences in ALT and AST between treated and control groups. Student's t-test; all data are presented as means ± SEM. Error bars represent SEM.

**Effect of MTK on serum lipid profiles**

The concentrations of serum lipid were examined to study the short-term effects of MTK in female rats. The findings revealed significant decreased ( $P < 0.01$ ) levels of TC and TG in MTK group compared control group

(Fig. 4 A and B). However, HDL and VLDL levels were significantly reduced ( $P < 0.05$ ) in animals treated with MTK compared with control group (Fig. 4 C and E). While the levels of LDL cholesterol does not show any significant differences in rats treated with MTK compared with control group (Fig. 4 D).

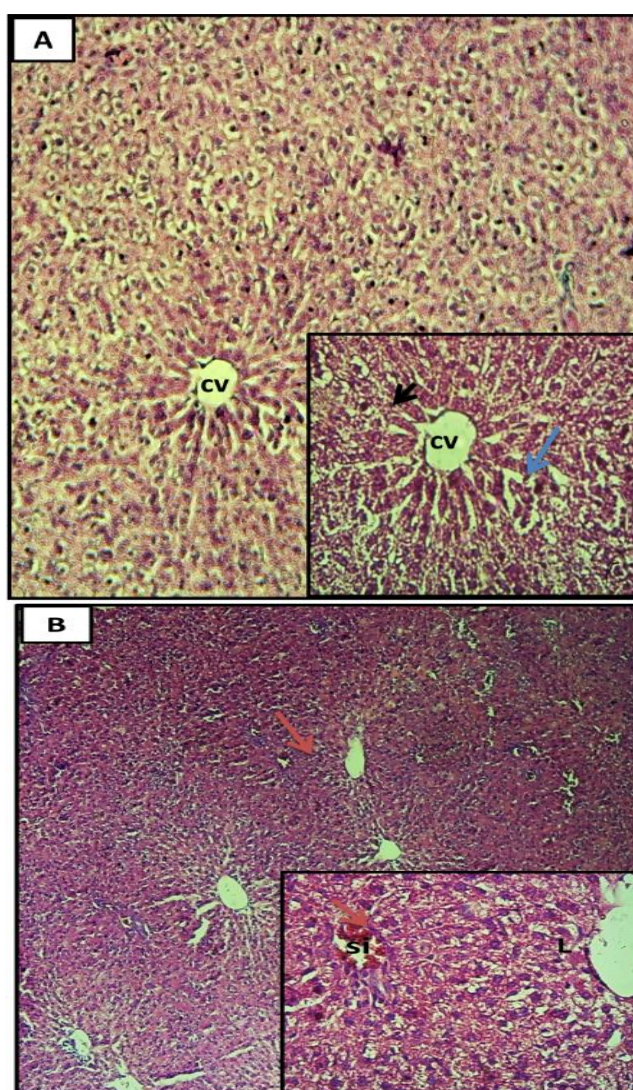


**Fig. 4: MTK Effect on serum lipid.** (A) the total cholesterol (TC), (B) the triglycerides (TG), (C) high-density lipoprotein (HDL) cholesterol, (D) low-density lipoprotein (LDL) cholesterol and (E) very low-density lipoprotein (VLDL). One-way ANOVA, Bonferroni's post-test with error bars representing SEM, \* $P < 0.05$ , \*\* $P < 0.01$  versus control group.

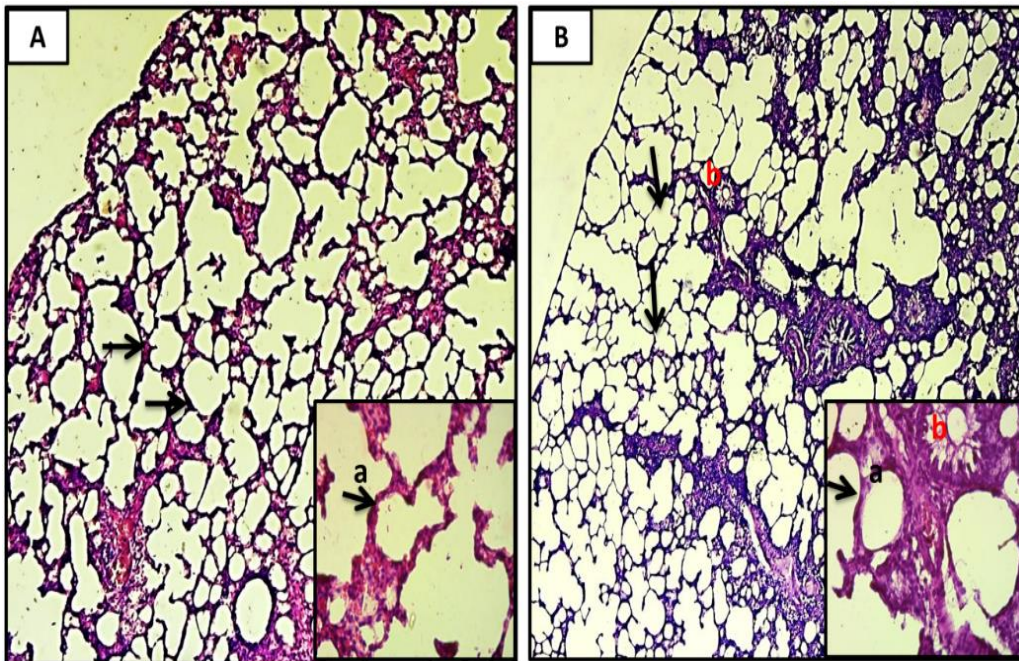
### Histopathological findings

Liver histopathological analysis in control group (Fig. 5A) showed integral hepatocytes architecture. However, several morphological variations were noticed in animals treated with MTK. These variations were displayed by fat vacillation, congested and dilated hepatic vein. Moreover, the hepatic lobe showed irregular localization of liver (Fig. 5B). Furthermore, lung tissue photomicrographs showed no evident histopathological variations in treated animals comparing with untreated animals. The control and treated groups have normal

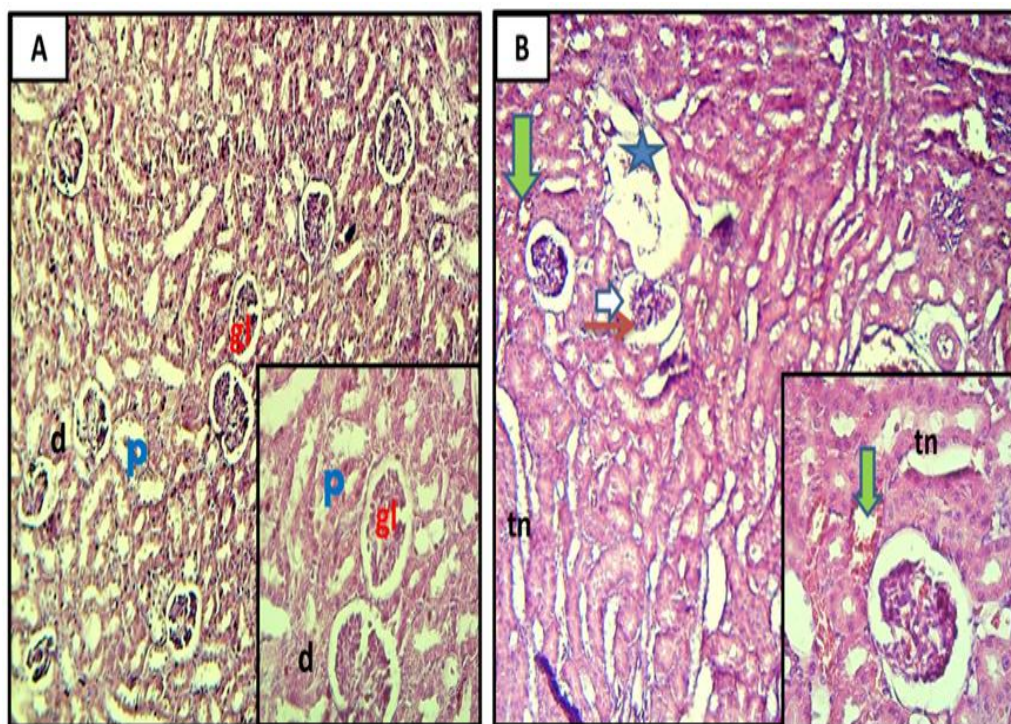
architecture of lung tissue bronchioles exhibited normal and the alveoli structure have normal thin inter-alveolar walls (Fig. 6). Histological analysis of the kidney tissue in the untreated group showed normal glomeruli and tubules with normal thickness of the capillary walls. In contrast, the kidneys' sections of MTK group demonstrated destructive changes including bleeding and congestion in the blood vessels, dilation of the glomerular capillaries, shrinkage of the glomeruli, necrosis in the epithelial tissue of tubules and enlargement of the Bowman's space (Fig. 7).



**Fig. 5: Histopathological effects of MTK on rats liver tissue.** (A) Untreated group showed normal liver histology: normal structure of hepatocytes (black arrow), normal central vein (cv) and normal sinusoid (blue arrow). (B) MTK treated group elucidated dilated in central vein and sinusoid infiltration (red arrow) and loss normal structure of hepatocytes (L). H&E stain and magnifications 100x and 400x for main and inset images respectively.



**Fig. 6: Histopathological effects of MTK on rat's lung tissue.** (A) Untreated group showed normal lung tissue with normal structure of the alveoli covered by thin septa (a and black arrow) and normal bronchiole (b). (B) MTK treated group elucidated normal structure lung histology as in control group. H&E stain and magnifications 100x and 400x for main and inset images respectively.



**Fig.7: Histopathological effects of MTK on rat's kidneys tissue.** (A) Control group displayed normal kidney tissue with normal glomerulus (gl), proximal (p) and distal tubules (d). (B) MTK treated group showed shrinkage in the glomerular (red arrow), enlargement in Bowman's space (white arrow), and necrosis in tubular (tn), in addition to dilation and congestion in the blood vessels (blue star). Using H&E stain and magnifications 100x and 400x for main and inset images respectively.

## Discussion

The present study was designed to investigate the short-term effects of MTK on some physiological, biochemical and histopathological parameters. The findings demonstrated that MTK did not show any effect on body and organs weight. The possible explanation of these results is might be due to the short treatment period. Similar results were observed in previous studies<sup>20</sup>. Also, the findings for MTK demonstrated there were no significant hematological alterations compared with control group. These findings are conflict with previous studies<sup>21&22</sup>. For example, Tugtepe and colleagues demonstrated that MTK reduced neutrophil recruitment and promoted the resolution of inflammation via antagonizing the effects of leukotrienes, which are effective stimuli for WBCs infiltration<sup>23</sup>. The elevation levels of liver enzymes such as ALT and AST are main factors for the progress of liver diseases<sup>24</sup>. The results of a previous study suggest that there was a strong relationship between elevated in the ALP, ALT and AST enzymes levels in rats with hepatic diseases and liver cells damage<sup>25</sup>. The Hepatic enzymes that are usually associated with hepatotoxicity are AST and ALT, which are considered biomarkers for hepatic toxicity<sup>26</sup>. Further, the current study showed a non-significant increase in the ALT and AST levels in rats treated with MTK as compared control group. These findings are broadly in line with previous study<sup>27</sup>. Interestingly, several studies have demonstrated the antioxidant, anti-inflammatory, and antiapoptotic properties of MTK. Moreover, the valuable effects of MTK have been documented in experimental models of liver damage<sup>28</sup>. The current study also found a reduction in the serum lipid concentrations of total cholesterol and triglyceride in rats treated with MTK compared with control group. The possible justification that may account for these outcomes is could be due to the antioxidant and anti-inflammatory activities of MTK. These results are in agreement with previous report<sup>29</sup>. However, Saibal and colleagues suggested in an infrequent case that MTK induced hypercholesterolemia, severe hypertriglyceridemia and acute pancreatitis in a 22 years old male patient<sup>30</sup>. Importantly, it has been demonstrated that the administration of MTK can protect the liver from

lipopolysaccharide-induced oxidative damage, as evidenced by decreased liver marker enzymes, protein oxidation, and neutrophilic infiltration markers as well as an increased antioxidant cascade<sup>31</sup>. In the context of lipid profile results, the current study showed reductions in serum lipid levels of the MTK treated group compared with control group. This finding might has an interesting implication. For instance, asthma patients taking montelukast may benefit from low levels of some lipid profiles such as TC, and TG to counter signs of hyperlipidemia. These results are in agreement with previous study which was conducted by Hooman *et al.*, they were observed that asthmatic patients receiving MTK have lower lipid levels<sup>29</sup>. However, the reduction of HDL cholesterol levels is of concern, the undesirable impacts of MTK on HDL levels raise a vital question that needs more investigation. Also, it would be of importance to investigate the biochemical mechanisms by which MTK impacts lipid metabolism. The present histological analysis confirmed the protective effect of the lung in MTK group. While in liver organ, there were some changes, but the most affected organs was the kidney. The present findings suggested that the continuous treatment with this drug may be caused several health problems such as kidney and hepatic diseases. However, Serdar *et al.*, (2015) results established that treatment with MTK ameliorated the negative effects of obstructive jaundice on liver histology<sup>28</sup>. In conclusion, to the best of our knowledge, the current work highlighted the safe effect of MTK on each of body weight, blood parameters, liver function and lipid profile. However, MTK has harmful effects on the kidneys. Therefore, more research is required to shed further light on the MTK effect in asthmatic patients and evaluate the efficacy of MTK on kidney function.

## REFERENCES

1. G. O. Dengiz, F. Odabasoglu, Z. Halici, E. Cadirci and H. Suleyman, "Gastroprotective and antioxidant effects of montelukast on indomethacin-induced gastric ulcer in rats", *J Pharmacol Sci*, 105 (1), 94-102 (2007).

2. D.F. Rogers, "Physiology of airway mucus secretion and pathophysiology of hypersecretion", *Respir Care*, 52(9), 1134-1146 (2007).
3. B. J. Udem, "Pharmacotherapy of asthma", In: Brunton L, Parker K, Blumenthal D, Buxton I, eds. Goodman & Gilman's The Pharmacological Basis of Therapeutics. 11th ed. New York: McGraw-Hill, 27, 462-474 (2006).
4. N.A. El-Boghdady, N.F. Abdeltawab and M.M. Nooh, "Resveratrol and Montelukast Alleviate Paraquat-Induced Hepatic Injury in Mice: Modulation of Oxidative Stress, Inflammation, and Apoptosis", *Oxid Med Cell Longev*, 2017, 9396425 (2017).
5. M.A. Ibrahim, E.F. Amin, S.A. Ibrahim, W.Y. Abdelzاهر and A. Abdelrahman, "Montelukast and irbesartan ameliorate metabolic and hepatic disorders in fructose-induced metabolic syndrome in rats", *Eur J Pharmacol*, 724, 204-210 (2014).
6. S. Kuru, K. Kismet, A.M. Barlas, S. Tuncal, P. Celepli, H. Surer, E. Ogus and E. Ertas, "The Effect of Montelukast on Liver Damage in an Experimental Obstructive Jaundice Model", *Viszeralmedizin*, 31(2), 131-138 (2015).
7. E. Kose, H.I. Salmaz, E. Sarihan, N. Vardi, Y. Turkoz and N. Ekinci, "Beneficial effects of montelukast against methotrexate-induced liver toxicity: a biochemical and histological study", *Sci World J*, 2012, 987508 (2012).
8. G. Daglar, T. Karaca, Y.N. Yuksek, U. Gozalan, F. Akbiyik, C. Sokmensuer, B. Gurel and N.A. Kama, "Effect of Montelukast and MK-886 on Hepatic Ischemia-Reperfusion Injury in Rats", *J Surg Res*, 153(1), 31-38 (2009).
9. K.D. Tripathi, "Anticholinergic drugs and drugs acting on autonomic ganglia", In: Tripathi M, ed. Essentials of Medical Pharmacology, 5<sup>th</sup> ed, New Delhi: Jaypee Brothers Medical Publishers (P) Ltd; 15, 195-209 (2003).
10. E.S. Ford, "Asthma, body mass index, and C-reactive protein among US adults", *J Asthma*, 40(7), 733-739 (2003).
11. T. Savykoski, T. Harju and M. Paldanius, "Chlamydia pneumonia infection and inflammation in adults with asthma", *Respiration*, 71(2), 120-125 (2004).
12. M. Takemura, H. Matsumoto, A. Niimi A, "High sensitivity C-reactive protein in asthma", *Eur Respir J*, 27(5), 908-912 (2006).
13. C. Iribarren, I.V. Tolstykh, M.D. Eisner, "Are patients with asthma at increased risk of coronary heart disease?", *Int J Epidemiol*, 33(4), 743-748 (2004).
14. A. Hozawa, J.L. Billings and E. Shahar, "Lung function and ischemic stroke incidence: the Atherosclerosis Risk in Communities study", *Chest*, 130(6), 1642-1649 (2006).
15. S. Onufrak, J. Abramson, V. Vaccarino, S. Onufrak, J. Abramson and V. Vaccarino, "Adult-onset asthma is associated with increased carotid atherosclerosis among women in the Atherosclerosis Risk in Communities (ARIC) study", *Atherosclerosis*, 195(1), 129-137 (2007).
16. H. Allayee, J. Hartiala, W. Lee, M. Mehrabian, C.G. Irvin, D.V. Conti and J.J. Lima, "The effect of montelukast and low-dose theophylline on cardiovascular disease risk factors in asthmatics", *Chest*, 132(3), 868-874 (2007).
17. T.H. W. Aledani, M. N. Al-Hayder, S. H. Mohammed and R. S. Al-Mayyahi, "Investigation of Montelukast Effect on Rosuvastatin-Induced Late Puberty in Rats", *J Hum Reprod*, 15(3), 228-232 (2022).
18. A. Gebrie, N. Gnanasekaran, M. Menon, M. Sisay and A. Zegeye, "Evaluation of lipid profiles and hematological parameters in hypertensive patients: laboratory-based cross-sectional study", *SAGE Open Med*, 6,2050312118756663 (2018).
19. N. Aljuhani, M.A. Elkablawy and H.M. Elbadawy, "Protective effects of Ajwa date extract against tissue damage induced by acute diclofenac toxicity", *J Taibah Univ Med Sci*, 14(6), 553-559 (2019).
20. E.S. Adel, A.M. Rania, E. Amany, Z. Noha and E. Rana, "Protective effect of melatonin versus montelukast in cisplatin-



- induced seminiferous tubule damage in rats", *Andrologia*, 50 (9), e13077 (2018).
21. M.A. Muslim, A. M. Sulta, M. Ali, S. Ahmed, S. Ali and B. Al Tuwajri, "Effects of Montelukast on free radical production in whole blood and isolated human polymorphonuclear neutrophils (PMNs) in asthmatic children", *Saudi Pharm J*, 19(4), 215-220 (2011),
  22. E. Noiri , T. Yokomizo, A. Nakao, T. Izumi , T. Fujita, S. Kimura and T. Shimizu, "An *in vivo* approach showing the chemotactic activity of leukotriene B(4) in acute renal ischemic–reperfusion injury", *Proc Natl Acad Sci*, 97(2), 823–828 (2000).
  23. H. Tugtepe, G. Sener, S. Cetinel, A. Veliog˘lu-Og˘u˘nc and B.C. Yeg˘en, "Oxidative renal damage in pyelonephritic rats is ameliorated by montelukast, a selective leukotriene CysLT1 receptor antagonist", *Eur J Pharmacol*, 557 (1), 69–75 (2007).
  24. G.P. Aithal and C.P. Day, "Nonsteroidal anti-inflammatory drug-induced hepatotoxicity", *Clin Liver Dis*, 11(3), 563-575 (2007).
  25. M. N. Al-Hayder, R. S. Al-Mayyahi and A. S. Abdul-Razak, "Effects of sunflower oils and beef tallow on serum parameters and liver histopathology in experimental rats" *Obesity Medicine*, 18, 100232 (2020).
  26. S. Bindu, S. Mazumder and U. Bandyopadhyay, "Non-steroidal anti-inflammatory drugs (NSAIDs) and organ damage: a current perspective", *Biochem Pharmacol*, 180, 114147 (2020).
  27. I.I. Hegab, H.E. El-Horany, M.M. Elbatsh and D.S. Helal, "Montelukast abrogates prednisolone-induced hepatic injury in rats: Modulation of mitochondrial dysfunction, oxidative/nitrosative stress, and apoptosis", *J BiochemMol Toxicol*, 1, e22231(2018).
  28. S. Kuru, K. Kismet, A.M. Barlas, S. Tuncal, P. Celepli, H. Surer and E. Oguş, "The Effect of Montelukast on Liver Damage in an Experimental Obstructive Jaundice Model", *Viszeralmedizin*, 31(2), 131-138 (2015).
  29. A. Hooman , H. Jaana, L. Won, M. Margarete, G.I. Charles, V. David, J.L. Conti and John, "The Effect of Montelukast and Low-Dose Theophylline on Cardiovascular Disease Risk Factors in Asthmatics", *Chest*, 132(3) 868-874 (2007).
  30. D. Saibal, M. Somnath, K. Jayanta, B. Sanjib, S. Indranil and K. Santanu, "A case of montelukast induced hypercholesterolemia, severe hypertriglyceridemia and pancreatitis", *J Young Pharm*, 5(2), 64-66 (2013).
  31. A. M. Mohamadin, A.A. Elberry, M.A. Elkablawy, H.S. Gawad and F. A. Al-Abbasi, "Montelukast, a leukotriene receptor antagonist abrogates lipopolysaccharide-induced toxicity and oxidative stress in rat liver", *Pathophysiology*, 18(3), 235–242 (2011).



## نشرة العلوم الصيدلانية جامعة أسيوط



### الآثار قصيرة المدى للدواء المضاد للربو ، مونتيلوكاست ، في إناث الجرذان

منال ن. الحيدر<sup>١</sup> - زهرة المياح<sup>٢</sup> - رواء سالم المياحي<sup>٣\*</sup> - قاسم أ. حسين<sup>٤</sup>

<sup>١</sup> قسم علم الأدوية والسموم ، كلية الصيدلة ، جامعة البصرة ، العراق

<sup>٢</sup> دائرة صحة البصرة ، البصرة ، العراق

<sup>٣</sup> قسم علوم المختبرات الإكلينيكية ، كلية الصيدلة ، جامعة البصرة ، البصرة ، العراق

<sup>٤</sup> مستشفى البصرة العام ، البصرة ، العراق

الربو مرض مزمن يصيب أكثر من ٣٠٠ مليون شخص حول العالم. ولقد أدى ارتفاع معدلات الربو إلى زيادة الطلب على بذل المزيد من الجهد للتركيز على الآثار المحتملة للعلاجات المضادة للربو. أن عقار المونتيلوكاست هو أحد مضادات مستقبلات الليكوترين ، ويعتبر علاج أساسي للربو إذ انه يمتلك آلية عمل مزدوجة ، حيث يعمل كموسع للقصبات الهوائية ومضاد للالتهابات. ومع ذلك ، يرتبط هذا العلاج بآثار ضارة. تهدف هذه الدراسة إلى تحديد التأثيرات قصيرة المدى لعلاج المونتيلوكاست. حيث تم تقسيم اناث الجرذان المستخدمة في هذه الدراسة والبالغ عددها عشرين حيوانا إلى مجموعتين متساويتين. تلقت مجموعة السيطرة ٠,٢ مل من المحلول الملحي (٠,٩%) ، بينما تلقت المجموعة المعالجة ١٠ ملجم / كجم / يوم من مونتيلوكاست مخفف في محلول ملحي ٠,٩% لمدة خمسة أيام متتالية. تمت دراسة تحاليل الدم والكيمياء الحيوية والأنسجة المرضية. وبينت نتائج الدراسة عدم وجود فروق معنوية في تحليل الدم وأنزيمات الكبد مقارنة مع مجموعة السيطرة. بينما لوحظ وجود انخفاض معنوي في مستويات الكوليسترول الكلي والدهون الثلاثية والبروتين الدهني عالي الكثافة مقارنة مع مجموعة السيطرة. أيضا ، لوحظت العديد من التغيرات النسيجية المرضية في أنسجة كبـد الفئران والكلى في الحيوانات المعاملة بالمونتيلوكاست. وعليه فقد بينت الدراسة الحالية وجود آثار ضارة للمونتيلوكاست حتى بعد فترات العلاج قصيرة.