



Clinical and diagnostic study of ovine chronic progressive pneumonia (Maedi-Visna) in sheep of Basrah, Iraq

K.M. Alsaad¹, A.J. Lafta¹, M.H. Lafta¹ and J.A. Ahmed²

¹Department of Internal and Preventive Medicine, ²Department of Pathology and Poultry Diseases, College of Veterinary Medicine, University of Basrah, Barah, Iraq

Article information

Article history:

Received 26 August, 2024

Accepted 27 October, 2024

Published online 01 January, 2025

Keywords:

Chronic pneumonia

Maedi-Visna

Iraq

Correspondence:

K.M. Alsaad

kamalsad58@yahoo.com

Abstract

In the current study 135 blood samples from local breed sheep (3-5 years old) and of both sexes, raised in Basrah, Iraq, was collected. The suspected animals showed signs of chronic pneumonia, anorexia, emaciation, progressive emaciation, and chronic cough. 25 samples clinically healthy local breeds were served as a control group. 88 sheep were found positive for the specific IgG of Lentivirus with an infection rate 65.18% which was confirmed by the indirect ELISA test. Hematological analysis indicated a significant increase in ESR with significant leukocytopenia, lymphocytopenia, and monocytopenia, with clear differences in indices of clotting factors. On post-mortem examinations, (40) dead carcasses show signs of progressive pneumonia, with an enlarged and heavy lung. Diseased lungs show whitish nodules on the parietal surface. Moreover, Variable whitish patches on the parietal surface of the affected lung were also detected. The histopathological appearance shows lobar pneumonia consists of progressive inflammatory exudation filling the lobar alveolar spaces with severe infiltration of inflammatory cells and erythrocytes inside alveolar spaces. A progressive inflammatory exudation filling the lobar alveolar spaces of the lung consists of inflammatory cell infiltration and exudation with erythrocytes inside the alveolar spaces; also, there is a hyperplastic proliferation of the bronchial epithelial lining was also indicated. Moreover, Early fiberoptic lesion refers to the stage of red hepatization of pneumonia besides many inflammatory cells, and erythrocyte infiltration in the alveolar spaces was also recognized. The disease was confirmed in Basrah, Iraq. Therefore, preventive measures to protect animals in the area is advised.

DOI: [10.33899/ijvs.2024.152796.3833](https://doi.org/10.33899/ijvs.2024.152796.3833), ©Authors, 2025, College of Veterinary Medicine, University of Mosul.

This is an open access article under the CC BY 4.0 license (<http://creativecommons.org/licenses/by/4.0/>).

Introduction

Ovine chronic progressive pneumonia (Maedi-visna) is a persistent virus infection distributed globally and considered an essential chronic viral disease of sheep and goats with a high worldwide prevalence. It is caused by a Lentivirus with characteristic clinical signs including chronic pneumonia, mastitis, encephalitis and arthritis, which may also be observed in diseased animals (1-3). The disease causes significant economic losses because of animal culling or high mortalities of diseased animals and depressing animal productivity (4). The disease is characterized by the lifelong

persistence of the causative virus in host monocytes and macrophages. However, a changeable prolonged time between the onset of the disease and the stimulation of a serologically detectable antiviral antibody response might be needed (5). The disease could infect sheep and goats even though, diseased animals do not show obvious signs, However, they stay persistently infected and can transfer the causative agent (6,7). Maedi-visna refers to labored or exhausted breathing (Maedi), which reflects progressive interstitial pneumonitis. Moreover, wasting or shrinkage (Visna) is another clinical manifestation diseased animals, reflecting paralyzing meningoencephalitis. On the other

hand, progressive pulmonary disease is the primary finding with Maedi-visna virus infection (2,8). It was shown that the high speed of the disease spreading due to flaws or lateness of treatment or vaccination programs and the lack of prevention measurement plan protocols, resulted in control difficulties, as did the lack of active protocols for early and fit diagnosis of diseased patients using precise and specific serological and molecular techniques (9,10). Furthermore, isolation and characterization of Maedi-visna infection might not always be attempted for usual diagnostic procedures because of the persistent nature of the virus. Therefore, stability and a positive antibody status could be enough to identify and detect the carrier status. Furthermore, because of the seroconversion, which comes late after the viral infection, a negative serological status might indicate recently infected animals (11,12). It was documented; that the World Organization for Animal Health (OIE) included Maedi-visna disease the list of notifiable contagious diseases that considerably affect animal world trade and products. Moreover, in ovine, the economic losses related to Maedi-visna infection could be more evident and effective (1). It was shown that ELISA is the common screening test used for detection and surveillance. It detects antiviral antibodies with high sensitivity and specificity regarding disease occurrence and seroconversion (13,14). Notwithstanding, serum-positive samples do not indicate or approve the clinical disease. On the contrary, a seronegative animal also cannot be considered disease-free. Consequently, seroconversion might require a period even at the beginning of the infection. The titer antibodies could reflect the differences within an animal's life. However, in some diseased cases, antibodies could not be detectable using different ELISA tests (depending on the antibody titration and the type of ELISA applied), which may indicate the inaccuracy of this test for an accurate and final diagnosis (15,16).

Ovine chronic progressive pneumonia (Maedi-visna) is suspected in sheep of Basrah, Iraq, for the first time causing high morbidity and mortality rates, Therefore, clinical and diagnostic studies were applied.

Materials and methods

Ethical approve

The Animal Ethics Committee at the College of Veterinary Medicine, University of Basrah, Iraq, allowed this research to be conducted in accordance with the official letter No. 7/18/4729 dated 2023.

Study design

The study assessed 135 local sheep breeds 3-5 years old and of both sexes reared in Basrah province, Iraq. The study started from October 2023 to June 2024. Suspected animals show signs of chronic pneumonia, inappetence, emaciation, progressive wasting, and chronic cough. Twenty-five

clinically healthy local sheep breeds were served as a control group. Diseased and control groups were subjected to complete clinical and clinical pathological examinations to exclude common clinical diseases such as blood parasitic, viral, gastrointestinal parasitic infection and nutritional diseases using the usual laboratory procedures.

Sampling and hematological assessment

Fifteen milliliters of blood were withdrawn from the animal jugular vein from each diseased and control animal, From these, three milliliters (3) of blood were mixed with EDTA for evaluation of the complete blood picture, including, the total erythrocyte count (RBC), hemoglobin concentration (Hb), packed cell volume (PCV), total thrombocytes count, thrombocytes distribution with, the mean thrombocytes volume and total leukocytes count (TLC) using a general blood analysis device from (GENEX . USA). Moreover, differential leukocyte count was applied by using blood smears according to the Giemsa stain technique (17). On the other hand, three milliliters (3) of blood were mixed with Trisodium citrate to estimate blood clotting factor indices (using plasma) (prothrombin time, activated partial thromboplastin time, and fibrinogen time), using special kits from Bi-olabo, France. Furthermore, the erythrocyte sedimentation rate (ESR) was also estimated using the Wintrobe tube technique, according to Weiss and Wardrop (18).

Macroscopic and histopathological examinations

Forty dead carcasses confirmed with ovine chronic progressive pneumonia were subjected to postmortem macroscopic and histopathological examinations and evaluation. Hereby, according to Cullen, Stalker (19). Samples were extracted from the lungs of dead animals and placed in a 10 percent formaldehyde solution (buffered neutral). Specimens were cleaned with tap water following seventy-two hours of fixation. After that, regular handling and processing were performed with a series of alcohol concentrations starting from 70 to 100% absolute alcohol for two hours at each concentration to remove water from the processed tissues. Moreover, xylol was used during the clearing procedure. Afterward, specimens were embedded using liquid paraffin wax at 58°C in two phases to create specimen blocks, which were sectioned at a thickness of 5 mm for all tissues. Finally, sectioned tissues were stained with hematoxylin and eosin stain (19).

Indirect ELISA test

To investigate the specific IgG immunoglobulin, an ELISA assay for Maedi-visna was applied according to the manufacturer's procedures from CREATIVE DIAGNOSTICA (USA).

Statistical analysis

SPSS (student *t*-test), according to Leech *et al.* (20). Statistical calculations were used in the current work to

estimate and calculate the statistical difference between the diseased and control groups. The significant value was set at ($P < 0.05$).

Results

Clinical and Hematological results data

Results indicated that out of 135 sheep serum examined via the indirect ELISA test 88 65.18% was positive for the specific IgG of Lentivirus casing ovine chronic progressive pneumonia Maedi-visna. Where, infected animals exhibited various clinical signs, including loss of appetite which was seen in 81.8% of diseased sheep, dyspnea with an obvious increase in abdominal breathing 78.4%, chronic cough with abnormal lung sound (dry rales and/or crepitation) 73.8%, an extension of the neck with nostrils expansion 73.8%, progressive weakness and emaciation 72.7%, decrease milk production in lactating ewes 37.5% and lameness 31.8% (Table 1). On the other hand, during the clinical

examinations, diseased sheep showed average body temperature associated with a significant rise in respiratory and heart rate compared with the control group (Table 2). Hematological analysis of diseased sheep affected with Media/visna compared with control healthy sheep indicates a significant increase in ESR values, A significant leukocytopenia due to a decrease in total leukocyte count and a significant lymphocytopenia, as well as monocytopenia in diseased sheep, compared with the control group (Table 3). Concerning the indices of clotting factor of the infected sheep group and the controls, the results indicated a significant decline in total thrombocyte count in the diseased sheep group than in the control group. While a significant increase has been encountered in the amount of the distribution width of the platelets, the mean volume of the platelets, prothrombin time, the activated partial thromboplastin time, as well as the fibrinogen time of the diseased sheep group compared with the control group (Table 4).

Table 1: Clinical manifestations of sheep suffering from Maedi-visna

Clinical signs	Diseased animals (n=88)	%
Loss of appetite	72	81.8
Dyspnea with an obvious increase in abdominal breathing	69	78.4
Chronic cough with abnormal lung sound	65	73.8
Extension of the neck with nostril expansion	65	73.8
Progressive weakness and emaciation	64	72.7
Decrease milk production in lactating ewes	33	37.5
Lameness	28	31.8

Table 2: Body temperature, Respiratory, and heart rate of diseased sheep with Maedi-visna and control group

Clinical parameters	Control group (n=25)	Diseased sheep group (n=88)
Body temperature (°C)	38.45±0.32	38.62±0.43
Respiratory (rate/minute)	21.51±2.25	62.4±8.2*
Heart (rate/minute)	81.21±4.81	109.4±11.2*

Mean±Standard error of the mean. * Significant at $P < 0.05$.

Table 3: Hematological changes of diseased sheep with Media-visna and control group

Hematological Parameters	Control group (n=25)	Diseased sheep group (n=88)
RBC ($\times 10^6$)	7.88±1.13	7.76±1.31
Hb (g/dl)	12.35±1.12	12.67±1.87
PCV (%)	31.4±2.76	33.78±3.23
ESR (mm/24hr)	4.11±1.6	25.78±5.91 *
TLC ($\times 10^3$)	12.23±1.78	9.23±4.76*
Neutrophils (%)	6772±131.23	6410.17±36.12
Lymphocytes (%)	5221±112.33	3012.33±131.22*
Monocytes (%)	172±45.16	143.22±25.71*
Eosinophils (%)	200±21.23	202.15±31.11
Basophils (%)	30±4.45	32.12±10.13

Mean±Standard error of the mean. * Significant at $P < 0.05$.

Table 4: Changes in the indices of the clotting factor of sheep with Maedi-visna and the control group

Parameters	Control group (n=25)	Diseased sheep group (n=88)
Thrombocytes count (g/L)	455.74±13.41	295.37±65.14*
The platelet distribution width (%)	14.53±4.32	23.51±5.14*
The mean platelet (volume/fL)	9.34±2.34	15.36±7.33*
Prothrombin (time/sec)	15.82±2.54	22.18±4.61*
The activated partial thromboplastin (time/sec)	52.59±2.73	69.21±6.88*
Fibrinogen (time/sec)	20.34±4.45	33.31±7.78*

Mean±Standard error of the mean. * Significant at P<0.05.

Postmortem and histopathological examination

Postmortem examinations confirmed that dead carcasses with ovine chronic progressive pneumonia (Maedi-visna) show signs of progressive pneumonia, whereby the affected lung was enlarged and heavy without any collapse. Moreover, there are apparent rib impressions on the costal surface of the affected pulmonary lobe. In addition, the lung has patchy hemorrhagic lesions (Figure 1).

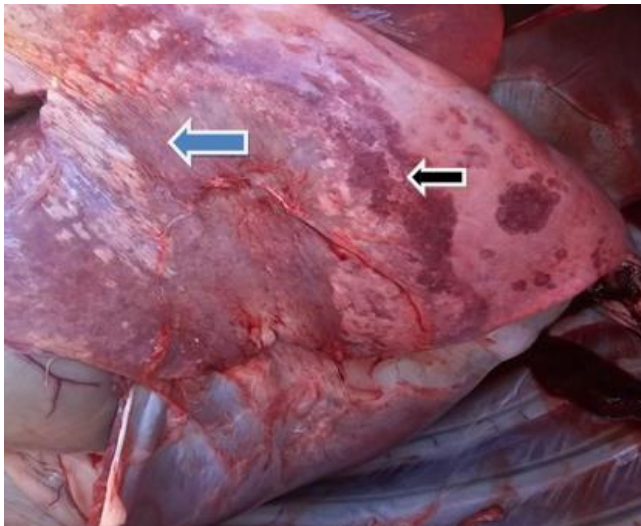


Figure 1: The gross appearance of the lung shows progressive pneumonia, whereby the affected lung is enlarged and heavy without any collapse. Moreover, there are obvious rib impressions on the costal surface of the affected pulmonary lobe (black arrow), In addition, there are patchy hemorrhagic lesions on the lung (blue arrow).

On the other hand, diseased lungs also show variable nodular sizes with whitish nodules on the parietal surface. Moreover, the affected lung failed to collapse. Further, variable whitish patches on the parietal surface of the affected lung were also detected (Figures 2 and 3). Nonetheless, the histopathological appearance of dead sheep with Maedi-visna shows lobar pneumonia consists of progressive inflammatory exudation filling the lobar alveolar spaces with severe infiltration of inflammatory cells, and erythrocytes inside alveolar spaces, referring to the

congestion stage of pneumonia. Furthermore, progressive inflammatory exudation filling the lobar alveolar spaces of the lung consists of inflammatory cell infiltration and exudation with erythrocytes inside the alveolar spaces. Also, a hyperplastic proliferation of the bronchial epithelial lining is indicated in diseased lungs (Figures 4 and 5). On the other hand, early fiberoptic lesion refers to the stage of red hepatization of pneumonia and many inflammatory cells and erythrocytes infiltration in the alveolar spaces (Figure 6).

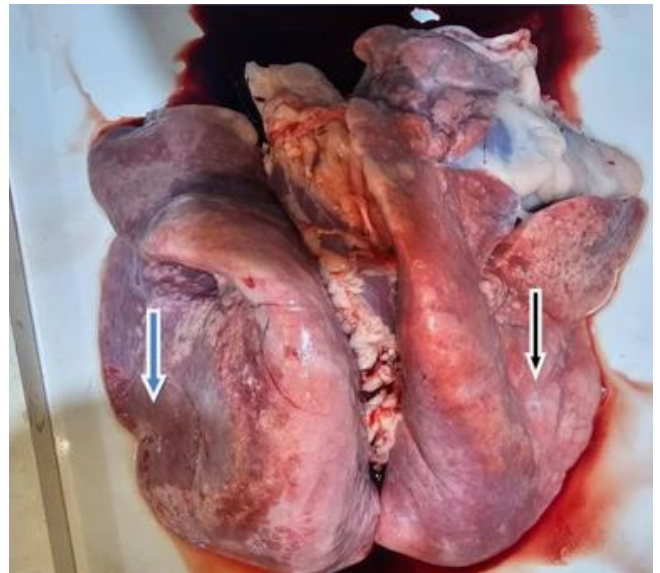

Figure 2: The gross appearance of the lung shows progressive pneumonia, The affected lung is enlarged and has variable modular sizes with whitish nodules on the parietal surface, in addition, the affected lung failed to collapse (black arrow), and there are diffuse hemorrhagic patches on the lung (blue arrow).

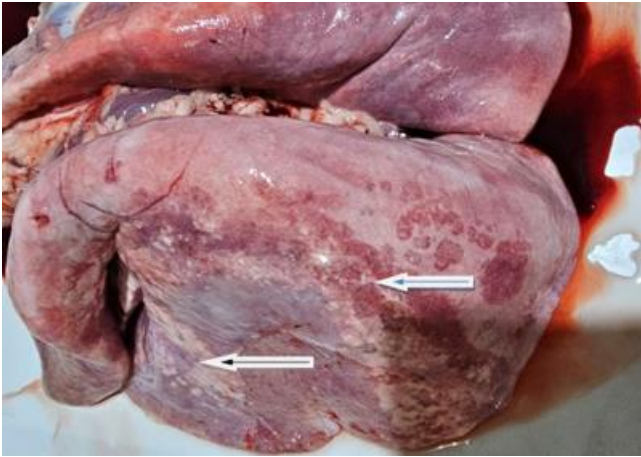

Figure 3: The gross appearance of the lung shows progressive pneumonia, The affected lung is enlarged and has variable whitish patches on the parietal surface, Moreover, the affected lung failed to collapse (black arrow); there are diffuse hemorrhagic patches on the lung (blue arrow).

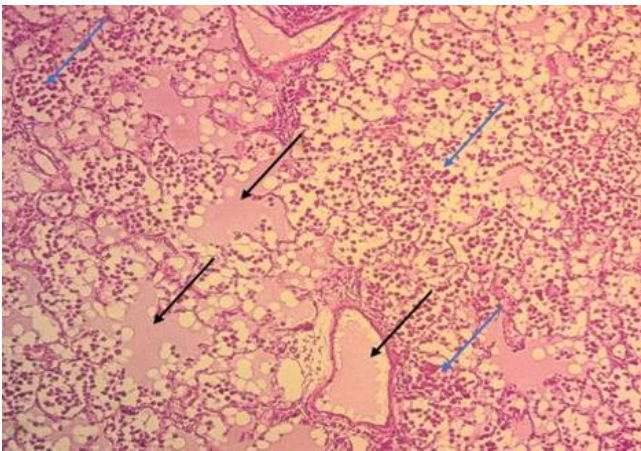


Figure 4: This histopathological micrograph of lobar pneumonia shows progressive inflammatory exudation filling the lobar alveolar spaces (black arrows), severe infiltration of inflammatory cells, and RBCs inside alveolar spaces (blue arrows). referring to the congestion stage of pneumonia. The H&E stain, is 10X.

Discussion

Scientific workers proved and indicated that ovine chronic progressive pneumonia (Maedi-visna) in sheep is caused by the Maedi-visna virus, a small lentivirus that causes a chronic type of infection and different inflammatory lesions in diseased sheep and goats. Pneumonia and mastitis are the most common clinical features. Moreover, the virus's most target tissues are pulmonary, mammary, and nervous. However, joints could also be affected (4,21,22).

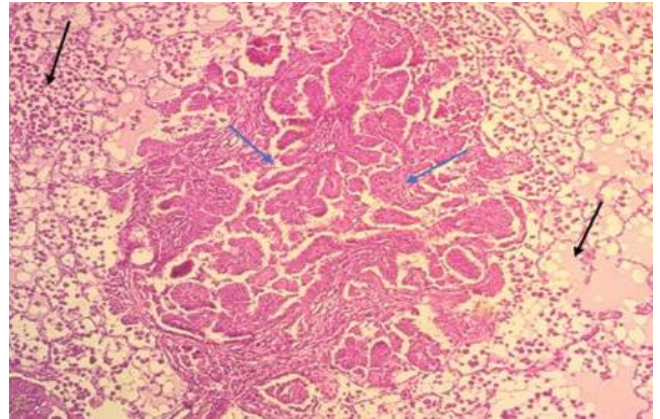


Figure 5: Histopathological micrograph of progressive inflammatory exudation filling the lobar alveolar spaces of the lung (black arrows) consists of inflammatory cell infiltration and exudation with RBCs inside the alveolar spaces, also there is a hyperplastic proliferation of bronchial epithelial lining (blue arrows). H&E stain, 40X.

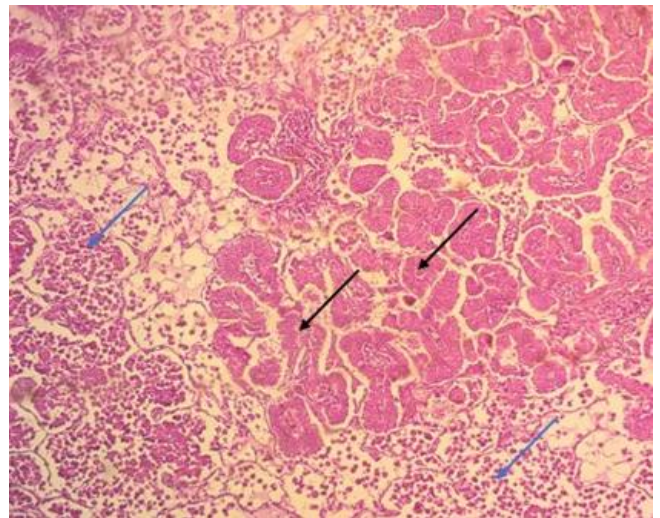


Figure 6: Histopathological micrograph of the lung shows an early fibrotic lesion referring to the stage of red hepatization of pneumonia (black arrows) as well as many inflammatory cells and RBCs infiltration in the alveolar spaces (blue arrows). H&E stain, 40X.

It was shown that the clinical appearance of Maedi-visna could depend on the virulence and strain of the causative agent, the reflected immune response of the infected host, and the susceptibility of the host, including the genetic resistance to the causative virus (23). Moreover, it was documented that, the predominance of infected cases, slow virus replication, and the considerable value of infected erythrocytes in the bloodstream are minimal (2). Hereby, Maedi-visna turns to latent form or progressive. Therefore, diseased animals could not show clear or obvious signs of

the disease, particularly at its early stages (2,24). On the other hand, any suppression of immunity due to senility (old age), the presence of concurrent diseases, and the stress of the environment might increase and enhance the replication of the virus. Therefore, clinical manifestations of the disease become more obvious and visible (25). In the current study, diseased sheep exhibited different clinical manifestations, which were also mentioned by Constable *et al.* (2), Minguijón *et al.* (3), and Gomez-Lucia *et al.* (24). Chronic respiratory manifestations are the more common clinical feature of the disease (21).

It was shown that the most important clinical manifestations resulting from Lentivirus infection in sheep and goats are progressive pneumonia, meningoencephalitis, and synovitis with obvious chronic arthritis. However, some of those manifestations could only occur in newborn animals (26,27). Moreover, Luqman and Cumali, (15) and Brinkhof *et al.* (28) documented that a high prevalence of infection was recognized in sheep showing respiratory symptoms, or what they call (breathing ewes) compared with clinically normal sheep. On the other hand, Constable *et al.* (2) and Gomez-Lucia *et al.* (24) also agreed that the first targeting of Maedi-visna virus in animals was in the respiratory system, which developed into more severe respiratory distress and was associated with a progressive wasting type, as indicated in the current study. Furthermore, Blacklaws (29) describes the relationship between respiratory and other clinical manifestations and disease seropositivity.

In the present work, the final confirmation of the diagnosis of the disease was proved by the detection of the virus antibodies in sheep serum using an indirect ELISA test, whereby it was shown that the multiplication of the Lentivirus could be detected in more restricted cells reflecting more restricted antigen productions by the immune system and then might reflect an obvious immunological reaction (13). On the other hand, it was documented that various ELISA tests can be used to confirm the causative virus antigens in diseased animals' serum. However, most of those ELISA are indirect types of ELISA. Nevertheless, a competitive ELISA test using monoclonal antibodies also showed high sensitivity and specificity for detecting of the virus antigens (24,29,30). It was also mentioned that the ELISA test was used globally to confirm the diagnosis and apply the control and eradication plans for the disease in sheep and goats (31).

Al-Baroodi *et al.* (13) and Brinkhof and Van Maanen (28) indicate that early and inevitable diagnosis of the disease is a definitive criterion for controlling and eradicating of the disease. as any control and eradication programs should be based on serological tests, mainly the ELISA test to detect the specific antibodies against the virus. At this moment, only the seropositive animals are considered infected and subsequently removed from the flock, which can be considered the main snag for eradication of the disease. Whereby the immune response of Maedi-visna

needed a longer period (14). The hematological changes in the present work indicated significant leukocytopenia, lymphocytopenia and monocytopenia, Zhang *et al.* (32) and Pérez *et al.* (33) also indicated the same results.

The most important incident that assists viral replication has yet to be fully know. However, the immune response created in the diseased animal's body reflected a chronic inflammation causing different pathological changes, including infiltration of mononuclear cells, such as lymphocytes, and macrophages, as well as the plasma cells which will be arranged into forms like the lymphoid follicles and could devastate the normal tissue structure and affected tissue functions (2,4). Moreover, increased levels of Granulocyte-macrophage colony-stimulating factor in Maedi-visna may contribute to developing of lymphoid follicles in the lungs (chronic lymphocytic interstitial pneumonia) in animals infected with Maedi-visna. However, it is unclear whether the increased expression of the Granulocyte-macrophage colony-stimulating factor in vivo is the direct consequence of the causative virus (32).

Leukocytopenia is a clear decrease in the circulating total white blood cells, which might result from depression of their production, increased utilization destruction or both (17). On the other hand, lymphocytopenia reflects a decreased number of lymphocytes in the blood, has a vital role in immune protection (18). It was documented that viral infection is mostly characterized by lymphocytopenia due to decreased re-circulation of lymphocytes from lymphoid tissues. However, stress arising from chronic diseases plays a good role too (17). Moreover, Constable *et al.* (2). added that the causative Lentivirus infects the monocytes (the macrophage lineage) and adheres to those cells by linking its glycoprotein envelope to specific receptors on the cell surface, which results in cell disintegrations and depletions that reflect monocytopenia in most diseased cases. Furthermore, the production of viral antigens attracts more monocytes.

Results also indicate a significant increase in ESR in diseased sheep than in the control group. The rate of erythrocyte sedimentation readings frequently increases in diseased animals with anemia or tissue damage compared to normal healthy sheep. Hereby, the highly elevated values of ESR found in the current study of infected sheep may reflect the obvious inflammatory reaction induced by Maedi-visna, especially in the pulmonary tissue of infected sheep. Moreover, it was also documented that, increased fibrinogen levels (hyperfibrinogenemia) when indicated in the blood will also play an important role in causing erythrocytes to clump, and the sedimentation rate will be enhanced rapidly (18,33).

In the current study, the results indicate a significant difference in the clotting factor indices induced by the Maedi-visna virus in diseased sheep, which could reflect the occurrence of a disseminated intravascular coagulation syndrome and a bleeding tendency of infected animals seen

in tissues of dead carcasses, whereby the intensity of this coagulopathy depends on the severity and duration as well as the ischemic and inflammatory problems indicated by the disease (34). It was believed that hypofibrinogenemia and decreased thrombocyte count, with less clotting time, could reflect the appearance of hemorrhagic patches indicated on different body tissues, especially on the lungs, which may be explained by the release of some endogenous mediators such as platelet-activating factor reflected by the inflammatory disorders (35).

Most scientific reports on Maedi-visna refer to different macro and microscopic pathological changes detected in dead animals, which is also indicated by the current study, where they believe that lesions in different tissues always arise from various immune reflexes induced via the antigen (Maedi-visna virus) as well as the replication of the virus itself (2). Although it was mentioned, most tissues could be affected by the causative virus, including lung, mammary, and nervous tissues. Nonetheless, the current study indicated that the lesions in both lungs of dead sheep were affected by the disease (26).

Luján *et al.* (36) mention that the primary macroscopic lesion is an enlargement of both lungs with increased weight. Furthermore, Maedi-visna could also affect regional lymph nodes (24). Moreover, chronically affected lungs will be hypertrophic. They might be up to three times their normal size, with grayish yellow, rubbery, rounded, and focal to diffuse red and/or gray spots that could be seen on the pulmonary pleural surface. Furthermore, an enlargement of mediastinal lymph nodes could also be indicated (2).

It was indicated that the histopathological changes seen in pulmonary tissues of Maedi-visna diseased sheep reflect a characteristic chronic interstitial pneumonia with the proliferation of lymphoid tissue and numerous lymphoid follicles (36). On the other hand, Constable *et al.* (2) added that any secondary microbial infections will lead to engorgement and redness of the cranioventral area, which might become moist with the marked lobular pattern. Further, it was also documented that the histopathological feature of diseased lungs indicates an increase in the thickness of the alveolar septa, resulting in a decreased air exchange capacity of affected lungs (37-40). Moreover, the intra-alveolar septa are infiltrated with a large number of monocytes, lymphocytes, and macrophages, as well as plasma cells, which enhance increased thicknesses and hyperplasia of the smooth muscle fibers of the alveolar walls reflected pulmonary dysfunction and severe respiratory distresses (2). On the other hand, red patches could indicate clotting factor disturbances enhancing the bleeding tendency process (24). Further, Luján *et al.* (36) added that diffuse lymphoid hyperplasia, detected in the histopathological view of diseased lungs might reflect and be responsible for the gray spots sometimes indicated in the pleural membrane. As the disease develops, the pulmonary lesions become fibrotic (which is indicated in the current study), reflecting an

overgrowth, hardening, and scarring due mostly to a reparative response to damage and is attributed to excess deposition of extracellular matrix components, including collagen (37-45).

Conclusions

The current study concluded that Maedi-visna considered one of the chronic progressive diseases that harm farm animals, ended mostly with high mortalities. Therefore, the haste to take preventive measures to limit its spread must always be considered.

Acknowledgments

The authors extend their thanks and gratitude to the College of Veterinary Medicine, University of Basra, Iraq.

Conflict of interest

In this article, there are no conflicts of interest.

References

1. Terrestrial Animal Health Code. 28th ed. France: World Organization for Animal Health; 2019. [\[available at\]](#)
2. Constable PD, Hinchcliff KW, Done SH, Grunberg W. Veterinary Medicine. A textbook of the Diseases of Cattle, Sheep, Goats and Horses. 11th ed. USA: WB Saunders Co.; 2017. 886 p. [\[available at\]](#)
3. Minguijón E, Reina R, Pérez M, Polledo L, Villoria M, Ramírez H, Leginagoikoa I, Badiola JJ, Garciamarín JF, De Andrés D, Luján L, Amorena B, Juste RA. Small ruminant lentivirus infections and diseases. *Vet Microbiol.* 2015;181:75-89. DOI: [10.1016/j.vetmic.2015.08.007](#)
4. Shuaib M, Green C, Rashid M, Duizer G, Whiting TL. Herd risk factors associated with seroprevalence of Maedi-Visna in the Manitoba sheep population. *Can Vet J.* 2010;51:385-390. [\[available at\]](#)
5. Reina R, Berriatua E, Luján L, Juste R, Sánchez A, de Andrés D, Amorena B. Prevention strategies against small ruminant lentiviruses: An update. *Vet J.* 2009;182(1):31-7. DOI: [10.1016/j.tvjl.2008.05.008](#)
6. Luján L, Begara I, Collie DD, Watt NJ. CD8+ lymphocytes in bronchoalveolar lavage and blood: In vivo indicators of lung pathology caused by Maedi-Visna virus. *Vet Immunol Immunopathol.* 1995;49(1-2):89-100. DOI: [10.1016/0165-2427\(95\)05460-n](#)
7. Watt NJ, King TJ, Collie D, Sargan D, McConnel I. Clinicopathological investigation of primary, uncomplicated Maedi-Visna virus infection. *Vet Rec.* 1992;131:455-61. DOI: [10.1136/vr.131.20.455](#)
8. Olech M, Valas S, Kuźmak J. Epidemiological survey in single-species flocks from Poland reveals expanded genetic and antigenic diversity of small ruminant Lentiviruses. *PLoS One.* 2018;13. DOI: [10.1371/journal.pone.0193892](#)
9. Homme LY, Leboeuf A, Arsenault J, Fras M. Identification and characterization of an emerging small ruminant Lentivirus circulating recombinant form (CRF). *Virology.* 2015;475:159-171. DOI: [10.1016/j.virol.2014.11.006](#)
10. Chakraborty S, Kumar A, Tiwari R, Rahal A, Malik Y, Dhama K, Pal A, Prasad M. Advances in diagnosis of respiratory diseases of small ruminants. *Vet Med Int.* 2014;1-16. DOI: [10.1155/2014/508304](#)
11. De Andrés X, Ramírez H, Bertolotti L, San Román B, Glaría I, Crespo H, Jáuregui P, Minguijón E, Juste R, Leginagoikoa I, Pérez M. An insight into a combination of ELISA strategies to diagnose small ruminant Lentivirus infections. *Vet Immunol Immunopathol.* 2013;152:277-288. DOI: [10.1016/j.vetimm.2012.12.017](#)

12. Deandres D, Klein D, Watt NJ, Berriatua E, Torsteinsdottir S, Blacklaws BA, Harkiss GD. Diagnostic tests for small ruminant lentiviruses. *Vet Microbiol.* 2005;107:49-62. DOI: [10.1016/j.vetmic.2005.01.012](https://doi.org/10.1016/j.vetmic.2005.01.012)
13. Al-Baroodi SY, Moosa DA, Al-Atta MY. Detection of Maedi-visna virus in sheep in Nineveh province. *Iraqi J Vet Sci.* 2022;36(1):61-64. DOI: [10.33899/ijvs.2021.129075.1622](https://doi.org/10.33899/ijvs.2021.129075.1622)
14. Glaría I, Reina R, Ramírez H, de Andrés X, Crespo H, Jauregui P, Salazar E, Luján L, Pérez MM, Benavides J, Pérez V, Polledo L, García-Marín JF, Riezu JI, Borrás F, Amorena B, de Andrés D. Visna/Maedi virus genetic characterization and serological diagnosis of infection in sheep from a neurological outbreak. *Vet Microbiol.* 2012;155(2-4):137-146. DOI: [10.1016/j.vetmic.2011.08.027](https://doi.org/10.1016/j.vetmic.2011.08.027)
15. Luqman AH, Cumali O. Serological investigation of Maedi-Visna in sheep with chronic respiratory disease in Erbil, Iraq. *Ataturk Univ Vet Bil Derg.* 2017;12(3):227-234. DOI: [10.17094/ataunivbd.295120](https://doi.org/10.17094/ataunivbd.295120)
16. Herrmann LM, William PC, Katherine LM, Travis CM, Melinda MH, Gregory SL, Donald PK. Detection of serum antibodies to ovine progressive pneumonia virus in sheep by using a caprine arthritis-encephalitis virus competitive-inhibition enzyme-linked immunosorbent assay. *Clin Diagn Lab Immunol.* 2003;10(5):862-865. DOI: [10.1128/CDLI.10.5.3](https://doi.org/10.1128/CDLI.10.5.3)
17. Harvey JW. *Veterinary Hematology: A diagnostic guide And Color Atlas.* USA: Elsevier Inc.; 2012. 77-112 p. [\[available at\]](#)
18. Weiss DJ, Wardrop KJ. *Schalm's veterinary hematology.* USA: John Wiley & Sons; 2011. 233-245 p. [\[available at\]](#)
19. Maxie G. *Jubb, Kennedy & Palmer's pathology of domestic animals: volume 3.* USA: Elsevier health sciences; 2016. [\[available at\]](#)
20. Leech N, Barrett K, Morgan GA. *SPSS for intermediate statistics: Use and interpretation:* USA: Routledge; 2013. 54 p. [\[available at\]](#)
21. Leymaster KA, Chitko-McKown CG, Clawson ML, Harhay GP, Heaton MP. Effects of TMEM154 haplotypes 1 and 3 on susceptibility to ovine progressive pneumonia virus following natural exposure in sheep. *J Anim Sci.* 2013;91:5114-5121. DOI: [10.2527/jas.2013-6663](https://doi.org/10.2527/jas.2013-6663)
22. Polledo L, González J, Fernández C, Miguélez J, Martínez-Fernández B, Morales S, Ferreras MC, García Marín JF. Simple control strategy to reduce the level of Maedi-Visna infection in sheep flocks with high prevalence values (>90%). *Small Rumin Res.* 2013;112:224-229. DOI: [10.1016/j.smallrumres.2012.12.010](https://doi.org/10.1016/j.smallrumres.2012.12.010)
23. Aphrodite IK, Ioannis B, Loukia VK, Athanasios IG. Etiology, epizootiology and control of Maedi-Visna in dairy sheep: A review. *Animals.* 2020;10(4):61. DOI: [10.3390/ani10040616](https://doi.org/10.3390/ani10040616)
24. Gomez-Lucia E, Barquero N, Domenech A. Maedi-Visna virus: Current perspectives. *Vet Med Res Rep.* 2018;21(9):11-21. DOI: [10.2147/VMRR.S136705](https://doi.org/10.2147/VMRR.S136705)
25. Straub OC. Maedi-Visna virus infection in sheep. History and present knowledge. *Comp Immunol Microbiol Infect Dis.* 2004;27:1-5. DOI: [10.1016/S0147-9571\(02\)00078-4](https://doi.org/10.1016/S0147-9571(02)00078-4)
26. Gayo E, Polledo L, Balseiro A, Martinez CP, Garcia Iglesias MJ, Prezioso S, Rossi G, García Marín JF. Inflammatory lesion patterns in target organs of Visna/Maedi in sheep and their significance in the pathogenesis and diagnosis of the infection. *J Comp Pathol.* 2018;159:49-56. DOI: [10.1016/j.jcpa.2018.01.001](https://doi.org/10.1016/j.jcpa.2018.01.001)
27. Larruskain A, Jugo BM. Retroviral infections in sheep and goats: Small ruminant Lentiviruses and host interaction. *Viruses.* 2013;5:2043-2061. DOI: [10.3390/v5082043](https://doi.org/10.3390/v5082043)
28. Brinkhof J, Van Maanen C. Evaluation of five enzyme-linked immunosorbent assays and an agar gel immunodiffusion test for detection of antibodies to small ruminant Lentiviruses. *Clin Vacc Immunol* 2007;14(9):1210-1214. DOI: [10.1128/CVI.00282-06](https://doi.org/10.1128/CVI.00282-06)
29. Blacklaws BA. Small ruminant Lentiviruses: Immunopathogenesis of Visna-Maedi and caprine arthritis and encephalitis virus. *Comp Immunol Microbiol Infect Dis.* 2012;35(3):259-269. DOI: [10.1016/j.cimid.2011.12.003](https://doi.org/10.1016/j.cimid.2011.12.003)
30. Herrmann LM, Cheevers WP, Mcguire TC, Adams DS, Hutton MM, Gavin WG, Knowles DA. A Competitive-inhibition enzyme-linked immunosorbent assay (Celisa) for detection of serum antibodies to caprine arthritis-encephalitis virus (Caev): A diagnostic tool for successful eradication. *Clin Diagn Lab Immunol.* 2003;10:267-271. DOI: [10.1128/cdli.10.2.267-271.2003](https://doi.org/10.1128/cdli.10.2.267-271.2003)
31. Alshammary HK, Mirhish SM. Morphological study of laying and non-laying female genital system in peacock (*Pavo cristatus*). *Iraqi J Vet Sci.* 2024;38(1):45-53. DOI: [10.33899/ijvs.2023.134898.2466](https://doi.org/10.33899/ijvs.2023.134898.2466)
32. Zhang Z, Harkiss GD, Hopkins J, Woodall C J. Granulocyte macrophage colony-stimulating factor is elevated in alveolar macrophages from sheep naturally infected with Maedi-Visna virus and stimulates Maedi-Visna virus replication in macrophages in vitro. *Clin Exp Immunol.* 2002;129:240-246. DOI: [10.1046/j.1365-2249.2002.01826.x](https://doi.org/10.1046/j.1365-2249.2002.01826.x)
33. Pérez M, Biescas E, Reina R, Glaría I, Marín B, Marquina A, Salazar E, Álvarez N, de Andrés D, Fantova E, Badiola JJ, Amorena B, Luján L. Small ruminant Lentivirus-induced arthritis: Clinicopathologic findings in sheep infected by a highly replicative SRLV B2 genotype. *Vet Pathol.* 2015;52(1):132-139. DOI: [10.1177/0300985813519654](https://doi.org/10.1177/0300985813519654)
34. Bick RL. Disseminated intravascular coagulation: Current concepts of etiology, pathophysiology, diagnosis and treatment. *Hematol Oncol Clin N Am.* 2003;17:149. DOI: [10.1016/S0889-8588\(02\)00102-8](https://doi.org/10.1016/S0889-8588(02)00102-8)
35. Duval C, Ariëns RA. Fibrinogen splice variation and cross-linking: Effects on fibrin structure/function and role of fibrinogen γ' as thrombomodulin II. *Matrix Biol.* 2017;60:8-15. DOI: [10.1016/j.matbio.2016.09.010](https://doi.org/10.1016/j.matbio.2016.09.010)
36. Luján L, García Marín JF, Fernández de Luco D, Vargas A, Badiola JJ. Pathological changes in the lungs and mammary glands of sheep and their relationship with Maedi-Visna infection. *Vet Rec.* 1991;129(3):51-54. DOI: [10.1136/vr.129.3.51](https://doi.org/10.1136/vr.129.3.51)
37. Michel P, Christian V, Pierre R, Jean-François M, Ernst P. Maedi-visna virus infection in sheep: A review. *Vet Res.* 1998;29(3-4):341-367. [\[available at\]](#)
38. Abawy NA, ALzubaidy MH. Evaluating the toxic oral doses of iron oxide nanoparticles in mice. *Iraqi J Vet Sci.* 2023;37(4):801-11. DOI: [10.33899/ijvs.2023.138368.2796](https://doi.org/10.33899/ijvs.2023.138368.2796)
39. Ahmed JA, Al-Autaish HH, AlSaad KM. Acute enzootic muscular dystrophy of adult lambs at Basrah, Iraq. *Iraqi J Vet Sci.* 2022;36(2):471-7. DOI: [10.33899/ijvs.2021.130539](https://doi.org/10.33899/ijvs.2021.130539)
40. Muhammad RS, Azi DM. Estimation of gestational age in Shami goats based on transabdominal ultrasonographic measurements of fetal parameters. *Iraqi J Vet Sci.* 2022;36(4):839-846. DOI: [10.33899/ijvs.2022.131845.2011](https://doi.org/10.33899/ijvs.2022.131845.2011)
41. Alnakeeb AS, Alsarhan QT. Detection of *Anaplasma phagocytophilum* in cows in Mosul City, Iraq. *Iraqi J Vet Sci.* 2024;38(1):89-95. DOI: [10.33899/ijvs.2023.140648.3074](https://doi.org/10.33899/ijvs.2023.140648.3074)
42. Rasheed BY, Hamad MA, Isihak FA. Molecular study of resistance genes in *Escherichia coli* isolated from chronic respiratory disease cases in broilers. *Iraqi J Vet Sci.* 2024;38(1):119-24. DOI: [10.33899/ijvs.2023.139069.2873](https://doi.org/10.33899/ijvs.2023.139069.2873)
43. Abobatta W, Ismaiel H, Mohamed S. Influence of nano silicon and seaweed extract applications on growth and fruiting of young lime trees (*Citrus aurantifolia* Swingle) under sandy soil conditions. *Mesopotamia J Agric.* 2024;52(1):1-0. DOI: [10.33899/mja.2024.146188.1351](https://doi.org/10.33899/mja.2024.146188.1351)
44. Fikratzade F, Khalilov H, Huseyn R. Analyzing the affordable dimensions for restricting the division of agricultural land: The case of Azerbaijan. *Mesopotamia J Agric.* 2024;52(1):17-32. DOI: [10.33899/mja.2024.145881.1343](https://doi.org/10.33899/mja.2024.145881.1343)
45. Abbi AS. Impact of zinc supplementation on nutrients digestibility and blood minerals concentration during hot season of local growing lambs. *Mesopotamia J Agric.* 2024;52(1):79-0. DOI: [10.33899/mja.2024.145475.1326](https://doi.org/10.33899/mja.2024.145475.1326)
46. Abdulqader S. Effect of different types of fertilizers on the growth and productivity of olive trees (*Olea europaea* L.) cv. Arbequina. *Mesopotamia J Agric.* 2024;52(1):151-0. DOI: [10.33899/mja.2024.145274.1314](https://doi.org/10.33899/mja.2024.145274.1314)

مجموعه ٢٥ عينة من سلالات محلية سليمة سريريًا كمجموعة سيطرة. أظهرت ٨٨ من الأغنام نتيجة إيجابية للغلوبولين المناعي النوعي للفيروس الخاص بالمرض بمعدل إصابة ٦٥,١٨% وما تم تأكيده بواسطة اختبار الاليزا. أشار تحليل الدم إلى وجود زيادة معنوية في سرعة تنقل كريات الدم الحمر مع قلة في أعداد خلايا الدم أبيض وقلة الخلايا الليمفاوية وتناقص الخلايا وحيدة النواة مع وجود اختلافات معنوية واضحة في مؤشرات عوامل تخثر الدم. أظهرت نتائج التشريح المرضي لأربعون من الحيوانات النافقة علامات الالتهاب الرئوي التدريجي مع تضخم وثلث الرئة وآفات نزفيه غير مكتملة على الرئتين. وأظهرت الرئتان المصابة عقيدات وبقع بيضاء متغيرة على السطح الجداري فضلا عن فشل الرئة المصابة، في حين اظهر الفحص النسيجي أن الالتهاب الرئوي الفصي تكون من نضح التهابي تقدمي ملء الفراغات السنخية الفصية مع ارتشاح شديد للخلايا الالتهابية وكريات الدم الحمراء داخل الفراغات السنخية. النضح الالتهابي التدريجي تكون من ارتشاح الخلايا الالتهابية ونضحها بكريات الدم الحمراء داخل الفراغات السنخية، كما تمت الإشارة أيضًا إلى تكاثر مفرط للتنسج في البطانة الظهارية القصبية. علاوة على ذلك، تشير آفة التليف المبكرة إلى مرحلة التكبد الرئوي الأحمر للالتهاب الرئوي إلى جانب العديد من الخلايا الالتهابية، كما تم التعرف على ارتشاح كريات الدم الحمراء في الفراغات السنخية.

دراسة سريرية وتشخيصية للالتهاب الرئوي المزمن التقدمي (ميدي - فيزنا) في أغنام محافظة البصرة، العراق

كمال الدين مهلهل السعد^١، علي جراد لفته^١، مهند حسن لفته^١ و
جهاد عبد الأمير احمد^٢

^١ فرع الطب الباطني والوقائي، فرع الأمراض وأمراض الدواجن، كلية
الطب البيطري، جامعة البصرة، البصرة، العراق

الخلاصة

شخص الالتهاب الرئوي المزمن التقدمي في أغنام محافظة البصرة
العراق. أذ جمعت ١٣٥ عينة دم من أغنام محلية بأعمار تراوحت بين
(٣-٥ سنوات) ومن كلا الجنسين، تم تربيتها في محافظة البصرة،
العراق. أظهرت الحيوانات المشتبه بها علامات الالتهاب الرئوي المزمن
وفقدان الشهية وفقدان الوزن التدريجي والسعال المزمن. تم استخدام