

## **Histopathological study and molecular characterization of Infectious Bronchitis virus circulating in broilers in Basrah governorate, Iraq**

**N. H. Megdad, W. M. Seger\* and Y. J. Mohammed**

*Department of Pathology and Poultry Disease, Faculty of Veterinary Medicine,  
University of Basrah, Basrah, Iraq*

*\*Corresponding e-mail: waleed.seger@uobasrah.edu.iq*

*Received August 02, 2023; Accepted October 23, 2023*

### **ABSTRACT**

The poultry industry plays an important role in the food economics and the food industry in both their layer and broiler chicken. Poultry diseases on the other way impact in the poultry industry especially diseases from virus sources since it does not have a specific treatment except for vaccines with routine prevention and control. This study was designed for the assessment of histopathological changes, molecular diagnosis and phylogenetic analyses of the Infectious Bronchitis virus circulating in broilers in Basrah province in the south of Iraq. The tissue samples were (trachea, lung and kidney). One hundred samples were studied with clinical signs and lesions related to IB. The histopathological changes caused by the virus were studied with hematoxylin and eosin stain, and the causative agent Infectious Bronchitis Virus (IBV) was identified using a polymerase chain reaction combined with explaining the phylogenetic analysis. The results of molecular diagnosis and identification showed the twelve Iraqi field strains of IBV were closely related and shared a high identity of 98.44 %- 99.69 % of each other. Variant 2(IS/1494 like) was a predominant genotype of IBV in the present study, and has high similarity with the variant 2(IS/1494) like a strain of IBV circulating in Iran and in the Kurdistan region north of Iraq. The histopathological findings were desquamation of the cilia of the mucosa layer of the trachea, infiltration of inflammatory cells, hyperplasia of goblet cells with thickening of mucosal layer in some areas infiltration of inflammatory exudate within capillaries and Para bronchus, where the microscopic results in kidney were showed interstitial hemorrhage, necrosis of the renal tubular epithelium, infiltration of inflammatory cell. The present results provided useful information on target organs damaged by IBV and the genetic epidemiology of such virus strains circulating in Basrah governorate Iraq during this year that would be helpful to develop a local vaccine.

*Keywords: Broilers, IBV, Histopathological changes, Polymerase chain reaction, Phylogenetic analysis*

## INTRODUCTION

The Infectious Bronchitis Virus (IBV) is a severe, contagious respiratory disease caused by IBV virus that affects chickens (de Wit *et al.*, 2011). The extremely contagious respiratory disease Avian (IBV), is a member of the Coronaviridae family and order Nidovirales, affects chickens. It can also occasionally affect their urogenital system IBV is a serious poultry virus that is prevalent around the world and causes substantial financial losses (Feng *et al.*, 2012). Due to its wide genetic variety, rapid generation, and high mutation rate, the infectious bronchitis virus is both very contagious and highly challenging to treat (Khataby *et al.*, 2016). The disease affects both commercial broilers and layer chickens and is present everywhere in the world, having significant negative economic effects. All bird ages are vulnerable to infectious bronchitis, which results in respiratory symptoms, nephritis, proventriculitis, and a decrease in the quality and quantity of eggs (Cavanagh, 2007; Han *et al.*, 2011).

The IB can frequently become worse by further bacterial infections that increase mortality rates, making it the most economically significant respiratory viral disease in birds in areas where avian influenza and velogenic Newcastle disease are not highly pathogenic (Cavanagh, 2005). Watery eyes, tracheal rales, coughing, sneezing, thicker nasal and tracheal mucosa, are some of the clinical symptoms of IBV-induced respiratory diseases in broilers. The most observable symptoms are those which affect the respiratory tract, for this reason the term 'infectious bronchitis'. The severity of the clinical sign is influenced by several factors associated with the IB field virus (such as strain, virulence and dosage), host (age, sex, type and immune status), environment (dust, ammonia and stress) and management and biosecurity (Ganapathy, 2009). The other forms of the disease are mainly associated with the reproductive, renal and gastrointestinal systems. can have many different clinical manifestations in susceptible layers, such as decreased egg production, damaged eggshells,

and poor internal quality of eggs (Chousalkar and Roberts, 2009). Several abnormalities, such as a shortening of the oviduct, a reduction in the number of ovarian hierarchical follicles, and yolk peritonitis, can be found in the female reproductive system (Hong *et al.*, 2012). Although inactivated and live attenuated vaccinations are now used to prevent IB with (H120 and 4/91 strains) in the Iraq's broiler farms, outbreaks of the disease have nonetheless been documented there (Seger *et al.*, 2016). As a result, the most prevalent problem in Iraqi commercial broiler flocks is the spread of viral respiratory infections in poultry.

In this work, IBV-related histopathological alterations and molecular detection and identification of IBV strains from broiler farms in the southern portion of Iraq were conducted based on part of the S1 sequence. According to Khataby *et al.* (2016), infectious bronchitis has a widespread geographic distribution and has been reported in areas of Africa, Asia, Australia, Europe, and the United States. IBV genotypes come in a variety of classic and variant forms that are widely used (de Wit *et al.*, 2011). The vaccination strains and some IBV genotypes and serotypes are closely related whilst other variants are localized to a specific region (Bande *et al.*, 2017). IBV is RNA's positive-sense single-stranded strand that makes up the viral genome and is encased in an envelope that measures around 27.5–28 kb in length. Spike (S), envelope (E), membrane (M), and nucleocapsid (N) proteins make up virions, which are made up of four essential structural proteins (Cavanagh D. 2005).

In terms of both antigenic and immunogenic factors, the S protein is the most important of the group. The two S1 and S2 subunits, which have roughly 520 and 625 amino acids, respectively, make up the trimerized S protein. Variant serotypes linked to disease outbreaks are produced as a result of changes to the S1 subunit in chicken, which is connected to virus attachment to host cells and a major inducer of neutralizing antibodies (Jackwood *et al.*, 2003). Understanding the various IBV serotypes and using vaccinations against those particular serotypes are crucial for managing IBV in chickens because there are nu-

merous different serotypes of BV worldwide. IBV strains have been divided into categories using serological and genetic typing techniques. Cross-protection and the degree of similarity among the S1 gene sequences are correlated (De Wit *et al.*, 2011). The isolated strain of IBV is 98% homologous to an Israeli strain (Israel variation 2, IS 1494), although it differs from other strains, particularly the one found in northern Iraq (the Sulemania Strain) (Alhatami *et al.*, 2020). Another study related to IBV circulating strains in Iraq ;who explained The thirty-two IBV-positive samples out of the total were picked, and nested PCR was performed to further characterize them. Using phylogenetic analysis, four groups of isolates (group I, variant 2 [IS/1494-like], group II, 793/B-like, group III, QX-like, and group IV, DY12-2-like) were discovered (Seger *et al.*, 2016).

The present study was purposed to clarify histopathological study and molecular characterization of Infectious Bronchitis virus circulating in broilers in Basrah governorate, Iraq.

## MATERIALS AND METHODS

### Sampling

In the present study, one hundred tissue samples (trachea, lung and kidney tissue) were taken from ten broiler chicken farms located in Al-Qurna, Karmat Ali and Al-Faw areas in Basrah Governorate / southern Iraq, where the ages of the birds ranged from 17 to 28 days, and the capacity of the broiler farms ranged from 5,000 to 9,000 broiler chicks. Suffer from respiratory signs including gasping, sneezing and rales. The samples (trachea, lung and kidney) were taken from a chicken broiler for gross study. Samples were also taken for purpose of histopathological study by placing them a formalin concentration of 10% and then making a histopathological section (Mohammed and Yousif, 2022). As well as trachea, lung and kidney samples were frozen at (-20°C) for molecular examination.

### Molecular procedure

#### Extraction of RNA and synthesis of cDNA

Extraction of the RNA was done by the manufacturer's instructions. (SV Total RNA Isolation System (Promega, USA). and maintained at (-80°C) until cDNA synthesis.

#### Synthesis of cDNA

For this step, cDNA Synthesis Kit (GoScript™ Reverse Transcription System kit (Promega, USA)) with random primers was used. cDNA was synthesized and stored at a temperature of (-20°C).

#### PCR reaction

A set of IBV, S1-specific primers, XCE1 and XCE2 (5'-CACTGGTAATTTTTCAGATGG-3' and 5'-CTCTATAAACACCCTTACA-3') (Ghorbani *et al.*, 2020) were used to achieve the process. The reaction components were mixed: 12.5µl of Master Mix 2x, 2.5 µl of primer XCE1 (10 µM), 2.5 µl of primer XCE2 (10 µM), 5µl of DNA template and, 3.5µl of nuclease-free water in the final volume of 25µl (Promega, USA), then 35 cycles were carried out in a thermocycler at 94 °C for 5 min: 30 s at 94 °C (Denaturation), 30 s at 55 °C (Annealing), and 35 s at 72 °C (Extension). Final Elongation was done for 4 minutes at 72 °C. Finally, on a 2% agarose gel, PCR products were electrophoresed at 100 volts and observed with UV (Ultra Violet) light after staining. PCR products were sent to South Korea for sequencing done by the (Macrogen Korea).

#### Sequence analysis

The HVR (Hypervariable region) of S1 gene sequences of the field strains used in the present investigation. PCR products were sent to Macrogen company (South Korea) for sequencing with the illumina method; with XCE1 and XCE2 (5'-CACTGGTAATTTTTCAGATGG-3' and 5'-CTCTATAAACACCCTTACA-3') primers and compared with IBV reference strains that have been previously described at (NCBI) as shown in table (3). A phylogenetic tree of the nucleotide sequences was created using MEGA7 (Kumar *et al.*, 2016).

### Histopathological procedure

The collected tissue samples infected with IBV were fixed in 10% natural buffered formalin. The tissue samples were then processed through the routine tissue fixation procedure, and with hematoxylin and Eosin as the (Ahmed, 2016) protocol. Trachea, kidney, and lung samples were taken using sterilized forceps, scissors, and fixatives in 10% formalin; following that, standard procedures for histological identification were carried out on tissues from infected broilers. The slides were created and examined in the pathology department of the Faculty of Veterinary Medicine, University of Basrah, South Iraq according to Luna (1968), the optical microscope Olympus was used to determine the histological properties of tissues using colored slides of hematoxylin and eosin (HE).

## RESULTS

### Molecular Investigation

In this part, the studied samples of infected broiler chicken tissue (trachea, lung, kidney) were subjected to the PCR technique to confirm the presence of IBV. The size of the PCR product was 464bp that targeted the S1 gene's hyper-variable region 3 (HVR3), which is located between nucleotide positions 671 and 1135. PCR amplification of the S1 gene showed that there are twelve IBV positive samples as shown in Figure 1 which were chosen for further sequence analysis. All twelve positive samples of the present study are (IBV/Iraq/YWN01) as shown in Table 1.

### Phylogenetic Analysis

The phylogenetic tree revealed that every isolate under our investigation was IBV (variant 2 (IS-1494) like as shown in Figure 2. Variant 2 (IS/1494) likestrains were a predominant genotype of IBV in the current study. Whereas, IBV/Iraq/YWN01 and other strains of the present study have a close relationship with the Iraqi strain (gCoV/Ck/IRQ/AC-28569/01/2022) and that of Iran IBV/Chicken/Iran/IS1494-like/MRB02/2016

### Post Mortem Examination Results

Post-mortem examination results of the trachea of an infected bird with IBV showed there is a yellow caseous plug (abscess filling the trachea) along the trachea (A), severe congestion and hemorrhage at the tracheal mucosa (B) and the lung (C), The examination of the kidney of the bird infected with IBV showed irregular kidney shape lobes, swollen of the kidney, and severe congestion and hemorrhage (D), as shown in Figure 3.

### Histopathological Examination Results

Current study results showed various microscopic changes in the trachea, lungs and kidneys. The results of histopathological examination of non-infected cases showed the normal structure of the chicken trachea manifested by normal histological structure (A), the histopathological change in the trachea of infected cases include loss of the cilia of the epithelia of the trachea, infiltration of inflammatory cells (B), also to present of hyperplasia of goblet cells and thickening of the tracheal mucosa (C) and (D) as shown in Figure 4. Also, the normal structure of the lung tissue histological section is seen (A), while the histopathological change in the lung involves the presence of a thrombus was fills the blood vessels as shown in figure (B), inflammatory exudate within air capillaries and parabronchus and infiltration of inflammatory cells as (C) shown in Figure 5. The normal histological section of the kidney tissue of the group control is shown in the figure (A), also there is various change that was noted in the kidney tissue, including the presence of hyperplasia of the renal glomerulus, necrosis of renal tubular epithelium and aggregation of inflammatory cells (B), and present of interstitial hemorrhage (C) as shown in Figure 6.

## DISCUSSION

IBV referred to as the avian infectious bronchitis virus, is one of the most dangerous viral infections which could infect chickens. This virus is a problem for the chicken industry in many regions of the world (Flageul *et al.*, 2022; Ulai-

Table1. Results of analysis of the sequences

No.	Strain	Identity	Gene
1	IBV/Iraq/YWN01		Spike (S1) gene
2	IBV/Iraq/YWN02		Spike (S1) gene
3	IBV/Iraq/YWN03		Spike (S1) gene
4	IBV/Iraq/YWN04		Spike (S1) gene
5	IBV/Iraq/YWN05		Spike (S1) gene
6	IBV/Iraq/YWN06		Spike (S1) gene
7	IBV/Iraq/YWN08	Avian coronavirus	Spike (S1) gene
8	IBV/Iraq/YWN09		Spike (S1) gene
9	IBV/Iraq/YWN13		Spike (S1) gene
10	IBV/Iraq/YWN14		Spike (S1) gene
11	IBV/Iraq/YWN15		Spike (S1) gene
12	IBV/Iraq/YWN18		Spike (S1) gene

Table 2. Comparison between the identity of strain IBV/Iraq/YWN01 against other strains

Strain	IBV/Iraq/YWN01	
	Sequence cover	Identity (%)
IBV/Iraq/YWN09	100%	99.69
IBV/Iraq/YWN05	100%	99.69
IBV/Iraq/YWN04	100%	99.69
IBV/Iraq/YWN03	100%	99.69
IBV/Iraq/YWN06	100%	99.38
IBV/Iraq/YWN02	100%	99.38
IBV/Iraq/YWN18	100%	98.44
IBV/Iraq/YWN15	100%	98.44
IBV/Iraq/YWN14	100%	98.44
IBV/Iraq/YWN13	100%	98.44
IBV/Iraq/YWN08	100%	98.44

wi, 2019). The virus affects the respiratory, reproductive and renal systems, which causes the chicken business to suffer huge financial losses. The disease still exists despite many years of diligent research, support for farm biosecurity, availability of several attenuated live and inactivated vaccines, and widespread chicken immunization. The main reason for this is the extraordinary variability of the virus, which is due to its membership in the Coronaviridae family, which allows it to exist in various genetic and serological forms (De Wit *et al.*, 2011).

The molecular side of the current study was achieved to confirm the presence of IBV where

the detection of such viruses in tissue samples was by qPCR that showed 12 positive samples using S1 gene-specific primers with 464 bp ; these results were consistent with Ghorbani *et al.* (2020), who detect IBV with same primers in broiler flock in Iran. Recombination, deletion, or insertion of RNA segments by the IB virus and poor management techniques and biosecurity in many of the chicken farms in Iraq cause recombinants, variations, and re-emerging IB strains (Hosseini *et al.*, 2015; Najafi *et al.*, 2016). The significant single-stranded RNA found in the coronaviruses' genomic structure, virus biology (the viral polymerase's error-prone




Figure 1. S1 gene amplification, product size 464bp, line 1 (DNA ladder), line 2 Nc (Negative control), line 3 Pc (Positive control), lines (4-15) IBV infected positive samples.

Table 3. Comparison between the identity of strain IBV/Iraq/YWN01 against strains registered in the NCBI database

Strains	Sequence Cover	Identity (%)	Accession number
Infectious bronchitis virus isolate IBV/Chicken/Iran/IS1494-like/MRB02/2016	100%	98.75	<a href="#">MG013973.1</a>
Infectious bronchitis virus isolate IBV/Chicken/Iran/IS1494-like/MRB01/2016	100%	98.75	<a href="#">MG013972.1</a>
Avian coronavirus strain IBV/chicken/Markazi/RIBV-3/2019	100%	98.75	<a href="#">OK626292.1</a>
Avian coronavirus strain IBV/chicken/Yazd/RIBV-2/2017	100%	98.75	<a href="#">OK626291.1</a>
Avian coronavirus strain IBV/chicken/Hamedan/RIBV-1/2017	100%	98.75	<a href="#">OK626290.1</a>
Infectious bronchitis virus isolate IQR10	100%	98.75	<a href="#">OL321808.1</a>
Infectious bronchitis virus isolate IQR6	100%	98.75	<a href="#">OL321804.1</a>
Infectious bronchitis virus isolate IQR2	100%	98.75	<a href="#">OL321800.1</a>
Infectious bronchitis virus isolate Iran/GI-23/Kadkan/RVSRI-370/19	99%	98.75	<a href="#">MW366343.1</a>
Infectious bronchitis virus isolate IS-1494	100%	98.44	<a href="#">MG233398.1</a>
Infectious bronchitis virus isolate IQR9	100%	98.44	<a href="#">OL321807.1</a>
Infectious bronchitis virus isolate IQR8	100%	98.44	<a href="#">OL321806.1</a>

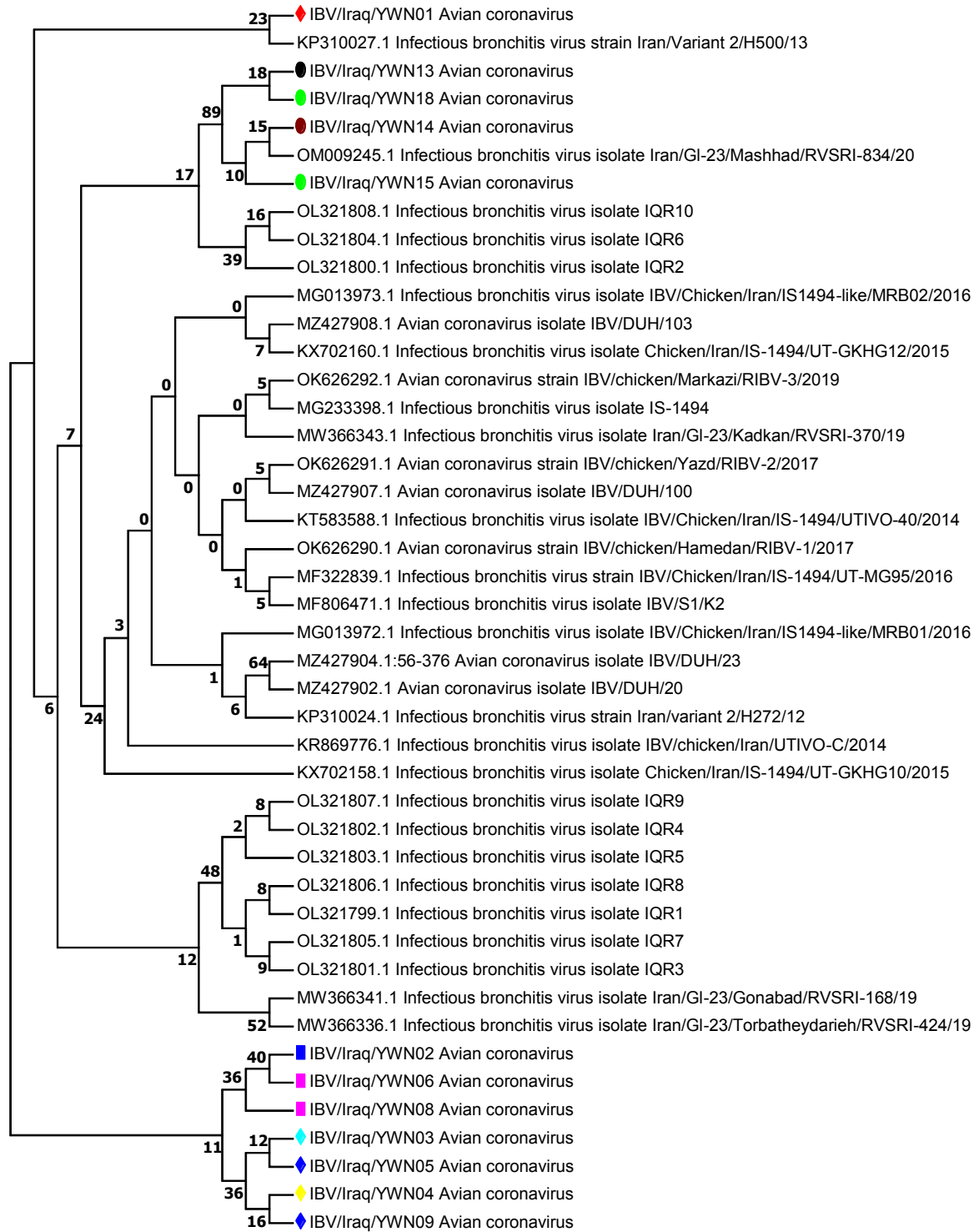


Figure 2. Molecular Phylogenetic analysis by Maximum Likelihood method for the 12 tested strains (colored figures) vs avian corona virus sequences registered in the NCBI. The evolutionary history was inferred by using the Maximum Likelihood method based on the Jukes-Cantor model (Jukes and Cantor, 1969). The tree with the highest log likelihood (-506.95) is shown. Initial tree(s) for the heuristic search were obtained automatically by applying Neighbour-Join and BioNJ algorithms to a matrix of pairwise distances estimated using the Maximum Composite Likelihood (MCL) approach, and then selecting the topology with superior log likelihood value. The tree is drawn to scale, with branch lengths measured in the number of substitutions per site. The analysis involved 12 nucleotide sequences. Codon positions included were 1st+2nd+3rd+Noncoding. All positions containing gaps and missing data were eliminated. There was a total of 321 positions in the final dataset. Evolutionary analyses were conducted in MEGA7 (Kumar *et al.*, 2016).

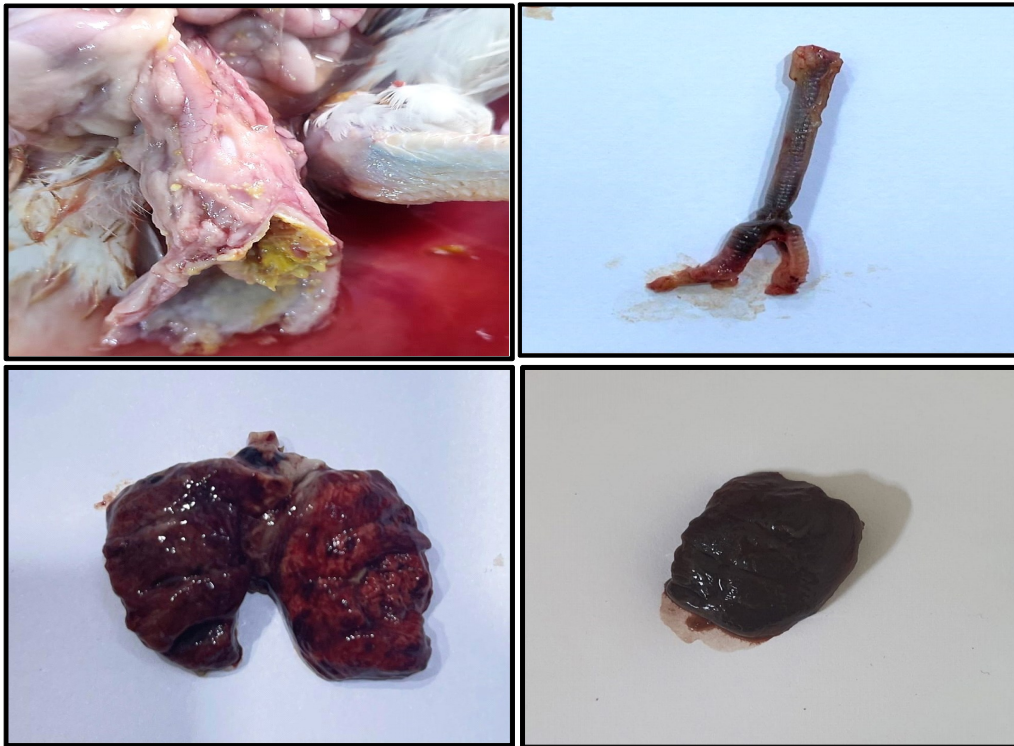

Figure 3. Gross lesion results of IBV infected chicken tissue showing; trachea showing the presence of yellow caseous plug (A), trachea showing severe congestion and hemorrhage of the tracheal mucosa(B), lung showing severe congestion and hemorrhage (C), kidney showing severe congestion, hemorrhage, swollen, and irregular shape lobes (D).

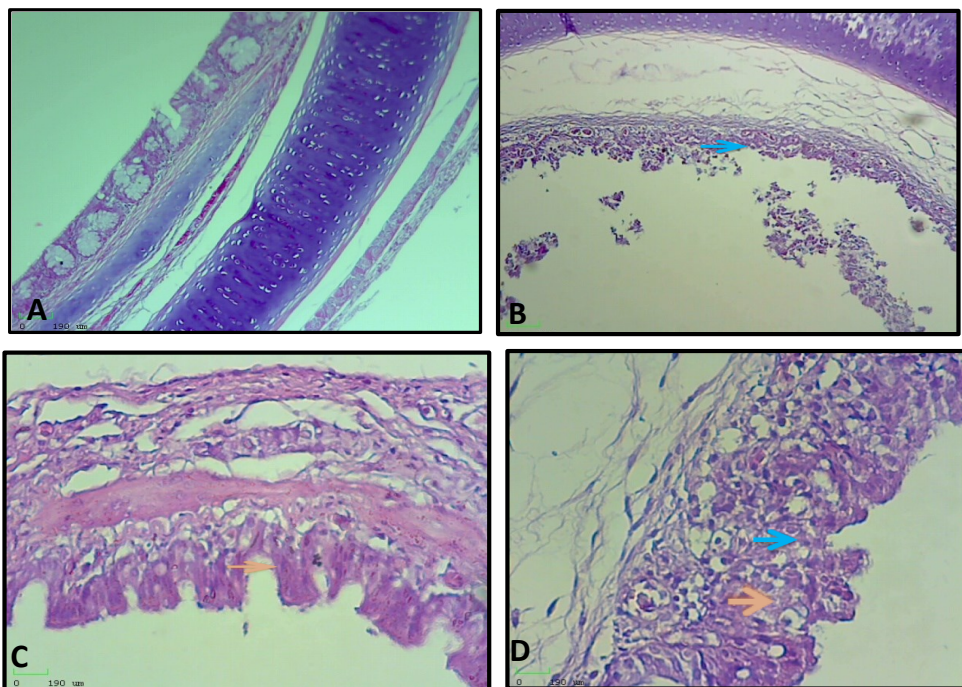


Figure 4. Histopathological section of non-infected and infected chicken trachea showing; non-infected chicken trachea (HE staining 40x) as shown in (A), infected chicken trachea with IBV showing epithelial cells loss their cilia. ( → ) HE staining 40x, as shown in (B), infected chicken trachea with IBV showing hyperplasia the goblet cells and thickening of mucosa layer. ( → ) (HE staining 100x) as shown in (C), infected chicken trachea with IBV showing hyperplasia the goblet cells ( → ) and desquamation of epithelium ( → ) (HE staining 100x), as shown in (D).



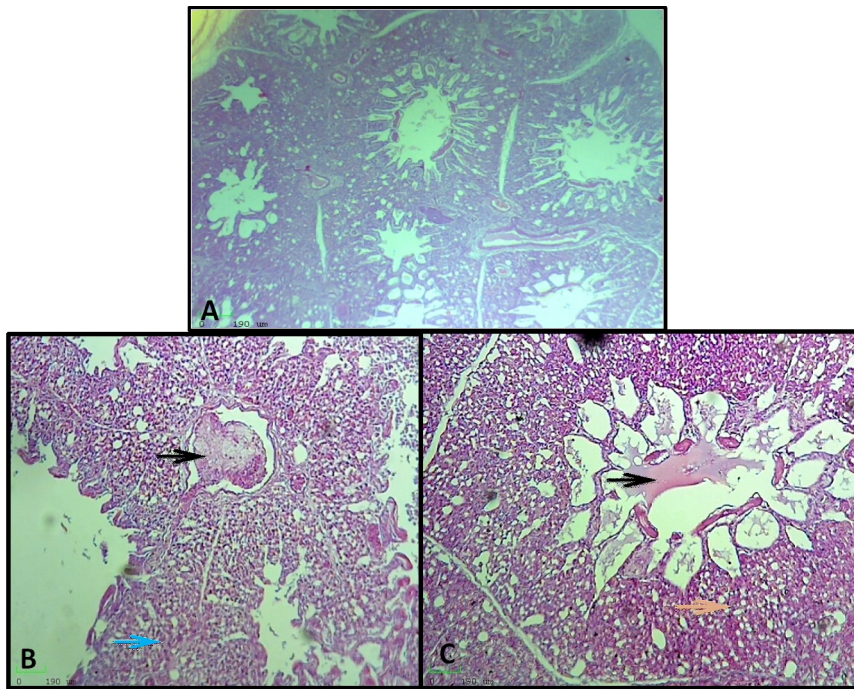


Figure 5. Histopathological section of non-infected and infected chicken lung showing; non-infected chicken lung (HE staining 100x) as shown in (A), infected chicken lung with IBV showing the presence of thrombus filled the blood vessels (●), and infiltration inflammatory exudate within air capillaries and arteria (→) (HE staining 100x) as shown in (B), infected chicken lung with IBV showing inflammatory exudate filled the parabronchus (●) and infiltration of inflammatory cell through air capillaries (→) (HE staining 400x) as shown in (C).

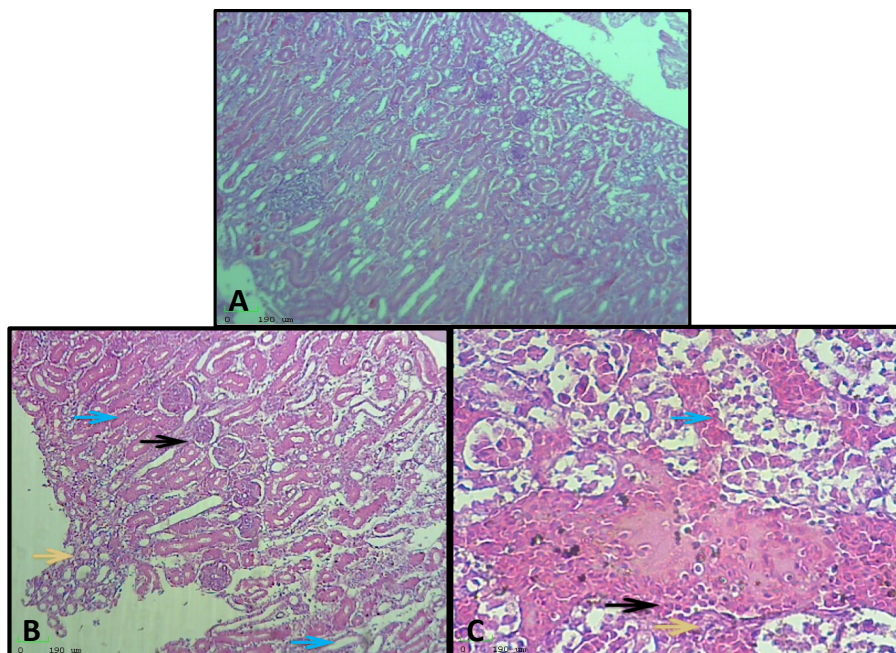


Figure 6. Histopathological section of non-infected and infected chicken kidney showing; non-infected chicken kidney (HE staining 100x) as shown in (A), infected chicken kidney with IBV showing the presence of hyperplasia of the glomerulus at the capsular region (●), necrosis of the renal tubular epithelium (→) and aggregation of inflammatory cells (→) (HE staining 100x) as shown in (B), infected chicken kidney with IBV showing the presence of interstitial hemorrhage (●), necrosis of the renal tubular epithelium (→) and aggregation of inflammatory cells (→) (HE staining 400x) as shown in (C).

proofreading activity), as well as modern practices in poultry breeding and immunological stress brought on by overuse of vaccines, are the factors that create the ideal environment for such events (Domanska-Blicharz *et al.*, 2020).

There are new genotypes or serotypes as a result of S1 gene mutations (De Wit *et al.*, 2011). The virus new classification classified 32 lineages into 6 genotypes (GI to GVI), with the GI genotype containing GI-1 to 27 lineages (Valastro *et al.*, 2016). Two further lineages (GI-28 and 29), as well as a new genotype (GVII), have been identified in China in recent years (Domanska-Blicharz *et al.*, 2020). In the current study, IBV was isolated from 12% of the 20 flocks from various regions of the province of Basrah, variant-2 like (GI-23 lineage) was the predominant strain. This result was related to Kahya *et al.* (2013) who reported the predominant kind as variant 2 (IS-1494-like viruses). Most of our positive strains in this study had over 98.99% similarity to some of Iraqi isolates like IBV/DUH/103 and gCoV/Ck/IRQ/AC-28569/01/2022 strains from Kurdistan region/Iraq and 98.75% to some of Iranian isolates like IBV/Chicken/Iran/IS1494-like/MRB02/2016 and IBV/chicken/Markazi/RIBV-3/2019. This similarity may be explained as it has been hypothesized that wild birds may be the source of introduction based on the evidence that IB viruses may replicate in members of the order Anseriformes (Pohuang *et al.*, 2009).

Another probable cause for the mode of spread of IBV between the countries in the Middle East, cross border movements of poultry (broilers) and poultry-related products are likely to be important factors geographically, the GI-23 lineage (variant 2) is unique to the Middle East, and some infected farms have respiratory and kidney distress (Valastro *et al.*, 2016). The Egypt/Beni-Suef/01 IBV which was isolated from Egypt in 2001 has 99% genetic similarity to the GI-23 lineage (Gelb Jr *et al.*, 2005). Since then, IBV like IS-1494 has been tracked in Jordan, Turkey, and other Middle Eastern countries (Franzo *et al.*, 2016). In Iran, the GI-23 lineage (variant 2) was identified for the first time in

2010 and between 2014 and 2015 it was reported that out of the eight nations, Iran had the second-highest incidence of variation 2 cases. After that Najafi *et al.* (2016) indicated that the variant-2 IBV was the most common in 2014–2015.

The predominant strains of viruses in Jordan, Egypt, Turkey, and other Middle East continued to be the variant 2 virus (Najafi *et al.*, 2016). It is likely that this variant will spread widely since Iraq does not use the variant 2 vaccination and because the available vaccinations do not completely protect against this strain Habibi *et al.*, 2017). These results were in line with Seger *et al.* (2016) that Inferred from phylogenetic research, isolates fall into four groups (group I, variant 2 IS/1494-like; group II, 793/B-like; group III, QX-like; group IV, DY12-2-like). Nucleotide sequence identities among groups I, II, and III were found to be 99.68%–100%, 99.36%–100%, and 96.42%–100%, respectively, according to sequence analyses Group I (variant2) was the dominant IBV genotype. Variant 2-like strain IS/1494 which detected in our study was characterized with respiratory and renal damages that combined with clinical signs and postmortem lesions of trachea and kidney of infected broilers; such result was related to Abdollahi *et al.* (2021).

The infectious bronchitis virus, which is ubiquitous and highly mutagenic, has a high mutation rate. It comes in a variety of genotypes or serotypes around the world. It has been proven by many nations that their flocks of chicken were carrying different IBV strains (De Wit *et al.*, 2011). Current study results revealed that trachea, lung and kidney tissue in the control group the presence of normal histological structure. The results of an infected bird with infectious bronchitis virus reflected different histopathological conditions in the trachea lung and kidney. Pathological examination of the trachea's tissue as shown in Figure 4 revealed an IBV has a remarkable impact on the mucosal layer of the trachea. These changes included desquamation of the cilia with epithelial of the mucosa layer of the trachea, mild infiltration of inflammatory cells, vacuolation of the epithelium, hyperplasia of

goblet cells and thickening of the mucosal layer in some areas. These changes could be the result of the immune system's inflammatory and cellular response to the virus infection, which is a crucial defense mechanism against IBV infection. These results agreed with (Hasan *et al.* (2020), they observed the presence of neutrophil infiltration, severe hyperplasia that causes thickening in extensive epithelial areas, and loss of epithelial cells with their cilia. As well as the result of the current study in the lung showed, the presence of thrombus filled the blood vessels, and infiltration of inflammatory exudate within capillaries and Para bronchus, these results match to El-Fetouh *et al.* (2016), they reveal the lungs had edema, hemorrhage congestion, and thickening of the interalveolar tissue, where the histopathological results in kidney were showed present of interstitial hemorrhage, necrosis of the renal tubular epithelium, infiltration of inflammatory cell, hyperplasia of glomerulus and atrophy of the renal tubules these results corresponding to results of Pourbakhsh *et al.* (2007), they observed different changes in renal tissues section. These results due to IBV predominantly affects the respiratory tract and exhibits tissue tropism in a variety of tissues, particularly the renal tissues causing nephropathogenic properties and that the local renal tissue damage following IBV infection was caused by a strong inflammatory response brought on by cytokines.

### CONCLUSION

The present study revealed the presence of clear and pathognomonic histopathological changes caused by IBV replication in target organs combined with circulation of IBV genotype variant 2(IS/1494-like, which is genetically closely related to such strains in Iran. These results provided useful information of target organs which damaged by IBV and the genetic epidemiology of such virus circulating in Basrah/south of Iraq that would be helpful to develop a local vaccine.

### ACKNOWLEDGMENTS

The author would like to acknowledge the staff members at the Department of Pathology and poultry diseases, Faculty of Veterinary Medicine, University of Basrah /Iraq

### CONFLICT OF INTEREST

We are declaring that they have no conflict of interest.

### REFERENCES

- Abdollahi,H., M. Rezaei-Tavirani, A. Ghal-yanchilangeroudi, H. Maghsoudloo, M. Hashemzadeh, H. Hosseini, and A. Barin. 2021. Coronavirus: proteomics analysis of chicken kidney tissue infected with variant 2 (IS-1494)-like avian infectious bronchitis virus. *Arch. Virol.* 166:101–113
- Ahmed, M. 2016. Steps of tissue processing in histopathology laboratory, Review Report. *Heal Dig.* 1:26–27.
- Alhatami, A. O., Alaraji, F., Abdulwahab, H. M., and Khudhair, Y. I. 2020. Sequencing and phylogenetic analysis of infectious bronchitis virus variant strain from an outbreak in egg-layer flocks in Baghdad, Iraq. *Vet. World* 13(7):1358.
- Bande, F., S. S. Arshad, A. R. Omar, M. Hair-Bejo, A. Mahmuda and V. Nair. 2017. Global distributions and strain diversity of avian infectious bronchitis virus: a review. *Anim. Health Res. Rev.* 18(1):70–83.
- Cavanagh D. 2005. Coronaviruses in poultry and other birds. *Avian Pathol*, 34(6):439–448.
- Cavanagh D. 2007. Coronavirus avian infectious bronchitis virus. *Vet. Res.*, 38(2):281–297.
- Chousalkar, K. K., and J. R. Roberts. 2009. Effects of Australian strains of infectious bronchitis virus on internal and external quality of hen eggs. *Anim. Prod. Sci.*, 49 (2):162–169.
- De Wit, J.S., J.K.A Cook, and H. van der Heijden. 2011. Infectious bronchitis virus variants: A review of the history, current situation and control measures. *Avian*

- Pathol. 40(3):223-235.
- Domanska, Blicharz, K., A. Lisowska, and J. Sajewicz-Krukowska. 2020. Molecular epidemiology of infectious bronchitis virus in Poland from 1980 to 2017. *Infect Genet Evol.* 80:104177.
- El-Fetouh A., M. H. Mohamed, N. Refat, M. Ahmed, and A. E. El-Zanaty. 2016. Pathological studies on infectious bronchitis disease in chickens. *Zagazig Vet. J.* 44(3):248–259.
- Feng J., Y. Hu, Z. Ma, Q. Yu, J. Zhao, X. Liu, and G. Zhang. 2012. Virulent avian infectious bronchitis virus, People’s Republic of China. *Emerg. Infect. Dis.* 18(12):1994.
- Flageul A., C. Allée, C. Courtillon, V. Béven, H. Quenault, Y. Blanchard, M. Amelot, D. Courtois, S. De Wit, and N. Eterradossi. 2022. Infectious bronchitis coronavirus: genome evolution in vaccinated and non-vaccinated spf chickens. *Viruses*, 14(7): 1392.
- Franzo, G., C. M. Tucciarone, A. Blanco, A., M. Nofrarias, M. Biarnés, M. Cortey, N. Majó, E. Catelli, and M. Cecchinato. 2016. Effect of different vaccination strategies on IBV QX population dynamics and clinical outbreaks. *Vaccine*, 34(46):5670–5676.
- Ganapathy, K. 2009. Diagnosis of infectious bronchitis in chickens. *In Practice* 31: 424–431
- Gelb Jr, J., Y. Weisman, B. S. Ladman, and R. Meir. 2005. S1 gene characteristics and efficacy of vaccination against infectious bronchitis virus field isolates from the United States and Israel (1996 to 2000). *Avian Pathol.* 34(3):194–203.
- Ghorbani, M., Z. Boroomand, M. Mayahi, and M. R. Seyfi Abad Shapouri. 2020. Molecular identification of infectious bronchitis virus isolated from respiratory diseases in some Iranian broiler flocks. *Mol. Biol. Rep.* 47:7161–7168.
- Habib M., V. Karimi, A. G. Langeroudi, S. A. Ghafouri, M. Hashemzadeh R. K. Farahani, H. Maghsoudloo, H. Abdollahi, and P. Seifouri. 2017. Combination of H120 and 1/96 avian infectious bronchitis virus vaccine strains protect chickens against challenge with IS/1494/06 (variant 2)-like infectious bronchitis virus. *Acta Virol.* 61(2):150–160.
- Han, Z., C. Sun, B. Yan, X. Zhang, Y. Wang, C. Li, Q. Zhang, Y. Ma, Y. Shao, and Q. Liu. 2011. A 15-year analysis of molecular epidemiology of avian infectious bronchitis coronavirus in China. *Infect. Genet. Evol.* 11(1):190–200.
- Hasan, I. I., S. T. Rasheed, N. A. Jasim, and M. K. Shakor. 2020. Pathological effect of infectious bronchitis disease virus on broiler chicken trachea and kidney tissues. *Vet. World* 13(10):2203.
- Hong, S.-M., H.-J. Kwon, I.-H. Kim, M.-L., Mo and J.-H. Kim. 2012. Comparative genomics of Korean infectious bronchitis viruses (IBVs) and an animal model to evaluate pathogenicity of IBVs to the reproductive organs. *Viruses*, 4(11):2670–2683.
- Hosseini, H., M. H. B. Fard, S. Charkhkar, and R. Morshed. 2015. Epidemiology of avian infectious bronchitis virus genotypes in Iran (2010–2014). *Avian Dis.* 59(3):431–435.
- Jackwood, M. W., D. A. Hilt, and T. B. Brown. 2003. Attenuation, safety, and efficacy of an infectious bronchitis virus GA98 serotype vaccine. *Avian Dis.* 47(3):627–632.
- Jukes, T.H. and C.R. Cantor. 1969. Evolution of protein molecules. In Munro HN, editor, *Mammalian Protein Metabolism*, pp. 21–132, Academic Press, New York.
- Kahya, S., F. Coven, S. Temelli, A. Eyigor, and K. T. Carli. 2013. Presence of IS/1494/06 genotype-related infectious bronchitis virus in breeder and broiler flocks in Turkey. *Ankara Univ. Vet. Fak. Derg.* 60(1):27–31.
- Khataby, K., S. Fellahi, C. Loutfi, and E.M. Mustapha. 2016. Avian infectious bronchitis virus in Africa: a review. *Vet Q*, 36(2):71–75.
- Kumar S., G. Stecher and K. Tamura. 2016. MEGA7: Molecular Evolutionary Genetics Analysis version 7.0 for bigger datasets. *Mol. Biol. Evol.*, 33:1870–1874.
- Luna, L. G. 1968. Manual of histologic staining methods of the Armed Forces Institute of

- Pathology. In Manual of histologic staining methods of the Armed Forces Institute of Pathology (pp. xii–258).
- Najafi, H., A. G. Langeroudi, M. Hashemzadeh, V. Karimi, O. Madadgar, S. A. Ghafouri, H. Maghsoudlo and R. K. Farahani. 2016. Molecular characterization of infectious bronchitis viruses isolated from broiler chicken farms in Iran, 2014-2015. *Arch. Virol.*, 161:53–62.
- Pohuang T, N. Chansiripornchai A. Tawatsin and J. Sasipreeyajan. 2009. Detection and molecular characterization of infectious bronchitis virus isolated from recent outbreaks in broiler flocks in Thailand. *J. Vet. Sci* 10:219–223
- Pourbakhsh, S. A., A. Tavasoly, S. Mahdavi, and R. Momayez. 2007. Experimental histopathologic study of the lesions induced by serotype 793/B (4/91) infectious bronchitis virus. *Arch. Razi Inst.* 62(1):15–22.
- Seger, W., A. GhalyanchiLangeroudi, V. Karimi, O. Madadgar, M. V. Marandi and M. Hashemzadeh. 2016. Genotyping of infectious bronchitis viruses from broiler farms in Iraq during 2014-2015. *Arch. Virol.*, 161(5): 1229–1237.
- Ulaiwi, A. H. 2019. Role of some aromatic essential oil on immune status against infectious bronchitis vaccine and lipid profile of broiler chicken. *Iraqi J. Agric. Sci.*, 50(6).
- Valastro, V., E. C. Holmes, P. Britton, A. Fusaro, M. W. Jackwood, G. Cattoli, and I. Monne. 2016. S1 gene-based phylogeny of infectious bronchitis virus: an attempt to harmonize virus classification. *Infect. Genet. Evol.* 39:349–364.