

# Annular Pancreas in Neonates; Case Series and Review of Literatures

Haithem Hussein Ali Almoamin, Sadik Hassan Kadhem<sup>1</sup>, Ansam Mahmood Saleh<sup>2</sup>

Department of Surgery, University of Basrah, Al-Zahraa College of Medicine, Consultant, Basrah Children Specialty Hospital, <sup>1</sup>Department of Surgery, University of Basrah, Al-Zahraa College of Medicine, Basrah Children Specialty Hospital, <sup>2</sup>Department of Paediatric, Basrah Children Specialty Hospital, Iraq

## Abstract

**Background:** The annular pancreas is a rare congenital disorder of the pancreas first recognized in 1818. It is believed to result from faulty rotation of the ventral pancreatic bud in its course around the posterior aspect of the duodenal anlage. The duodenum is encircled and might be obstructed by normal pancreatic tissue. The management of the annular pancreas is still developing and under revision. **Case Presentation:** Six cases of neonatal intestinal obstruction secondary to the annular pancreas diagnosed, operated on, and involved in our study. Age, gender, maturity, age at referral, birth weight, clinical presentation, imaging findings, associated congenital anomalies, treatment, complications, and hospital stay were all studied. Polyhydramnios is found in 3 cases (50%). Down syndrome was diagnosed in one case. One patient has associated malrotation. Symptoms started earlier within the first 24 hours. Vomiting was bile stained in 4 cases (66.7%). Passing meconium, sometimes frequent, does not exclude the annular pancreas. Most patients show double bubbles sign on plain abdominal X-ray. All six neonates were treated with duodenoduodenostomy with excellent results. Survival was 100% and complications were minimum. **Conclusion:** The annular pancreas, although rare, is an important cause of neonatal duodenal obstruction. The accurate diagnosis is usually performed during laparotomy. Vomiting may contain bile or not, furthermore, passing meconium does not exclude this condition. The best and the excellent surgical option is diamond duodenoduodenostomy. This case series might be added to the registered cases of the annular pancreas to standardize the method of diagnosis and to define the best management.

**Keywords:** Annular, congenital, neonate, obstruction, pancreas

## INTRODUCTION

The annular pancreas is a rare congenital disorder of the pancreas, first recognised by Tiedman in 1818 and named by Ecker in 1862.<sup>[1-4]</sup> Three varieties of pancreatic fusion anomalies are identified: pancreas divisum, annular pancreas and portal annular pancreas.<sup>[5]</sup> The pancreas is formed by two buds, dorsal and ventral, originating from the endodermal lining of the duodenum. When the duodenum rotates to the proper, the ventral bud moves dorsally to lie just inferior and behind the dorsal bud.<sup>[6]</sup> The Annular pancreas is thought to result from abnormal rotation of the ventral pancreatic bud in its course around the posterior aspect of the duodenal anlage. The duodenum is encircled and might be obstructed by normal pancreatic tissue.<sup>[7]</sup> Three theories try to explain the development of the annular pancreas.

1. Baldwin (1910): The annular pancreas is due to failure of atrophy of the left component of the ventral pancreatic anlage which maintains a true ventral connection<sup>[8]</sup>
2. Lecco: The ventral pancreas adhered to surrounding tissues at its site of origin within the ventral mesogastrium maintaining a true ventral connection<sup>[9,10]</sup>
3. Verga (1972): The first abnormality is duodenal with the pancreas “filling the space” around a narrowed duodenum.<sup>[11]</sup>

The cause of congenital duodenal obstruction may be intrinsic or extrinsic.<sup>[12]</sup> The most common cause of duodenal obstruction is atresia (1 in 5,000–10,000).<sup>[13]</sup> The annular pancreas occurs in 1 in 20,000 births. In children, it is more

**Address for correspondence:** Dr. Haithem Hussein Ali Almoamin, Assistant Professor, University of Basrah, Al-Zahraa College of Medicine, Consultant, Basrah Children Specialty Hospital, Basrah, Iraq. E-mail: haithem.ali@uobasrah.edu.iq

Received: 19-12-2020 Revised: 04-06-2021 Accepted: 24-06-2021 Available Online: 01-01-2022

### Access this article online

#### Quick Response Code:



**Website:**  
www.afrijpaedsurg.org

**DOI:**  
10.4103/ajps.AJPS\_180\_20

This is an open access journal, and articles are distributed under the terms of the Creative Commons Attribution-NonCommercial-ShareAlike 4.0 License, which allows others to remix, tweak, and build upon the work non-commercially, as long as appropriate credit is given and the new creations are licensed under the identical terms.

**For reprints contact:** WKHLRPMedknow\_reprints@wolterskluwer.com

**How to cite this article:** Ali Almoamin HH, Kadhem SH, Saleh AM. Annular pancreas in neonates; case series and review of literatures. Afr J Paediatr Surg 2022;19:97-101.

commonly associated with other congenital anomalies including Down syndrome, cardiac anomalies, duodenal atresia or stenosis and intestinal malrotation.<sup>[1,14]</sup> When diagnosed in utero, the most common presentation is polyhydramnios due to duodenal obstruction.<sup>[1]</sup> The clinical significance relates primarily to an intrinsic duodenal obstruction, typically with bilious vomiting.<sup>[15]</sup> When the annular pancreas presents in childhood, it tends to be severe, presenting at a median age of 1 day.<sup>[1]</sup> The diagnosis is usually made by the presence of a double bubble of air on a plain abdominal radiograph, but it can be confirmed by upper gastrointestinal series that demonstrate duodenal obstruction.<sup>[16]</sup>

## PATIENTS AND METHODS

Medical records of all cases of duodenal obstruction, admitted in the neonatal care unit at Basrah Children Specialty Hospital from January 2016 to January 2020, were retrospectively reviewed. Basrah Children Specialty Hospital is a tertiary hospital within the south of Iraq with neonatal surgical services. Congenital duodenal obstruction was encountered in 34 neonates. Duodenal atresia was found in 12 cases. Malrotation without volvulus and with volvulus is found in 10 and 4 cases, respectively. Annular pancreas is seen in 6 cases only. Malrotation, associated with congenital diaphragmatic hernia or congenital abdominal wall defects, was excluded.

Six neonates were diagnosed with the annular pancreas, operated on and involved in our study. Age, gender, maturity, age at referral, birth weight, clinical presentation, imaging findings, associated congenital anomalies, treatment, complications and hospital stay were all studied.

This study was approved by the University of Basrah/Alzahraa College of medicine and Basrah health directorate.

## CASE REPORTS

The following six case reports illustrate the annular pancreas as a cause of neonatal intestinal obstruction.

### Case 1 (2020)

A 6-day-old male neonate, a product of full-term vaginal delivery presented with nonbilious vomitus since the 2<sup>nd</sup> day of life. The patient passed a little amount of meconium with no subsequent stool thereafter. There was mild upper abdominal distention after feeds. He was active, alert and afebrile. Mother was multipara with good antenatal care. The birth weight was 2.8 kg. The prenatal ultrasound was normal. Physical exam revealed no facial dysmorphism, no cyanosis, no pallor, but mild dehydration. The abdomen displayed normal fullness with neither visible peristalsis nor a mass. Plain abdominal X-ray showed high intestinal obstruction and contrast follow-through showed no contrast beyond the duodenum consistent with duodenal obstruction. The abdominal ultrasound and echocardiogram were normal. Through a transverse right supraumbilical incision, he underwent a duodenoduodenostomy for the annular pancreas

causing a duodenal obstruction. The patient was discharged home after 8 days with a simple wound infection.

### Case 2 (2018)

A 3-day-old male neonate, a product of full-term vaginal delivery of uneventful pregnancy. He presented with bile-stained vomiting after 1 day of birth with failure to pass meconium. The abdomen was not distended. The patient developed jaundice on the 2<sup>nd</sup> day with total serum bilirubin of 250 mmol/dl and was treated with phototherapy. Furthermore, he developed a frequent attack of cyanosis, although the echocardiogram was normal. The birth weight was 1.9 kg. A plain abdominal X-ray showed high intestinal obstruction. Laparotomy was done and an annular pancreas was confirmed. It was associated with malrotation. Duodenoduodenostomy with Ladd procedure was done. The patient was discharged home after 9 days. He continued complaining from bile-stained vomiting and was treated conservatively. The vomiting subsided after about 3 months.

### Case 3 (2018)

A 4-day-old female neonate, a product of full-term vaginal delivery. The pregnancy was complicated with polyhydramnios. Her family consulted a paediatric surgeon for frequent bile-stained vomiting for a few hours of birth. The patient passes frequent small amounts of meconium. Physical examination was unremarkable except mild jaundice. He had obvious upper abdominal distension. The birth weight was 2.8 kg. Laboratory investigations were normal. A plain abdominal X-ray demonstrated a double bubble sign. A contrast meal showed complete duodenal obstruction. The echocardiogram was normal. Laparotomy was done and an annular pancreas was found. Duodenoduodenostomy was done. The patient was discharged home after 10 days with no complications.

### Case 4 (2017)

A 4-day-old male neonate, a product of full-term vaginal delivery to a para 6 + 0 mother. The pregnancy was uncomplicated. He presented with bile-stained vomiting within the 1<sup>st</sup> day of life. The patient did not pass meconium. He developed mild jaundice after the 2<sup>nd</sup> day with progressively decreased feeding and poor activity. The birth weight was 2.5 kg. Physical examination was unremarkable other than the facial characteristic of trisomy 21. The abdomen was not distended. Laboratory investigations were normal except indirect hyperbilirubinaemia. A plain abdominal X-ray demonstrated a double bubble sign. The abdominal ultrasound and echocardiogram were normal. Laparotomy was done on the next day and an annular pancreas was discovered. Duodenoduodenostomy was done. The patient was discharged home after the 9<sup>th</sup> day effortlessly.

### Case 5 (2017)

A 4-day-old male neonate, a product of full-term vaginal delivery to a para 3 + 0 mother. The pregnancy was complicated with polyhydramnios. He presented with bile-stained vomiting since the 1<sup>st</sup> day after birth. The patient

passed small amounts of meconium. Physical examination revealed a vigorous neonate with mild dehydration but reduced urine output. He had obvious upper abdominal distension. The birth weight was 3 kg. Lab investigations were normal apart from anemia (Hb% =8.2). A plain abdominal X-ray demonstrated a double bubble sign. The echocardiogram was normal. Laparotomy, after correction of dehydration and anemia, was done and an annular pancreas was confirmed. Duodenoduodenostomy was done. The patient was discharged home after 12 days well.

### Case 6 (2016)

A 12 h female neonate, a product of vaginal delivery. The pregnancy was complicated with polyhydramnios. She presented with nonbile-stained vomiting since the 1<sup>st</sup> day of birth with a gastric aspirate of 25 ccs. The patient did not pass meconium. Physical examination was unremarkable other than mild jaundice. He had mild upper abdominal distension. The birth weight was 2.4 kg. Laboratory investigations were normal. A plain abdominal X-ray demonstrated a double bubble sign. The echocardiogram was normal. Laparotomy was done and an annular pancreas was found. Duodenoduodenostomy was done. The child was discharged home after 9 days with no complications.

**Table 1: Demography of neonates with annular pancreas**

Cases	Age at referral (days)	Sex	Birth weight (kg)	Maturity
1	6	Male	2.8	Term
2	3	Male	1.9	Preterm
3	4	Female	2.8	Term
4	4	Male	2.5	Term
5	4	Male	3	Term
6	0.5	Female	2.4	Term

**Table 2: Presentation and associated anomalies of annular pancreas**

Cases	Polyhydramnios	Vomiting	Meconium	Upper distension	Jaundice	Others	Associated anomalies
1	No	Nonbilious	Infrequent/small	Mild	Absent		Absent
2	No	Bilious	No	No	Moderate/phototherapy	Cyanosis	Malrotation
3	Yes	Bilious	Frequent/small	Mild	Mild		Absent
4	No	Bilious	No	No	Mild		Down syndrome
5	Yes	Bilious	Frequent/small	Obvious	Absent	Anaemia	Absent
6	Yes	Nonbilious	No	Mild	Mild		Absent

**Table 3: Diagnosis, treatment, and prognosis of annular pancreas**

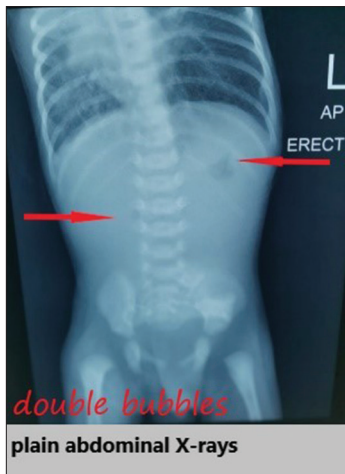Cases	X-rays	Operation	Complications	Survival	Hospital stay (day)
1	High intestinal obstruction	Duodenoduodenostomy	Wound infection	Yes	8
2	High intestinal obstruction	Duodenoduodenostomy Ladd procedure	Vomiting	Yes	9
3	Double bubble	Duodenoduodenostomy	No	Yes	10
4	Double bubble	Duodenoduodenostomy	No	Yes	9
5	Double bubble	Duodenoduodenostomy	No	Yes	12
6	Double bubble	Duodenoduodenostomy	No	Yes	9

## RESULTS

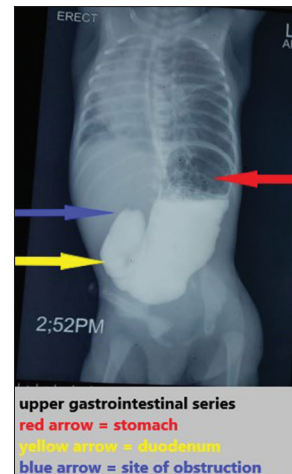
Details about the demography, presentation, associated anomalies and mode of diagnosis, treatment and prognosis are illustrated in Tables 1-3.

## DISCUSSION

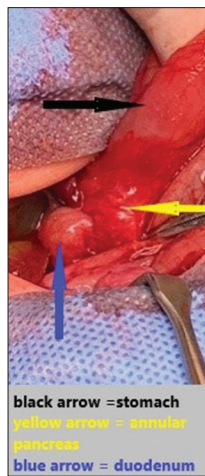
Six cases of neonatal intestinal obstruction secondary to the annular pancreas were studied. The diagnosis of duodenal obstruction was easy with the aid of clinical and radiological studies, but the differentiation of the annular pancreas from other causes of duodenal obstruction was rather difficult and usually assured during operation. Polyhydramnios was found in 3 cases (50%). Male was affected more than female with a ratio of 2:1. In one study, the male gender recorded in 10 from 22 paediatric patients with an annular pancreas.<sup>[17]</sup> The same study<sup>[17]</sup> showed that the mean birth weight was  $2285.2 \pm 675$  g, while, the present study revealed that the mean birth weight was 2566 g (range: 1.9–3 kg). In a study of 152 annular pancreas cases; Wang D *et al.* stated that the association of annular pancreas and low birth weight could be due to the failure of amniotic fluid absorption in the gastrointestinal tract in addition to pancreatic insulin secretion impairment.<sup>[18]</sup> Down syndrome was diagnosed in one case (16.7%), while Yigiter *et al.* reported that 8 of 22 (36.3%) patients had trisomy 21.<sup>[17]</sup> One patient has associated malrotation (16.7%). In a review of seven cases of the annular pancreas by Sencan *et al.*; the most frequent associated anomaly was intestinal malrotation (42.8%).<sup>[19]</sup> The mean age at referral was 3.6 days (range 12 h–6 days) but findings of duodenal obstruction were evident earlier within the 1<sup>st</sup> 24 h. A report of 11 cases of the annular pancreas by Li *et al.* showed that the age of patients ranged from 1 to 13 days (mean 4.2 days).<sup>[20]</sup> Only one patient was preterm (16.7%), Jimenez *et al.* declared that Four of sixteen patients (25%) were premature.<sup>[21]</sup> Vomiting was nonbilious in only 2 cases (33.3%). Yigiter *et al.*<sup>[17]</sup> and Jimenez



**Figure 1:** Plain abdominal X-rays erect shows double bubble sign

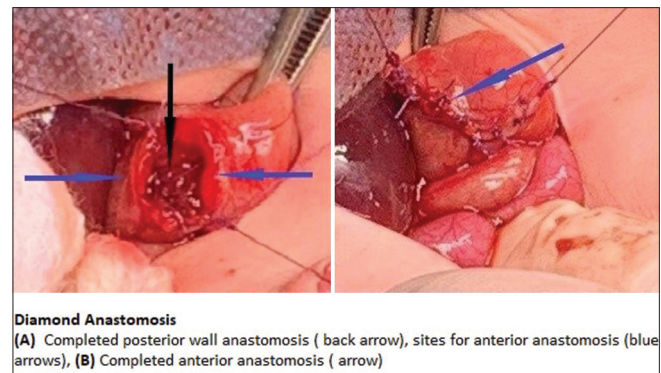


**Figure 2:** Contrast meal and follow through shows duodenal obstruction



**Figure 3:** Operative illustration of annular pancreas

*et al.*<sup>[21]</sup> reported that the vomiting was nonbilious in 59% and 94% of patients, respectively. Sencan *et al.*<sup>[19]</sup> found in their study that of the seven cases reviewed, two (28.57%) having partial duodenal obstruction, Jimenez *et al.*<sup>[21]</sup> in their study of sixteen cases, they found that the obstruction of the duodenum was partial in 69% of patients while in our study complete duodenal obstruction was present in all patients. Passing meconium, sometimes frequent, does not exclude the annular pancreas. In our study, two cases (33.3%) passed frequent small amounts of meconium. No abdominal distension was encountered apart from mild upper abdominal fullness. Mild indirect hyperbilirubinaemia is common in cases of upper intestinal obstruction, although one neonate developed moderate jaundice requiring phototherapy. The diagnosis was done with plain abdominal X-rays which showed a characteristic double bubbles sign in four cases [Figure 1] and a picture of high intestinal obstruction in the remaining two cases. Yigiter *et al.*<sup>[17]</sup> and Sencan *et al.*<sup>[19]</sup> studies reported the presence of typical double bubbles sign in 90.9% and 100%, respectively. Water-soluble upper gastrointestinal series was done in two patients and showed no contrast beyond the duodenum consistent with duodenal obstruction [Figure 2].



**Figure 4:** Operative illustration of diamond duodenoduodenostomy

The treatment of the annular pancreas is surgical. Its aim is the relief of the duodenal obstruction. For this, various procedures are being used.

1. Division of a portion of the annular pancreas: this approach has many disadvantages. It harbors a risk of pancreatitis, pancreatic or duodenal fistula.<sup>[22,23]</sup> Direct division of the annular pancreas should be avoided because this does not address the underlying intraluminal duodenal obstruction, and there is a significant risk of injury to the accessory pancreatic duct<sup>[1,16]</sup>
2. Gastrojejunostomy or duodenojejunostomy with Roux en Y loop.<sup>[23-25]</sup> They are associated with peptic ulcer and the risk of anastomotic ulcer suggest the need for a procedure like a vagotomy which reduces acid secretion by the stomach.<sup>[9,23]</sup> These complications lead to the reluctance of many paediatric surgeons to perform these procedures
3. Duodenoduodenostomy. The best and commonly used procedure nowadays with fewer complications.<sup>[1,9,16,22]</sup>

In the present study, the six neonates were treated with duodenoduodenostomy with excellent results [Figures 3 and 4]. Kimura *et al.*<sup>[26]</sup> stated that diamond-shaped duodenoduodenostomy provided early functioning wide anastomosis with the avoidance of a blind loop. Excellent results have been obtained after laparoscopic duodenoduodenostomy

done by Li *et al.* for 11 neonates with the annular pancreas.<sup>[20]</sup> Survival was 100% and complications were minimal. One patient continued suffering from repeated vomiting but improved after 3 months. A simple wound infection occurred in one patient. The reported survival rate was 100% in three studies,<sup>[19-21]</sup> and (63.6%) in one study.<sup>[17]</sup> The average hospitalisation reported by three studies: Yigiter *et al.*,<sup>[17]</sup> Sencan *et al.*,<sup>[19]</sup> and Jimenez *et al.*<sup>[21]</sup> were (24.1 ± 15.5 days), (22 ± 1.8 days) and (24.0 days), respectively. In this study, the mean of hospital stay was 9.5 days.

The prognosis of patients with annular pancreas depends largely upon the age of presentation.<sup>[27]</sup> In infants and children, the prognosis largely depends on the associated congenital abnormalities.<sup>[21]</sup> The low incidence of associated congenital anomalies in the present study may reflect the 100% survival rate. In addition, this outcome indicates the recent advances in both anesthetic and intensive care of surgical neonates.

## CONCLUSION

The annular pancreas, although rare, is an important cause of neonatal duodenal obstruction. The accurate diagnosis is usually performed during laparotomy. Vomiting may contain bile or not, furthermore, passing meconium does not exclude this condition. The best and excellent surgical option is diamond duodenoduodenostomy. This case series might be added to the registered cases of the annular pancreas to standardise the method of diagnosis and to define the best management.

## Declaration of patient consent

The authors certify that they have obtained all appropriate patient consent forms. In the form the patient(s) has/have given his/her/their consent for his/her/their images and other clinical information to be reported in the journal. The patients understand that their names and initials will not be published and due efforts will be made to conceal their identity, but anonymity cannot be guaranteed.

## Financial support and sponsorship

Nil.

## Conflicts of interest

There are no conflicts of interest.

## REFERENCES

- Riall TS. Pancreas anatomy and physiology. In: Mulholland MW, Collier FA, Arbor A, editors. *Greenfield's Surgery/Scientific Principles and Practice*. 5<sup>th</sup> ed., Vol. 51. Philadelphia, PA, USA: Lippincott Williams and Wilkins, A Wolters Kluwer Business; 2011. p. 802-3.
- Miyano T. The pancreas. In: Grosfeld JL, O'Neill JA Jr., Coran AG, Fonkalsrud EW, Caldame AA, editors. *Pediatric Surgery*. 6<sup>th</sup> ed., Vol. 107. Philadelphia: Mosby; 2006. p. 1671.

- Tiedemann F. Annular pancreas. *Dtsch Arch Physiol* 1818;4:403.
- Ecker A. Bildungsfehler des pancreas und des herzens [defective formation of the pancreas and heart]. *Z Rat Med Leipz* 1862;14:354-6.
- Nijs E, Callahan MJ, Taylor GA. Disorders of the pediatric pancreas: Imaging features. *Pediatr Radiol* 2005;35:358-73.
- Sadler TW. Digestive system. In: Langman's Medical Embryology. 12<sup>th</sup> ed. Baltimore, MD and Philadelphia, PA: Wolters Kluwer/Lippincott Williams and Wilkins; 2012. p. 221.
- Fusco JC, Malek MM, Gittes GK. Lesions of the pancreas. In: Holcomb GW 3<sup>rd</sup>, Murphy PJ, Ostlie DJ, editors. *Ashcraft's Pediatric Surgery*. 7<sup>th</sup> ed., Vol. 46. London, New York, Oxford, Philadelphia, St. Louis, Sydney and Toronto: Elsevier Saunders; 2020. p. 737.
- Heyries L, Sahel J. Congenital anomalies of the pancreas. *Hepatology*; [7-102-a-15].
- Lloyd-Jones W, Mountain JC, Warren KW. Annular pancreas in the adult. *Ann Surg* 1972;176:163-70.
- Ikeda Y, Irving IM. Annular pancreas in a fetus and its three-dimensional reconstruction. *J Pediatr Surg* 1984;19:160-4.
- Dowsett JF, Rode J, Russell RC. Annular pancreas: A clinical, endoscopic, and immunohistochemical study. *Gut* 1989;30:130-5.
- Ladd WE. Congenital obstruction of the duodenum in children. *N Engl J Med* 1931;206:277-83.
- van der Zee DC. Laparoscopic repair of duodenal atresia: Revisited. *World J Surg* 2011;35:1781-4.
- Shaw-Smith C. Genetic factors in esophageal atresia, tracheo-esophageal fistula and the VACTERL association: Roles for FOXP1 and the 16q24.1 FOX transcription factor gene cluster, and review of the literature. *Eur J Med Genet* 2010;53:6-13.
- Urushihara N, Fukumoto K, Fukuzawa H, Suzuki K, Matsuoka T, Kawashima S, *et al.* Recurrent pancreatitis caused by pancreatobiliary anomalies in children with annular pancreas. *J Pediatr Surg* 2010;45:741-6.
- Schwartz MZ, Katz MS. Disorders of the pancreas. In: Mattei P, editor. *Fundamentals of Pediatric Surgery*. Vol. 80. Philadelphia, PA, USA: Springer; 2010. p. 617.
- Yigiter M, Yildiz A, Firinci B, Yalcin O, Oral A, Salman AB. Annular pancreas in children: A decade of experience. *Eurasian J Med* 2010;42:116-9.
- Wang D, Kang Q, Shi S, Hu W. Annular pancreas in China: 9 years' experience from a single center. *Pediatr Surg Int* 2018;34:823-7.
- Sencan A, Mir E, Günsar C, Akcora B. Symptomatic annular pancreas in newborns. *Med Sci Monit* 2002;8:R434-7.
- Li B, Chen WB, Wang SQ, Wang YB. Laparoscopic diagnosis and treatment of neonates with duodenal obstruction associated with an annular pancreas: Report of 11 cases. *Surg Today* 2015;45:17-21.
- Jimenez JC, Emil S, Podnos Y, Nguyen N. Annular pancreas in children: A recent decade's experience. *J Pediatr Surg* 2004;39:1654-7.
- Zyromski NJ, Sandoval JA, Pitt HA, Ladd AP, Fogel EL, Mattar WE, *et al.* Annular pancreas: Dramatic differences between children and adults. *J Am Coll Surg* 2008;206:1019-25.
- Thomford NR, Knight PR, Pace WG, Madura JA. Annular pancreas in the adult: Selection of operation. *Ann Surg* 1972;176:159-62.
- Mahdi B, Selim S, Hassen T, Mongi MM, Fadhel CM, Fathi C, *et al.* A rare cause of proximal intestinal obstruction in adults-annular pancreas: A case report. *Pan Afr Med J* 2011;10:56.
- Whittingham-Jones PM, Riaz AA, Clayton G, Thompson HH. Annular pancreas – A rare cause of gastric obstruction in an 82-year-old patient. *Ann R Coll Surg Engl* 2005;87:W13-5.
- Kimura K, Mukohara N, Nishijima E, Muraji T, Tsugawa C, Matsumoto Y. Diamond-shaped anastomosis for duodenal atresia: An experience with 44 patients over 15 years. *J Pediatr Surg* 1990;25:977-9.
- Available from: <https://www.uptodate.com/contents/annularpancreas>. (updated 2021, May, 16).