



RESEARCH ARTICLE

Isolation and Characterization of *Aeromonas Hydrophila* Associated with Septicemia in *Cyprinus Carpio* l., 1758

Nadia A. H. Al- Shammari^{1*}, Adnan B. Al-Hawash², Khalidah S AL-Niaeem³

¹Department of Biological DevelopmenMarine Sciences Centre, University of Basra, Basra, Iraq

^{1,3}Department of Fisheries and Marine Resources, College of Agriculture, University of Basrah, Basrah, Iraq

²Department of Biology, College of Education-Qurna, University of Basrah, Basra, Iraq

²Key Laboratory of Molecular Biophysics of MOE, College of Life Science and Technology, Huazhong University of Science and Technology, Wuhan, 430074, China

| ARTICLE INFO | ABSTRACT |
|-------------------------------|---|
| Received: Feb 22, 2024 | The study shows the effect of Motile <i>Aeromonas</i> on the liver and Kidney of <i>Cyprinus carpio</i> . <i>Aeromonas hydrophila</i> was identified from Quantitative PCR by 16srRNA gen and challenged with an injection dosage of 6.9×10^7 CFU/ mL. <i>Aeromonas hydrophila</i> caused 80% mortality in fish for seven days of injection for the current study, the <i>Aeromonas</i> infection causes global disease problems due to the high mortality of fish especially in Iraq, liver and kidney tissues were collected on days 7 post-infection some signs of the infection are inflammation on different region of the fish body, ulceration on skin, and necrosis, degeneration at soft rays of the fins, in which hemorrhage and necrosis in internal organs of fish increased aggregation of melanocytic phagocytes in the liver and kidney. Based on these results <i>A. hydrophila</i> infection may elicit oxidative stress and damage in the liver and the kidney directly contributes to the pathophysiology and pathogenesis of infected fish. |
| Accepted: May 9, 2024 | |
| Keywords | |
| <i>Aeromonas hydrophila</i> | |
| Gram-negative | |
| Fish disease | |
| Virulence factor | |
| Histological effect | |
| *Corresponding Author: | |
| abbiology@yahoo.com | |

INTRODUCTION

Aeromonas hydrophila is an opportunistic pathogen causing *Aeromonas* mobile blood poisoning in many fish species, including *Cyprinus carpio*, and causes motile *Aeromonas* septicemia (MAS) *A. hydrophila* is still a challenge in fish because of bacterial diversity and is a Gram-negative bacterial (Zhao et al., 2024) *Cyprinus carpio* is also an important fish species cultured in Iraq which are exposed to many environmental factors dangerous to them in the water (FAO, 2020).

Water pollution by microbes or toxic pollutants is a global problem that negatively impacts the health of fish and has stimulated many physiological, biological, and also histopathological changes in fish during the past decades. Agricultural practices and Rapid industrialization mainly led to microbial pollution in the aquatic environment, through accumulation in the internal tissues of fish leading to potential dangers for fish and their consumers (Abiona et al., 2019).

Bacterial fish pathogens are one of the main challenges for the aquaculture industry, which is a rapidly growing industry worldwide. These pathogens rely on many virulence factors such as toxins, adhesives, effectors and enzymes to promote infection and colonization (Mekasha and Linke, 2021).

Aquaculture regarded is as one of the key and fast-growing industries that provide the world's population with nutritional protection. *Cyprinus carpio* is the most widely consumed and heavily cultivated freshwater fish in the world (Mahboub and Tartor 2020). Histopathological indicators are vital indicators of the correlations between pathogen and histopathology. Cytoplasm degeneration of hepatocytes, necrosis, atrophy, formation of vacuoles, and high number of immune phagocytic cells, are pathological changes that can be observed in the liver of freshwater fish (FAO, 2020).

Tissues liver and kidney are the most affected organs, the pathological pathways linked with its damage during *A. hydrophila* infection of histopathological. Abdel-Tawwab and El-Araby (2021). They are responsible for the detoxification processes in these tissues, which highlights their significant role in antioxidant immune defense and cellular protection (Habte-Tsion, 2020).

This study aims to experimentally establish the cause of pathological and histopathological changes and pathological signs in common carp with *A. hydrophila* and its pathogenetic effects on the liver and kidney.

MATERIALS AND METHODS

Bacteria identified and prepared.

Bacteria were identified from the gram-native bacterial and biochemical test Tabal 2. *Aeromonas hydrophila* isolated from dead dying fish and confirmed by PCR polymerase chain reaction was isolated from diseased fish and identification of 16s rRNA using a DNA sequencer online at <http://www.ncbi.nlm.nih.gov/>. Al- Shammari et al. (2023). The lyophilized culture was in Tryptic soy broth at 37°C for 24 h and then, transfer done to the Tryptic soy agar streak plate method was followed to obtain the desired single isolated colonies on Tryptic soy agar. For dos preparation, the bacteria were inoculated in nutrient broth (NB) and then incubated at 37°C for 24 h after that centrifuged at 5000 x g for 4 min and then washed with physiological saline.

Preparing fish for the experiment

Healthy *Cyprinus carpio* (n= 40, the average of body weight 28.4 ± 0.14 g) were included in this experiment. Fish were bring from the Karma Ali River in Basra governorate, Iraq. The Fish were put under observation for 7 d before starting the experiment. A clinical examination was also performed to check the disease-free status of the fish before experimenting. Fish were acclimated using maintaining in glass aquaria of dimensions (60 × 40 × 50 cm) with a rate of 6 fish per 60 L of DE-chlorinated with tap water. The parameters of water quality in the laboratory including pH (6.9 ± 0.1), temperature (23.1 ± 1.1 °C), clinical diagnostic symptoms, and daily mortality were recorded for 7 d.

Experimental design

Forty fish were divided healthy *Cyprinus carpio* were divided into four equal groups (B1–B4). *A. hydrophila* was previously isolated from moribund dying fish of *C. carpio*. The lethal dose (LD50) was determined. During the challenge, the fish of treatment groups (4 tanks) were intraperitoneally injected by 0.2 mL of bacterial suspension, whereas the control fish (1 tank) were inoculated by sterile saline solution (0.86%). The semi-lethal dose (LD50) was recognized as 6.9×10^7 CFU/ mL,

which was used for injected fish intraperitoneal (IP) according to (Abdelsalam et al., 2021). Mortalities and clinical signs were monitored during the experiment.

Histopathology

Tissue samples of Liver and Kidney were extracted from all the groups of fish, and kept in 10% buffered neutral formalin, then in ascending grades of alcohol, cleared in xylene, embedded in paraffin, then stained with hematoxylin and eosin (H&E), then scanned by optical microscope .

RESULTS

A Table 1 showing the properties and biochemical tests performed on the isolate to determine them by conventional methods.

Table 1: Some characteristics of *A. hydrophila* isolates isolated from infected carp (Mostafa et al., 2008).

| Characters | Characterization |
|-----------------|------------------|
| Gram stain | - |
| Oxidase | + |
| Indole | + |
| Voges-Proskauer | + |
| Catalase | + |
| Methyl-red test | - |
| Shape | Rod |

Clinical and pathological symptoms *A. hydrophila*

In Figure (2) Morphological sign of motile Aeromonad septicemia (MAS) in *C. carpio* has been well-known as the causative agent of several symptoms with inflammation of the skin, liver, and kidneys. It is associated with septicemia and ulcerative-necrotic disorders in fish and is considered an opportunistic pathogenetic *A. hydrophila*. *A. hydrophila* reasons disease in fish known as aerobic motile blood poisoning, hemorrhagic blood poisoning, ulcer disease or erythrodermic ulcer disease, Hemorrhagic septicemia, ulcer cause mortality in freshwater fish. *A. hydrophila* ,and cause Motile Aeromonas septicemia (MAS) in fish caused mortality of 80% in fish by hibernation during seven days of injection of fish.

Mortality and post-mortem Clinical diagnostic symptoms of *Cyprinus carpio*

Aeromonas infection is one of the most common bacterial diseases of freshwater fish. and it causes many pathological symptoms, including ulcers and lesions, exophthalmos, inflammation of the intestines, bleeding, and eating fins, so that death is rapid when infected *A. hydrophila*, Deaths or

deaths in species of fish were high in *Cyprinus carpio* from the first day of bacterial injection, the fish began reactions affected by injections, namely irregular swimming and interrupted feeding, then the death rates on the third day increased. The percentage of deaths increased, and *Cyprinus carpio* continued to gradually decrease by the fifth day and then on the seventh day, there were very few deaths in *Cyprinus carpio* Figure 1.




Fig.1. Mortality of *C. carpio* during LD 50-7th of *A. hydrophila* infection

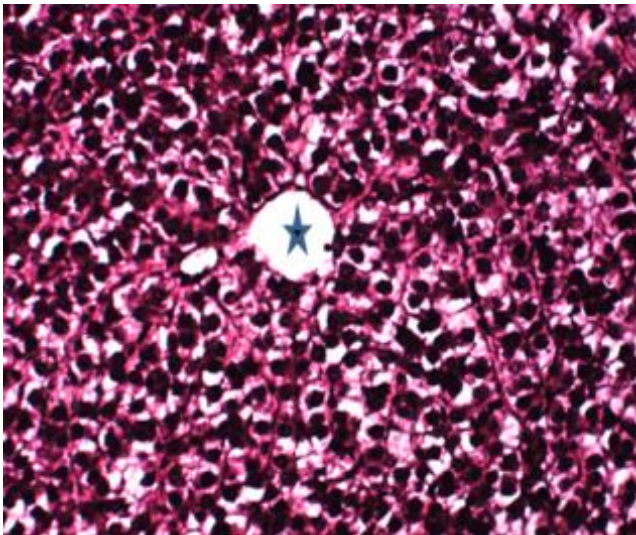


Figure 2: Morphological sing of motile aeromonad septicemia (MAS) in *C. carpio*

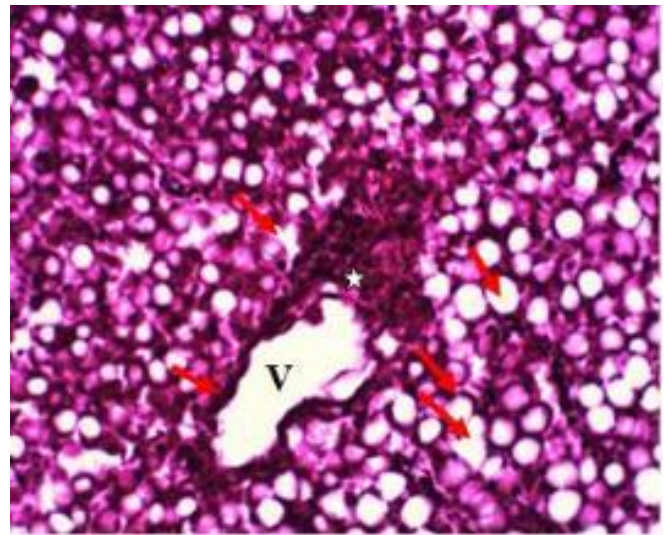
Histopathological analysis

Especially strong reaction of the liver appeared in the hepatic pancreas. the structure of the Liver showed the A- distributed melanomacrophages massive necrosis of hepatocytes, B- liver showed vacuole degeneration (arrows) of most hepatocytes and dilation of vein (V) and infiltration of inflammatory cells (asterisk) liver vacuole degeneration (arrows) of most hepatocytes and dilation of vein (V) and infiltration of inflammatory cells (asterisk), vacillation of liver tissue, liver vacuole degeneration of most hepatocytes (arrows) (see Figure 3.).

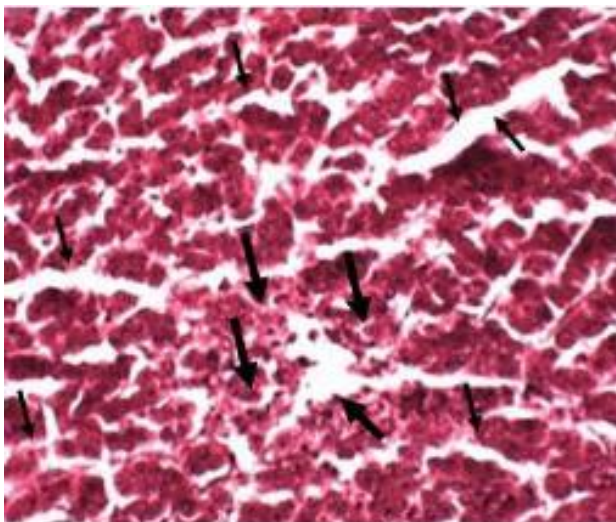
The structure of the Kidney (see Figure 4.) Showed the: E-kidney necrosis of lining epithelial cells of renal tubule (arrows), and dilation of other tubule (asterisks). F- Kidney dilation of lumen of renal tubule.



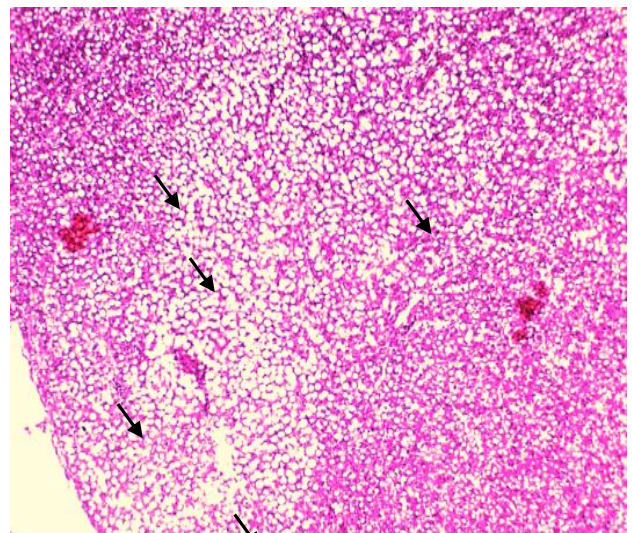
A-Liver showed the distributed melanomacrophages massive necrosis of hepatocytes H&E, 40x.



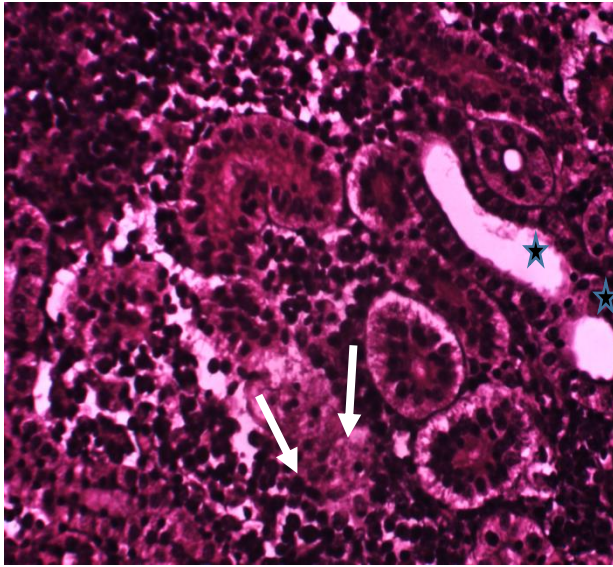
B- liver showed vacuole degeneration (arrows) of most hepatocytes and dilation of vein (V) and infiltration of inflammatory cells (asterisk), H&E, 40x.



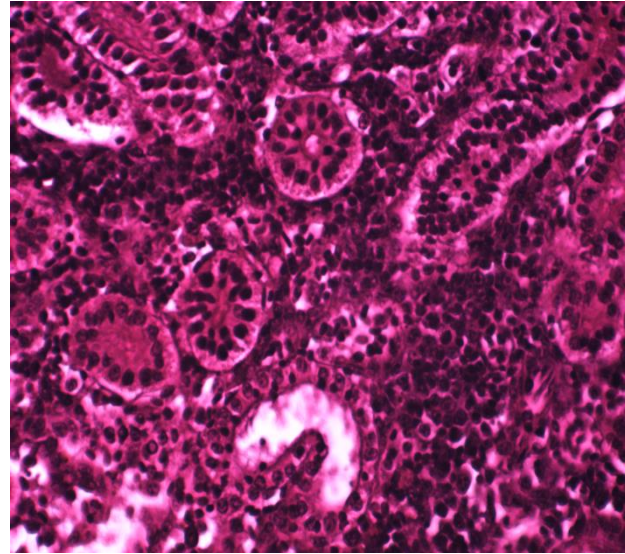
C- liver vacuole degeneration (arrows) of most hepatocytes and dilation of vein (V) and infiltration of inflammatory cells (asterisk), H&E, 40x.



C- liver vacuole degeneration of most hepatocytes (arrows), H&E, 40x.



E-kidney necrosis of lining epithelial cells of renal tubule (arrows), and dilation of other tubule (asterisks) 40x



F- Kidney dilation of lumen of renal tubule 40x

Figure 4: Photomicrograph showing H&E sections of Liver part of *C. carpio* injected with *A. hydrophila*

DISCUSSION

In the present study the different effects of histopathological, Image analysis, of one sub-dosage bacterial 6.9×10^7 CFU/ mL on the Liver and Kidney fingerlings *Cyprinus carpio*. current study showed infected fish within 24 hours of the *A. hydrophila* infection, the kidneys and liver showed pathological lesions and it is worth mentioning, after the challenge with *A. hydrophila*, our results showed that these liver and kidney tissues are well-known to be the target organs of bacteria *A. hydrophila* it is significant to note that the liver and kidneys may subsequently develop necrosis due to cytotoxins produced by *A. hydrophila* manifested itself as external symptoms including skin, a lesser degree of lesions, with the development of pathological lesions that occur later during the duration of the injection. The toxicological potential of pathogenic bacteria of different fish species is attributed to differences in Sensitivity, Tolerance, biotransformation, and excretion

The following figure 1 mortality of *C. carpio* during injection LD₅₀th of *A. hydrophila* infection samples were taken from the internal organs on the seventh day to make histological sections and figure 2 shows morphological signs of motile *Aeromonads* septicemia (MAS) in *C. carpio*, show ulcers, dermatitis, and focal rancidity appear in skin and organs.

In the current study, perivascular congestion was observed as a result of the presence of bacteria in them. the presence of this congestion confirms that bacteria secrete toxins that damage the inner lining of blood vessels and increase their permeability in tissues, which indicates changes in the liver infrastructure after infection with bacteria *A. hydrophila* in fish, the liver is the organ most associated with detoxification, metabolism, serum protein synthesis, detoxification and, due to its function, location and blood supply, it is also one of the organs most affected by bacterial contaminants and

toxins that infect fish (Biuki et al., 2013). The liver of the fish studied in the current study showed focal areas of necrosis, congestion of the central vein, and swelling of the liver cells. Since the liver is a detoxification site for all types.

The following figure 3 and figure 4 show the histological changes in fish after infection with bacteria *A. hydrophila*, additional several clinical signs of *A. hydrophila* infection. *A. hydrophila* in addition to its toxic products is responsible for its pathogenicity, which negatively impacts the health and performance of fish, leading to these deformities and pests (Youssef et al., 2023) and a recent study conducted by (Said et al., 2023) It was shown that the infection of common carp with bacteria *A. veronii* led to loss of balance, hemorrhagic spots, rotting of fins and loss of scales.

The current study showed the presence of dysfunction in the organs of the liver, and kidneys represented by pathological histological changes in the tissues of the liver, kidneys, and spleen. As a result of the secretion of some toxic agents by these bacteria, including lipopolysaccharide somatic antigen, which is a highly variable surface antigen that determines the specificity of each bacterial species, proteins, extracellular factors hemolysin and lipases, proteases (proteases) these toxins can produce oxidative damage in the tissues of the liver, kidneys and spleen and cause organ dysfunction, suppression of the immune system and histological changes (Hossain and Heo, 2021).

Appeared on the target organs of acute *A. hydrophila* infection. *hydrophila* in fish mainly occurs in the liver, kidneys, and spleen, and studies have indicated mild necrosis and deformation of hepatocytes in the liver of common carp. Where focal necrosis was in the kidneys and liver of carp fish, diffuse necrosis of the kidneys and histopathological changes in the liver of *C. carpio* due to the influence of bacterial infection have been reported (Mohanty et al., 2008).

Necrosis can be defined as a pathological process of cell death that can be because by infection, trauma, hypoxia, or toxins, necrosis is uncontrolled and releases a lot of chemicals from the dying cell that cause damage to the surrounding cells inflammation often begins due to necrosis coagulated necrosis generally occurs due to infarction (lack of blood flow from an obstruction that causes ischemia) and can occur in all cells of the body excluding the brain. The heart, kidneys, or spleen are decent examples of coagulated necrosis cells that undergo coagulation necrosis can become dry, hard, and is interesting is that the jelly-like appearance occurs in necrotic tissues, but the structure of the cells is preserved for at least a few days. Coagulation occurs when proteins break down and their nature is distorted (Abdel Rahman et al., 2022; Moustafa, 2020)

CONCLUSION

A. hydrophila is caused highly pathogenic and is linked with outbreaks and high mortality rates in *C. carpio* in the water. This result, along with other recently described bacterial pathogens in fish farming, this study highlights the significance of designing disease control programs based on the correct identification of pathogens to facilitate timely and important decision-making at the level of fish production and the identification of their histopathology on internal organs using a specific dose that determines the degree of pathogenicity.

REFERENCES

Abdel-Tawwab, M. El-Araby, D.A. (2021) Immune and antioxidative effects of dietary licorice (*Glycyrrhiza glabra* L.) on the performance of Nile tilapia, *Oreochromis niloticus* (L.) and its susceptibility to *Aeromonas hydrophila* infection. *Aquaculture* 530:735828. <https://doi.org/10.1016/j.aquaculture.2020.735828>

- Abdel Rahman, A.N.; Van Doan, H.; Elsheshtawy, H.M.; Dawood, A.; Salem, S.M.R.; Sheraiba, N.I.; Masoud, S.R.; Abdelnaeim, N.S.; Khamis, T.; Alkafafy, M and Mahboub, H.H. (2022b). Dietary *Salvia officinalis* leaves enhances antioxidant-immune-capacity, resistance to *Aeromonas sobria* challenge, and growth of *Cyprinus carpio*. *J. Fish Shellfish Immunol*, 127:340–348. <https://doi.org/10.1016/j.fsi.2022.06.030>.
- Al Shammari, N.A.; AL-Niaeem, K.S.; and Al-Hawash, A.B. (2023). Molecular identification of some zoonotic bacteria isolated from fishes *Cyprinus carpio* L. and *Oreochromis niloticus* (L.) *J. Aquatic Biology & Fisheries*, 27(4): 1047 – 1062.
- Abdelsalam M.; Ewiss, M.A.Z.; Khalefa, H.; Mahmoud, M.A.; Elgendy, M. and Abdel-Moneam, D.A. (2021). Coinfections of *Aeromonas* spp., *Enterococcus faecalis*, and *Vibrio alginolyticus* isolated from farmed Nile tilapia and African catfish in Egypt, with an emphasis on poor water quality. *J. Microbial Pathogenesis*, 160.105213.DOI: 10.1016/j.micpath.2021.105213.
- FAO (2020). *The State Of World Fisheries and Aquaculture (SOFIA) 2020*. Rome: FAO.
- Mekasha, S. and Linke, D. (2021). Secretion Systems in Gram-Negative Bacterial Fish Pathogens. *J. Front Microbiol*, 12: 782673. doi: 10.3389/fmicb.2021.782673
- Mostafa, K. M.T. Islam, M.A. Sabur, M.M. Rashid, Experimental pathogenesis of *Aeromonas hydrophila* bacteria in shing *Heteropneustes fossilis* (Bloch), *Bangladesh J. Fish. Res.* 12 (1) (2008) 27–33. Mustafa, S.A (2020) Histopathology and heavy metal bioaccumulation in some tissues of *Luciobarbus xanthopterus* collected from Tigris River of Baghdad, Iraq, *The Egyptian Journal of Aquatic Research*, 46 (2): 123-129
- Mustafa, S.A (2020) Histopathology and heavy metal bioaccumulation in some tissues of *Luciobarbus xanthopterus* collected from Tigris River of Baghdad, Iraq, *The Egyptian Journal of Aquatic Research*, 46 (2): 123-129
- Molnár K.; Székely C.; Láng M (2019). Field guide to the control of warmwater fish diseases in Central and Eastern Europe, the Caucasus and Central Asia. In: *FAO Fisheries and Aquaculture Circular 1182*: FAO, Ankara
- Hossain S, Heo GJ (2021) Ornamental fish: a potential source of pathogenic and multidrug resistant motile *Aeromonas* spp. *Lett Appl Microbiol* 72:2–12. <https://doi.org/10.1111/lam.13373>
- Hossain, M.; Sun, D.; Donald J.; Shannon, M.; Alexander, W.; Martino, M.E.; Jeffery, Y. S.; Terhune, M and Liles, R. (2014) An Asian Origin of Virulent *Aeromonas hydrophila* Responsible for Disease Epidemics in United States-Farmed Catfish. *ASM J. mBio.* (5): DOI: <https://doi.org/10.1128/mbio.00848-14>
- Habte-Tsion, H-M (2020) A review on fish immuno-nutritional response to indispensable amino acids in relation to TOR, NF- κ B and Nrf2 signaling pathways: trends and prospects. *Comp Biochem Physiol B-Biochem Mol Biol* 241:110389. <https://doi.org/10.1016/j.cbpb.2019.110389>
- Said, AA, Reda RM, Metwally MMM, Abd El-Hady HM (2023) Therapeutic efficacy of coriander (*Coriandrum sativum*) enriched diets in *Oreochromis niloticus*: effect on hepatic-renal functions, the antioxidant-immune response and resistance to *Aeromonas veronii*. *Fish Physiol Biochem* 49:687–709. <https://doi.org/10.1007/s10695-023-01220-6>

- Youssef, A.; Dudhipala, N.; and Majumdar, S. (2020) Ciprofloxacin Loaded Nanostructured Lipid Carriers Incorporated into In-Situ Gels to Improve Management of Bacterial Endophthalmitis *Pharmaceutics* 2020, 12(6): 572.
- Youssef, H.A, Ayoub HF, Soror E-I, Matter AF (2023) Virulence genes contributing to *Aeromonas veronii* pathogenicity in Nile tilapia (*Oreochromis niloticus*): approaching the development of live and inactivated vaccines. *Aquacul Inter* 31:1253–1267. <https://doi.org/10.1007/s10499-022-01023-1>
- Zhao, C. Zhao, X. Li, J. Chen, Y. Liu, S. Fang, L. and Huo, Z. (2024) Intestinal Bacteria Community Structures of *Ruditapes philippinarum* and Their Correlation with Environmental Factors. *J. environmental and earth sciences*, 15:00:11: doi: 10.20944/preprints202403.0875.v1