



# Improvements in Some Physiological and Histologic Aspects in the Rat Model When Lipoic Acid is Combined with Salbutamol

HUDA K. KHASSAF<sup>1\*</sup>, ZAINAB A.H. AL-MOUSAWI<sup>1</sup>, SAWSAN A. ALI<sup>2</sup>, ANWAR NATHER SEIWAN<sup>3</sup>

<sup>1</sup>Department of Physiology, Pharmacology and Biochemistry, College of Veterinary Medicine, University of Basrah, Iraq; <sup>2</sup>Department of Anatomy and Histology, College of Veterinary Medicine, University of Basrah, Iraq; <sup>3</sup>Department of Biology, College of science, University, Basrah, Iraq.

**Abstract** | This rat model study investigated the effects of alpha-lipoic acid (ALA) and salbutamol (SAL) on many blood thyroid hormones and electrolytes. A total of forty rats, weighing between 200–250 g at the beginning, were divided into three experimental groups at random: the control group, the SAL group which was given (80 mg/kg) of SAL orally for two days, and SAL plus ALA groups which was given (80 mg/kg) of SAL orally for two days, followed by 20 mg/kg of oral ALA for 28 days. The levels of the hormones TSH, T4, free T3 and free T4 were estimated. Also, total bilirubin (TB), Na<sup>+</sup>, K<sup>+</sup>, Cl<sup>-</sup> and Ca<sup>2+</sup> were measured. A statistical analysis of the thyroid gland tissue's histological alterations was conducted. According to the findings, rats that got both SAL and ALA had higher levels of serum thyroxin T4, Free T3, and Free T4 than rats that did not get ALA ( $p < 0.05$ ). As well as decreased total bilirubin, Na<sup>+</sup>, and Ca<sup>2+</sup> levels and increased K<sup>+</sup> and Cl<sup>-</sup> levels ( $p < 0.05$ ). Furthermore, ALA is an effective therapeutic medication that improves the histological characteristics of the thyroid gland noticeably. The results of this study indicated that supplementing with ALA improved blood thyroid profiles more than SAL did, and that this may have the ability to prevent unwanted side effects.

**Keywords** | Alpha-lipoic acid, Salbutamol, Thyroid hormones, Histology, Rats

**Received** | December 21, 2023; **Accepted** | February 14, 2024; **Published** | March 01, 2024

\***Correspondence** | Huda K. Khassaf, Department of Physiology, Pharmacology and Biochemistry, College of Veterinary Medicine, University of Basrah, Iraq; **Email:** Huda.khassaf@uobasrah.edu.iq

**Citation** | Khassaf HK, Al-Mousawi ZA, Ali SA, SeiwAN AN (2024). Improvements in some physiological and histologic aspects in the rat model when lipoic acid is combined with salbutamol. *Adv. Anim. Vet. Sci.*, 12(5):844-848.

**DOI** | <https://dx.doi.org/10.17582/journal.aavs/2024/12.5.844.848>

**ISSN (Online)** | 2307-8316



**Copyright:** 2024 by the authors. Licensee ResearchersLinks Ltd, England, UK.

This article is an open access article distributed under the terms and conditions of the Creative Commons Attribution (CC BY) license (<https://creativecommons.org/licenses/by/4.0/>).

## INTRODUCTION

Salbutamol (SAL), a short-acting 2-adrenergic receptor agonist, has one chiral carbon atom (Figure 1). SAL is widely used to treat most bronchial asthma and bronchospasm disorders because of its excellent safety, low level of discomfort, and simplicity of administration (Brambilla *et al.*, 2000). Regrettably, there could be harmful health consequences if  $\beta_2$ -agonist residues from animal edible tissues accumulate in the human body through the food chain (Fraczek *et al.*, 2016; Hifumi *et al.*, 2014). Changes in thyroid hormones, such as a decreased T3 level,

are important predictors of disease prognosis, according to clinical trials of patients with various non-thyroid conditions (e.g., respiratory and heart failure) (Ichiki, 2010; Mancini *et al.*, 2016). The quantity of SAL that persists in the body is harmful to the animal's health, even though it is helpful commercially to enhance the animal's lean meat ratio. It is unknown if SAL has any negative effects on the bronchial morphology of the lung. Oxidative stress (OS) and inflammation are strongly connected processes, as demonstrated by obesity and cardiovascular disorders (Azab *et al.*, 2014). Reciprocally, OS and hormonal dysregulation are linked. Thyroid hormones are among the

many hormonal factors that affect the antioxidant balance, and they are particularly significant because OS has been linked to both hyperthyroidism and hypothyroidism in humans and animals (Sun *et al.*, 2012).

for 28 days. Blood samples from cardiac punctures were gathered after the trial and put into a gel tube for serum biochemical analysis.

### STATISTICAL ANALYSIS

All normally distributed data were reported as means ± SEM and were analyzed using the independent sample t-test and Pearson correlations, respectively, (SPSS, version 20.0, Chicago, IL, USA), to examine the differences in physiological and biochemical values for correlation analysis. When P < 0.05, the differences were deemed significant in Walters *et al.* (2021).

### HISTOPATHOLOGICAL ANALYSIS

Samples of tissue fixed thyroid were made in 10% neutral buffered formalin and paraffin. On glass slides, sectors with a thickness of 5 µm were placed, Xylene was used to deparaffinize them, and hematoxylin and eosin (H and E) stain was applied (Suvarna *et al.*, 2018).

## RESULTS AND DISCUSSION

### BIOCHEMICAL RESULTS

The current study's findings indicate that the SAL group had significantly higher levels of T4, free T3, and free T4 than the control group, while the ALA-treated groups saw significantly lower levels of hormone assay (p≤0.05) than the SAL group. As showing in Table 1.

**Table 1:** Hormonal analyzed for all experimental groups.

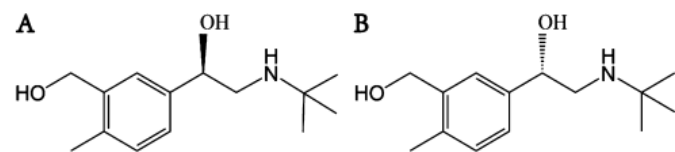
| Group   | TSH (µIU/ml)       | T4 (nmol/l)      | FreeT3 (pmol/l) | Free T4 (pmol/l) |
|---------|--------------------|------------------|-----------------|------------------|
| Control | 0.007a<br>±0.0008  | 32.53 b<br>±0.91 | 5.55 b<br>±0.54 | 6.05 c<br>±0.32  |
| SAL     | 0.0078a<br>±0.0007 | 39.36 a<br>±0.53 | 8.12 a<br>±0.28 | 8.71 a<br>±0.36  |
| SAL+ALA | 0.0061a<br>±0.004  | 33.34 b<br>±0.75 | 5.65 c<br>±0.32 | 7.75 b<br>±0.18  |

The small letter reveals significance between groups P≤0.05.

By the end of the trial, the SAL-treated group had increased K<sup>+</sup> and Cl<sup>-</sup> levels and had a statistically significant (p≤0.05) decrease in total bilirubin (TB), Na<sup>+</sup>, and Ca<sup>2+</sup> levels when compared to the control group. Conversely, the ALA-treated group exhibited significantly lower K<sup>+</sup> and Cl<sup>-</sup> levels (p≤0.05) and elevated TB, Na<sup>+</sup>, and Ca<sup>2+</sup> levels in comparison to the SAL group. As showing in Table 2.

### HISTOLOGICAL RESULTS

The gland is divided into round follicles by thin septa, or trabeculae, that extend to the parenchyma. The normal thyroid tissues in the control group revealed a gland composed of lobules surrounded by capsules, including fibrous connective tissue. Simple cuboidal epithelium



**Figure 1:** Chemical structure of (A) (R)-salbutamol and (B) (S)-salbutamol.

Because natural herbs have anti-inflammatory, antibacterial, anti-cancer, and antioxidant properties, their applications in medicine are steadily growing (Kim *et al.*, 2016). In a variety of in-vitro and in-vivo models, ALA has been shown to reduce the damage that oxidative stress causes to cells (Jung *et al.*, 2014; Prathima *et al.*, 2017). Because of its capacity to seek out free radicals and withstand the antioxidant defense mechanism of intrinsic cells, it also functions as an antioxidant (Jeong *et al.*, 2016). It has been found that ALA protects against radiation-induced thyroid gland (Zhang *et al.*, 2009), salivary gland (Chen *et al.*, 2011), and intestinal damage. Furthermore, ALA is a vital cofactor in biological systems and plays a crucial role in the metabolism of lipids and mitochondrial energy (Hamano, 2007; Zhang *et al.*, 2009; Kim *et al.*, 2011). These metabolic effects of ALA may also enhance pig development and lipid metabolism.

This study set out to determine if SAL alone or in combination with ALA may improve the alterations in blood thyroid hormone levels and the related profiles in rats.

## MATERIALS AND METHODS

### CHEMICALS

The following substances were acquired: Lipid profile (Spinreact/Spain), salbutamol (S.D.I. /Iraq), and alpha-lipoic acid (Neutec/ Turkey).

### EXPERIMENTAL DESIGN

Animals male Wister rats weighing 200–250 grams were kept in regular cages with free access to food and water on a schedule. The rats were split into three groups of six rats each for the first round of studies. These groups included:

- Control group was given normal saline
- SAL-treated group was given 80 mg/kg of SAL orally for two days in a row, followed by 28 days of normal saline.
- SAL-plus-ALA (20 mg/kg of oral SAL) group was given SAL for two days in a row, followed by ALA

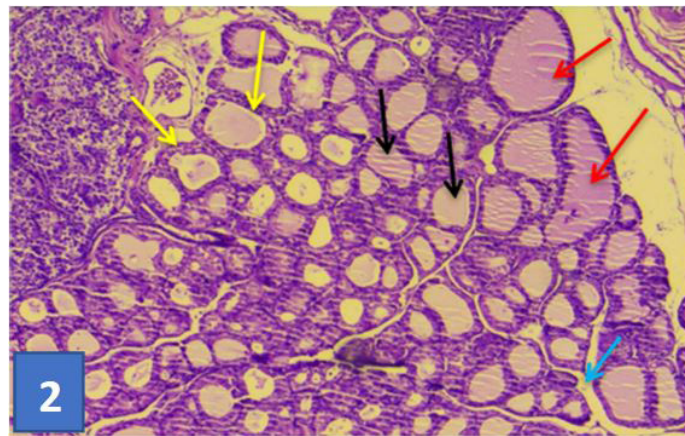


encircles the colloid-filled lumen of each thyroid follicle (Figure 2). The thyroid gland tissue of rat treated with SAL revealed disintegrated thyroid follicles, shrunken and atrophied with variable size and shape, in addition hyperemia between lining epithelium and degenerated follicular cells, hyperplasia of the lining epithelium; and more congested capillaries.

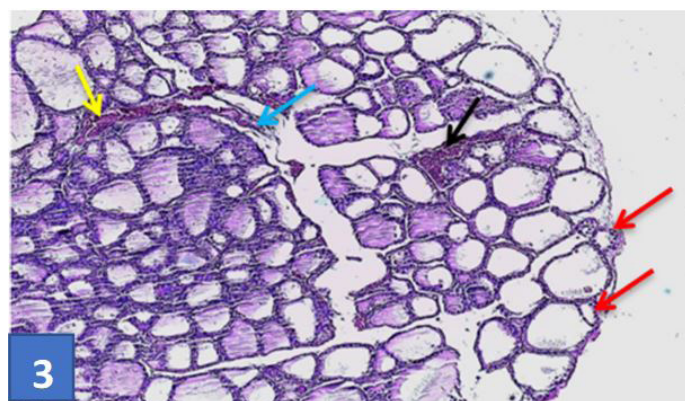
**Table 2:** Electrolytes analyzed for all experimental groups.

| Group   | TB (mg/dL)      | Na <sup>+</sup> (mmol/L) | K <sup>+</sup> (mmol/L) | CL <sup>-</sup> (mmol/L) | Ca <sup>2+</sup> (mg/dL) |
|---------|-----------------|--------------------------|-------------------------|--------------------------|--------------------------|
| Control | 0.213a<br>±0.28 | 149a<br>±1.67            | 5.08c<br>±0.13          | 97b<br>±4.87             | 10.1a<br>±0.39           |
| SAL     | 0.09c<br>±0.36  | 139c<br>±0.64            | 4.24a<br>±0.18          | 101.5a<br>±10.51         | 7.76c<br>±0.16           |
| SAL+    | 0.153b<br>±0.06 | 147b<br>±0.59            | 4.67b<br>±0.06          | 97.4b<br>±1.43           | 9.24b<br>±0.38           |
| ALA     |                 |                          |                         |                          |                          |

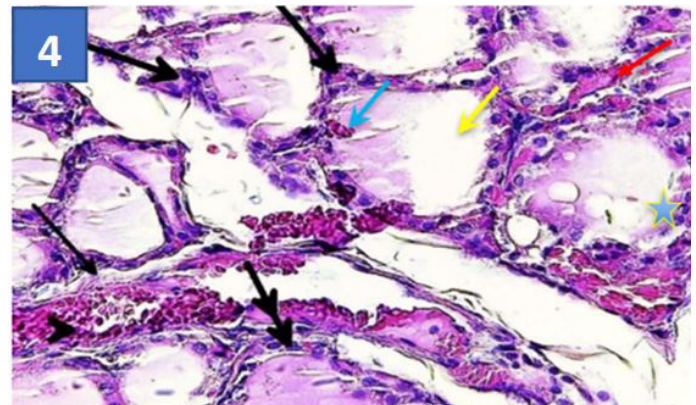
The small letter reveals significance between groups P≤0.05.



**Figure 2:** Section of thyroid gland of control group: showing normal histological appearance of follicles (red darts) of different size lining with simple epithelial (yellow darts), colloid substance (black darts), this connective tissue septa separated gland lobules (blue dart). (H & E) stain (10X).

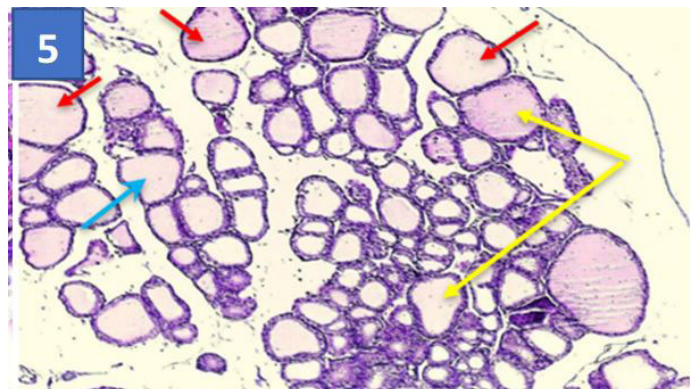


**Figure 3:** Section of thyroid gland treated by SAL: showing atrophied with shrinking follicles (red darts), congested large blood vessel (yellow dart), and hyperplastic changes (black dart) thickness of connective tissue separated the thyroid lobules (blue dart) (H & E) stain (10X).



**Figure 4:** Section of thyroid gland treated by SAL: Showing thickness of tissue separated of the lobules (black darts) moderate depletion of para follicular cell (thick arrows), scanty colloid (yellow dart) hyperemia between thyroid follicles (red dart), and between thyrocyte (blue dart), infiltrated of inflammatory cell around some follicles (double arrow), hyperplastic capillaries (arrow head) and intra-follicular hyperplasia (blue star) (40X).

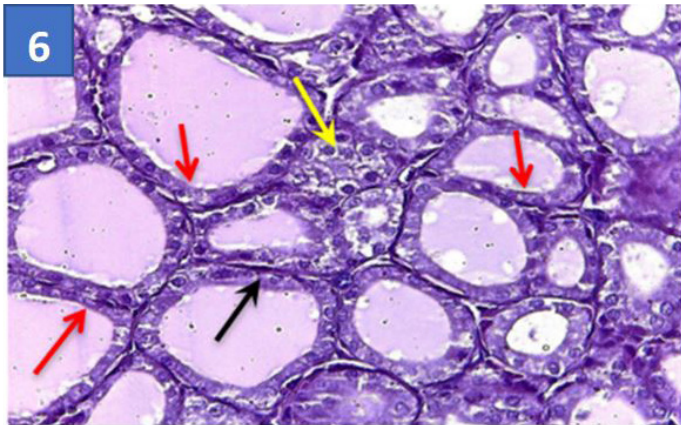
Moreover, the thyroid follicles' lumen appears empty of colloid or with scanty materials and connective tissues extending and separating the thyroid follicles, moderate depletion of the para-follicular cell (Figures 3, 4). While the observation of a section of the thyroid gland of a rat with SAL+ALA treatment showed clear regenerated follicles exhibiting normal size and shape lining with simple cuboidal epithelial cells, para-follicular cells among the follicles can be distinguished, as can mild hyperemia with rich colloid materials (Figure 5, 6).



**Figure 5:** Section of thyroid gland treated by SAL+ALA: showing more large regular follicles thyroid (red darts) follicles hyperplastic intra-follicular connective tissue (blue dart), some large follicle with partially amount of tissue (yellow darts) (H & E) stain (10X).

Owing to salbutamol's ability to increase the efficiency of animal production, an increasing number of researchers are concentrating on providing the industry with positive production benefits. However, the question remains as to what the drawbacks of this industry trend are and how they might be mitigated.





**Figure 6:** Section of thyroid gland treated by SAL+ALA: Showing more improvement thyroid follicle wall lined with typical cuboid epithelial cells (red darts), with clear parafollicular cells (yellow darts), thin septa of collagen fibers between thyrocytes and follicles (black dart) (H & E) stain(40X).

Previous research from our lab and other groups has demonstrated that using ALA could improve rats' serum thyroid hormone levels and antioxidant capacity (Chen *et al.*, 2011). Therefore, adding ALA along with SAL may enhance growth performance, while the data is still inconclusive (Smith *et al.*, 2002). According to a previous study, thyroid hormones can regulate animal skeletal muscle growth by promoting nuclear accumulation and proliferation within skeletal muscle fibers (Qiao *et al.*, 2013). Therefore, the growth-promoting effects of SAL or SAL+ALA in rats may be partially explained by changes in thyroid hormone. In the current investigation, the blood thyroid hormones, including T3 and T4, were measured to investigate the association between animal growth and serum hormones. The findings demonstrated that rats given SAL alone had significantly higher serum levels of T3 and T4. Lower serum T3 and T4 levels may be the reason for decreased myofiber protein accretion and satellite cell proliferation (Hashem and Saad, 2022). The results of the trial showed that the ALA group's serum levels of T3 and T4 were significantly lower than those of the SAL groups. When the ALA group is compared to the other groups, there is a non-significant drop in the TSH serum level. Additionally, the ALA group's electrolyte level is getting closer to the control group's typical range. The study's findings were consistent with those of (Hashem and Saad, 2022) in that there was a considerable drop in T3 and a highly significant drop in T4. there was a highly substantial drop in T4 and a large decrease in T3. The research's noted modifications corresponded with those reported by (Abd Elazeem *et al.*, 2016).

## CONCLUSIONS AND RECOMMENDATIONS

The results of this research conveyed a significant rise in

the histologic pattern in salbutamol treatment and by its beneficial effects on both histological and functional aspects, this study concluded that alpha lipoic acid effectively treated thyroid gland lesions that resulted from SAL treatment. While further research is necessary to clarify the pathways behind ALA's effects, it might be a practical treatment option to save the thyroid gland. There is a need for more research and studies to demonstrate the impact of the increasing use of salbutamol in animal fattening and to find safe and harmless alternatives.

## ACKNOWLEDGMENTS

The Basrah University College of Veterinary Medicine faculty and staff, as well as the animal house staff, are deeply appreciated by the authors for their help and support.

## NOVELTY STATEMENT

This study used an experimentally trialed rat model to evaluate the therapeutic effects of alpha lipoic acid (ALA) in combination with SAL on thyroid hormones and tissue. When used as a medicinal treatment, ALA effectively improves the hormonal and histological characteristics of the thyroid glands.

## AUTOR'S CONTRIBUTION

The work that is being presented here was contributed by all of the authors. Every author has contributed to the study's conception and design, data collection, analysis and interpretation of the results, and writing of the report.

## ETHICAL APPROVAL

With IACUC ethical approval for animal 4/37 in 2024, this study was carried out in the animal house at the College of Veterinary Medicine, University of Basrah, Iraq.

## CONFLICTS OF INTEREST

The authors have declared no conflict of interest.

## REFERENCES

- Abd-Elazeem A, Mohammed MZ, Hassan IZHS (2016). Effect of experimentally induced hypothyroidism on the parotid gland of adult male albino rats and the possible role of thyroid hormone supplementation. *Br. J. Sci.*, 14 (1):19-36.
- Azab AE, Fetouh FA, Albasha MO (2014). Nephroprotective effects of curcumin, rosemary and propolis against gentamicin induced toxicity in guinea pigs: Morphological and biochemical study. *Am. J. Clin. Exp. Med.*, 2(2): 28–35. <https://doi.org/10.11648/j.ajcem.20140202.14>
- Brambilla G, Cenci T, Franconi F, Galarini R, Macri A, Rondoni F, Strozzi M, Loizzo A (2000). Clinical and pharmacological profile in a clenbuterol epidemic poisoning of contaminated

- beef meat in Italy. *Toxicol. Lett.*, 114: 47–53. [https://doi.org/10.1016/S0378-4274\(99\)00270-2](https://doi.org/10.1016/S0378-4274(99)00270-2)
- Chen P, Ma QG, Ji C, Zhang JY, Zhao LH, Zhang Y, Jie YZ (2011). Dietary lipoic acid influences antioxidant capability and oxidative status of broilers. *Int. J. Mol. Sci.*, 12: 8476–8488. <https://doi.org/10.3390/ijms12128476>
- Fraczek MM, Gackowski A, Przybylik ME, Jadwiga N. (2016). The relation between the low T3 syndrome in the clinical course of myocardial infarction and heart failure. *Polski Merkuriusz Lekarski J.*, 40: 380–383.
- Hamano Y (2007). Continuous infusion of lipoic acid rapidly reduces plasma beta-hydroxybutyrate with elevation of non-esterified fatty acids in broiler chickens. *Br. J. Nutr.*, 97: 495–501. <https://doi.org/10.1017/S0007114507381312>
- Hashem H, Saad S (2020). Comparative study of the effect of experimentally induced hyperthyroidism and hypothyroidism on the parotid gland in adult male albino rats. *Egypt. J. Histol.*, 43(3): 791–807.
- Hifumi T, Okada I, Kiri N, Eiju H, Tomoko O, Hiroshi K, Yuichi K, Junichi I, Yuko A, Kenya K, Masanobu H, Yasuhiro K. (2014). Thyroid hormone alterations in trauma patients requiring massive transfusion: An observational study. *World J. Emerg. Med.*, 5: 270–274. <https://doi.org/10.5847/wjem.j.issn.1920-8642.2014.04.005>
- Ichiki T (2010). Thyroid hormone and atherosclerosis. *Vascul. Pharmacol.*, 52: 151–156. <https://doi.org/10.1016/j.vph.2009.09.004>
- Jeong BK, Song JH, Jeong H, Choi HS, Jung JH, Hahm JR (2016). Effect of alpha-lipoic acid on radiation-induced small intestine injury in mice. *Oncotarget.*, 7(12): 15105. <https://doi.org/10.18632/oncotarget.7874>
- Jung JH, Jung J, Kim SK, Woo SH, Kang KM, Jeong B-K (2014). Alpha lipoic acid attenuates radiation-induced thyroid injury in rats. *PLoS One*, 9(11): e112253. <https://doi.org/10.1371/journal.pone.0112253>
- Kim JH, Kim KM, Jung MH, Jung JH, Kang KM, Jeong BK (2016). Protective effects of alpha lipoic acid on radiation-induced salivary gland injury in rats. *Oncotarget*, 7(20): 29143. <https://doi.org/10.18632/oncotarget.8661>
- Kim MY, Kim EJ, Kim YN, Choi C, Lee BH (2011). Effects of  $\alpha$ -lipoic acid and L-carnosine supplementation on antioxidant activities and lipid profiles in rats. *Nutr. Res. Pract.*, 5: 421–428. <https://doi.org/10.4162/nrp.2011.5.5.421>
- Mancini A, Di Segni C, Raimondo S, Olivieri G, Silvestrini A, Meucci E (2016). Thyroid hormones, oxidative stress, and inflammation. *Mediators Inflamm.*, 2016: 6757154. <https://doi.org/10.1155/2016/6757154>
- Prathima P, Venkaiah K, Pavani R, Daveedu T, Munikumar M, Gobinath M (2017).  $\alpha$ -lipoic acid inhibits oxidative stress in testis and attenuates testicular toxicity in rats exposed to carbimazole during embryonic period. *Toxicol. Rep.*, 4: 373–381. <https://doi.org/10.1016/j.toxrep.2017.06.009>
- Qiao X, Zhang HJ, Wu SG, Yue HY, Zuo JJ, Feng DY, Qi GH (2013). Effect of  $\beta$ -hydroxy- $\beta$ -methylbutyrate calcium on growth, blood parameters, and carcass qualities of broiler chickens. *Poult. Sci.*, 92: 753–759. <https://doi.org/10.3382/ps.2012-02341>
- Smith JW, Evans AT, Costall B, Smythe JW (2002). Thyroid hormones, brain function and cognition: A brief review. *Neurosci. Biobehav. Rev.*, 26: 45–60. [https://doi.org/10.1016/S0149-7634\(01\)00037-9](https://doi.org/10.1016/S0149-7634(01)00037-9)
- Sun LQ, Chen YY, Wang X, Li XJ, Xue B, Qu L (2012). The protective effect of alpha lipoic acid on Schwann cells exposed to constant or intermittent high glucose. *Biochem. Pharmacol.*, 84(7): 961–973. <https://doi.org/10.1016/j.bcp.2012.07.005>
- Suvarna KS, Layton C, Bancroft JD (2018). Bancroft's theory and practice of histological techniques E-Book. Elsevier Health Sciences.
- Walters SJ, Campbell MJ, Machin D (2021). Medical statistics: A textbook for the health sciences. John Wiley and Sons.
- Zhang Y, Hongtrakul K, Ji C, Ma QG, Liu LT, Hu XX (2009). Effects of dietary alpha-lipoic acid on anti-oxidative ability and meat quality in arbor acres broilers. *Asian Australas. J. Anim. Sci.*, 22: 1195–1201. <https://doi.org/10.5713/ajas.2009.90101>