

Original Article

Anatomical, Histological, and Immunohistochemical Description of the Abomasum in One-Humped Adult Camel (*Camelus dromedary*) in the South of Iraq

Salan, Z, A¹*, Ali, S. A¹, Sadoon, A. H²

1. Anatomy and Histology Department, College of Veterinary Medicine, University of Basrah, Basrah, Iraq
2. Veterinary Anatomy and Histology Department, College of Veterinary Medicine, University of Basrah, Iraq

Received 18 July 2022; Accepted 10 September 2022
Corresponding Author: zainab.ali.salan92@gmail.com

Abstract

The camel is an important mammal, especially in the Middle EAST, although it has received less attention than other mammals and ruminants. Due to the lack of studies in this field, the current research was designed to investigate the morphological, histological, and immunohistochemical of one-humped camel's stomach. In this study, the third chamber (abomasum) of the stomach in adult one-humped camels (*Camelus dromedaries*) were evaluated (n=12). The morphological study of the third chamber showed that it consisted of two parts, the letter J, where the front part was found to be tubular, the outer surface is smooth, swollen, and transparent, while the inner surface has longitudinal folds with a low height. The posterior part is spherical, and the inner surface is divided into two regions. Histological study showed that the abomasum consists of four layers and is lined with simple columnar epithelium. The lamina property is composed of loose connective tissue. It contains different glands that, according to their location from the abomasum, where cardiac, Fundus, and pyloric glands are found, as well as stomach cells such as neck cells, mucous cells, chief cells, and parietal cells. In contrast, the sub mucosa layer is composed of loose connective tissue. It was also observed that the muscular layer is developed and contained from two layers, a circular inner and the outer one is longitudinal. It was also noted that the fourth layer is composed of loose connective tissue. The histochemical study showed a positive response to the PAS reagent.

Keywords: Digestive system, Camelidae, Ruminants

1. Introduction

The camel is an important mammal, especially in the Middle EAST, although it has received less attention than other mammals and ruminants. Camels are divided into two types: the humped Dromedary (*Camelus dromedarius*) and the humped Bactrian (*Camelus bactrianus*) (1). Ruminants and camels are animals that have several compartments in their stomachs (2). Ruminants' stomachs have four compartments, while camelids' stomachs have three macroscopically abomasa consisting of only two regions: the fundus region with thick longitudinal folds and the pyloric

region with smooth lining (3). Histologically abomasum was divided into four regions, cardiac, pseudo cardiac, Fundus, and pyloric (1, 4).

The abomasum (actual stomach) is the fourth part of the stomach, and it is the first glandular part of the digestive system of ruminants, and it is bean-shaped and smaller than compartment 3 and divided into fundic and pyloric areas. The epithelium of the abomasum consists mainly of two glandular regions, equivalent to the fundus gland region in other ruminants (5).

In immunohistochemistry, gastrointestinal and endocrine cells are mainly distributed through

gastrointestinal walls and enteroendocrine cells (6). A researcher conducted by Abdellatif (7) showed that the location and distribution of endocrine cells in the digestive system are mainly located within the islets of the pancreas and throughout the wall of the stomach and intestines. These cells regulate many of the body's functions by secreting hormones. Synaptophysin is a transmembrane glycoprotein that is expressed in nearly all types of endocrine cells as well as in synaptic vesicles; the results of a study conducted by Lehmann and Beglinger (8) showed that Gastrin-releasing peptide (GRP) is an enteric hormone, isolated from the stomach of pigs, which can increase plasma gastrin levels and now the presence of GRP has been detected in nerve fibers in noncentral gastric tissue.

Due to the lack of studies in this field, the current research was designed to investigate the morphological, histological, and immunohistochemical of one-humped camels' stomachs.

2. Materials and Methods

2.1. Sample Collection and Preparation

Twelve samples were isolated from the abomasum in the stomach of the camel from adult males; their ages ranged from 5-10 years; the samples were collected from the Basrah governorate from the modern Zubair slaughterhouse.

The samples were taken immediately after slaughter, where anatomical measurements and weights were taken and then cut into approximately 1×1.5 cm pieces for histological examination.

Following sample washing with distilled water for the following fixation, the samples were placed in formalin at a rate of 10% for 24 hours (9).

2.2. Immunohistochemistry

Immunohistochemistry tests were performed to identify endocrine cells within the abomasum and distinguish them from exocrine cells; descending degrees of ethanol and paraffin slices were deparaffinized in xylene and rehydrated. Antigenic epitopes were extracted by boiling the sections in 10

mm citrate solution (pH 6.0) for 25 minutes in a microwave at 750 watts. Endogenous peroxidase activity was inhibited by incubating tissue slices for 20 minutes at room temperature in a 0.3 percent hydrogen peroxide solution (RT). Before applying the primary antibody, slices were washed in phosphate-buffered saline and then incubated in 10% donkey serum for 1 hour at room temperature to inhibit non-specific binding.

After that, the blocked sections were treated with rabbit anti-synaptophysin monoclonal antibody. Three hours at room temperature (BioGenex, CA, USA). The primary antibody was replaced with a blocking buffer for the negative control sections.

For 30 minutes, each section was treated with biotinylated donkey anti-rabbit secondary antibody (Jackson ImmunoResearch, PA, USA) and VECTASTAIN Elite ABC kit (Vector labs, CA, USA). Incubation of stained sections with diaminobenzidine solution (Sigma-Aldrich, MO, USA) for 5-10 minutes revealed bound antibodies. Using a Leica DM3000 light microscope, all slices were counterstained with hematoxylin and photographed (10).

3. Results

The study was designed to show the stomach's appearance, size, shape, and natural position (abomasum) in adult camels in south Iraq. The shape of the abomasum in camels is similar to a letter (J) (Figure 1). The Cranial part is tubular and smooth, and it corresponds to the omasum in ruminants, and the caudal part is dilated, resembling a ball, corresponding to the abomasum in ruminants and the stomach in simple stomach animals. This compartment is located in the abdominal cavity opposite the rumen, dorsally to the liver, and ventrally to the intestine. Also noted is that the inner surface of the abomasum in camels is that the tubular part is lined with parallel longitudinal folds (Figure 2). The caudal part of the stomach (actual stomach) in camel, as for the inner surface, the camel's abomasum caudal part was found to contain two

regions anatomically different in shape and color. The Fundus and pyloric region of the abomasum posteriorly connect to a thin bulge. The folds change from longitudinal folds in the cardiac region to thick brown

longitudinal folds in the cardiac region to thick brown

longitudinal folds that extend between them (Figures 3 and 4). Table 1 shows Anatomical morphometric measurements of the abomasum in camels (*Camelus dromedaries*).

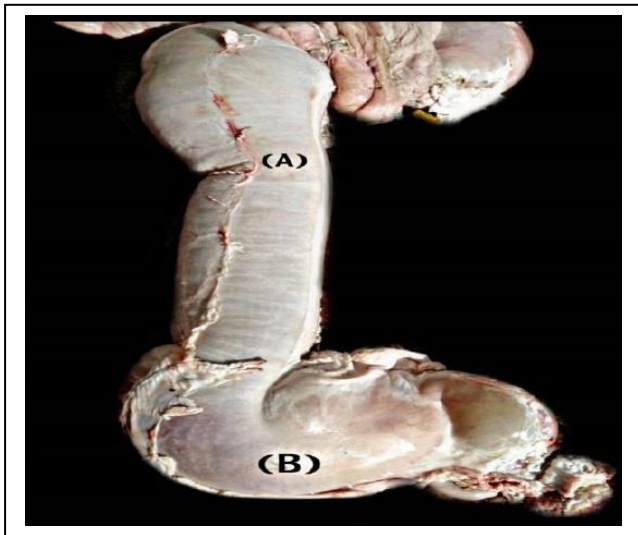

Figure 1. A. Cranial part of abomesum (tubular abomesum)
B. Caudal part of abomesum (true stomach)

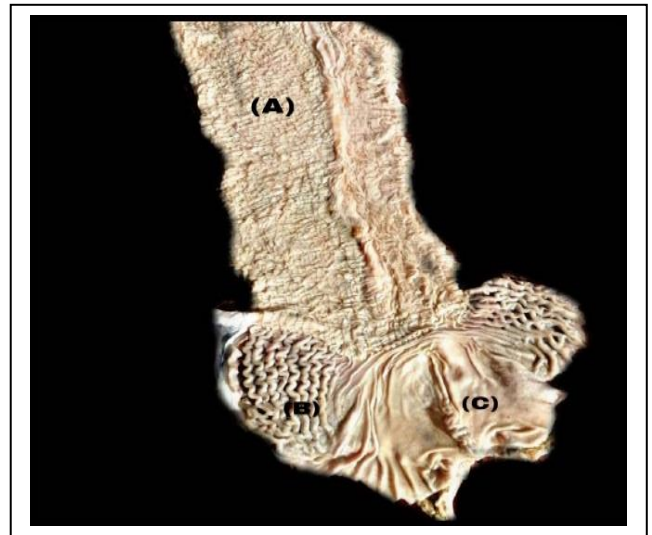

Figure 3. Internal surface of abomasum show A) Cardiac region (cranial abo, B) fundus region, C) pyloric region (caudal abomasum)

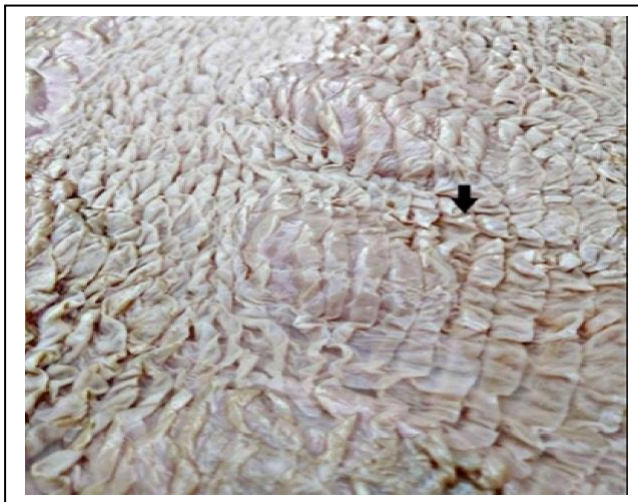

Figure 2. Internal surface with longitudinal fold in the tubular abomasum

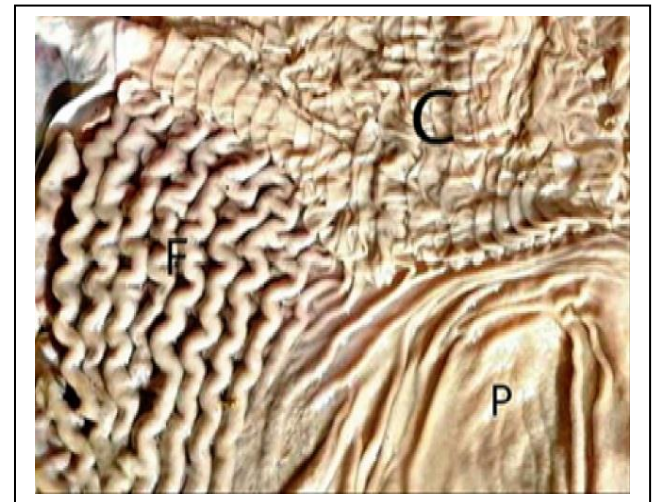


Figure 4. Internal surface of abomasum shows C) cardiac region, F) fundus region, P) pyloric region

Table 1. Morphometric Measurements of Abomasum

| Age of camels (years) | Cranial part | | | Caudal part | | |
|-----------------------|--------------|------------|-----------|--------------|------------|-----------|
| | Length | Width | Wight | Length | Width | Wight |
| (5-7) | 56.55±0.69 | 15.35±0.48 | 0.98±0.48 | 24.45±48.287 | 16.13±0.23 | 0.85±0.07 |
| (7-10) | 66.78±1.23 | 18.68±0.52 | 1.55±0.05 | 27.88±0.59 | 18.98±0.39 | 1.43±0.08 |

*Different litters in the same column mean significant difference $P < 0.05$

The histological study of the camel abomasum showed that it consists of four layers that start from the inside towards the outside, mucosa, submucosa, muscular, and serosa. It was observed during the current study that the abomasum of camels consists of two parts, an upper tubular part (cardiac) and a spherical lower part that contains two parts of the Fundus and pylorus, where there is no separation between the three areas of the stomach.

3.1. Cardiac Region

Mucosa layer composed of a superficial columnar epithelial tissue comprising one layer of columnar cells stacked with each other. It was also observed that the cytoplasm of these cells is pale, and the nucleus is dark with a basal location. It also appeared in dark blue when stained with Masson Trichrome to detect the collection fiber in this region, and detector PAS is positively shown in figure 5. The lamina propria; consists of loose connective tissue and some reticular and colloid fibers, as well as the presence of collagen fibers that overlap with each other. It was also noted that the spindle-shaped fibroblast is heterogeneous, with a lot of dark spherical cells, which are lymphocytes, as well as the presence of some blood vessels of different diameters and capillaries Muscularis mucosa: This layer was observed in the form of thin bundles of smooth cells that were immersed within the loose connective tissue. Submucosal layer: It is the second layer, where it was noted that it consists of loose connective tissue and a group of fibers, some blood vessels, lymphocytes, and the Meissner's nerve plexus. The muscularis this layer appeared in the form of smooth muscle bundles. Two layers of the muscular bundles, the first circular and the second longitudinal, can also be noted: connective tissue between these muscle bundles. Capillary blood vessels, fibroblast cells, and other types of cells, such as fatty and lymphatic, and Aurbach's nerve plexus can be observed. The serosa layer is the last layer surrounding the three mentioned layers. It shows a dark blue coloration when stained with Masson, in addition to the presence of blood vessels in different diameters. It was also noted that they are surrounded by a layer of squamous cells (mesothelium) shown in figure 6.

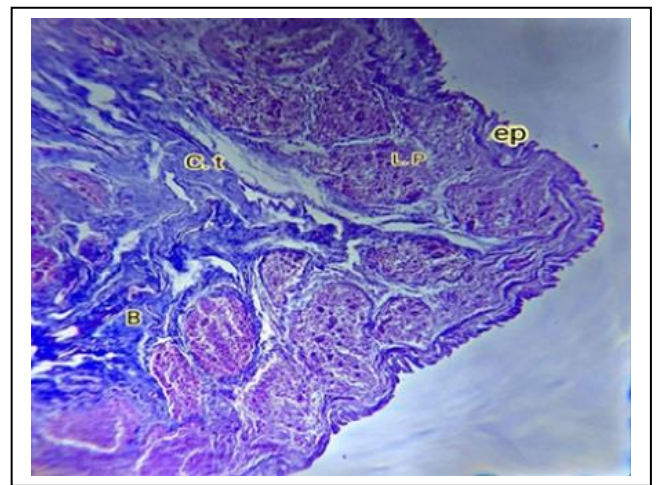


Figure 5. Cross-section of cardiac region shows (ep) simple columnar epithelium, (L. P) lamina propria with glands, (c. t) connective tissue (B) blood vessels (mason trichrom x100)

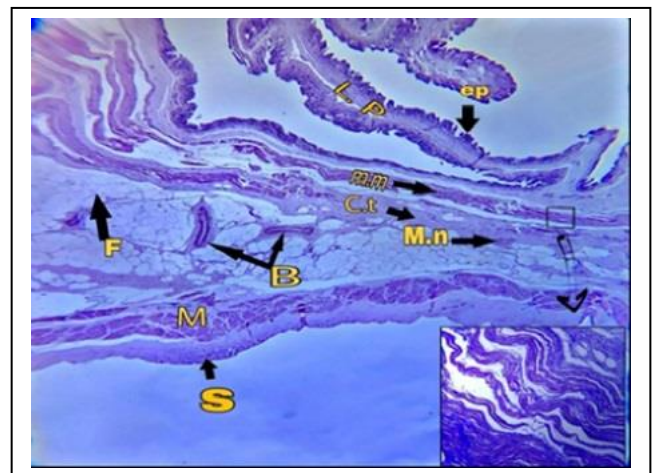


Figure 6. cross-section of cardiac region shows (ep) simple columnar epithelium, (L. P) lamina propria with glands, (c. t) connective tissue, (B) blood vessels, (F) fat tissue, (mm) muscularis mucosa, (M. n) Meissner's nerve plexus, (M) muscularis, (S) serosa layer (H&E x40)

Abomasum consists of its two regions, cranial and caudal, as it was divided according to the presence and types of glands in the lamina propria. The cardiac region is distinguished by the presence of two types of glands, large and small; the large, including elongated cells and spherical nuclei in the center, and the other are small in size, their cells are cubic, and their nuclei are flat in the center show figure 7.

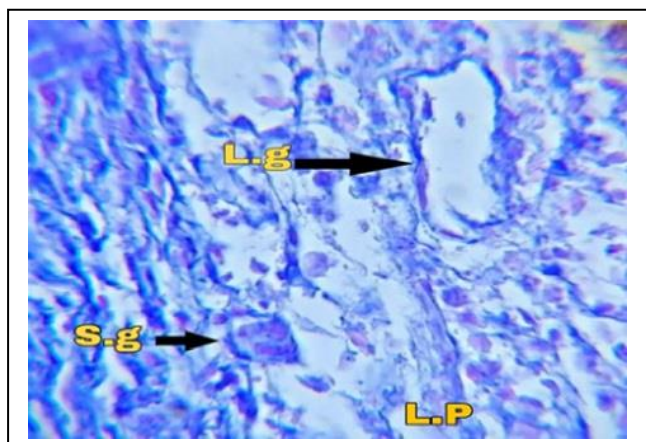


Figure 7. Cross-section of lamina propria of cardiac region show: (L. g) large gland, (S. g) small gland ((mason tryicrom x1000)

The caudal part of the abomasum showed during the current study that this region consists of two parts.

3.2. The Fundus Region

The tissue sections showed that it has high longitudinal folds compared to the other part, where the present study observed these two regions showed that it is lined with simple columnar epithelium where it was noted that the lamina propria is composed of simple branched tubular glands, and it is the fundus glands that these glands consist of columnar cells with flat nuclei at the base, where these glands proved a positive response to the detector PAS reagent show figure 8. Types of cells in this region: Surface mucus cells: They are located in the cervical region of the lamina propria; chief cells: these cells appeared in the form of a cuboid; parietal cells could be seen through this region, showing that these glands start from the fundus region and extend some of them to the glands between the Fundus and pyloric regions, enteroendocrine cell their cells were characterized by small in size located in the base of gastric bit and the nucleus located in the apex of cell (Figure 9).

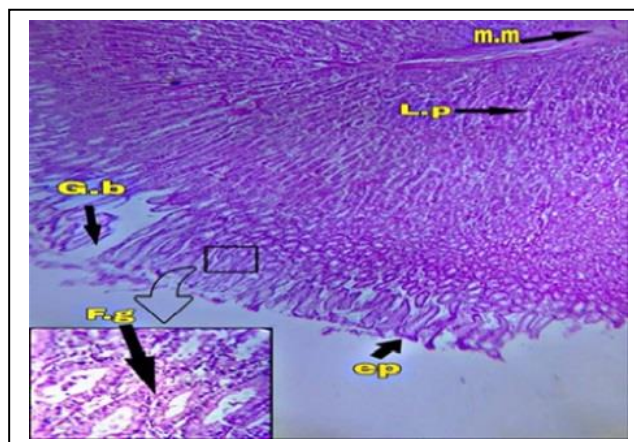


Figure 8. Cross-section of fundus region show: (mm) muscularis mucosa, L. p) lamina propria (g.b) gastric pit, F. g) fundus gland. (ep) simple columnar epithelium (H&E x40)

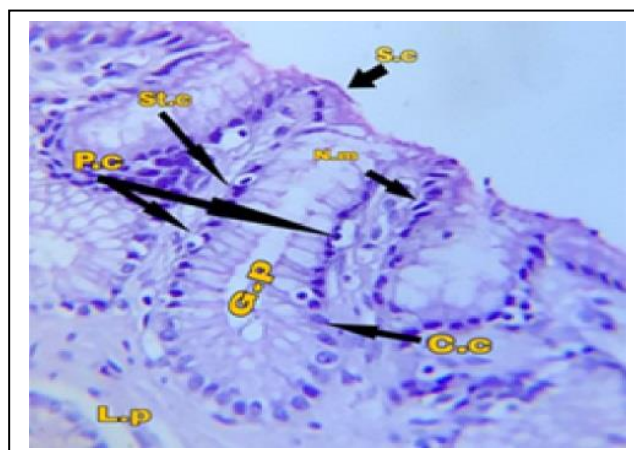


Figure 9. Cross-section of lamina propria of fundus region show: (s. c) surface mucus cell, (N. m) nech mucus cell, (st. c) stem cell, (p. c) parietal cell, (c. c) chief cell, (G. P) gastric pit (H&E x400)

3.3. Pyloric Region

A histological examination of the stomach showed the pyloric region. This region is characterized as being smooth compared to the fundus region And lined with epithelium similar to the cardiac and fundus region; the glands appeared in a small percentage of branching, which is pyloric glands show figure 10 Where long pyloric glands appeared, and it was noted that their lumen was more expansive than their counterparts in the fundus glands, which showed a positive interaction with the reagent (PAS) (Figures 11 and 12).

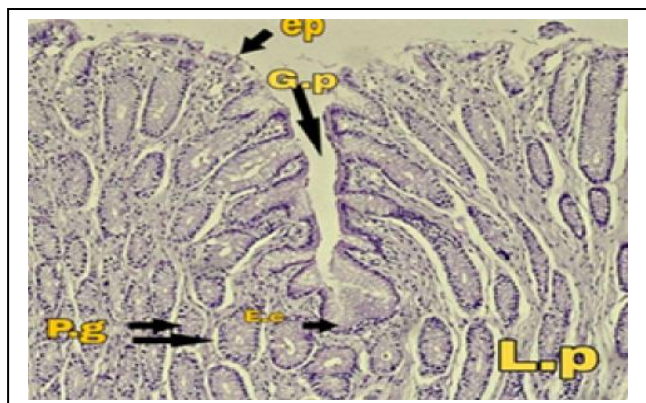


Figure 10. Cross-section of pyloric region show: (G. p) Gastric pit, (ep) epithelium, (E. c) enteroendocrine cell, (p. g) pyloric gland, (L. P) lamina propria (PAS x100)

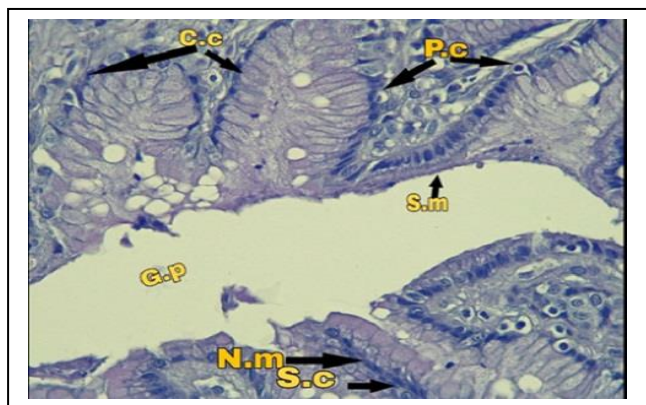


Figure 11. Cross-section of lamina propria of fundus region show (c. c) chief cell, (p. c) parental cell, (s. m) surface mucus cell, (G. p) gastric pit, (N. m) neck mucus cell (PAS properia (PAS x100)

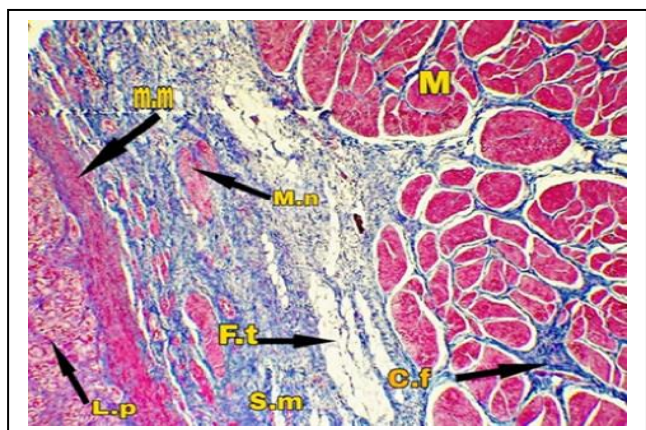


Figure 12. Cross-section of lamina propria of fundus region show: (L. p) lamina propria, (m. m) muscularis mucosa, (s. m) submucosa, (m. n) Meissner's nerve plexus, (M) muscularis, (F. t) fat tissue, (c. f) collagen fiber (mason trycrom x40)

3.4. Immunohistochemistry

The stomach of the one-humped camel in southern Iraq contains many endocrine glands. This study observed two types of glands for the last part of the abomasum. The distribution of cells within the stomach wall was studied, and the results were as follows:

3.4.1. Distribution of Cells

Synaptophysin-immunoreactive (syp-IR): Inside the abomasum wall, the distribution of these cells in the three regions of Cardiac, Fundus, and pyloric regions were studied. The cardiac region where no immunoreaction of syp-IR cells was observed in the cardiac abomasum region in the lamina propria layer, nor in the cardiac glands and on the epithelium of the region, but it can be observed that some cells are present in tiny quantities in the structures of neurons in the submucosal layer as well as their appearance in a medium to moderate form. The density in the muscle layer within the nerve fibers and nerve endings, where these cells are among the cells located in different layers of the wall of the abomasum (Figure 13).

The fundus region: where a wide spread of syp-IR cells can be observed at the base of lamina propria and less in the epithelium region where they cannot be observed within the gastric pit. It can also be observed at the bases of the fundus glands in addition to their presence in small numbers in the submucosal layer in the nervous structures. Their numbers range from low to moderate in the muscle layer at the ends of the nerve fibers (Figure 14).

The pyloric region: Medium to moderate immunoreaction can be observed; its presence is concentrated at the base of lamina propria and decreases towards the top, absent in the gastric pit (Figure 15). Also, SYP-IR immune cells can be observed in the submucosal layer in the nervous structures, in addition to its presence within the nerve fibers of the muscle layer in the form of immune activity low to Moderate, as in figures 16 and 17.

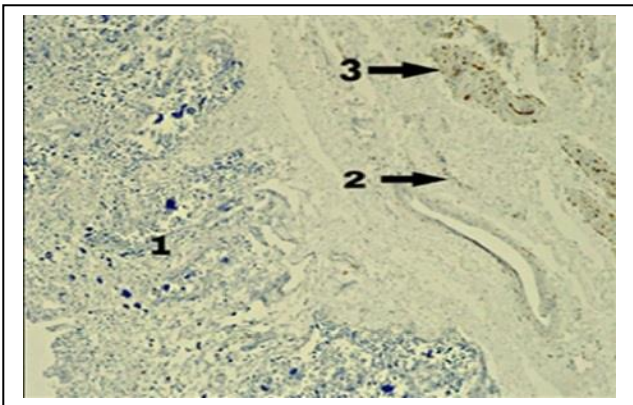


Figure 13. Shows the distribution of (syp – IR) in the cardiac region shows negative immunoreaction in lamina propria (1), low immunoreaction of (syp-IR) in the submucosa layer (2), moderate immunoreaction in the muscularis layer (3) (syp-IR x40)

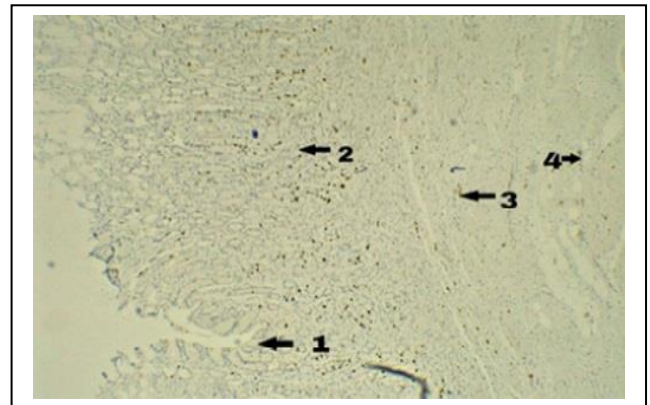


Figure 16. Pyloric region show distribution of synaptophysin cell (1) negative immunoreaction in the epithelium and gastric pit, (2) positive result low to moderate immunoreaction of syp-IR in the gastric gland, (3) low distribution of synaptophysin cell in the submucosa and muscularis (syp-IR x40)

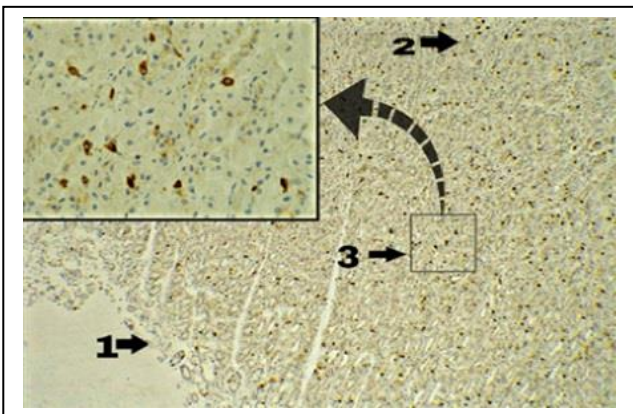


Figure 14. Shows the distribution of (syp-IR) in the fundus region, showing positive immunoreaction in lamina propria; (1) low to the absence of SYP-IR in the epithelium and gastric pit, (2) high to moderate SYP-IR in the base of lamina peoperia, (3) high to moderate of the gastric gland (syp-IR x40)

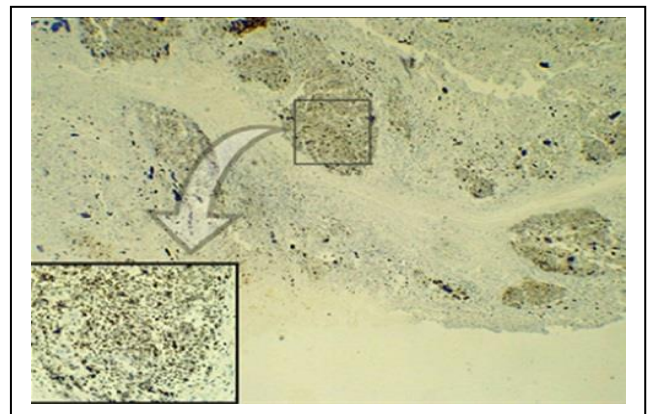


Figure 17. Show positive immunoreaction of the cardiac region of the abomasum in the camel, show the high distribution of gastrin cell in some area and low in other areas in lamina propria, and no immune reactive show in the submucosa and muscularis (GSR-IR x40)

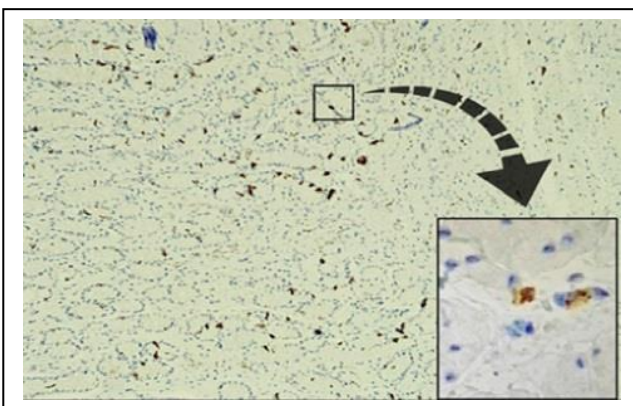


Figure 15. the pyloric region of the abomasum in the camel show positive immunoreaction (low to moderate) distribution of synaptophysin cell in lamina propria and pyloric gland (syp-IR x100)

3.5. Gastrin-Immunoreaction (GSR-IR)

The presence and distribution of gastrin gland cells in the abomasum wall of the camel were studied, and the following was observed:

3.5.1. Cardiac Region

In the cardiac region, gastrin cells in the abomasum wall can be discreetly observed in areas of the stomach, while it is reduced or absent in another area adjacent to it, where it forms intense gatherings of these cells in the lamina propria layer.

Its density is concentrated in a specific area within the cardiac glands in the lamina propria, while no immune activity can be observed in the

other areas of the same layer (Figure 18). Also, no immune activity was observed in the presence of gastrin glands in both the submucosal and muscularis layers.

3.5.2. Fundus Region

As for the fundus region, we notice a very high density of gastrin in the layer lamina properia, and its density is concentrated at the base of lamina properia and gradually decreases towards the top, where it is low to moderate in the middle region in lamina properia and is concentrated at the bases of the fundal glands while it decreases towards the top to be absent in the lining of the region fundus (Figure 19). Also, no immune activity of gastrin glands was observed in the submucosal and muscular layers (Figure 20).

3.5.3. Pyloric Region

As for the pyloric region, we did not observe any immune activity of gastrin glands in this region, where we recorded low to no immune activity in the lamina properia layer. We also did not notice these glands in the submucosal or muscularis layer (Figure 20).

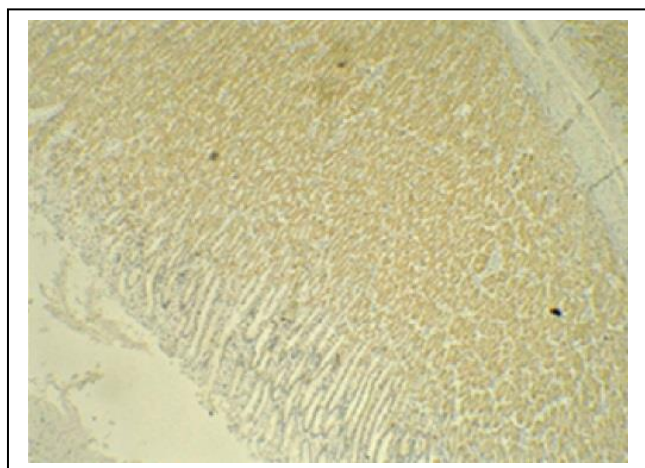


Figure 18. Positive immunoreaction (syp-IR) in the fundus region shows the high distribution of gastrin gland in lamina properia and fundus gland (1), and no immunoreaction in the epithelium and gastric pit (2), negative gastrin -IR in the submucosa (GSR-IR x40)

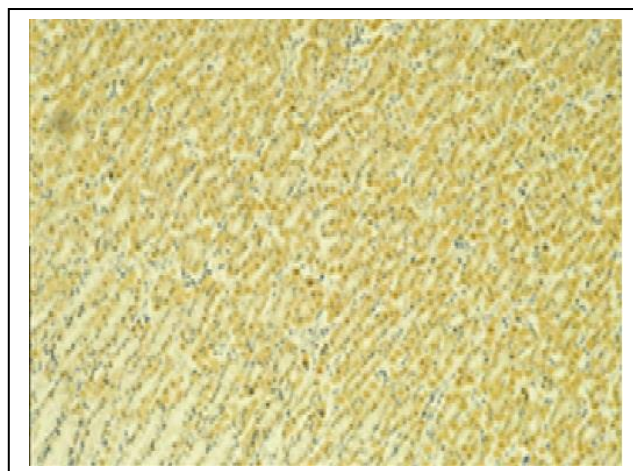


Figure 19. The fundus region of the abomasum in the camel show the high distribution of gastrin cell in the fundus gland (1) and moderate to weak the epithelium and the gastric pit (2) (GSR x100)

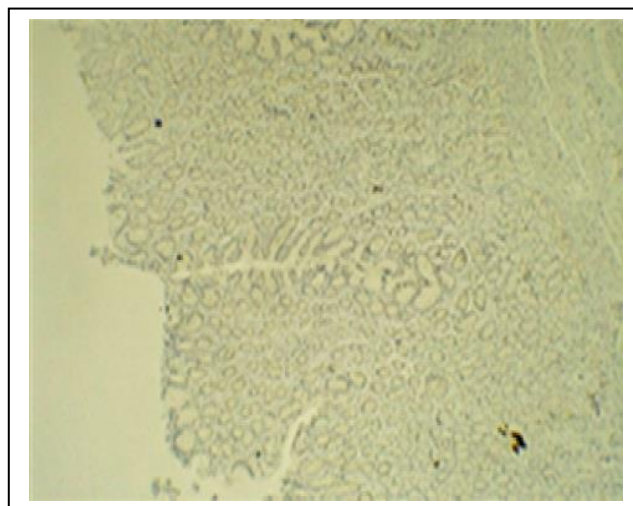


Figure 20. The pyloric region of the abomasum in the camel show negative immunoreaction in lamina properia and submucosa (GSR x40)

4. Discussion

The current study showed that the abomasum in a one-humped adult camel resembles the (J) letter. It was found that the cranial part connects with the reticulum, which is called the cardiac part, while the posterior dilatation is called the actual stomach, which consists of the fundus part and pyloric, and this is close to the

description of the researcher Raji (11), but it contradicts the description of both researchers Ibrahim, Radwan (12) and Kareshk, Oliaee (3), who described this part on omasum and classified it as a separate part of the abomasum, who classified it as a separate chamber, where the study found that this area belongs to the abomasum and is not considered omasum, and that the camel lacks its paper, and that The omasum in ruminants is located between the reticulum and the abomasum, as stated in Pelagalli (13) research on the stomach of a buffalo, where the omasum was described as containing (100 platelets) and small papillae spread on its surface, Caudal abomasum.

The current study showed an enlarged part that complements the tubular part; it has a smooth dorsal surface and a curved inner surface, and no boundaries were observed separating it from the tubular part, so it was not considered a separate chamber and considered a part of the abomasum, and this matches what was described by each of the researcher Raji (11) in his study on morphological and histochemical investigation of the camel, and this was not observed in this part of the camels. It was also noted that this region of the abomasum is similar to the simple stomach, as the length of this part (24.45 ± 0.48), (27.88 ± 0.59) cm and width (16.13 ± 0.23), (18.98 ± 0.39), and weight (0.85 ± 0.07), (1.43 ± 0.08) Kg.

It differs from what Kareshk, Oliaee (3), and Ibrahim, Radwan (12) mentioned, and it may be due to the type of forage that the animal feeds on and the nature of the area.

The current study showed that the anterior part of the opposition is called the cardiac, as it was found to be lined with simple columnar epithelium, lamina propria composed of loose connective tissue containing as shown on the number of tubular glands, it gave a positive reaction of the detector (PAS), and this is consistent with the studies of the researchers, as Abdel- Magied and Taha (1) considered that the anterior region of the abomasum, It was also revealed the presence of large numbers of simple tubular cardiac

glands this is confirmed by the researcher Jarrar and Faye (14).

The mucosal muscular layer appeared clear arranged parallel to the mucous layer, which was found in the form of tissue, and these results are consistent with the results of Kareshk, Oliaee (3). The muscle layer also appeared similar to what the researchers described. Kareshk, Oliaee (3) confirmed that it consists of two layers, the first circular and the other longitudinal, interspersed with different fibers. It was also shown that it differs from leaf and reticulum in ruminants (13). In ruminants, the leaf lining is lined by stratified squamous epithelium, and lamina propria does not have any glands.

The current study showed that this area is lined with simple columnar epithelium. This area was divided into two areas, in addition to a meeting area between the anterior and posterior segments.

Furthermore, here is the Fundus, pyloric, and part of the cardiac, which corresponded to the studies of researchers Abdel- Magied and Taha (1), where the cardiac tissue first part belonged to an area and was found that contains several cardiac glands, while the other part it contains the fundus glands, and the last part contains the pyloric glands, and this is consistent with the research of Abdel- Magied and Taha (1), Badi (5) and Kareshk, Oliaee (3). As it was noted, some cells surface mucus cells & neck mucous cells & parietal cells, and a considerable number of chief cells, enteroendocrine cells, and stem cells.

It was also found that the pyloric region contains pyloric glands. However, some researchers did not address enteroendocrine cells and stem cells.

The present study also agreed with the studies of researchers Ali and Al-Derawi (10) in their study on anatomical and histological that the glands of the anterior region are cardiac, and some of their glands in the cardiac region in the actual stomach.

It has an apparent response to the PAS detector, and some other researchers touched on the description of the pyloric region containing 5 types of cells (1, 3).

The posterior region of the apposition also showed a clear difference from the stomach of ruminants described in the research of Pelagalli (13), which differs in the cardiac region and is similar to it in the pyloric and fundal regions in terms of the presence of glands, and it also gives a clear response to (PAS) reagent, and this is consistent with the current study.

It was found in the pyloric region deeper than in the gastric pit and the portal region, and this agrees with the researchers Abdel- Magied and Taha (1) and Kareshk, Oliaee (3).

The histological study also showed that the muscle layer of this region is thick and contains bundles of smooth muscle fibers similar to their counterparts in the first two parts of the stomach, as the serous region contains connective tissue mesothelium. This agrees with the researchers Abdel- Magied and Taha (1), Kareshk, Oliaee (3), and Eurell and Frappier (15).

The present study was carried out for two types of endocrine cells in the abomasum wall of the one-humped camel in southern Iraq. Synaptophysin and gastrin, As the current study mentioned, the appearance of Synaptophysin in the abomasum in camels, which is Synaptophysin in cytoplasmic staining in the stomach, is a transmembrane glycoprotein marker present in the gastric gland and also found in synaptic vesicles of neurons in submucosa and muscularis.

Where the reaction was positive, differing in distribution and intensity from one part to another, The result was a dense distribution of synaptophysin cells in the lamina propria of the fundus region and less than in the pyloric region, while they are absent in the cardiac, and this is consistent with the research of Abdellatif (7), in his research that it included the distribution of Synaptophysin in the abomasum and pancreas of camels when he took 10 samples from the stomach of male camels and conducted a study on them, he noticed a positive interaction of Synaptophysin for all parts of the abomasum.

As is consistent with the research García, Masot (16), which observed a positive interaction of Synaptophysin

in the abomasum of goat embryos at the age of 64 days, when he took 146 samples from goat embryos to study the development of the rumen by electron microscopy and immunohistochemistry, he noticed a positive interaction of Synaptophysin in all parts of the rumen.

Also, Kim and Shivdasani (17) observed an immune reaction to Synaptophysin inside the nerve fibers. The cells in the camels' abomasum wall align with the present study.

It also agrees with many studies such as (16) in the stomach of a compound goat and the researcher Asar, Bayram (18) in the stomach of a rat, Where he studied the emergence of immune neurons in rat embryos aged between 13-21 days, where he noticed the emergence of neurons at the age of 13 days, where the result was positive for all parts of the stomach a similar reaction was observed as it was in.

Our study is consistent with Qin, Tao (19) in his study of the turtle gastro-pancreatic system, as it is consistent with the cycle of nerve impulse conduction in the research.

The present study also showed the presence of a dense distribution of synaptophysin cells in the part of the Fundus of the stomach more than pyloric. At the same time, it is absent in the cardiac glands in the cardiac region, which is consistent with the research of Abdellatif (7). However, they did not accurately describe cell intensity and distribution nor mention any synaptophysin glands in the cardiac region. The current study showed the distribution of Synaptophysin in gastric cells and the submucosal and muscularis layers in the areas and distribution of cells and nerve ganglia.

The current study also showed the presence of Synaptophysin in large numbers in the fundus area and less than it in the pyloric stomach of the camel, and this corresponds to and completes the description Türk, Çınar (20) in Immunohistochemistry study of the gut of deer, where he described seven types of immune cells in the gut A positive interaction with an unusual distribution pattern of endocrine cells has been described.

Gastrin is a hormone secreted by endocrine cells in the stomach wall that controls the secretion of HCl from parietal cells.

Gastrin appeared in the present study on the abomasum wall of the camel's stomach, where it showed a positive reaction in the cardiac and fundus regions. In contrast, no immune activity of gastrin cells was shown in the pyloric region, where this study is one of the studies rare or few, if not the first for these endocrine glands in camels (20) where they are studying gastrin with another group of immune glands in the digestive tract of deer, where the result was a positive interaction, and the presence of gastrin in the pyloric area was confirmed. However, this study contradicts the current study. Whereas our present study confirmed that there is no gastrin in camel's pyloric area in the abomasum, this may be due to environmental conditions, nature of food, the Geographical patch, and differences between the stomachs of deer and camels.

Based on the results of the current study, it is highly recommended for future research projects investigate abomasum development in camel embryos. Also, the immunological investigation of the glandular part of the camel's rumen seems exciting and pivotal. Furthermore, studying another type of endocrine cell in the abomasum would be crucial in understanding the one-humped camel's digestive system.

Authors' Contribution

Study concept and design: Z. A. S.

Acquisition of data: S. A. A.

Analysis and interpretation of data: A. H. S.

Drafting of the manuscript: Z. A. S.

Critical revision of the manuscript for important intellectual content: Z. A. S.

Statistical analysis: S. A. A.

Administrative, technical, and material support: A. H. S.

Ethics

The protocol was accepted by University of Basrah, Basrah, Iraq.

Conflict of Interest

The authors declare that they have no conflict of interest.

References

1. Abdel- Magied E, Taha A. Morphological, morphometric and histochemical characterization of the gastric mucosa of the camel (*Camelus dromedarius*). *Anat Histol Embryol.* 2003;32(1):42-7.
2. Dittmann MT, Runge U, Ortmann S, Lang RA, Moser D, Galeffi C, et al. Digesta retention patterns of solute and different-sized particles in camelids compared with ruminants and other foregut fermenters. *J Comp Physiol.* 2015;185(5):559-73.
3. Kareshk AT, Oliaae RT, Mahmoudvand H, Keyhani A, Mohammadi MA, Bamorovat M, et al. The first survey of isolation and molecular typing of *Toxoplasma gondii* by bioassay and PCR method in BALB/c mice in camels (*Camelus dromedarius*) from eastern Iran. *Iranian Journal of Parasitology.* 2018;13(3):382.
4. Burger PA, Ciani E, Faye B. Old World camels in a modern world—a balancing act between conservation and genetic improvement. *Anim Gen.* 2019;50(6):598-612.
5. Badi IAA. Morphological and Histochemical Studies on the Stomach with special emphasis on the Glandular Sacs of the Camel *Camelus dromedarius*: Sudan University of Science and Technology; 2014.
6. Jorsal T, Rhee NA, Pedersen J, Wahlgren CD, Mortensen B, Jepsen SL, et al. Enteroendocrine K and L cells in healthy and type 2 diabetic individuals. *Diabetologia.* 2018;61(2):284-94.
7. Abdellatif AM. Assessment of the endocrine cells and neural structures in the abomasum and pancreas of dromedary camel based on their synaptophysin immunoreactivity. *J Adv Vet Res.* 2020;10(4):226-32.
8. Lehmann F, Beglinger C. Gastrin-releasing peptide. *Handbook of biologically active peptides*: Elsevier; 2006. p. 1047-55.
9. Suvarna KS, Layton C, Bancroft JD. *Bancroft's*

- theory and practice of histological techniques E-Book: Elsevier health sciences; 2018.
10. Ali SA, Al-Derawi KH. Testicular toxic effect of lead acetate on adult male rats and the potential protective role of alcoholic extract of ginseng (histological, histomorphometrical and physiological). 2018.
 11. Raji AR. Morphological and histochemical investigation of the camel (*Camelus dromedarius*) abomasal mucous membrane by light and scanning electron microscopy (SEM). 2011.
 12. Ibrahim MA, Radwan MI, Kim HK, Han J, Warda M. Evaluation of global expression of selected genes as potential candidates for internal normalizing control during transcriptome analysis in dromedary camel (*camelus dromedarius*). *Small Rumin Res.* 2020;184:106050.
 13. Pelagalli G. Morphological studies in the buffalo as a contribution to biotechnological methodologies in the animal production. *Ital J Anim Sci.* 2007;6(2):184-93.
 14. Jarrar B, Faye B. Normal pattern of camel histology. FAO publications, Riyadh, Saudi Arabia; 2013.
 15. Eurell JA, Frappier BL. Dellmann's textbook of veterinary histology: John Wiley & Sons; 2013.
 16. García A, Masot J, Franco A, Gázquez A, Redondo E. Histomorphometric and immunohistochemical study of the goat rumen during prenatal development. *The Anatomical Record: Advances in Integrative Anatomy and Evolutionary Biology.* 2012;295(5):776-85.
 17. Kim T-H, Shivdasani RA. Stomach development, stem cells and disease. *Development.* 2016;143(4):554-65.
 18. Asar M, Bayram Z, Korgun E, Tertemiz F, Akkoyunlu G, Demir R. Immunocytochemical detection of synaptophysin in enteric neurones during prenatal development in the rat stomach. *Anat Histol Embryol.* 2004;33(3):135-40.
 19. Qin P-S, Tao C-R, Yin S, Li H-M, Zeng D-L, Qin X-M. Complete mitochondrial genome of *Lacerta agilis* (Squamata, Lacertidae). Taylor & Francis; 2014.
 20. Türk S, Çınar K, Öztop M. Distribution and relative frequency of immunohistochemically detected endocrine cells in the stomach of New Zealand White rabbit (*Oryctolagus cuniculus*). *Iran J Vet Res.* 2019;20(1):39.