

ORIGINAL ARTICLE

Survey and Histological study of *Eimeria* species in poultry of Basra Governorate, Iraq

Heba A. H. Kadim, Ghazi Y. A. Al-Emarah, Wasfi A. Al-Masouddi,

Department of Basic Medical Sciences, College of Dentistry, Misan University, Misan, Iraq

Department of Microbiology and Parasitology, College of Veterinary Medicine, Basrah University, Basrah, Iraq

Department of Physiology and Chemistry, College of Veterinary Medicine, Basrah University, Basrah, Iraq

Email: habahussain1986@gmail.com; Ghazi.azzsl@uobasrah.edu.iq; wasfi.masoudi@uobasrah.edu.iq

ABSTRACT

A survey study was conducted to determine the rate of *Eimeria* species infection in broiler chickens in Basra Governorate in southern Iraq. 100 intestine samples were collected. The total infection rate of *Eimeria* species was 20%. the Highest infection rate was 13% with *E. acervulina* while lowest infection rate was 1% with *E. necatrix* and *E. tenella*. Highest percentage occur in 3-4 weeks of age 65% while the lowest percentage occur in 1-2 weeks of age 10%. Macroscopical results showed petechial hemorrhage of different sizes diffused into the intestinal lining, severe mucosa secretion mixed with blood and congestion along the intestinal wall. Histopathological results of poultry coccidiosis revealed severe infiltration of inflammatory cells mainly mononuclear inflammatory cells in the intestinal mucosa, presence large numbers of immature and mature *Eimeria* oocysts into the crypts and villi of mucosa layers of intestine, and congested blood vessels. **Keywords:** Broilers, Coccidiosis, *Eimeria*, Histological study. Protozoon parasite

Received 17.05.2023

Revised 24.06.2023

Accepted 23.08.2023

How to cite this article:

Heba A. H. Kadim, Ghazi Y. A. Al-Emarah, Wasfi A. Al-Masouddi. Survey and Histological study of *Eimeria* species in poultry of Basra Governorate, Iraq. Adv. Biores. Vol 14 [5] September. 2023. 203-208.

INTRODUCTION

Avian coccidiosis is an enteric parasitic disease caused by multiple species of the protozoan parasite of the genus *Eimeria* (family Eimeriidae) that belong to the phylum Apicomplexa [14]. Coccidiosis in hens is one of the most prevalent and economically significant poultry diseases, causing an estimated \$13.6 billion USD annual losses [5]. It inflicts the birds in both clinical and sub-clinical forms. The clinical form of the disease manifests through prominent signs of mortality, morbidity, diarrhea or bloody feces, and sub-clinical coccidiosis manifests mainly by poor weight gain and reduced efficiency of feed conversion [2, 25]. Selective *Eimeria* species infections can be catastrophic and destructive for chicken farms, depending on their prevalence, fecundity, and pathogenicity. Seven *Eimeria* species are widely recognized for infecting chickens with varying degrees of pathogenicity: *E. tenella*, *E. necatrix*, *E. brunetti*, *E. acervulina*, *E. mitis*, *E. maxima*, and *E. praecox* [3, 4] and infection with this parasite normally occurs through ingestion of feed or water contaminated with sporulated Oocysts [5-9]. Mortality rates are usually high in young chick because most of the *Eimeria* species. affects birds between the age of 3 and 18 weeks [10]. The diagnosis of coccidiosis is based on clinical signs, coprology and pathomorphological and pathohistological analysis [11, 12]. In recent years, various biochemical and molecular methods have also been used [13]. Majority of *Eimeria* oocysts have ovoid shape. Other characteristics that is useful in species identification includes: zone of intestine parasitized, nature of macroscopic lesions, minimum sporulation time, minimum prepatent period, schizonts size and area in which it develops, location of the parasite within the epithelial cells and cross-immunity trails [14].

MATERIAL AND METHODS

Collection of Samples

100 intestinal samples of broiler chickens of different ages and sexes were collected from (poultry houses in Shatt al-Arab, Al Zubair and Safwan, veterinary clinics and Al-Noor veterinary laboratory), during the

period from the first of December 2021 till end of October 2022. After collection the intestines samples with sterile disposable plastic containers, it were kept in ice bag to avoid contamination or rotting by bacteria or fungi and preserved in 10% buffered formalin for histopathologic testing and staining with hematoxylin (H) and eosin (E) stain (Talukder, 2007). All samples were transported to the parasitological laboratory at College of Veterinary Medicine in University of Basra. The intestinal samples were examined for gross pathological changes and the mucosa of duodenum, jejunum, ileum and the cecum were examined for the presence of *Eimeria* spp. Stage according to the method described by [15].

#### Parasitological technique

Wet smears of mucosa were prepared from intestinal and cecal scraping for microscopic examination of *Eimeria* spp. and *Eimeria* spp. identified according on the site of infection and oocysts morphology including size, color presence or absence of micropyle, cap and time of sporulation [16].

## RESULTS

**Occurrence of coccidiosis:** The total infection rate of *Eimeria* spp. in broiler chicken is 20% (Table 1). While The rate of *Eimeria* spp. infection in broiler chicken according to the species of *Eimeria* Indicate the highest infection rate was 13% with *E. acervulina* while lowest infection rate was 1% with *E. tenella* and *E. necatrix* (Table 2). Also found the rate of *Eimeria* spp. infection in broilers chicken according to the age indicate the highest percentage occur in 3-4 weeks of age 65% while the lowest percentage occur in 1-2 weeks of age 10% (Table 3).

**Table (1): Total infection rate of *Eimeria* spp. in broiler chickens.**

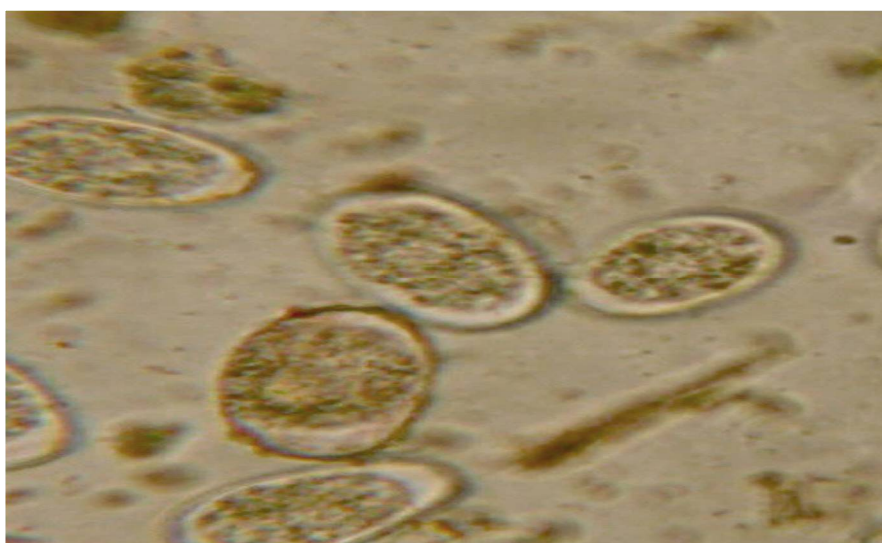
Birds	No. of sample	No. of positive	Percentage %
Broiler chickens	100	20	20

**Table (2): The rate of *Eimeria* spp. infection in broiler chickens according to the species of *Eimeria*.**

Species of <i>Eimeria</i>	Birds (No. of positive)	Percentage %
<i>E. acervulina</i>	13	13
<i>E. praecox</i>	5	5
<i>E. necatrix</i>	1	1
<i>E. tenella</i>	1	1
Total	100	20

**Table (3): The rate of *Eimeria* spp. infection in broiler chickens according to the age.**

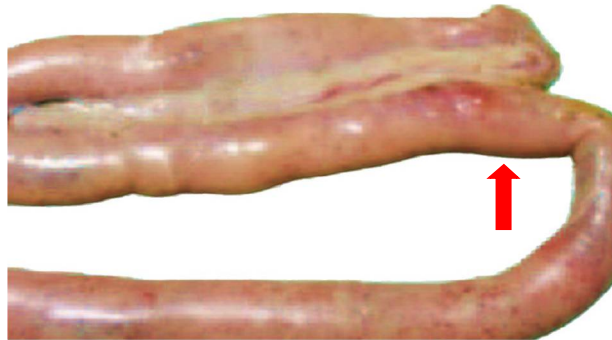No. of positive samples	1-2 weeks (% age infection)	3-4 weeks (%age infection)	4-6 weeks (% age infection)
20	2 (10)	13 (65)	5 (25)



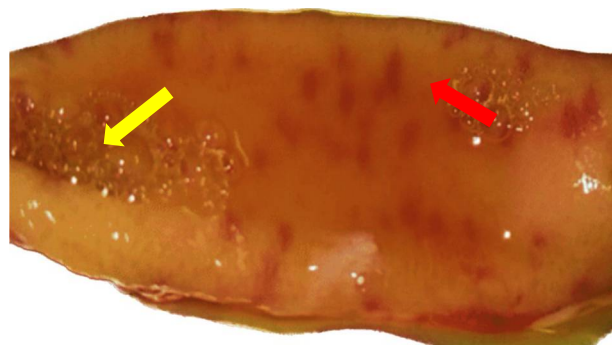
**Figure (1): Oocysts of *Eimeria* species (40X).**

**Macroscopical results:** Infected birds showed there are petechial hemorrhages as well as to ballooning like appearance of the duodenum as in figure (2). In addition, mucoid bloody enteritis as well as thickening

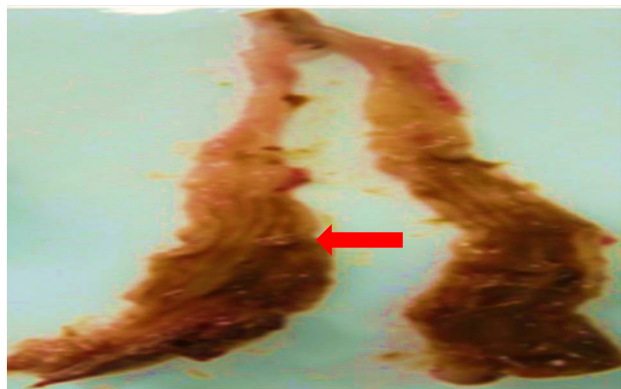
and ecchymotic hemorrhagic jejunum mucosa as in figure (3). There was mucoïd to blood-tinged exudates (cecum) as in figure (4).



**Figure (2):** Petechial hemorrhages as well as to ballooning like appearance of the duodenum (red arrow).



**Figure (3):** Mucoïd bloody enteritis (yellow arrow) as well as thickening and ecchymotic hemorrhagic jejunum mucosa (red arrow).



**Figure (4):** Mucoïd to blood-tinged exudates (cecum) (red arrow)

**Histopathological results:** Microscopical results include the section of intestine (duodenum) showed marked sever infiltration of inflammatory cells mainly mononuclear inflammatory cells with marked presence large numbers of immature and mature *Eimeria* oocysts into the crypts and villi of mucosa layers of intestine and congested blood vessels as in figure (5). The section of intestine (cecum) showed marked superficial sloughing of the epithelium with marked inflammation of the lamina propria as in figure (6).

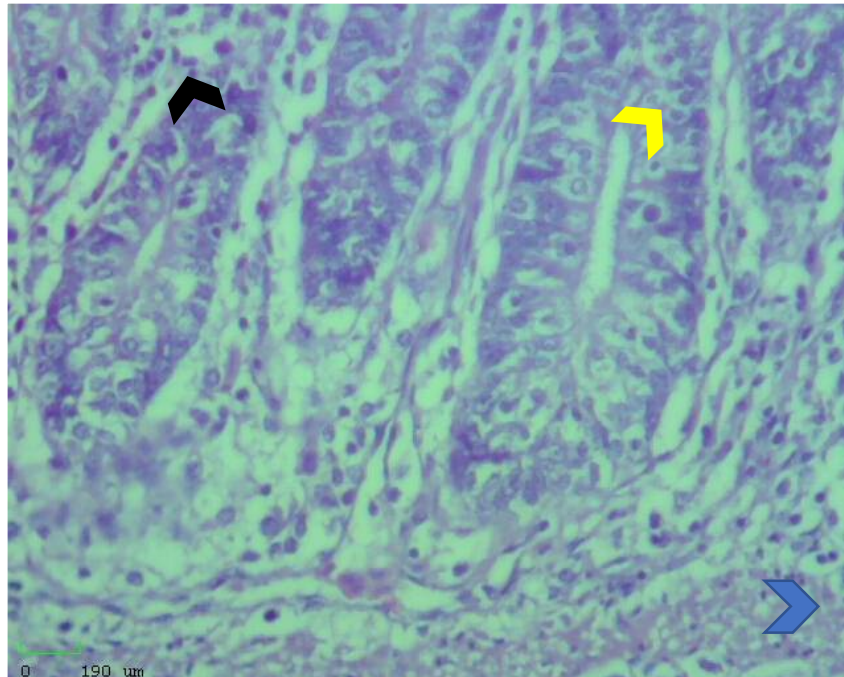


Figure (5): Histopathological section of intestine (duodenum) showed marked severe infiltration of inflammatory cells mainly mononuclear inflammatory cells (black arrow head) with marked presence large numbers of immature and mature *Eimeria* oocysts into the crypts and villi of mucosa layers of intestine (yellow arrow head) and congested blood vessels (blue arrow head) H&E stain (40X).

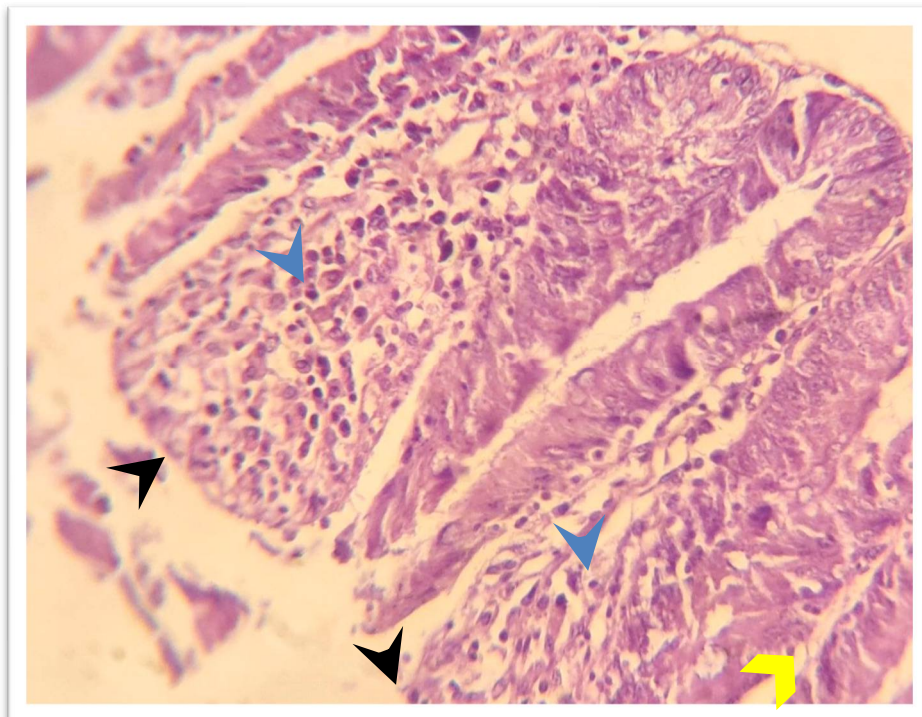


Figure (6): Histopathological section of intestine (cecum) showed marked superficial sloughing of the epithelium (black arrow head) with marked inflammation of the lamina propria (blue arrow head) and congested blood vessels (yellow arrow) H&E stain (10X).

## DISCUSSION

**Microscopical study:** The result of the current study explain that avian coccidiosis is endemic in Basra Governorate with an overall rate of 20% *Eimeria* spp. infection was recorded in this study. This result was in agreement with the finding in Basra province [19, 16, 26] and Al-Muthanna province [1] who reported a prevalence of 22.2% and 21.7% respectively. However, the current result in the rate of *Eimeria* spp. infection is much lower than the findings of [5] (71.1%). This high reduction of the rate of *Eimeria* spp. infection observed in the current study might be ascribed mainly to the application of preventive measures which basically sanitary measures and use of anticoccidial drugs that were given at early stages of age. In the present study *E. acervulina* (13%) was the predominant species, followed by *E. praecox* (5%). This finding is in agreement with the finding of [1] in Al-Muthanna province and [2] in Iran revealed that *E. acervulina* was the predominant species of *Eimeria*. However, previous research conducted in Basra province by [24] revealed that *E. praecox* was the most prevalent species. The probable reasons for this discrepancy could be the differences in virulence of the *Eimeria* species at different management system and /or due to the prophylaxis use of anticoccidial drugs in feed and water or may be due to breed differences. It is likely that resistance has developed to more recent anticoccidial drugs [3] and very few drugs are equally efficacious against all *Eimeria* species [17].

Results of the current study, in provisions of age of the infected birds, was higher in broiler chicken having 3-4 weeks age (65%) followed by birds having 4-6 weeks age (25%) and lower in birds having age of 1-2 weeks (10%). The results were in agreement with the study of [2] who also determined the higher predominance of coccidian infection in the broiler chicken of the same age groups. However, the variation was observed between the age categories. This may be due to management system and breed factors. The amount of oocyst discharged from infected chicken depends on the dose of oocysts ingested and the immunological status acquired from previous exposure [24-27].

**Macroscopical study:** The macroscopic results of Infected birds showed there are hemorrhages as well as to ballooning like appearance of the duodenum. In addition, mucoid bloody enteritis as well as thickening and ecchymotic hemorrhagic jejunum mucosa. The reason is due to congestion in the blood vessels to disruption it and occur hemorrhages. This result agrees with Sharma *et al.*, [21] who mentioned that blood vessel congestion indicates a disturbance, which is followed by bleeding also ballooning like appearance due to hyperemia with edema this result agreed with El-Naggar, [12] who mentioned that inflammation such as hyperemia, edema, also agreed with Sharma *et al.*, [21] how The post-mortem examination revealed a severely inflated gut with hemorrhages. The blood-tinged exudate occurs as a result the distraction of blood vessels due to heavy congestion these findings similarly mentioned by Chapman, [7] who stated that in case of cecal coccidiosis, enlarged and distended caeca filled with blood and petechial hemorrhages were observed in *E. tenella* infected chickens.

**Histopathological study:** The difference histological lesions observed could be due to destruction of the epithelial lining of the infected intestine by different *Eimeria* spp. The histopathological changes in *E. acervulina* revealed, presence of oocysts and schizonts with characteristic inflammatory cells in duodenal part of intestine, focal to sever hemorrhage. Similar occurrence have been reported by Asaduzzaman *et al.* [4] who stated that *E. acervulina* showed presence of oocyst and schizonts with the characteristic of inflammatory cells in duodenal part of intestine. While the histopathological changes in *E. tenella* revealed, loss of epithelial tissue, congestion of blood vessels which indicated disruption followed by leakage of blood, necrosis of submucosa, loss of villi, disruption of cecal mucosa, cluster of oocysts, schizonts and marked hemorrhage, necrosis of cecal mucosa considerable numbers of oocyst in lamina propria of caecum, presence of different developmental stages of parasite, villous atrophy, severe inflammation and mononuclear inflammatory cell infiltrate. Similar findings were reported by Soomro *et al.* [22], McDougald and Fitz-Coy, [26] and Meskerem *et al.* [18].

## CONCLUSIONS

The results of this study offer the coccidia species identified were *E. praecox*, *E. tenella*, and *E. necatrix*, while *E. acervulina* were the predominant species. The infection rate detected in this study may suggest for the presence of favorable condition for biology and transmission of the parasite. It is must be improved to prevent the incidence and dissemination of avian coccidiosis. The effect of coccidiosis on the production ability of chicken and its economic importance should be further studied.

## REFERENCES

1. Al Se'adawy Mohenned, A. H. (2013). Prevalence of subclinical coccidiosis associated with house reared chickens in Al-Muthanna province, Iraq. Kufa Journal for Veterinary Medical Sciences, 4(1).

2. Allen PC, Fetterer RH (2002). Recent advances in biology and immunobiology of *Eimeria* species and in diagnosis and control of infection with these coccidian parasites of poultry. *Clin microbiol Rev* 15: 58-65.
3. Amin, Y., Aslam, A., Anwar, K. & Ali, Z. (2014). Seasonal prevalence of eimeriosis in broiler chicken. *Advancements in Life Sciences*, 1 (3): 160-164.
4. Asaduzzaman, M.N., Miah, M. S., Siddika, A.T., Popy, N. and Hossain, M. M. (2011): Experimental production of necrotic enteritis in broiler chickens. *Bangle Journal of veterinary medicine*, 9(1):33-41.
5. Blake DP, Worthing K, Jenkins MC. (2020). Exploring *Eimeria* genomes to understand population biology: recent progress and future opportunities. *Genes (Basel)* ;11:1103; [<https://doi.org/10.3390/genes11091103>]
6. Brown Jordan A, Blake D, Beard J, Beharry A, Serrette L, Soleyn A, et al. (2018) Molecular identification of *Eimeria* species in broiler chickens in Trinidad, West Indies. *Vet Sci* ; 5:12; <https://doi.org/10.3390/vetsci5010012>
7. Chapman, H.D. (2005). Perspectives for the control of coccidiosis in poultry by chemotherapy and vaccination. IX international coccidiosis conference, September 19-23, 2005, *Foz do Iguassu*, Brazil, pp. 99-103.
8. Chapman, H.D. (2014). Milestones in avian coccidiosis research: A review. *Poultry Science*, 93:501-511.
9. Conway DP, McKenzie ME (2007). *Poultry Coccidiosis: Diagnostic and Testing Procedures*. 3rd ed. Blackwell Publishing, State Avenue, Iowa, USA.
10. Dakpogan HB, Salifou S (2013). Coccidiosis prevalence and intensity in litter based high stocking density layer rearing system of Benin. *J Anim Plant Sci* 17:2522-6.
11. Dinka ,A and Yacob, H. (2012). Coccidiosis in Fayoumi Chickens at Debre Zeit Agricultural Research Center Poultry Farm, Ethiopia. *European Journal of Applied Sciences* 4 (5): 191-195.
12. El-Naggar, A. K. (2017). What is new in the World Health Organization 2017 histopathology classification? *Current Treatment Options in Oncology*, 18(7), 1–4
13. Haug A, Gjevne AG, Tebo P, Mattsson JG, Kaldhusdal M (2008). Coccidial infections in commercial broilers: epidemiological aspects and comparison of *Eimeria* species identification by morphometric and polymerase chain reaction techniques. *Avian pathol* 37: 161-70.
14. Latif AA, Fazal S, Manzoor F, Maqbool A, Asghar S, et al. (2016) A Comparative Study on Prevalence of Coccidian Parasites in Broiler Chicken (*Gallus gallus domesticus*), Japanese Quail (*Coturnixcoturnix japonica*) and Wild Pigeon (*ColumbaLivia*). *PakJZool*48:295-7.
15. Mattiello, R. (1990). Detect subclinical coccidiosis, *Misset World Poultry*. *Misset* (October/November), pp. 82–83.
16. McDougald, L. R. (2003). *Coccidiosis disease of poultry* 11<sup>th</sup> ed. Iowa state press. Iwoa. Pp;1001-1010.
17. McDougald, L.R. and Fitz-Coy, S.H. (2008). Protozoal infection, In: Saif, Y.M. (ed.). *Disease of poultry*. 12th ed. Blackwell Publishing. Ames, IA, USA. Pp.1068-1080.
18. Meskerem, A., Chaiwat, B., Nirat, G. and Montakan,V. (2013). Hematological, biochemical and histopathological changes caused by coccidiosis in chickens. *Kasetsart Journal (Nat.Sci.)*, 47:238-246
19. Morris, G.M. and R.B. Gasser. (2006). Biotechnological advances in the diagnosis of avian coccidiosis and the analysis of genetic variation in *Eimeria*. *Biotechnol. Adv.* 24:590–603.
20. Reid WM (1978). *Coccidiosis. Diseases of Poultry (7th Edn)*. Iowa State University Press, Ames, Iowa, USA, 784-805.
21. Sharma, S., Azmi, S., Iqbal, A., Nasirudullah, N., & Mushtaq, I. (2015). Pathomorphological alterations associated with chicken coccidiosis in Jammu division of India. *Journal of Parasitic Diseases*, 39(2), 147–151.
22. Soomro, N.M., Rind, R.A., Arijo, A. G. and Soomro, S.A. (2001). Clinical, Gross and Histopathological Studies of coccidia infection in Chicken. *International journal of Agriculture and Biology*,3(4):426-427.
23. Soulsby, E. J. L. (1982). *Helminths, Arthropods and protozoa of domesticated animals* . Academic press . London: 630-639.
24. Talukder, S. (2007): Histopathology techniques: Tissue processing and staining. [www.talukderb.com](http://www.talukderb.com).
25. Waqar, S. J., Jihad, A. A. and Harith A. N. (2021). Clinical and pathological scoring of avian coccidiosis in Basra province, Iraq. *Turkish Journal of Physiotherapy and Rehabilitation*, 32(3).
26. Williams, R. B.(2005). Intercurrent coccidiosis and necrotic enteritis of chickens: rational, integrated disease management by maintenance of gut integrity. *Avian Pathology*, 34 (3), 159-180.
27. Williams, R.B. (1999) A compartmentalized model for the estimation of the cost of coccidiosis to the world's chicken production industry, *International Journal of Parasitology*, 29: 1209-1229.

**Copyright:** © 2023 Author. This is an open access article distributed under the Creative Commons Attribution License, which permits unrestricted use, distribution, and reproduction in any medium, provided the original work is properly cited.