

A SINGLE SURGEON'S EXPERIENCE IN DEFINING THE LEARNING CURVE FOR TRANSORAL ENDOSCOPIC THYROIDECTOMY –VESTIBULAR APPROACH (TOETVA)

Salah Kadhim Muslim^{1*}.

¹Consultant surgeon, assistant professor in surgery, department of surgery, college of medicine, university of basrah, Iraq.

Abstract.

Background: Cosmetic outcome is one of the essential objectives in the surgical management of thyroid diseases. To improve that; many new technologies has been proposed, among these; mini-invasive and natural orifice thyroidectomy. Transoral endoscopic thyroidectomy-vestibular approach (TOETVA) is the most recent natural orifice approach to the thyroid and parathyroid glands.

Aim: To report the learning curve for Transoral endoscopic thyroidectomy –vestibular approach (TOETVA) for a senior surgeon already had experience in conventional thyroid and minimal access surgery.

Material and methods: From December 2017 to October 2019, ten patients were included in the study and serially grouped into two groups; five in each. They were prospectively observed for the operative time, Intra- and postoperative complications, hospital stay and functional assessment.

Results: When compared with group (1); operative time saving in group (2) was about 35 minutes. No case was converted to conventional surgery. Accidental mucosal and skin lesions while introducing the surgical trocars were observed in the first two cases only.

Recurrent laryngeal nerve was identified in nine cases; even that, transient palsy was noticed in two cases of group (1) only. One patient from each group experiences lower paresthesia. Even if it is not routine; the use of drain decreased significantly in the last five cases.

All the patients developed post-operative subcutaneous emphysema and ecchymosis and resolved spontaneously on 1 and 10 days respectively.

Conclusion: After five Transoral endoscopic thyroidectomy–vestibular approach (TOETVA), a senior surgeon who had adequate basic experiences in conventional thyroidectomy and minimal access surgery can safely masters the technique of the surgery with satisfactory operative times, and a decreasing rate of intra- and postoperative complications. Exposure to more cases would reduce the learning curve.

Key words. Transoral endoscopic thyroidectomy, vestibular approach.

Introduction.

Till now, Surgery is still having a role as the main treatment of thyroid diseases [1]. In general, cosmetic outcome is essential in thyroidectomy but its results are controversial if surgery done with conventional route [2] to minimize the visible scarring; many minimally invasive and remote access approaches have been proposed. Endoscopic access has also emerged as another option in the 1990s [3,4]. It is not universally accepted due the limited number of cases, limited indication, more surgical

trauma, more extensive flap dissection, longer operation time and technical difficulties. However, others claim that despite these drawbacks, it belongs a superior cosmetic result [5-7].

Natural orifice transluminal endoscopic surgery (NOTES) is a cosmetically excellent approach that involves insertion of an optical instrument through a native orifice. In February 2016; in the first International Thyroid NOTES Conference, an effort was made to standardize and refine thyroid NOTES techniques, including both transoral endoscopic and robotic thyroidectomy approaches [8]. Thyroid surgeons then established a NOTES procedure via oral vestibule , termed as the transoral endoscopic thyroidectomy vestibular approach (TOETVA) . apart from the thought that this approach is technically demanding due to the narrower working space when compared with open surgery [9]; we believe that to master such technique, we need surgeons with adequate training both in conventional thyroid and minimal access procedures. The learning curve for (TOETVA) and the number of cases required to master it is not settled yet due to the limited studies that described that [10].

Aim. To report the learning curve for Transoral endoscopic thyroidectomy –vestibular approach (TOETVA) for a senior surgeon already trained in conventional thyroid and minimal access surgery.

Materials and methods.

Prospective study conducted in Basrah teaching hospital from December 2017 to October 2019. All patients showed a high motivation toward avoiding visible scar for social reasons and accepted to be operated upon by transoral approach after adequate discussion about the procedure followed by informed consent.

Selection criteria for patients were a thyroid nodule with a size of their larger diameter < 50 millimeter , a gland with a volume less than 20 ml, as estimated by high-resolution Doppler ultrasound (US) with both 7.5- and 12-MHz linear array transducers, no history of thyroiditis or previous neck surgery or irradiation, the benign nature of the nodule and absence of suspicious metastatic lymph nodes [11]. Patients were divided sequentially into two groups. Group 1 comprised the first five patients. Group 2 included the subsequent five patients.

Preoperative diagnosis of the disease was based on clinical examination, thyroid function test and fine needle aspiration cytology and all were planned for thyroid lobectomy.

Operative technique.

1. Pre-operative: It consist of pre-operative mouth wash with Chlorhexidine twice daily for 3 days and a parenteral antibiotics like amoxicillin one hour before anesthesia.

2. Body position: Supine position with slight neck extension with the help of two sandbags; one behind the nape of the neck

and the other in between shoulder blades. (Figure 1) showed the team disposition during the procedure in the operation room.

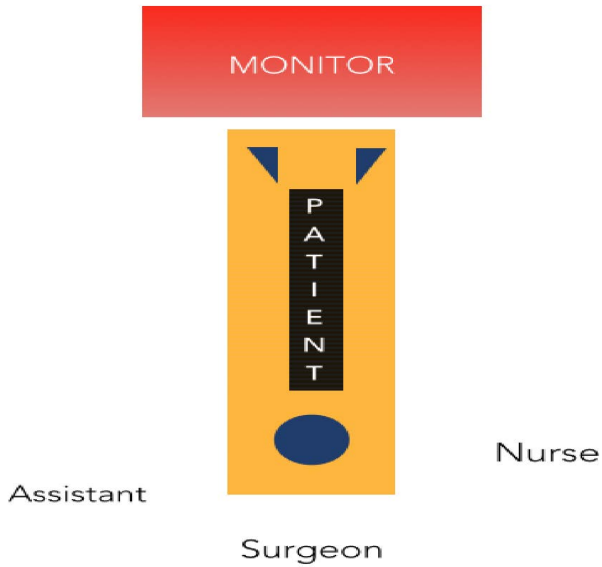


Figure 1. Disposition of team and equipment in the operating room [12].

3. Procedure: The patient was anaesthetized with Naso-tracheal intubation (Figure 2) , oral cavity was washed with saline and 10% povidone iodine. Then a one-centimeter transverse incision one centimeter above the frenulum was done for the 30° endoscope and other two lateral five-millimeter incision as a working port located one centimeter above each canine tooth.

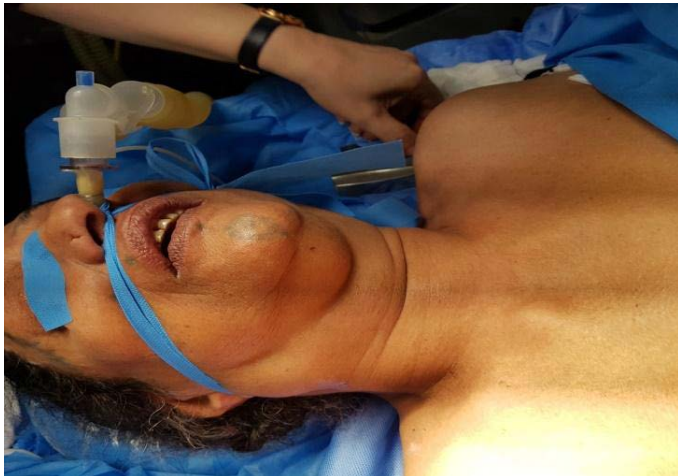

Figure 2. Naso-tracheal intubation.

In order to create a subplatysmal plane; a Veres needle is inserted and around 40-50 ml of normal saline containing adrenalin at a concentration of 1mg/1000ml normal saline as shown in (Figure 3).

The operative field which is shown in (Figure 4) was then insufflated with carbon dioxide (CO₂) with a pressure set at 6-8 mmHg. A plane is then created in sub-platysmal space followed by retraction of both strap muscles reaching to the deep fascia in which the isthmus of the gland then superior and inferior pedicles was identified and divided with help of ultra-

scission. Identification and preservation of recurrent laryngeal nerve and parathyroid glands is a mandatory step after securing hemostasis, the specimen was brought out through the oral cavity using a surgical glove as an endobag. Close drain was put in some cases. Strap muscles were approximated, and port sites were closed using fine absorbable sutures .A pressure dressing was applied over the chin and neck for 48 hours as shown in (Figure 5).

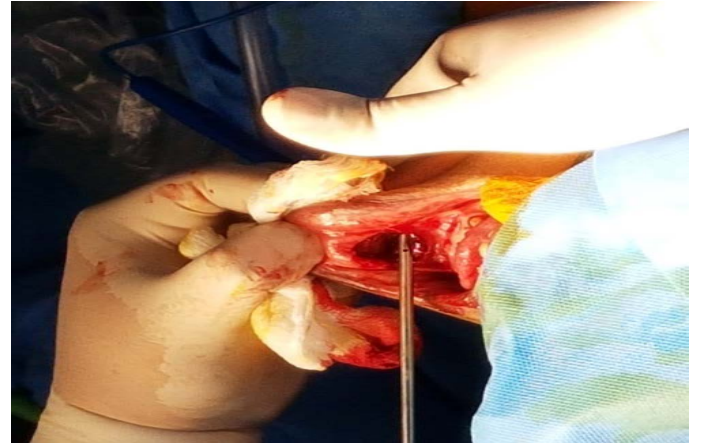


Figure 3. Veres needle inserted, and normal saline is infused.

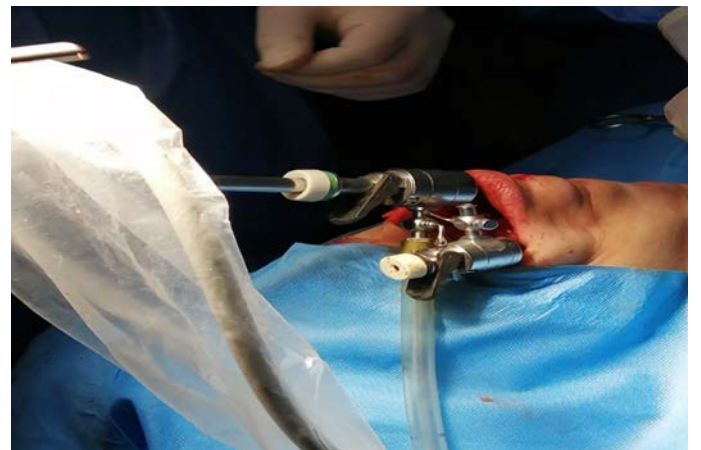

Figure 4. Positions of the ports.

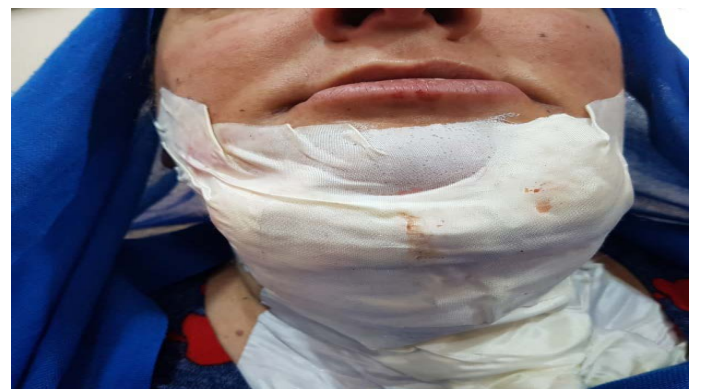

Figure 5. Post –operative dressing.

Post operatively, in both groups, patients were admitted to the surgical ward and kept on intravenous fluid for 24 hours while

oral diet then allowed after that .Antibiotics and daily mouth wash continued for seven days.

Simple and narcotic analgesics were used depending on patient's pain threshold.

For each case ,the main operation time was recorded and classified into the anesthetist's operative time (AOT) from patient entering the operating room to the correct naso–tracheal tube placement and the surgical operative time (SOT) from patient positioning, draping, toweleling and followed by starting surgery and ended with the last stitch to close such wound and application of the wound dressing. Both represent the learning experiences of both anesthetists and the surgeon respectively.

Mean hospitalization times were recorded. The following complications were analyzed: flap perforation, intra- and postoperative bleeding, seromas, wound infections, transient or permanent laryngeal nerve lesions and mental nerve injury.

All operations were indexed consecutively with a running number. Vessel sealing system is the method used for controlling hemostasis. Conversion to open surgery was needed when there is failure of the progress and uncontrolled bleeding .

All of the patients were followed up with direct laryngoscopy performed by independent ENT specialist both pre-and postoperatively to check vocal cord mobility and repeated after four weeks.

All the patients were anaesthetized by the same anesthetist and operated by the same surgeon who had an experience in both conventional thyroid and minimal access surgery.

Student's t-test was used for continuous data, and a p value of less than 0.05 was considered statistically significant.

Results.

Among the patients, there was nine female and one male. Their age ranged between 19-62 years with a mean age was 33.4 years. All were planned for thyroid lobectomy for complex thyroid nodule (eight in the left side and two in the right). All the patients were euo-thyroid except the male patient who had mild thyrotoxicosis. The size of nodule ranged between (26 x23) mm– (34 x45) mm with average size (29x41)mm. Fine needle aspiration cytology of all nodules showed benign colloid cells with no evidence of malignancy.

All of the surgeries ended successfully with no major complications that mandate actions like conversion to open surgery. Table 1 compares between group (1) and (2) regarding operation time, minor complication, the need to insert a drainage and post-operative hospital stay.

Table 1. Differences between group (1)and (2).

Parameter	Group (1)		Group (2)	
Operation time (mean)	119 min		86 min	
Anesthetist operation time (AOT)	31 min	26%	24 min	28%
Surgeons' operation time (SOT)	88 min	74%	62min	72%
Surgical complications				
Flap perforation	2		0	
Transient RLN injury	2	40%	0	0%
Permanent RLN injury	0	0%	0	0%
Lower lip paraesthesia or numbness (Suspected mental nerve injury)	1	20%	1	20%

The need for drainage	3	60%	1	20%
Post-operative hospital Stay (days)	3		3	

There is a statistically significant reduction in the operation time (both AOT and SOT) in group (2) when compared with group (1) (p ≥ 0.05) as shown in (Figure 6).

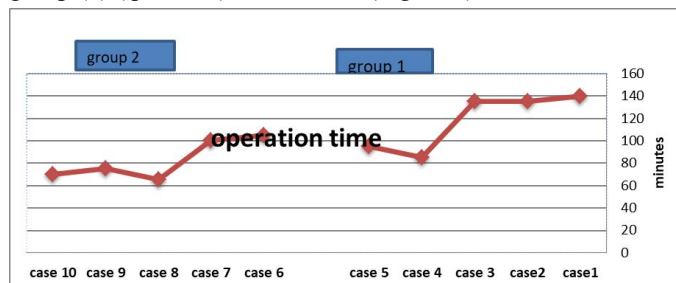


Figure. 6. Operation time differences between group 1and 2.

An accidental wounding of skin of the chin while introducing the first port and burning the anterior flap while using monopolar cautery. Both developed in the first two cases as shown in (Figure 7), such injury had been avoided after that.

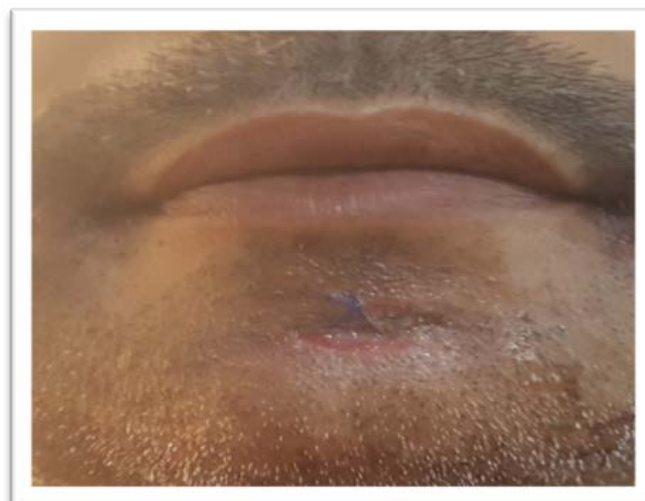

Figure. 7. Accidental anterior flap skin burn and perforation.

Recurrent laryngeal nerve could be identified in nine cases with confidence and protected during the procedure, but, postoperatively, the anesthetist identified weakness in the mobility of ipsilateral vocal cord of two patients from group (1) while extubating the naso-tracheal tube. Both patients noticed changes in their voice which is improved within four weeks and documented by indirect laryngoscopy done by the ENT specialist.

Mental nerve could be injured during inserting and manipulating the working ports that is inserted near its ends. In our study, one patient from each group developed such complications and presented with altered lower lip sensation and mild numbness in part of the chin.

Post-operatively, inserting a drain is not a routine and put when there was raw thyroid bed in such close space, and it is usually

related to the surgeon's personal confidence such confidence become clearer in the second five cases.

Mild subcutaneous emphysema was seen in all patients and resolved within 12–48 hours post-operatively. Mild ecchymosis around the skin was observed in both groups and resolved spontaneously after 10 -14 days as shown on (Figure 8).

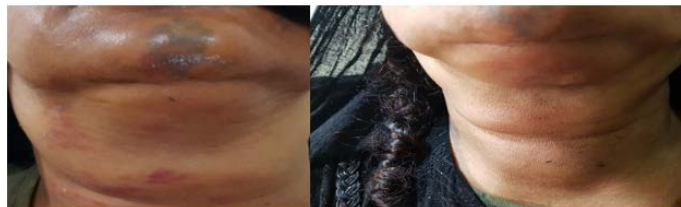


Figure. 8. Ecchymosis and mild subcutaneous emphysema 12 hours and 7th days post-operatively respectively.

Other complication like subcutaneous or mediastinal emphysema, extensive ecchymosis, deep seated neck infection, tracheal injuries and CO₂ induced gas embolism were not observed.

Although TOETVA converts thyroidectomy from clean surgery to clean contaminated surgery, wound infection was not observed.

Discussion.

Data analysis of most basic minimal access endoscopic procedures showed that 75% of intraoperative complications, as well as conversion to conventional open surgery, occurred during the first 5-10 cases [13].

In the present series, the overall operative time (both anesthetists and surgeons) was longer in group 1 than group 2 (119 to 86 minutes) and both times are comparable to that reported by Yang et al and Anuwong who published the largest series in the world [2,13-16]. A longer operative time were mentioned by Thomas Wilhelm et al who took multiple clinical studies and noticed a decrease in all over operation time of hemithyroidectomy +/- isthmus resection , subtotal thyroidectomy and total thyroidectomy from 283, 258 and 305 minutes to 49, 88 and 126 minutes respectively [2,13-18]. S.Bakkar, et al noticed that both anesthetist and surgeon required at least five patients to master the technique in the average time [13].

In the first two patients, we injured the flap that was created and lead to perforation by two different mechanisms; the first one is due to the heat that was transmitted from the monopolar diathermy device that is used to create the access at the commencement of the procedure as shown in (Figure 7). The other case is due to traumatic anterior flap perforation while introducing the camera port with some force to the subplatysmal plane. such complication occurred in our study at higher rate than that reported by Yang et al , Bakker et al and Hang Bian et al who reported single case of anterior flap perforation and another of neck skin burn in 39, 10 and 30 cases respectively. All of them face such accident; like in our study, the first three cases of their learning curve [13,14,18]. After that, more care was kept while creating the subplatysmal space with monopolar cautery and while sliding and pushing the trocar into the correct position.

The rate of conversion in our study is 0.0% which is less than that reported by the others (1.3%) [13]. Our result is attributed mostly to the higher selectivity of our patients than the others who included in addition patients with total thyroidectomy and those with history of thyroiditis. Surgery to those patients may carries difficulties that may lead to conversion; uncontrolled bleeding is the commonest one [18].

Although there is a limited beneficial use of drains in thyroid surgeries [19], many surgeons still using the drain as a tool to obliterate the dead space and evacuate collected blood and serum, reinforcing their belief by the fact that postoperative drains usually yield fluid [15,16]. In our study, the fear from post-operative collection in such closed space had been decreased after the fifth case and we believe like the others [11,19] that thyroid surgery without the use of a drain increases patient satisfaction independent on any surgical complication even it did not decrease the hospital stay of our patients.

Recurrent laryngeal nerve (RLN) injury is one of the most feared complications following thyroidectomy since it is very sensitive and can easily be injured by different intraoperative actions (i.e., clamping, cutting , stretching, compressing, and heating). Its affection could be permanent or transient . injury of this nerve induces a paresis or palsy of the vocal cord and presented post-operatively with dysphonia [13,21-23].

There is a considerable conjecture regarding the definition of 'transient' palsy. In general, Nerve palsy that continued for more than 6 -12 months was classified as permanent RLN palsy [22,23].

According to various studies, Permanent RLN injuries are observed between (0.5% to 5%) of the patients, whereas transient injuries are observed between (1% to 30%). Such wide range in the observation is possibly related to the stringency of the postoperative otolaryngologic controls, Intra-operative identification of RLN and the use of neurotransmitter [1,17-19,23].

In our study, we could identify others 18 the nerve in all patients except one patient in group (1). This enhances the safety of the procedure. Even that; two patients from group (1) developed weak vocal cord mobility while extubating the nasotracheal tube and it is further documented by indirect laryngoscopy done in the first post-operative day. Excessive use of sealing devices and stretching the gland while medial mobilization of the thyroid lobe can explain the occurrence of such injuries in our patients. Such factors were kept in our mind, and we did observe a good result in the second five cases.

Mental nerve which is a superficial one and it is more liable for injury while inserting the bilateral working port. The incidence of such complications varies, and it ranged between (0.0%-5.9%) [13,14,16-19]. The patient presented with numbness of the mucosal and cutaneous surfaces of the lower lip and chin . These symptoms then gradually ease in 6-12 months. Numbness can also occur without mental nerve injures, but it is relatively mild, and it usually resolved in about 3 months.

Inserting the working ports one centimeter or more lateral to the buccal fold at the level of the canine teeth can decrease the incidence of mental nerve injury (Figure 9) [1,11,17,20,24,25].

In our study, in contrast to that observed by Thomas Wilhelm

and Xiaowei et al [24,26] we could not visualize the nerve in any case while inserting the working ports. Even so, one patient from each group did not complain more than transient paresthesia and numbness in the lower lip which is resolved completely after four weeks. It has been emphasized recently that safe dissection of mental nerve is an important step during TOETVA in order to protect the nerve [29].

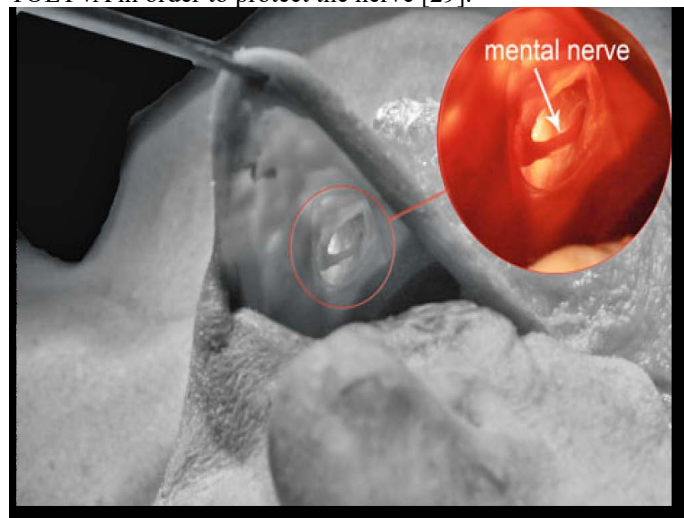


Figure.9. Identification of mental nerve under the mucosa [24].

All the patients recovered without any appreciable complications, but ; since the procedure is novel, we need a longer postoperative observation to exclude expected complications like airway obstruction, surgical site or neck space infection or bleeding. Our patients spent an average of three days in the hospital; a time more than reported by others [17,18]. The learning curve for TOETVA lobectomy has been defined as ten cases. a similar result was also reached by many other authors [19,28,29].

Conclusions.

It is not foreign to a surgeon who had vast experience in thyroid surgery in general and minimally invasive surgeries in particular to have a lesser steep learning curve compared to that for other remote access endoscopic procedures. This can be achieved with a stable proficiency after around five cases. A more standardized training program and exposure to more cases would reduce the learning curve.

To enhance patient safety , we believe that a proctor should be present in the first five cases not only by reinforcing the operative steps, but also by appropriately gauging when conversion to an open approach is required.

Consent.

Written informed consent was obtained from the patient for publication of this case report and accompanying images. A copy of the written consent is available for review by the Editor-in-Chief of this journal on request”.

REFERENCES

1. Quang V. Le, Duy Q. Ngo, et al. Transoral endoscopic thyroidectomy vestibular approach (TOETVA): A case report

as new technique in thyroid surgery in Vietnam. International Journal of Surgery Case Reports. 2018;50:60-63.

2. Gianlorenzo Dionigi, Luigi Boni, et al. Dissection and hemostasis with hydroxylated polyvinyl acetal tampons in open thyroid surgery. Annals of Surgical Innovation and Research. 2007;1:3

3. Gagner M. Endoscopic subtotal parathyroidectomy in patients with primary hyperparathyroidism. Br J Surg. 1996;83:875.

4. C.S. Huscher, S. Chiodini, C. Napolitano, A. Recher. Endoscopic right thyroid lobectomy. Surg Endosc. 1997;118:877.

5. Jeong Min Choo, Ji Young You, et al. Transoral Robotic Thyroidectomy: The Overview and Suggestions for Future Research in New Minimally Invasive Thyroid Surgery. Journal of Minimally Invasive Surgery. 2019;22:5-10.

6. Duh QY. Presidential address: minimally invasive endocrine surgery – standard of treatment or hype? Surgery. 2003;134:849-857.

7. G. Dionigi a, L. Boni , F. Rovera, et al. Defining the learning curve for video-assisted thyroidectomy. International Journal of Surgery. 2008;6:S1-S3.

8. Angkoon Anuwong ,Thanyawat Sasanakietkul, et al. Transoral endoscopic thyroidectomy vestibular approach (TOETVA): indications, techniques, and results. Surgical Endoscopy. 2018;31:456-465.

9. Hee Yong Kwak, Sang Hoon Kim, Byung Joo Chae, et al . Learning curve for gasless endoscopic thyroidectomy using the transaxillary approach: CUSUM analysis of a single surgeon's experience. International Journal of Surgery. 2014;12:1273-1277.

10. Lombardi CP, Raffaelli M, de Crea C, et al. Report on 8 years of experience with video-assisted thyroidectomy for papillary thyroid carcinoma. Surgery. 2007;142:944-951.

11. Gyan chand, SK Mishra. Transoral endoscopic thyroidectomy through vestibular approach. World journal of endocrine surgery. 2016;8:179-182.

12. Taissoun ZA, Anuwong A, Tobon AM, et al. Transoral thyroidectomy with vestibular approach: a new technique in Colombia .journal of Endocrinology. 2017;1:1-4.

13. Bakkar, M. Al Hyari, M. Naghawi, et al. Transoral thyroidectomy: a viable surgical option with unprecedented complications—a case series. Journal of Endocrinological Investigation. 2017.

14. Thomas Wilhelm , Guoyang Wu, et al. Transoral endoscopic thyroidectomy: current state of the art—a systematic literature review and results of a bi-center study . Translational Cancer Research. 2016;5:1521-1530.

15. Ugur Deveci, Fatih Altintoprak, et al. Is the Use of a Drain for Thyroid Surgery Realistic? A Prospective Randomized Interventional Study. Journal of Thyroid Research. 2013.

16. Sadq G. Kadem, Sarmad M. Habash, et al. Transoral Endoscopic Thyroidectomy via Vestibular Approach; A series of the first ten cases in Iraq. Sultan Qaboos University Medical. 2019;19:68-72.

17. T. Sivakumar, R. A. Amizhthu. Transoral endoscopic total thyroidectomy vestibular approach: A case series and literature review. Journal of Minimal Access Surgery. 2017;20:1-6.

18. Christian Camenzuli, Pierre Schembri Wismayer, et al.

Transoral Endoscopic Thyroidectomy: A Systematic Review of the Practice So Far. *Journal of Society of Laparoscopic Surgeons*. 2018;22:1-12.

19. Cong Bian, Hui Liu, XI Yu YAO, et al. Complete endoscopic radical resection of thyroid cancer via an oral vestibule approach. *Oncology Letters*. 2018;16:5599-5606.

20. N. Suslu, S. Vural, M. Oncel, et al. Is the insertion of drains after uncomplicated thyroid surgery always necessary? *Surgery Today*. 2006;36:215-218.

21. Jonathon O. Russell, Christopher R. Razavi, et al. Anterior Cervical Incision-Sparing Thyroidectomy: Comparing Retroauricular and Transoral Approaches. *Laryngoscope Investigative Otolaryngology*. 2018:1-6.

22. Nathan James Hayward, Simon Grodski, Meei Yeung, et al. Recurrent laryngeal nerve injury in thyroid surgery: a review. *ANZ Journal of Surgery*. 2013;83:15-21.

23. Mohamed Benkhadoura, Salah Taktuk, Reem Alobedi. Recurrent laryngeal nerve injury and hypoparathyroidism rates in reoperative thyroid surgery. *Turkish Journal of Surgery*. 2017;33:14-17.

24. Gaëtan-Romain Joliat, Valentine Guarnero, et al. Recurrent laryngeal nerve injury after thyroid and parathyroid surgery, Incidence, and postoperative evolution assessment. *Medicine*. 2017;96:17.

25. Thomas Wilhelm. *Trans-oral Endoscopic Thyroidectomy. Minimally Invasive Thyroidectomy*. Springer-Verlag Berlin Heidelberg. 2012:199-220.

26. Xiaowei Peng, Zan Li, Hui Li, et al. The clinical application of mental nerve dissection in transoral endoscopic thyroidectomy via an oral vestibular approach. *Surgical Endoscopy*. 2020;34:153-158.

27. Anuwong A, Ketwong K, Jitpratoom P, et al. Safety and outcomes of the transoral endoscopic thyroidectomy vestibular approach. *JAMA Surg*. 2017;153:21-27.

28. Christopher R. Razavi, Ralph P. Tufano & Jonathon O. Russell. *Current Otorhinolaryngology Reports*. 2019:1-5.

29. Xiaowei Peng, Zan Li, Hui Li, et al. The clinical application of mental nerve dissection in transoral endoscopic thyroidectomy via an oral vestibular approach. *Surgical Endoscopy*. 2020;34:153-158.