

## THE OUTCOME OF LONGITUDINAL DORSAL ISLAND FLAP FOR REPAIR OF HYPOSPADIAS IN CIRCUMCISED PATIENTS AND THOSE WITH FAILED PREVIOUS REPAIR

Majed Asgar Mohammad\*, Firas Shakir Attar<sup>@</sup>, & Khaldon Sadek Alkhateep<sup>#</sup>.

\*<sup>@</sup> MB,ChB, FIBMS, Assistant Professors of urology at Basrah College of Medicine, University of Basrah, Consultant Urologists at Basrah Teaching Hospital, Basrah. <sup>#</sup>MB,ChB, FIBMS, Specialist Urologist at Al-Mawani General Hospital, Basrah, IRAQ.

### Abstract

Patients with penoscrotal, proximal shaft and mid shaft hypospadias who were previously circumcised or patients with insufficient urethral plate such as those with severe chordee that cannot be corrected just by simple degloving, or failure of previous hypospadias repair, such patients represent a challenge for subsequent repair and appropriate procedure choice.

The aim of this study is to assess the outcome of longitudinal dorsal island flap (LDIF) by both onlay and tubularized repair for patients with hypospadias who were previously circumcised or had poorly developed urethral plate.

This prospective study was done on 36 patients who had penoscrotal, proximal and mid shaft hypospadias and were previously circumcised or had poorly developed urethral plate. Twenty four of them were operated upon by using onlay LDIF and 12 patients by using tubularized LDIF. Patients were followed-up for 12 months to look for any complication for these 2 types of surgeries and for assessing the functional outcome of the repair.

The success rate for onlay LDIF was 75% and for tubularized LDIF was 58.33%. Overall complications occurred in 11 (30.55%) children.

In conclusion, LDIF can be used successfully for repair of hypospadias in circumcised children or those with failed previous repair.

**Keywords:** *Hypospadias, LDIF, failed repair, tubularized incised plate urethroplasty*

### Introduction

Hypospadias is a congenital disorder of the urethra where the external meatus is located on the ventral penile aspect. It is the second most common birth abnormality of the male reproductive system<sup>1</sup>. In most cases, the frenulum is entirely missing; however, in rare cases the prepuce could be normal. The prepuce must be preserved early in life and a ritual neonatal circumcision should be avoided to make use of the preputial skin for future repair<sup>2</sup>.

The multi-factorial etiology of hypospadias is becoming more defined with ongoing investigations. Implicated factors include testosterone biosynthesis defects, 5 alpha-reductase type 2 mutations, androgen receptor mutations,

in vitro fertilization (IVF), progesterone administration or abnormalities of the endocrine system<sup>3</sup>.

The incidence of hypospadias is about 1 in each 250 newborn babies<sup>4</sup>. The fact that there are over 250 methods of surgical corrections of hypospadias described in the literature indicates that the “hypospadiologists” are still in search for the ideal technique<sup>5</sup>.

The term ‘hypospadias cripple’ has been applied for individuals with remaining functional complications after multiple attempts of hypospadias repair. Affected men have a heavy burden of psychological problems related to the complications of failed hypospadias repair<sup>6</sup>. Complications of the initial repair

vary widely and include urethro-cutaneous fistula, urethral stricture, glans dehiscence, persistent hypospadias, hair in the urethra, urethral stones, penile shortening, penile curvature, and penile torsion<sup>7</sup>.

This study aimed to evaluate the outcome of using longitudinal dorsal island flap (LDIF) for the repair of circumcised patients with proximal, mid and peno-scrotal hypospadias and patients with severe chordee or those with failed previous hypospadias repair.

### Patients and methods

This prospective study was done in Basrah General Hospital at urology department from May 2016 till December 2018. Thirty six patients were included in the cohort. Their age ranged from 3 years to 12 years. The included children either were circumcised or had insufficient urethral plates associated with severe chordee or previous repair failure. Six patients were operated upon but excluded from the study because they did not attend regular follow-up.

The inclusion criteria were: Patients with penoscrotal, proximal and mid-shaft hypospadias with history of previous circumcision. Patients with poorly developed urethral plate due to previous failure of hypospadias repair or severe chordee.

The exclusion criteria were: Patients with proximal hypospadias beyond the penoscrotal junction. No complaint patients. Previous failure of the same procedure of (LDIF). Diabetic or immune compromised patients. Patients who are candidates for tubularized incised plate urethroplasty (TIP) repair.

The surgical steps of LDIF start with placing the patient in supine position after having general anesthesia. Prophylactic antibiotics such as ceftriaxone vial 50 mg/kg body weight were given. Stay suture 3/0 vicryl is placed in the glans after insertion of 8 Fr feeding tube to the bladder. Degloving of the penis was done

completely and tourniquet was applied intermittently to the base of the penis to help in hemostasis. When thin distal urethra is present, it should be cut back till the level of normal spongiosum-covered urethra. In children with mild chordee correction is assessed by visual assessment after degloving; while in children with the presence of severe chordee, correction is assessed by producing an artificial erection by injection of normal saline in the corpora cavernosa. After correction of chordee, the glans wings are raised and the required length of LDIF is outlined from the dorsal skin in the midline. The flap is harvested from the distal half of the dorsal penile skin; with taking care not to extend too much to the proximal part of dorsal skin. The width of the flap is measured in such a way that it gives a neourethral caliber of at least 8-10 Fr in younger children and 10-12 Fr in older children. The dorsal flap is carefully isolated on its vascular pedicle and dartos attachment, separating it from the two lateral skin flaps. When the dissection is finished, the LDIF is transposed to the ventral site of the penis by making a hole in the center of its mesentery attachment near its base. For the onlay urethroplasty, the flap is sutured to the urethral plate by using 5/0 or 6/0 vicryl sutures starting from the base of the flap around the original meatus and continues distally till reaching to the neomeatus at the glans. Then the distal edge of the flap is sutured to the distal half of the glans after wide glans wings mobilization. For the tubularized repair, when the urethral plate is removed for correction of chordee, the proximal anastomosis is done by spatulation of the tube with the original meatus. An 8 or 10 Fr feeding tube is kept. The lateral flaps are then ventrally transposed to cover the neourethra and glanuloplasty is performed by closing the glans wings over the neourethra using 5/0 vicryl sutures in mattress fashion and the penile skin is closed. Dressing was placed

over the glans. The feeding tube was kept for 7-14 days. The child was discharged home after 2-3 days and the dressing was changed on the 4th post-operative day. Follow-up of children was carried out at 1 month, 3 months, 6 months and one year postoperatively by assessing the flow rate by uroflowmetry and any complication.

## Results

The mean age of the patient was 7.5 year (3-12) years (Table I). The hypospadias site was recognized as mid shaft,

proximal shaft and peno-scrotal meatus in 25, 6 and 5 cases respectively (Table II). Twenty four cases of the total 36 had circumcision and had no chordee and were operated upon by onlay LDIF, while in 12 cases, the urethral plate was excised due to the presence of severe chordee or fibrosis and a tubularized LDIF repair was performed (Table III). Excision of the urethral plate successfully corrected the chordee in those patients. The length of the urethral repair was ranged from about 1- 6 cm roughly (Table IV).

Table I: Number of patients in each age group.

Age	Number of patients	Percentage
3-6 years	10	27.77%
7-9 years	18	50%
10-12 years	8	22.22%

Table II: The site of meatus.

Site of meatus	Number of patients	Percentage
Midshaft	25	69.55 %
Proximal shaft	6	16.66 %
Penoscrotal	5	13.88 %

Table III: Number and percentage of cases in each group of onlay and tubularized LDIF repair.

Type of flap	Number of cases	percentage
Onlay LDIF	24	66.67%
Tubularized LDIF ( Excision of urethral plate was done )	12	33.33%

Table IV: The average length of the required urethral repair.

Length of the urethra	Number of cases	Percentage
<2cm	12	33.3%
2-6 cm	22	61.11%
>6 cm	2	5.55%

The success rate was 75% for onlay repair and 58.33% for tubularized repair so the overall mean success rate was 69.44% (fig.1). Complications occurred in 11 patients among all the 36 patients

who were operated upon by both onlay or tubularized LDIF, including 6 patients after onlay repair and 5 patients after tubularized repair (Table V).

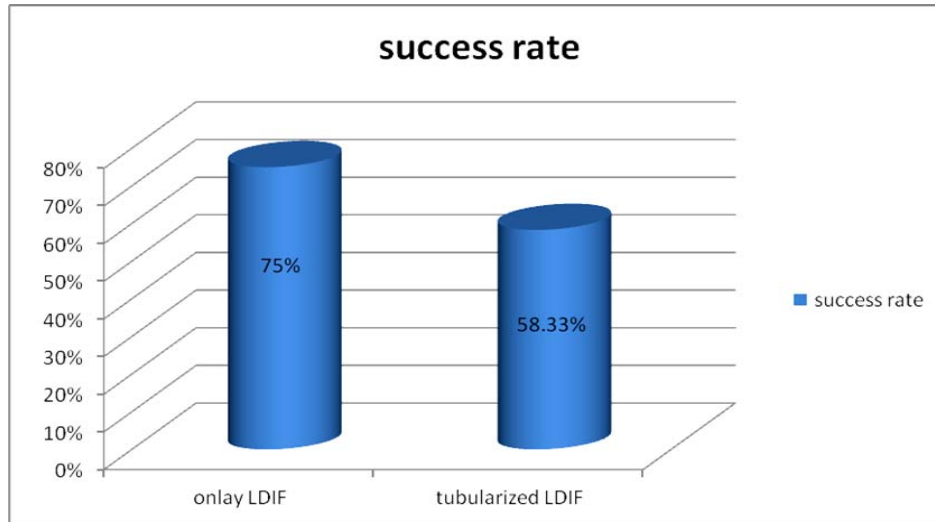


Figure 1: Success rate for each onlay and tubularized LDIF repair

Table V: Percentage of complications in LDIF repair

Type of repair	Number of patients	Number of complications	Percentage
Onlay repair	24	6	25%
Tubularized repair	12	5	41.66 %
Total	36	11	30.55%

Regarding the flow rate which was done at 3, 6 and 12 months after correction, the

mean range of improvement was from 8 ml per second to 11 ml per second (fig.2).

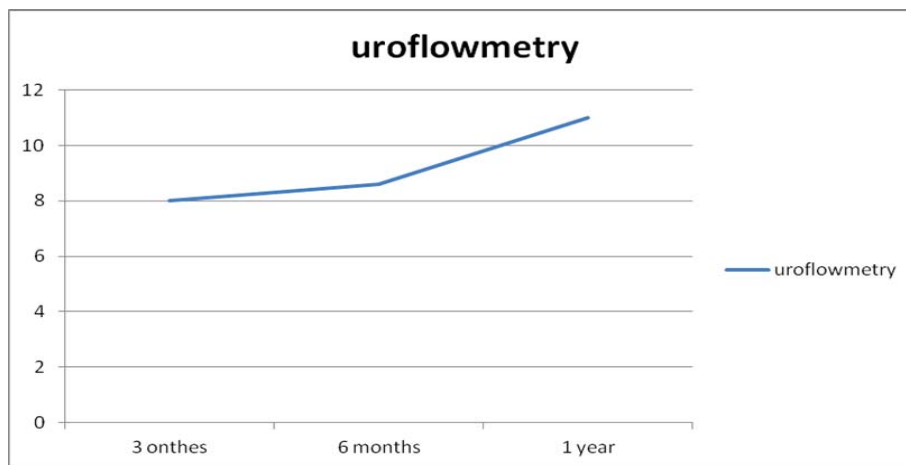


Figure 2: Flow rate ml per second in 3, 6 and 12 months follow-up.

Complications included neourethral stricture which occurred in 1 case in onlay repair group and another 1 case in tubularized repair group. Fistula occurred in 2 cases of onlay repair and 2 cases of tubularized repair. Glans dehiscence in 2 cases of onlay repair and 1 case of

tubularized repair. Urethral diverticulum occurred only in 1 case of tubularized repair and neomeatus which occurred in 1 case of onlay repair. No case of any types of LDIF developed flap necrosis, penile shortening or penile curvature (fig.3).

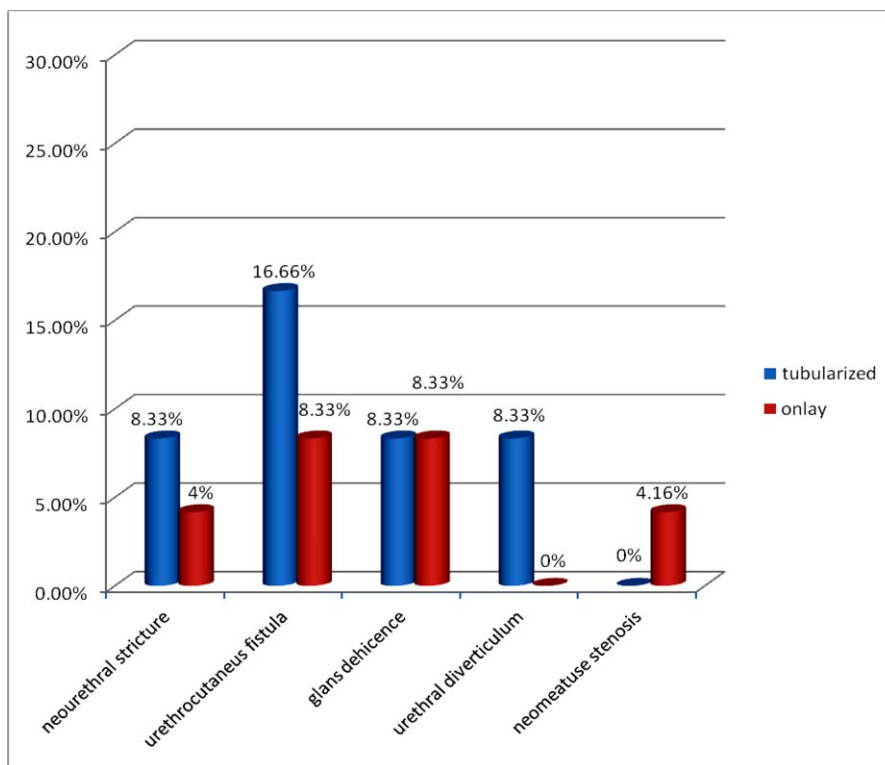


Figure 3: Types and percentage of complication for onlay and tubularized repair

### Discussion

In this study, the outcome of the LDIF was reviewed. It is found that correction of hypospadias by using single stage LDIF has good overall success rate with acceptable complication rates. The rate was 30.55% which is comparable with the other studies<sup>8-12</sup>. The complications of the tubularized longitudinal dorsal island flap repair was more than with onlay LDIF repairs (41.6% vs. 25%). Because of preservation of the urethral plate in most of the recruited cases, the use of the onlay repairs was more than tubularized repair, with better results and fewer rates of complications as was found by a previous research<sup>13</sup>. Children with severe chordee or previous surgery

requiring excision of the urethral plate may require a 2-stage repair; however, a 60% success rate may be achieved by using tubularized LDIF repair in selected cases as a single stage procedure<sup>14,15</sup>. In comparison of our results with tunneled buccal mucosa tube grafts for repair of proximal hypospadias, Aivar Bracka and Dino Papeš found in their study of 34 patient that the overall complication in one year follow-up was 32% (11 patients), including fistula in 5, proximal stricture in 4 and meatal stenosis in 2 patients. In the first 10 patients a total of 7 complications (70%) developed but there were only 4 complications in the next 24 patients (16%)<sup>16</sup>.

In this study, LDIF had more advantages over the transverse preputial flaps repair. This is mainly due to the axial direction of blood supply to the LDIF. In addition, these lateral flaps will provide ventral skin cover over the area of anastomosis<sup>17</sup>. According to surgical principles, the axial flap has better blood supply than a transverse flap<sup>5</sup>. Necrosis and ischemia of the neourethra has been reported after transverse preputial island flap repair in about 7% to 10% of cases in other studies<sup>6</sup>. However, we had no case of necrosis of the flap or distortion in our study. There is high risk of penile torsion when the transverse preputial flap is transposed on the ventral aspect of the penis and is then oriented in a vertical direction for urethroplasty repair<sup>9</sup>. Due to the original longitudinal orientation of the LDIF, there is no risk of penile rotation or torsion<sup>17</sup>. Another important advantage of using the LDIF technique is the mesentery of the flap naturally falls in place to cover the neourethral suture lines which helps in decreasing the risk of various complication<sup>3,17</sup>.

For children with distal and mid penile hypospadias who have a good urethral plate, the TIP repair gives excellent cosmetic and functional results usually and it is still the first choice of repair in such cases. However, hypospadias that have poorly developed urethral plate and more proximal may not be suitable for TIP repair so it is preferred to do LDIF repair. Holland and Smith studied the impact of urethral plate width and depth on the results following TIP repair for distal hypospadias<sup>18</sup>. They noted that fistulae commonly occur in children with narrow (<8mm width) urethral plates while shallow or flat urethral plates resulted in increased risk of neourethral stenosis. Urethral stricture is one of the most complex and difficult complications to be repaired. Some reports documented abnormal flow curves with obstructive pattern after TIP repair, sometimes even in the absence of an actual stricture<sup>19</sup>. To

overcome the penile torsion that was associated with the original Duckett's technique, authors modified the new technique by button holing the base of the mesentery for ventral transposition of the flap<sup>20</sup>. One of the main limitations of using LDIF technique as compared with other island flaps technique, is the limitation in the length of urethra that can be bridged for correction of hypospadias. In this study and by our personal experience of the use of the dorsal flap, we could provide about 2-6 cm length (mean length of LDIF in our study is 32 mm). Because the LDIF is raised from non-hair bearing skin, it has been employed successfully in adolescents and adults also<sup>17</sup>.

Interestingly, we noted in our study that types of complications after onlay and tubularized technique for repair were different. Glans dehiscence was more common after onlay repair surgery, mainly due to the bulk of tissue over which the glans needed to be sutured. An article reported about 5% of glans dehiscence occur after TIP repair, especially in patients with proximal hypospadias<sup>21</sup>.

Management of severe proximal hypospadias is challenging and several surgical techniques are suggested as single-stage procedures<sup>22-24</sup>. Previously they believed that no single surgical procedure that is ideal and the quest for such procedure continues<sup>25</sup>. There have been a lot of procedures of the two-stage for such severe proximal hypospadias cases in recent years<sup>26</sup>.

In conclusion, LDIF can be used for single-stage repair of mid, proximal and peno-scrotal hypospadias especially in circumcised children or those with failed previous repairs with good success and a relatively acceptable complication rate regarding onlay flap repair and tubularized flap repair. Onlay repairs had fewer complications than tubularized repairs.

## References

1. Snodgrass, Warren (2012). "Chapter 130: Hypospadias". In Wein, Allan. Campbell-Walsh Urology, Tenth Edition. Elsevier. pp. 3503–3536.
2. Perovic S, Djakovic N, Hohenfellner M. Penis-und Harnröhrenmissbildungen. Der Urologe, Ausgabe A. 2004 Apr 1;43(4):394-401.
3. Snodgrass W. Tubularized, incised plate urethroplasty for distal hypospadias. The Journal of urology. 1994 Feb;151(2):464-5.
4. Semenza JC, Tolbert PE, Rubin CH, Guillette Jr LJ, Jackson RJ. Reproductive toxins and alligator abnormalities at Lake Apopka, Florida. Environmental Health Perspectives. 1997 Oct;105(10):1030.
5. Djakovic N, Nyarangi-Dix J, Özturk A, Hohenfellner M. Hypospadias. Advances in urology. 2008 Oct 30;2008.
6. Kiss A, Sulya B, Szász AM, Romics I, Kelemen Z, Tóth J, Merksz M, Kemény S, Nyírády P. Long-term psychological and sexual outcomes of severe penile hypospadias repair. The journal of sexual medicine. 2011 May 1;8(5):1529-39.
7. Myers JB, McAninch JW, Erickson BA, Breyer BN. Treatment of adults with complications from previous hypospadias surgery. The Journal of urology. 2012 Aug 31;188(2):459-63.
8. Dason S, Wong N, Braga LH. The contemporary role of 1 vs. 2-stage repair for proximal hypospadias. Translational andrology and urology. 2014 Dec;3(4):347.
9. Singh BP, Solanki FS, Kapoor R, Dassi V, Kaswan HK, Agrawal V, Swain SK, Andankar MG, Pathak HR. Factors predicting success in hypospadias repair using preputial flap with limited pedicle mobilization (Asopa procedure). Urology. 2010 Jul 31;76(1):92-6.
10. Patel RP, Shukla AR, Austin JC, Canning DA. Modified tubularized transverse preputial island flap repair for severe proximal hypospadias. BJU international. 2005 Apr 1;95(6):901-4.
11. Sedberry-Ross S, Stisser BC, Henderson CG, Rushton HG, Belman AB. Split prepuce in situ onlay hypospadias repair: 17 years of experience. The Journal of urology. 2007 Oct 31;178(4):1663-7.
12. Barroso U, Jednak R, Barthold JS, Gonzalez R. Further experience with the double onlay preputial flap for hypospadias repair. The Journal of urology. 2000 Sep 30;164(3):998-1001.
13. Baskin LS, Duckett JW, Ueoka K, Seibold J, Snyder 3rd HM. Changing concepts of hypospadias curvature lead to more onlay island flap procedures. The Journal of urology. 1994 Jan;151(1):191-6.
14. Barbagli G, De Angelis M, Palminteri E, Lazzeri M. Failed hypospadias repair presenting in adults. European urology. 2006 May 31;49(5):887-95.
15. Andrich DE, Greenwell TJ, Mundy AR. The problems of penile urethroplasty with particular reference to 2-stage reconstructions. The Journal of urology. 2003 Jul 31;170(1):87-9.
16. Bracka A, Papeš D. Re: Tunneled Buccal Mucosa Tube Grafts for Repair of Proximal Hypospadias: R. Fine, EF Reda, P. Zelkovic, J. Gitlin, J. Freyle, I. Franco and LS Palmer J Urol, suppl., 2015; 193: 1813-1817. The Journal of urology. 2016 Jan;195(1):226.
17. Erol A, Baskin LS, Li YW, Liu WH. Anatomical studies of the urethral plate: why preservation of the urethral plate is important in hypospadias repair. BJU international. 2000 Apr 1;85(6):728-34.
18. Perović S, Vukadinović V. Penoscrotal transposition with hypospadias: 1-stage repair. The Journal of urology. 1992 Nov 1;148(5):1510-3.
19. Jordan GH. Techniques of tissue handling and transfer. The Journal of urology. 1999 Sep 1;162(3):1213-7.
20. Patel RP, Shukla AR, Austin JC, Canning DA. Modified tubularized transverse preputial island flap repair for severe proximal hypospadias. BJU international. 2005 Apr 1;95(6):901-4.
21. Barbagli G, Perovic S, Djinovic R, Sansalone S, Lazzeri M. Retrospective descriptive analysis of 1,176 patients with failed hypospadias repair. The Journal of urology. 2010 Jan 31;183(1):207-11.
22. Glassberg KI, Hansbrough F, Horowitz M. The Koyanagi-Nonomura 1-stage bucket repair of severe hypospadias with and without peno-scrotal transposition. The Journal of urology. 1998 Sep 30;160(3):1104-7.
23. Demirbilek S, Kanmaz T, Aydin G, Yücesan S. Outcomes of one stage techniques for proximal hypospadias repair. Urology. 2001 Aug 31;58(2):267-70.
24. Castanon M, Munoz E, Carrasco R, Rodo J, Morales L. Treatment of proximal hypospadias with a tubularized island flap urethroplasty and the onlay technique: a comparative study. Journal of pediatric surgery. 2000 Oct 31;35(10):1453-5.
25. Johal NS, Nitkunan T, O'Malley K, Cuckow PM. The two-stage repair for severe primary hypospadias. European urology. 2006 Aug 31;50(2):366-71.
26. Snodgrass WT. Re: Skin graft for 2-stage treatment of severe hypospadias: Back to the future? The Journal of urology. 2003 Jul 31; 170(1):193-4.