

# Investigation of Montelukast Effect on Rosuvastatin Induced Late Puberty in Rats

Tamadir Hamid Wadi Aledani, Manal Nasser Al-Hayder<sup>1</sup>, Suha Haitham Mohammed, Rawaa Salim Al-Mayyahi

Departments of Clinical Laboratory Sciences and <sup>1</sup>Pharmacology and Toxicology, College of Pharmacy, University of Basrah, Basrah, Iraq

## ABSTRACT

**Background:** Puberty is a critical process for the development of sexual organs and reproductive ability. It is triggered and regulated by the hormones. Rosuvastatin can delay the onset of puberty through the inhibition of cholesterol and androgen biosynthesis. On the other hand, montelukast has protective effects against various diseases and against reproductive toxicity induced by other medications, but its effects on puberty have not been studied. **Aims:** Assessment of the protective effect of montelukast against rosuvastatin-induced delayed puberty. **Settings and Design:** At the university. **Materials and Methods:** Eighteen male Wistar rats aged 30 days and weighted 50–60 g were distributed to three groups (six rats per group) and intraperitoneally administered every day for 5 days with 0.2 ml of distilled water as control, 10 mg/kg of rosuvastatin and with rosuvastatin + montelukast (10 mg/kg for each drug). These animals' groups were euthanised on day 50 of age to assess the effect of rosuvastatin alone and with montelukast on the serum levels of the reproductive hormones and histological manifestations and morphometric measurements of the testes. **Statistical Analysis Used:** One-way analysis of variance and Bonferroni multiple tests were performed to analyse the findings using the GraphPad Prism software. **Results:** Treatment of rats with rosuvastatin showed a significantly decreased level of testosterone and luteinising hormone as well as histopathological and morphometric alterations in the testicular tissues in comparison with the control. Interestingly, co-treatment of rosuvastatin with montelukast could not reverse or mitigate these changes induced late puberty. **Conclusion:** There is no protective effect of montelukast against rosuvastatin-induced delayed puberty.

**KEYWORDS:** *Histopathology, hormones, montelukast, morphometry, puberty, rosuvastatin*

## INTRODUCTION

Puberty is a complex physiological process for the development of sexual organs and reproductive ability.<sup>[1]</sup> Puberty is triggered by the secretion of gonadotropin-releasing hormone from hypothalamus that induces the pituitary gland to release gonadotropins (luteinising hormone and follicle-stimulating hormone) into bloodstream. These hormones stimulate the gonads (ovaries and testes) to produce sex steroids (oestradiol and testosterone).

During puberty, the steroids are increased in both sexes, but the level of testosterone is greater in boys in contrary to oestradiol which has a greater level in girls.<sup>[2]</sup>

The onset of puberty may be early or late depending on the various causes.<sup>[3]</sup> Genetic factors, nutrition, general health and endocrine-disrupting environmental chemicals play a role in the timing of puberty. Delayed puberty can be resulted from constitutional delay of puberty and

Received: 22-04-2022

Revised: 03-08-2022

Accepted: 10-08-2022

Published: 30-09-2022

### Access this article online

Quick Response Code:



Website:  
www.jhrsonline.org

DOI:  
10.4103/jhrs.jhrs\_56\_22

**Address for correspondence:** Dr. Tamadir Hamid Wadi Aledani, HP7V+QX8, Basrah, Iraq.  
E-mail: tamadir.wadi@uobasrah.edu.iq

This is an open access journal, and articles are distributed under the terms of the Creative Commons Attribution-NonCommercial-ShareAlike 4.0 License, which allows others to remix, tweak, and build upon the work non-commercially, as long as appropriate credit is given and the new creations are licensed under the identical terms.

For reprints contact: WKHLRPMedknow\_reprints@wolterskluwer.com

**How to cite this article:** Aledani TH, Al-Hayder MN, Mohammed SH, Al-Mayyahi RS. Investigation of montelukast effect on rosuvastatin induced late puberty in rats. *J Hum Reprod Sci* 2022;15:228-32.

growth as the most recurrent cause, in addition to gonadal failure, and permanent and functional hypogonadotropic hypogonadism which is caused by chronic diseases including asthma.<sup>[4]</sup> Malnutrition and weight loss are also considered in delayed puberty. Lower body fats are associated with decreased secretion of luteinising and follicle-stimulating hormones leading to the inhibition of oestrogen production. Furthermore, significant decreased calories result in gonadotropin deficiency as a consequence of decreasing in leptin concentration.<sup>[5]</sup> In addition, some medications can delay puberty and impair the development of reproductive organs such as rosuvastatin. Rosuvastatin was approved by the United States Food and Drug Administration agency in 2009 for children with heterozygous familial hypercholesterolemia at the age of 10 years or older and it is one of the statins used during childhood to treat dyslipidemias in obese children (males and females) through decreasing total cholesterol and triglycerides. It inhibits cholesterol biosynthesis enzyme (3-hydroxy-3-methyl-glutaryl coenzyme A reductase) and androgen biosynthesis. Androgen plays an essential role in the development and maturation of reproductive organs. The reduction of androgen may induce oxidative stress and DNA damage resulting in the death of the germ cells.<sup>[6,7]</sup>

On the other hand, another medication (montelukast) is used for children to treat paediatric asthma. Montelukast is leukotriene receptor antagonist that reduces the exacerbation of asthma.<sup>[8]</sup> It has properties of anti-inflammation, anti-oxidation and anti-apoptosis that exert protective effects against various diseases.<sup>[9,10]</sup> Moreover, the protective effects of montelukast have also been reported against reproductive toxicity induced by other medications such as doxorubicin.<sup>[11]</sup> However, the effects of the anti-asthmatic drug (montelukast) on puberty have not been studied; although asthma is indirectly considered in delayed puberty. Therefore, the objective of this investigation was to assess the protective effect of montelukast on the reproductive harms of rosuvastatin-induced delayed puberty because the two drugs have been used for children and perhaps at same time. Furthermore, the effect of montelukast as a protective agent against the reproductive toxicity of rosuvastatin has not been studied, as the effect of ascorbic acid on rosuvastatin-induced delayed puberty.

## MATERIALS AND METHODS

### Animals, study design, and ethical approval

Healthy, were free from genetic modifications, adult males and females Wistar albino rats were housed and mated in an animal house at the university under the controlled conditions of the light cycle and temperature.

After gestation and giving births, on postnatal day 30, 18 male neonates (50–60 g in weight) were selected and distributed in polypropylene cages into three groups (six rats per group): the control group received 0.2 ml of distilled water, the second group received 10 mg/kg rosuvastatin (Pioneer, Iraq)<sup>[12]</sup> and the third group received 10 mg/kg montelukast<sup>[13]</sup> (Pioneer, Iraq) co-administered with an equivalent dose of rosuvastatin (rosuvastatin + montelukast). The drugs were dissolved in distilled water and administered intraperitoneally every day (once time/day) for 5 days, after that, the animals were maintained until reaching the age of puberty and were euthanized at age of 50 days. Experimental protocol and animal using and care were approved by the ethical committee of our university for animal research with approval issue No. 2204001. All national ethical guidelines were applied in the current investigation involving housing, water and food, cleaning, acclimatisation, safety, movement freedom and avoiding unnecessary pain and distress. Furthermore, according to these ethical guidelines, animals' number as possible should be reduced in animal research, that determined the sample size in this study with considering the statistical acceptance.

### Evaluation of serum hormones

All animals were anaesthetised with diethyl ether to prevent pain, suffering and distress during cardiac puncture use to collect blood samples. Then, these samples were centrifuged (2400 rpm, 20 min) using a refrigerated apparatus (Genex, Florida, USA) to obtain serum. Luteinising hormone, testosterone and follicle-stimulating hormone levels in the serum were evaluated by commercial kits and I-Chroma II Immunoassay Analyzer (Boditech, Korea).

### Testicular histopathologic and morphometric analyses

When the animals were dissected, testes were removed and fixed with paraformaldehyde. The testes were sectioned at the thickness of 5 µm using the rotary microtome and then stained with haematoxylin and eosin. LCD light microscope (Genex, USA) was used for the examination and photography histological slides. Histomorphometric analysis was performed on testes cross sections to measure the testicular parameters (diameter, epithelium thickness and lumen size of the seminiferous tubules). Digital images (×200 magnification) of ten randomly selected microscopic fields were analysed with ImageJ software (National Institutes of Health, USA).

### Statistical analysis

The findings were statistically analysed by the one-way analysis of variance and a comparison test (Bonferroni

multiple tests) through version 5.0 of GraphPad Prism software (San Diego, CA, USA). Mean  $\pm$  standard error of the mean and significant  $P < 0.05$  was considered in this study.

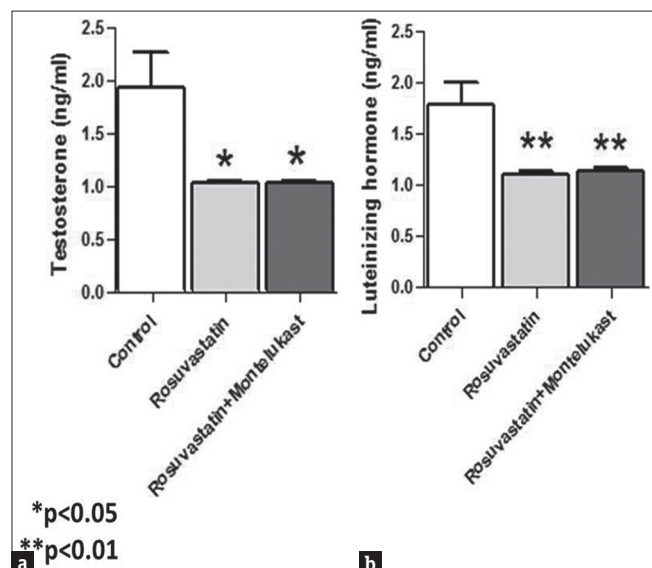
## RESULTS

### Serum levels of reproductive hormones

The concentrations of testosterone and luteinising hormone were significantly reduced in the serum as a result of rats' treatment with rosuvastatin and rosuvastatin + montelukast compared to the control [Figure 1], while the concentration of follicle-stimulating hormone in both treated groups was similar to the control group.

### Histopathological and morphometric findings of testes

The histopathological study of testicular sections of the control group showed normal spermatogenic and sertoli cells in the seminiferous tubules with normal lumens and normal Leydig cells in interstitial tissue between adjoining seminiferous tubules [Figure 2a]. In contrast, the testicular sections of rosuvastatin and rosuvastatin + montelukast groups were associated with the signs of structural damage. The two treated groups revealed degeneration in several seminiferous tubules resulting in evident germ cell loss and the absence or decrease of spermatozoa within the expanded lumen compared with the control group. The presence of acidophilic spermatocytes, clear vacuolisation in germinal epithelium and loss of interstitial connective tissue replaced with foci of congestions were also



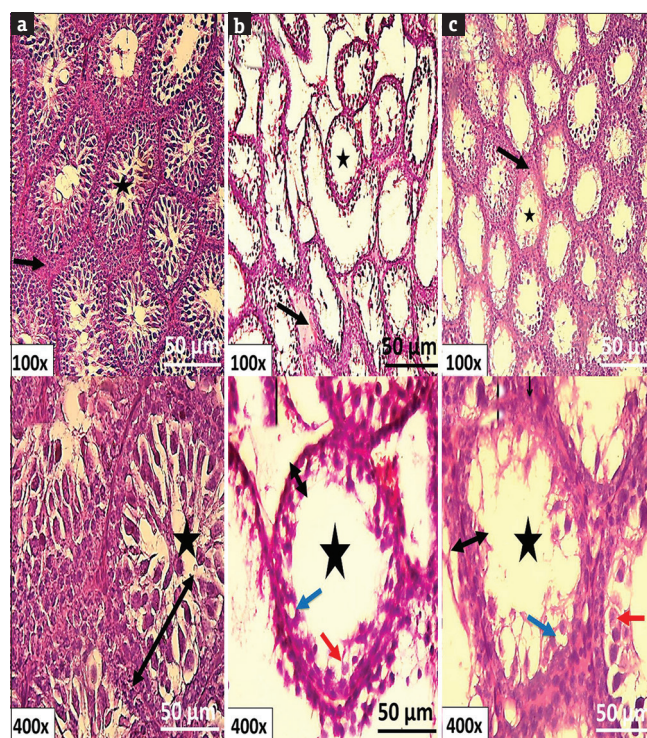
**Figure 1:** Significant levels of serum reproductive hormones for experimental groups. (a) Testosterone levels in rosuvastatin treated rats and rosuvastatin+montelukast co-treated rats compared to the control. (b) Luteinizing hormone levels in the two treated groups compared to the control

observed in the two treated groups compared with the untreated group [Figure 2b and c].

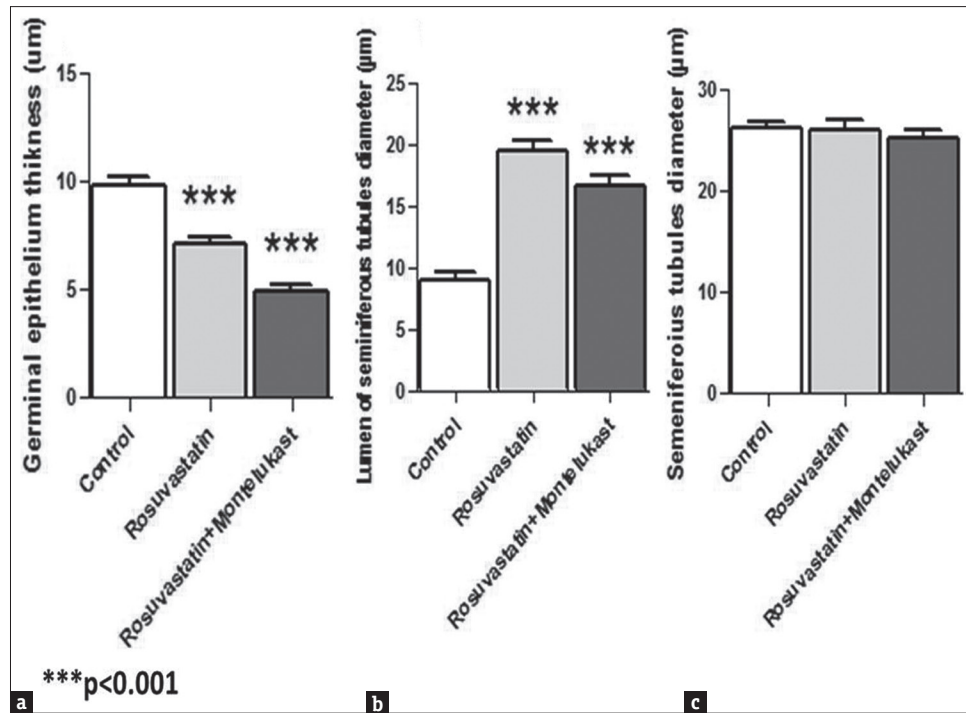
Testicular histomorphometric analysis showed that there were no significant differences with respect to the external diameter of seminiferous tubules, while there was a significant decrease of the epithelium thickness opposite to a significant increase in the size of the tubule lumen in the two treated (rosuvastatin and rosuvastatin + montelukast) groups compared with untreated group [Figure 3].

## DISCUSSION

Male albino rats become pubertal at the age of 42–48 days.<sup>[14,15]</sup> Pubertal development can be estimated by measuring hormone levels, hormonal measurement is typical to represent puberty.<sup>[2]</sup> Before puberty, testosterone level in the rats' serum and plasma is low and initiates a significant increase at puberty, and then, it reaches to a maximum at the puberty end to decrease gradually in the adult rats.<sup>[16]</sup> In present study, testosterone level in the serum was significantly lower in the rosuvastatin and rosuvastatin+montelukast groups



**Figure 2:** Histological examination of testicular sections stained with haematoxylin & eosin. (a) Normal seminiferous tubule with sperm in the lumen (asterisk) lined by germinal epithelium (double arrow) and surrounded by interstitial connective tissue (black arrow) in control group. (b) and (c) Photomicrographs of rosuvastatin treated rats and rosuvastatin+montelukast co-treated rats respectively showing degeneration in seminiferous tubules, lacking or few sperms in expanded lumen of seminiferous tubules (asterisk), presence of acidophilic spermatocytes (red arrow), loss of interstitial connective tissue with foci of congestions (black arrow) and clear vacuolisation in germinal epithelium (blue arrow)



**Figure 3:** Histomorphometric analysis of rats' testes. (a) Germinal epithelium thickness in rosuvastatin treated rats and rosuvastatin+montelukast co-treated rats versus control group. (b) and (c) Lumen diameter and seminiferous tubules diameter respectively across all conditions

compared to the control. This significant decrease in testosterone level can be an indicator of delayed puberty according to Zemunik *et al.*<sup>[16]</sup> It is well known that rosuvastatin can retard puberty and reduce serum testosterone concentration as a consequence of decreasing cholesterol by rosuvastatin (lipid-lowering drug) treatment; cholesterol is needed for testosterone synthesis,<sup>[12,17,18]</sup> but our outcome of co-treatment of rosuvastatin with montelukast was not in agreement with the protective role of montelukast against reproductive toxicity of cytotoxic drugs (doxorubicin and cisplatin) and it can ameliorate the decreased level of testosterone in adult male rats resulting from the administration of these drugs.<sup>[11,19]</sup> Moreover, montelukast has antioxidant and protective activities against hepatotoxic and myopathic effects of simvastatin.<sup>[20]</sup> Serum level of luteinising hormone also significantly diminished in the two treated groups compared to the untreated group, this result agreed with previous findings of rosuvastatin treatment during the pre-puberty of male rats,<sup>[21]</sup> but it disagreed with other studies.<sup>[12,17]</sup> Both treated groups did not differ from the control for the concentration of follicle-stimulating hormone in the serum, this result was in agreement with.<sup>[12,17]</sup> That might be due to the negative feedback regulation of follicle - stimulating hormone secretion by the direct action of inhibin on the pituitary gland. Inhibin is synthesized in the testes by Sertoli cells.<sup>[22]</sup> These cells underwent degeneration in the damaged testicular tissue of both treated groups

leading to reduction of the inhibin, which in turn resulted in negative regulation of follicle - stimulating hormone.

Furthermore, the current study exhibited other histopathological and morphometric alterations of the testicular tissues in the rosuvastatin and rosuvastatin+montelukast groups compared to the control, some of these alterations such as abnormal seminiferous tubules and the presence of acidophilic cells were in accordance with the results of rats' treatment with rosuvastatin.<sup>[12,17]</sup> Loss of germ cells induced by rosuvastatin treatment might be caused by a reduced level of testosterone, androgen depletion and oxidative stress-induced DNA damage resulting in death of germ cells represented by acidophilic cells.<sup>[12]</sup> Declined testosterone concentration leads to failure of spermatogenesis and apoptosis or sloughing of germ cells.<sup>[23,24]</sup> Sloughing of germ cells might be involved in the significant reduction of germinal epithelium thickness and subsequently significant expansion in the lumens of seminiferous tubules, but these morphometric findings did not agree with unaltered morphometric measurements of the previous studies.<sup>[12,17]</sup> It is noticeable that co-administration of montelukast with rosuvastatin could not ameliorate the histopathologic and morphometric alterations, although administration of montelukast can improve the alterations and damage induced by doxorubicin and cisplatin in the testicular histology of rats.<sup>[11,19]</sup> Worthy of mention, there are scarce studies on the relationship of montelukast with

reproductive toxicity. In addition, according to our search, there is not yet an available study on the effect of montelukast on puberty and against rosuvastatin.

## CONCLUSION

Herein, the prominent conclusion of this investigation, montelukast cannot eliminate the harms of rosuvastatin-induced delayed puberty in albino rats. It does not exert protective or anti-apoptotic effects against rosuvastatin treatment-mediated germ cell death and decline of serum testosterone level.

## Financial support and sponsorship

Nil.

## Conflicts of interest

There are no conflicts of interest.

## Data availability statement

The corresponding author has the data and they will be available on appropriate request.

## REFERENCES

- Alotaibi MF. Physiology of puberty in boys and girls and pathological disorders affecting its onset. *J Adolesc* 2019;71:63-71.
- Herting MM, Sowell ER. Puberty and structural brain development in humans. *Front Neuroendocrinol* 2017;44:122-37.
- Khan L. Puberty: Onset and progression. *Pediatr Ann* 2019;48:e141-5.
- Raivio T, Miettinen PJ. Constitutional delay of puberty versus congenital hypogonadotropic hypogonadism: Genetics, management and updates. *Best Pract Res Clin Endocrinol Metab* 2019;33:101316.
- Tang C, Zafar Gondal A, Damian M. Delayed Puberty. In: *StatPearls*. Treasure Island (FL): StatPearls Publishing; 2022. Available from: <http://www.ncbi.nlm.nih.gov/books/NBK544322/>. [Last accessed on 2022 Mar 31].
- Eiland LS, Luttrell PK. Use of statins for dyslipidemia in the pediatric population. *J Pediatr Pharmacol Ther* 2010;15:160-72.
- Leite GA, Figueiredo TM, Guerra MT, Borges CD, Fernandes FH, Anselmo-Franci JA, *et al.* Ascorbic acid co-administered with rosuvastatin reduces reproductive impairment in the male offspring from male rats exposed to the statin at pre-puberty. *Food Chem Toxicol* 2018;118:416-29.
- Lee YJ, Kim CK. Montelukast use over the past 20 years: Monitoring of its effects and safety issues. *Clin Exp Pediatr* 2020;63:376-81.
- El-Boghdady NA, Abdeltawab NF, Nooh MM. Resveratrol and montelukast alleviate paraquat-induced hepatic injury in mice: Modulation of oxidative stress, inflammation, and apoptosis. *Oxid Med Cell Longev* 2017;2017:1-9.
- Chen X, Zhang X, Pan J. Effect of montelukast on bronchopulmonary dysplasia (BPD) and related mechanisms. *Med Sci Monit* 2019;25:1886-93.
- Mohamed MZ, Zenhom NM. Mechanisms underlying the protective effect of leukotriene receptor antagonist montelukast against doxorubicin induced testicular injury in rats. *Prostaglandins Other Lipid Mediat* 2020;149:106447.
- Leite GA, Figueiredo TM, Pacheco TL, Sanabria M, Silva PV, Fernandes FH, *et al.* Vitamin C partially prevents reproductive damage in adult male rats exposed to rosuvastatin during prepuberty. *Food Chem Toxicol* 2017;109:272-83.
- Isikdemir F, Kurcer Z, Dengiz GO, Sipahi EY, Banoglu ZN, Baba F, *et al.* Effects of montelukast and zileuton on testicular torsion/detorsion injury in rats. *Andrologia* 2014;46:59-64.
- Drzewiecki CM, Willing J, Juraska JM. Synaptic number changes in the medial prefrontal cortex across adolescence in male and female rats: A role for pubertal onset. *Synapse* 2016;70:361-8.
- Sengupta P. The laboratory rat: Relating its age with Human's. *Int J Prev Med* 2013;4:624-30.
- Zemunik T, Peruzovic M, Capkun V, Zekan L, Tomic S, Milkovic K. Reproductive ability of pubertal male and female rats. *Braz J Med Biol Res* 2003;36:871-7.
- Leite GA, Rosa Jde L, Sanabria M, Cavariani MM, Franci JA, Pinheiro PF, *et al.* Delayed reproductive development in pubertal male rats exposed to the hypolipemiant agent rosuvastatin since prepuberty. *Reprod Toxicol* 2014;44:93-103.
- Barros JW, Tonon KS, Borges CS, Silva PV, Lozano AF, Pacheco TL, *et al.* Short- and long-term effects on reproductive parameters of female Wistar rats after exposure to rosuvastatin starting in pre-puberty. *Curr Res Toxicol* 2020;1:149-60.
- Beytur A, Ciftci O, Oguz F, Oguzturk H, Yilmaz F. Montelukast attenuates side effects of cisplatin including testicular, spermatological, and hormonal damage in male rats. *Cancer Chemother Pharmacol* 2012;69:207-13.
- Hareedy MS, Ahmed EA, Ali MF. Montelukast modifies simvastatin-induced myopathy and hepatotoxicity. *Drug Dev Res* 2019;80:1000-9.
- Leite GA, Sanabria M, Cavariani MM, Anselmo-Franci JA, Pinheiro PF, Domeniconi RF, *et al.* Lower sperm quality and testicular and epididymal structural impairment in adult rats exposed to rosuvastatin during prepuberty. *J Appl Toxicol* 2018;38:914-29.
- Tilbrook AJ, Clarke IJ. Negative feedback regulation of the secretion and actions of gonadotropin-releasing hormone in males. *Biol Reprod* 2001;64:735-42.
- Kim JM, Ghosh SR, Weil AC, Zirkin BR. Caspase-3 and caspase-activated deoxyribonuclease are associated with testicular germ cell apoptosis resulting from reduced intratesticular testosterone. *Endocrinology* 2001;142:3809-16.
- Show MD, Anway MD, Folmer JS, Zirkin BR. Reduced intratesticular testosterone concentration alters the polymerization State of the sertoli cell intermediate filament cytoskeleton by degradation of vimentin. *Endocrinology* 2003;144:5530-6.