

Article

Identification of hydatid cysts and concomitant liver enzyme dysfunction in patients from Al-Najaf and Al-Diwaniyah City by conventional and phylogenetic methods

Huda Shakir Farhan^{1*}, Suha Haitham Mohammed^{1*}; Azza Sajid Jabbar^{2*}

¹Department of Clinical Laboratory Sciences, College of Pharmacy, University of Basrah, Basrah, Iraq

³Department of Pharmacology, College of Pharmacy, University of Basrah, Iraq

* Correspondence: huda.farhan@uobasrah.edu.iq, suha.mohammed@uobasrah.edu.iq, azza.jabbar@uobasrah.edu.iq

Available from: <http://dx.doi.org/10.21931/RB/CSS/2023.08.02.9>

ABSTRACT

Hydatid cyst infection is a serious disease that affects humans who come into touch with the infective stage of the tapeworm *Echinococcus granulosus*, which is found all over the world. The current study used patient physical and laboratory examinations, X-ray imaging, ultrasonic inspection, and polymerase chain reaction (PCR) to identify hydatid cyst presence in patients from the Iraqi cities of Al-Najaf and Al-Diwaniyah and to identify hydatid cysts and concomitant liver enzyme dysfunction in patients from the Iraqi cities of Al-Najaf and Al-Diwaniyah using conventional and phylogeny. Both strategies used partial gene sequencing (PGS) to target the *E. granulosus* antigen subunit B2 (EgB2) gene. The findings revealed an abdominal lump (6-7cm, left costal border), leukocytosis (12103/mm³), eosinophilia (84101/mm³), and an increased erythrocyte sedimentation rate (ESR) (35mm/hr), ultrasonic-detected splenic and liver cysts, and increased levels of alkaline phosphatase (ALP)= Mean standard error (MSE) (170.12.3 IU/l), Patients with such changes were then given surgical interventions to diagnose and remove cysts, which were identified as hydatid cysts (wheel-like, "rosette-like," or "honeycomb-like" cysts with cystic cavity-based "snowflakes" like protoscoleces, wavy or serpentine-like cystic membranes of punctured or solid-pseudotumor ball-like calcified degenerated cysts, respectively). The existence of hydatid cysts from the *E. granulosus* tapeworm was discovered by PCR. The PGS validated the results of the previous tests, yielding three nucleotide-sequence-based isolates that were identical to those from Brazil (bovine), Argentina (camelid), and Bengal (buffalo). The study found hydatid cyst infection in human patients in the Iraqi cities of Al-Najaf and Al-Diwaniyah, implying the presence of the adult form of the worm, *Echinococcus granulosus* tapeworms, in dogs in these areas.

Keywords: *Echinococcus granulosus*, EgB2 gene, hydatid cysts.

INTRODUCTION

Echinococcosis is a zoonotic infection caused by the larvae of the cestode genus *Echinococcus*. Previously, it was considered that only *E. granulosus* caused cystic echinococcosis (CE). However, it was shown that additional taxa had different mature morphological traits, host specialization, and pathogenicity.¹ Various *E. granulosus* strains have been discovered, each with a specific affinity for intermediate hosts (such as buffalo, sheep, horses, cattle, and camels). Phylogenetic investigations demonstrated that *E. granulosus sensu stricto* (G1 to G3), *E. equinus* (G4), *E. ortleppi* (G5), *E. canadensis* (G6 to G10), *E. multilocularis*, *E. oligarthrus*, *E. vogeli*, *E. felidis*, and *E. shiquicus* are all different species. The taxonomy is currently under discussion and still needs to be finished. For example, the *E. granulosus* genotypes G6, G7, G8, and G10 have not been characterized^{2,3}. Depending on the species, *Echinococcus* can cause a range of ailments in humans. *E. granulosus sensu stricto* is the most prevalent cause of CE, but *E. equinus*, *E. ortleppi*, and *E. canadensis* are also to blame. *E. multilocularis* cause alveolar echinococcosis, whereas polycystic echinococcosis is caused by *E. vogeli* and *E. oligarthrus*. Carnivores (such as dogs, cats, and hyenas) serve as the parasites' final hosts, whereas intermediate hosts (such as cattle, sheep, goats, and camels) contain metacestode, the larval stage.

⁴. The cestode's egg-producing mature stage is discovered in the final host's small intestine. Hundreds of worms may infect a single final host, each of which can produce thousands of eggs per day. The eggs become infectious once they are discharged into the feces of the final host. Depending on the environment, the eggs could remain infectious for months or even a year. Eggs can withstand cold temperatures despite their fragility due to desiccation and heat⁵. The oncospheres hatch from the eggs when the intermediate host eats them, passing past the intestinal mucosa and into the bloodstream, reaching the liver and other key internal organs. A fluid-filled cyst (metacestode or hydatid cyst) occurs when an organ becomes diseased.⁶ When eaten by a definitive host, protoscolices arise from the germinal layer and grow into sexually mature adults by evaginating and adhering to the intestinal mucosa throughout 4 to 7 weeks. If a final host consumes a protoscolex or the cystic fluid leaks into a cavity such as the peritoneal membrane, the protoscolex can mature into an adult parasite (secondary CE). Although metacestodes can arise in mammals, not all intermediate hosts can continue the cycle. Humans are considered accidental or aberrant hosts for disease transmission because they are rarely involved. Human-to-human contact does not occur.⁷ The current study identified hydatid cysts in patients from Al-Najaf and Al-Diwaniyah cities, Iraq.

MATERIALS AND METHODS

Samples and conventional diagnosis

During the years 2018-2021, ten patients with fever, loss of appetite, dull abdomen ache, persisting pain, and left-side-abdominal dragging sensation, as well as weight loss, visited hospitals and private clinics in Al-Najaf and Al-Diwaniyah, Iraq. Physical and laboratory examinations, X-ray imaging, and ultrasonic inspection were used to assess the patients. Each patient's cystic lesion samples were taken surgically, along with a blood sample (for the level determination of ALP, ALT, and AST). The parasitology laboratory received the samples in an icebox.

Molecular detection

Polymerase chain reaction and DNA sequencing

The DNA was extracted according to the manufacturer's instructions using the G-spin genomic DNA extraction kit (iNtRON Biotechnology, South Korea). The F: 5'GGATCCTTCGTGGCCGTCGTTCAAGC3 and R5'TCGACAAATCATGTGTCCCGACGCA3 primers were used to target a 400bp segment of the *E. granulosus* EgB2 gene (Jena Bioscience, Germany). Initial denaturation was performed at 95°C for 3 minutes, followed by 35 cycles of (95°C-1min denaturation, 55°C-1min annealing, and 72°C-1.5min extension) and 72°C-10min final extension in a PCR thermocycler. The gel was viewed and photographed using a UV-dependent device after electrophoresis (80Volts and 100 Amp for 45 minutes) using a 0.7 percent ethidium bromide-stained agarose gel. The phylogenetic analysis regarding the after-PGS-processing was performed depending on criteria by Tamura and Nei ⁸ and by using MEGA6 ⁹

RESULTS

The findings revealed an abdominal lump (6-7cm, left costal border), leukocytosis (12103/mm³), eosinophilia (84101/mm³), and an increased erythrocyte sedimentation rate (ESR) (35mm/hr), ultrasonic-detected splenic and liver cysts, and increased levels of alkaline phosphatase (ALP)= Mean standard error (MSE) (170.12.3 IU/l), Patients with such changes were then given surgical interventions to diagnose and remove cysts, which were identified as hydatid cysts (wheel-like, "rosette-like," or "honeycomb-like" cysts with cystic cavity-based "snowflakes" like protoscoleces, wavy or serpentine-like cystic membranes of punctured or solid-pseudotumor ball-like calcified degenerated cysts, respectively). Figure 1.

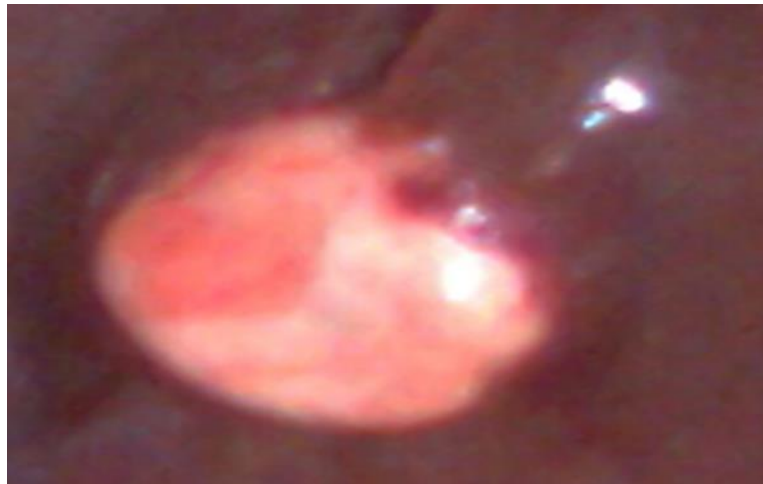


Figure 1. Liver-embedded hydatid cyst.

The PCR revealed the presence of hydatid cysts that belong to the *E. granulosus* tapeworm Figure 2.

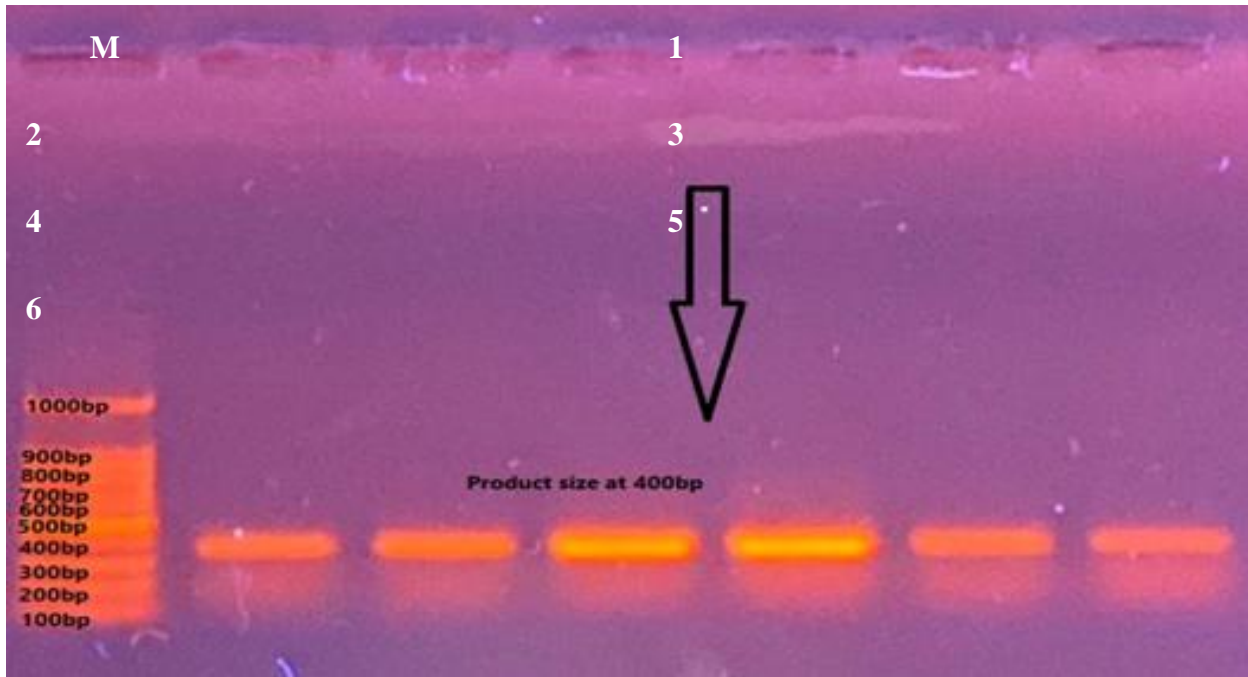


Figure 2. Image of electrophoresed 0.7%-agarose gel of a human patient's EgB2 gene PCR products of a hydatid cyst. M: DNA ladder (100-1000bp). Lanes 1 to 6: Positive amplified samples at 400bp.

The PGS confirmed the findings of the tests mentioned above, resulting in three isolates, which were nucleotide-sequence-based, similar to isolates from Brazil (bovine), Argentina (Camelid), and Bengal (buffalo) Figure 3.

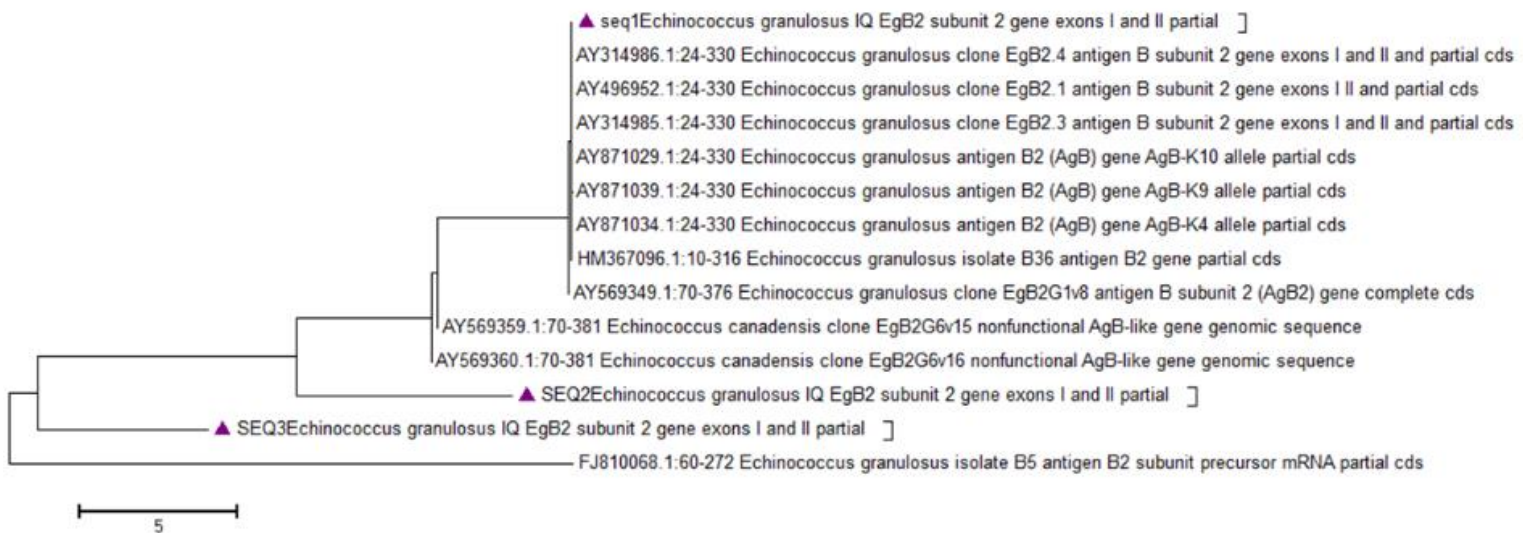


Figure 3. The phylogenetic tree of the partial sequencing of the EgB2 gene of hydatid cyst belongs to Echinococcus granulosus. The analysis was based on the Maximum Likelihood method, Neighbor-Joining, and Maximum Composite Likelihood (MCL) approach.

DISCUSSION

The current study's findings revealed that all of the patients had symptoms consistent with those reported in the literature, which state that CE usually has no symptoms unless there are complications. The main reasons for a cyst becoming clinically symptomatic include infection or allergy owing to cyst rupture, fistula creation with other bodily components (for example, the biliary system and gut), or mass influence on surrounding tissues¹⁰. A single cystic lesion affects 40 percent to 80 percent of people, and they are frequently discovered in a single organ. The liver is affected in 70% of cases, with the right lobe being more typically injured than the left. The lung is the second most common organ to be affected in around 20% of individuals. Cysts can form in the abdominal or pleural cavities, the spleen, kidney, bones, brain, ovaries, testes, pancreas, and eyes, among other organs and body parts.^{10,11}

The study outcomes revealed elevated serum ALP, ALT, and AST levels in the study patients. These results agree with those by¹², who found that four patients from Egypt with a history of abdominal pain and gastrointestinal problems plus contact with dogs and lived in rural areas had increased levels of eosinophils and leukocytes and increased serum levels of liver enzymes. They also discovered that three subjects had positive serological laboratory test results. Ultrasonography revealed well-defined cystic tumors in the liver, according to the investigators. Using computed tomography, they confirmed that the hydatid cysts were present. Finally, they reported that all the patients underwent surgery and chemotherapy and recovered completely.¹² ¹³ reported increased liver enzymes in a 49-year-old man from Portugal (with no rural area but only childhood-related dog contact) with persistent fatigue, elevated abdominal girth, and pain in the right upper quadrant, and the occurrence of multiple liver cysts, which was diagnosed as CE. Moreover,¹⁴ found that 88 CE patients from Bucharest were detected using the detection of the levels of liver enzymes and ultrasonography, revealing multiple cysts with elevations in the AST/ALT levels. The current study revealed that the EgB2 gene had been amplified, indicating that the study samples had been diagnosed as hydatid cysts. The findings came in agreement with those by¹⁴, who found using a PCR-restriction fragment length polymorphism (PCR-RFLP) targeting the internal transcribed spacer 1 (ITS1) gene and PGS of the cytochrome c oxidase subunit 1 (cox1) and NADH dehydrogenase subunit I (nad1) that 91.6% and 6.6% of patients had G1 strain and G6 strain of *E. granulosus*, respectively.¹⁵ found that PCR could identify the CE infection in samples from animals and humans from Iran. The phylogenetic analysis showed three isolates with nucleotide sequences that were similar to isolates from Brazil (bovine), Argentina (camelid), and Bengal (Bengal) (buffalo). The evolution of infectious agents can be traced in various methods, including animal movement across countries, such as through export/import procedures. The resemblance between the present isolates and those from the nations indicated above could be related to Iraq's borders being connected by soil-land, making it simple for dogs to cross them and spread the parasite to other animals. Furthermore, because the infection is sporadic, the evolution of a strain may be delayed enough to suggest that all of these isolates are related and descended from the same ancestor as a result of¹⁶.

CONCLUSION

The study found hydatid cyst infection in human patients from the Iraqi cities of Al-Najaf and Al-Diwaniyah. This logically implies the presence of the adult form, *Echinococcus granulosus* tapeworms, in dogs in these cities.

Conflict of interest: none

Funding: self-funding**References**

- 1 Bhutani N, Kajal P. Hepatic echinococcosis: A review. *Ann Med Surg [Internet]*. **2018** Dec 1 [cited **2022** Mar 9];36(12):99–105. Available from: /labs/pmc/articles/PMC6226561/
- 2 Lymbery AJ, Jenkins EJ, Schurer JM, Thompson RCA. Echinococcus canadensis, E. borealis, and E. intermedius. What is in a name? *Trends Parasitol [Internet]*. 2015 Jan 1 [cited **2022** Mar 9];31(1):23–9. Available from: <https://pubmed.ncbi.nlm.nih.gov/25440521/>
- 3 Nakao M, Lavikainen A, Yanagida T, Ito A. Phylogenetic systematics of the genus Echinococcus (Cestoda: Taeniidae). *Int J Parasitol [Internet]*. 2013 Nov [cited **2022** Mar 9];43(12–13):1017–29. Available from: <https://pubmed.ncbi.nlm.nih.gov/23872521/>
- 4 Andrew Thompson RC. The Molecular Epidemiology of Echinococcus Infections. *Pathogens [Internet]*. 2020 Jun 1 [cited **2022** Mar 9];9(6):1–9. Available from: /labs/pmc/articles/PMC7350326/
- 5 Otero-Abad B, Torgerson PR. A Systematic Review of the Epidemiology of Echinococcosis in Domestic and Wild Animals. *PLoS Negl Trop Dis [Internet]*. **2013** [cited **2022** Mar 9];7(6):e2249–62. Available from: /labs/pmc/articles/PMC3674998/
- 6 Gottstein B, Wang J, Blagosklonov O, Grenouillet F, Millon L, Vuitton DA, et al. Echinococcus metacestode: in search of viability markers. *Parasite [Internet]*. 2014 [cited **2022** Mar 9];21(11):63–72. Available from: /labs/pmc/articles/PMC4245873/
- 7 Golemanov B, Grigorov N, Mitova R, Genov J, Vuchev D, Tamarozzi F, et al. Efficacy and Safety of PAIR for Cystic Echinococcosis: Experience on a Large Series of Patients from Bulgaria. *Am J Trop Med Hyg [Internet]*. **2011** Jan [cited **2022** Mar 9];84(1):48–51. Available from: /labs/pmc/articles/PMC3005516/
- 8 Tamura K, Nei M. Estimation of the number of nucleotide substitutions in the control region of mitochondrial DNA in humans and chimpanzees. *Mol Biol Evol [Internet]*. **1993** [cited **2022** Mar 9];10(3):512–26. Available from: <https://pubmed.ncbi.nlm.nih.gov/8336541/>
- 9 Tamura K, Stecher G, Peterson D, Filipinski A, Kumar S. MEGA6: Molecular Evolutionary Genetics Analysis version 6.0. *Mol Biol Evol [Internet]*. 2013 Dec [cited **2022** Mar 9];30(12):2725–9. Available from: <https://pubmed.ncbi.nlm.nih.gov/24132122/>
- 10 Higuera NIA, Brunetti E, McCloskey C. Cystic Echinococcosis. *J Clin Microbiol [Internet]*. 2016 Mar 1 [cited **2022** Mar 9];54(3):518–23. Available from: /labs/pmc/articles/PMC4767951/
- 11 Rinaldi F, Brunetti E, Neumayr A, Maestri M, Goblirsch S, Tamarozzi F. Cystic echinococcosis of the liver: A primer for hepatologists. *World J Hepatol [Internet]*. **2014** [cited **2022** Mar 9];6(5):293–305. Available from: /labs/pmc/articles/PMC4033287/
- 12 Elshazly AM, Azab MS, ElBeshbishi SN, Elsheikha HM. Hepatic hydatid disease: four case reports. *Cases J [Internet]*. **2009** [cited **2022** Mar 9];2(1):58–61. Available from: /labs/pmc/articles/PMC2631541/
- 13 Leitão P, Carvalho A, Fernandes T, Gonçalves J. Cystic Echinococcosis: A Case of Extrahepatic Intra-Abdominal Involvement. *Case Rep Radiol [Internet]*. **2017** [cited **2022** Mar 9];2017(1):1–4. Available from: /labs/pmc/articles/PMC5282424/
- 14 Botezatu C, Mastalier B, Patrascu T. Hepatic hydatid cyst – diagnose and treatment algorithm. *J Med Life [Internet]*. **2018** Jul 1 [cited **2022** Mar 9];11(3):203–9. Available from: /labs/pmc/articles/PMC6197524/
- 15 Gholami S, Sosari M, Fakhari M, Sharif M, Daryani A, Hashemi MB, et al. Molecular Characterization of Echinococcus granulosus from Hydatid Cysts Isolated from Human and Animals in Golestan Province, North of Iran. *Iran J Parasitol [Internet]*. **2012** [cited **2022** Mar 9];7(4):8–16. Available from: /labs/pmc/articles/PMC3537467/
- 16 Fooks AR, Johnson N. Jet-set pets: examining the zoonosis risk in animal import and travel across the European Union. *Vet Med Res Reports [Internet]*. **2015** Dec [cited **2022** Mar 9];6(12):17–25. Available from: /labs/pmc/articles/PMC6067792/

Received: May 15, 2023/ Accepted: June 10, 2023 / Published: June 15, 2023

Citation: Farhan, H.S.; Mohammed, S.H.; Jabbar, A.S. Identification of hydatid cysts and concomitant liver enzyme dysfunction in patients from Al-Najaf and Al-Diwaniyah City by conventional and phylogenetic methods. *Revista Bionatura* 2023;8 (2) 90. <http://dx.doi.org/10.21931/RB/CSS/2023.08.02.9>