

Non-Surgical Treatment of Multilocular Central Giant Cell Granulomas (CGCG) in the Mandible. Presentation of Three Cases Treated In Basrah, Iraq

Sundus Abdul Wadood Aljazaeri¹, Zainab Abdulkareem Maktoof^{2*}, Mustafa S. Al-Mutar³

¹ M.Sc. In O&MFS, Basrah Dental College. University of Basrah/Iraq

²M.Sc. In Pathology, Basrah dental College, University of Basrah/Iraq

Zainab.maktoof@uobasrah.edu.iq

³ FIBMS; Radiodiagnosis, Senior Consultant Radiologist/ Al-Sadder Teaching Hospital, Basrah, Iraq

*Correspondence author: Zainab Abdulkareem Maktoof (Zainab.maktoof@uobasrah.edu.iq)

Received: 10 May 2023 **Accepted:** 12 June 2023

Citation: Aljazaeri SAW, Maktoof ZA, Al-Mutar MS (2023) Non-Surgical Treatment of Multilocular Central Giant Cell Granulomas (CGCG) in the Mandible. Presentation of Three Cases Treated in Basrah, Iraq. History of Medicine 9(2): 95–99. <https://doi.org/10.17720/2409-5834.v9.2.2023.015>

Abstract

Objective: This study's goal is to show how the medical management of three patients' Central Giant Cell Granulomas (CGCG) in the mandible performed better than surgical surgery. **Background:** The upper and lower jaws are occasionally affected by the central giant cell granuloma (CGCG), a benign non-cancerous tumour that destroys bone. Locally severe CGCG can cause facial asymmetries in people of all ages as well as bone distraction and root resorption. Conventional surgery is used to treat CGCG, albeit there is a higher recurrence rate after surgery than after medication therapy. The clinical behaviour divergence of the CGCG has resulted in a significant lack of consent for using the various treatment alternatives. Surgery to treat a large CGCG causes the patient to experience aesthetic issues. The worst complications following surgery are tooth or tooth germ loss and bone resection, both of which may necessitate extensive post-operative reconstructive surgery and rehabilitation. Corticosteroid non-surgical therapy has been shown to produce worthwhile outcomes that may be helpful. **Case presentation:** Three patients have been diagnosed with CGCG: two ladies, age 22 and 32, and a little boy, age 13. The remaining patients received intralesional triamcinolone injection therapy, whereas the female patient received intralesional hydrocortisone injection therapy. The lesions seemed to have shrunk in size seven to eight years after therapy, and the panoramic radiograph showed increased opacification without recurrence. **Conclusion:** In comparison to surgical treatment, non-surgical corticosteroid therapy for big CGCG produced good results.

Keyword

Central giant cell granuloma, mandible, steroid, non-surgical

The uncommon benign central giant cell granuloma (CGCG), which makes up 7% of jaw tumours, is an aggressive intraosseous disease(1). From asymptomatic radiolucency seen on a routine radiograph to abruptly worsening aggressive lesions, CGCG in the craniofacial region can take many different forms. Clinical-radiological diagnosis distinguishes between central giant cell granuloma (CGCG), which develops within the bone, and peripheral giant cell granuloma (PGCG), which affects the gingiva or edentulous alveolar process(2). These lesions were known as "Giant Cell Reparative

Granulomas" by Jaffe in 1953. However, the word "Reparative" was ultimately dropped because not all lesions were reportedly self-healing(3).

CGCGs are commonly introduced as unifocal lesions, but careful evaluation for multifocal lesions must also be performed because there is a chance of hyperparathyroidism, cherubism, or Noonan syndrome. Cherubism and Noonan syndrome were difficult to distinguish from giant cell lesions. While all tumours displayed abundant osteoclast fields, histologically(4).

The peak incidence of CGCG in men is between

the ages of 10 and 14; in females, it is between the ages of 15 and 19. It has been noted that CGCG is more prevalent in females and particularly affects the anterior mandibular region(5). Uncertainty surrounds CGCG's genesis. Localized injury, inflammation, intraosseous haemorrhage, and genetic anomalies have all been considered potential causes, but no single theory has been widely accepted(6). Clinically, CGCG can behave in a variety of ways, from a slowly growing, asymptomatic swelling to an aggressive lesion that causes pain, cortical perforation, and root resorption(7). Depending on the clinical behaviour and radiographic characteristics of the lesion, it is determined if it is aggressive or not. Clinical characteristics include the growth rate, bone lysis, resorption of the dental roots, presence of pain, and perforation of the bone cortex(8).

A well-circumscribed radiolucent lesion that is not connected to the teeth and does not lead to cortical bone expansion is known as a non-aggressive lesion. While also causing enamel displacement and cortical growth, the aggressive variant resembles a big lytic unilocular or multilocular lesion(9).

Histologically, CGCG produces many mononuclear stromal cells and multinucleated giant cells in the stroma of fibrous connective tissue. Its aetiology and pathogenesis are unknown, and it was formerly known as a large cell reparative granuloma. Nonetheless, this word is no longer utilized because it can be disruptive and confrontational(2).

Depending on the clinical indications and symptoms, treatment options range from straightforward curettage to surgical en-bloc excision; nonetheless, there is a (70%) recurrence risk after surgical therapy. Moreover, medical procedures are suggested to lessen the need for surgery, especially in children, however, there is no proof that this is preferable to surgery(10).

Alternative therapy options, such as intralesional corticosteroid injections, subcutaneous calcitonin administration, and interferon-alpha injections, are mentioned in several case reports with varying degrees of efficacy. Regrettably, randomized clinical trials were either little conducted or nonexistent. Many theoretically promising treatment alternatives, such as imatinib and OPG/AMG 162, will be used in such patients in the coming years(11).

The assumption that CGCG is of inflammatory origin leads to the possibility of administering corticosteroids directly into the lesion as a form of medical treatment. The enormous cells resemble osteoclasts in their traits. There is a belief that CGCG is a proliferative vascular lesion, which instructs researchers to employ antiangiogenic therapy and results in a response in the lesion, however, there is less information from long-term trials(12).

General management for all cases

The University of Basrah's Basrah Dental College's oral and maxillofacial surgery division received referrals for three patients. All patients received care following the ethical standards set by the dental college's ethical committee. With the patient's consent, cortisone was injected intralesionally to treat the condition. By signing the patient consent form, all patients consented to the use of their images, radiographs, medical information, and treatment outcomes for research. All patients underwent a full haematological examination, testing for parathyroid and thyroid gland function, FNS performed before incisional biopsy to the patients by the reflection of a mucoperiosteal flap, and radiographic investigation, including orthopantomography (OPG) and computed tomography scan (CT) scan.

Histopathological examination

When viewed under a microscope, CGCG resembles cellular fibrous tissue with numerous hemorrhagic foci, clumps of large multinucleated cells, and sporadic trabeculae of woven bone.

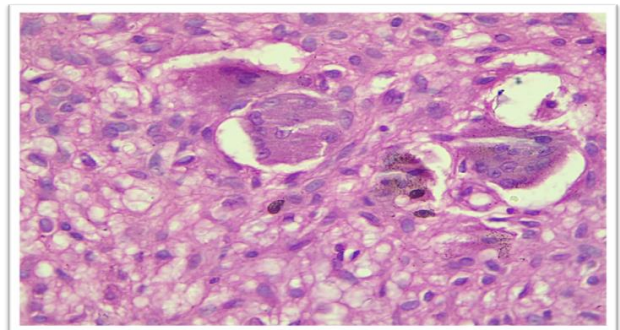


Figure 1: Histopathological examination of CGCG: Giant cells, foci of haemorrhage, and trabeculae of woven bone (10X magnification, stain by Hematoxylin and eosin)

Treatment protocols

Treatment involved administering intralesional injections of cortisone diluted with distilled water and combined with local dental anaesthesia (lidocaine, 1.8 ml with adrenaline) every week until resistance developed (the inability to inject the solution inside the tumour).

CASE No. 1

A woman in her 30s was diagnosed with a massive, painless mandibular swelling in June 2014 that extended from the ramus of the right side of the jaw to the lower anterior. Upon intraoral examination, the buccal and lingual plates on the right side expanded from the canine to the molar region.

Radiographically

A multilocular, eccentric, expansible bony mass lesion measuring (3.8*1.9*3) cm in the right mandible between the third molar and lower lateral incisor, together with cortical bone degradation, was seen during the patients' radiographic evaluation by CTS and OPG. in Figure 2.

Treatment

A six-month course of treatment involved weekly intralesional injections of 1.8 ml of lidocaine with adrenaline and 100 milligrams of hydrocortisone sodium succinate diluted in 5 ml distal water. A well-defined scope of radiolucency buccally was present in the patient's calcification in the area evident in CTS after a year and six months. The patient had the same injection for the next two months after an FNA was conducted to determine the type of radiolucency (figure 3). The amount of buccal oedema was smaller in 1/2017. (figure 4). The patient's OPG in 3/2022, eight years later, displays a healthy bone free of recurrence (figure 4).

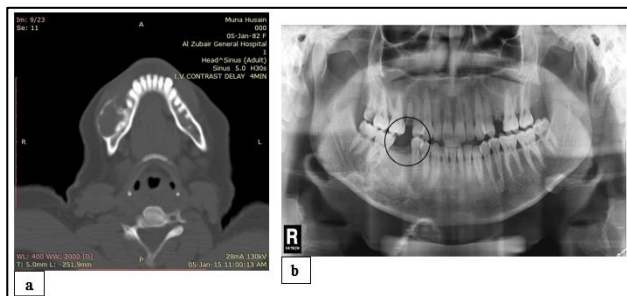


Figure 2: pretreatment radiographical examination: (a) CTS (b) OPG radiography shows multilocular radiolucency (3.8*1.9*3)cm at the right mandible between lower lateral incisor to the third molar right side with cortical bony erosion (taken in 2014).

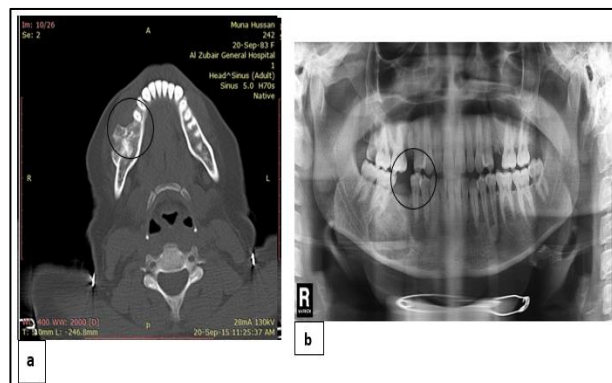


Figure 3: Post-treatment radiographical examination after one year and six months in 2015: radiograph shows there was calcification in the area seen clearly in (a) CTS, (b) OPG with a well-defined scope of radiolucency extending from the distal area of the right second premolar to mesial area of the right second molar.

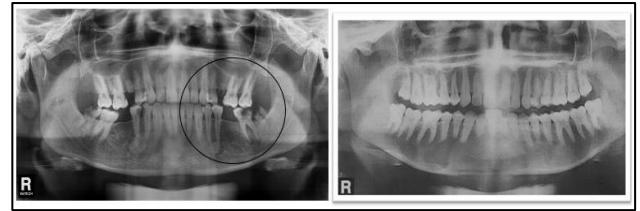


Figure 4: OPG radiograph shows calcification in the right side of the mandible eight years post-treatment, with normal mandibular contour and no reoccurrence (taken in 2022).

CASE No. 2

An anterior mandibular enlargement and skin redness were seen in a patient who was 20 years old in 2016. Intraoral, The mass extends to the region of the premolars and molars on the same side of the right mandible, expanding the cortex buccally and lingually. While the teeth are mobile and the swelling is soft in palpation on the labial and lingual sides.

Radiographically

A CT scan revealed a severe osteolytic mixed aggressive bone lesion with a broken glass matrix that measured around (5*4*3) cm in size and extended from the first premolar left side of the mandible to the first molar right side. Due to the mass of the bone, the premolar and molar roots resorbed as well as the anterior and posterior cortex was destroyed (figure 5).

Treatment

Treatment for the patient involved weekly intralesional injections of 20 mg of triamcinolone acetate (Kenalog), diluted in 5ml of distal water, combined with lidocaine and 1.8ml of adrenaline. Nine months after treatment in 2017 an OPG showed a well-defined radiolucency at the apical region of the lower canine and premolar teeth (Figure 6), but a viability test came back negative, therefore the lesion was treated with a root canal filling.

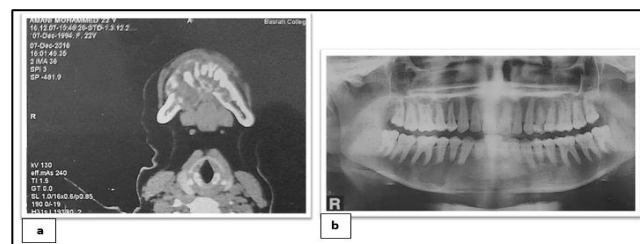


Figure 5: (a) CT scan shows a mass, which extended from the first premolar left side of the mandible to the first molar right side, about (5*4*3) cm in size, destructive osteolytic mixed aggressive bone lesion with crushed glass matrix and destroyed the anterior and posterior cortex, (b) OPG Premolar and molar roots resorbed due to the bone's mass, which also pretreatment 2016.

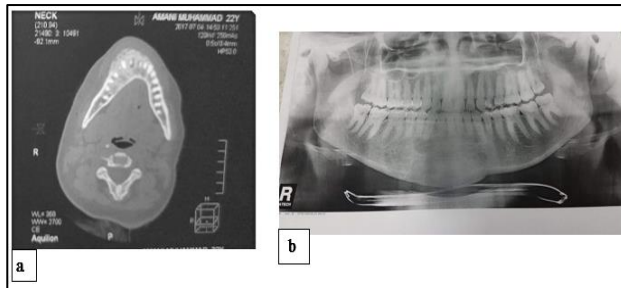


Figure 6: Both an (a)CT scan and a (b) OPG taken nine months after treatment revealed calcification of the lesion, although the OPG indicated a radiolucency at the apical region of the lower canine and premolar teeth.

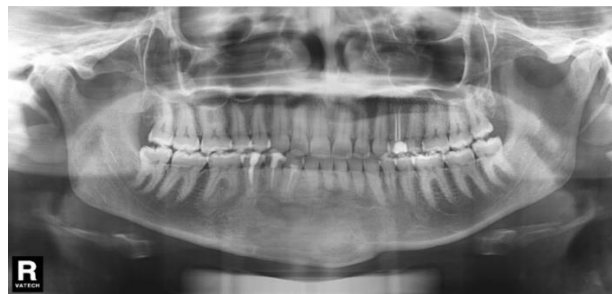

Figure 7: A 2022 OPG radiograph reveals calcification, there was a good response of the periapical lesion after endodontic treatment of the lower right canine and premolars, and there was an enlargement in the lower border right side.

CASE No.3

In 2015, a 12-year-old male patient appeared with a firm swelling at the left side of the mandible's body with normal skin surrounding it. The teeth were sound and immobile throughout the intraoral examination, with enlargement of the buccal and lingual cortex.

Radiographically

A well-defined expansile trabeculate bone lytic lesion measuring approximately 3.2x3x2.6 cm with intact surrounding tooth roots was seen on a CT scan of the radiographic field. With the divergence of the premolar and molar roots, OPG demonstrates the multilocular lesion. (8 Figures).

Treatment

The patient had a once-weekly injection of 20 mg of triamcinolone acetonide (Kenalog), diluted in 5 ml of distal water and 1.8 ml of lidocaine with adrenaline for four months. Because the buccal cortex had calcified, the final four injections were intraosseous. The patient's family discontinued the therapy in 2022 and resumed it in 2023. The enlargement of the buccal and lingual cortex is lessened after eight years,

according to CBCT calcification. In OPG, the roots divergence changed as well, in contrast to radiography in 2016. Calcification was discovered after six months (figure 12). The patient and his parent are pleased with the outcome and will stay in touch

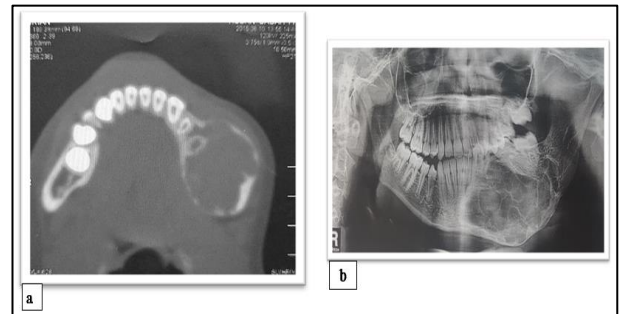


Figure 8: Radiographical examination: (a) CT Scan show a well-defined expansile trabeculate bony lytic lesion with thinning of the adjacent cortex, no calcification, about (3.2x3x2.6) cm with intact adjacent teeth roots, (b) OPG show the multilocular lesion very clearly with the divergence of the premolar and molar roots.

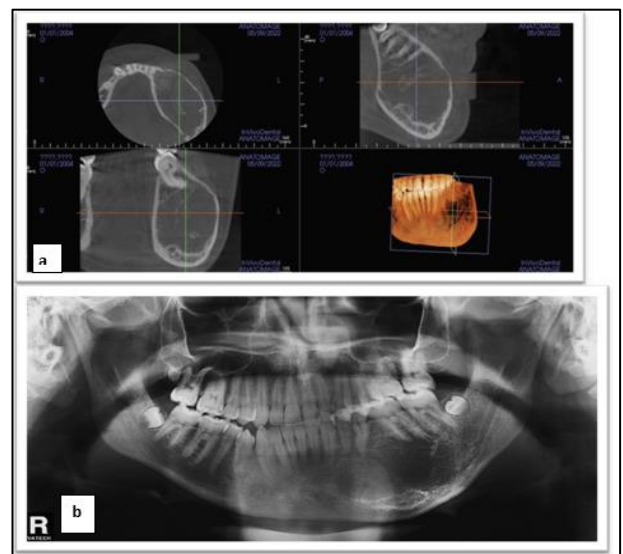


Figure 9: In 2022, after eight years, a) CBCT of the patient shows calcification with reducing in the size of buccal and lingual cortex swelling. b) OPG change in the roots divergence, unlike radiography in 2016.

Discussion

Among the jaw lesions, central giant cell granuloma (CGCG) accounts for 7%. Treatment options range from curettage to bone excision; however, medication treatment has been successfully used as corticosteroids. It is typically asymptomatic but can be aggressive(13).

A 1951 publication that discussed the advantages of intra-articular corticosteroid injection was followed by the introduction of prednisolone

treatment by intralesional injection by Rothermich and Phillips in 1956, with promising results. Later, in 1958, triamcinolone hexacetonide was once stated for intra-articular injection, and in the 1970s, bone cysts were dealt with in terms of the administration of corticosteroids. Moreover, Jacoway et al. suggested using intralesional corticosteroids for the treatment of CGCG in 1988, and it was shown that weekly injections of corticosteroids (a combination of triamcinolone acetonide and lignocaine) for six weeks showed encouraging effects(14).

Flanagan et al. explain the process by which corticosteroids reduce the extent of intraosseous lesions. They hypothesized that dexamethasone reduces the activity of cells that resemble osteoclasts in a culture of bone marrow cells(15).

Other hypotheses regarding the action of corticosteroids on CGCG were confirmed in vitro by Kremer et al., who administered 17-estradiol to avian osteoclast cells and giant cell tumours that resembled human osteoclasts. The result was a decrease in bone resorption. Additionally, a record was brought by Hiramaya et al. that included the action of dexamethasone on mature osteoclasts that demonstrated decreased bone(16).

The use of intralesional corticosteroid injection was very helpful in avoiding the necessity for surgery that might harm the jaws' appearance and functionality. Moreover, conservative therapy maintains the health of the surrounding tissues and the integrity of the teeth(17).

In this article, we present the treatment of three cases of patients with CGCG of the lower jaw. The therapy was conservative and involved intralesional injections of hydrocortisone in one case weekly for eight months and triamcinolone in two different cases for six months. This clinical treatment eliminates the need for surgical intervention by significantly shrinking the lesion.

Patients received varying levels of service depending on their financial situation. The first patient requested to be treated with hydrocortisone since it is less expensive than triamcinolone, whilst the others were treated with triamcinolone, which researchers bought for them. Despite the sizeable tumours in the other two patients, the treatment time was shorter than it was for the first patient.

References

Imanimoghaddam M, Mortazavi S, Goudarzi F. A Literature Review of the Rare Coexistence of Central Giant Cell Granuloma with Aneurysmal Bone Cyst: A Case Report. 2021;33(118):319–25.
Gupta S, Narwal A, Kamboj M, Devi A, Hooda A. Giant Cell Granulomas of Jaws: a Clinicopathologic Study. J Oral Maxillofac Res. 2019;10(2):1–10.

Cell YS et al. Recurrent case of central giant granuloma with multiple soft tissue involvement. Nati J Maxillofac Surg. 2014;5(1):60–66.,.
Idowu, B.D., Thomas, G., Frow, R., Diss, T. C. & Flanagan AM. Mutations in SH3BP2, the cherubism gene, were not detected in central or peripheral giant cell tumours of the jaw. Br J Oral Maxillofac Surg. 2008;46(3):229–30.
BAYRAK NB, İŞİK BK, ERİNANÇ ÖH, Dolanmaz D. Treatment of Mandibular Central Giant Cell Granuloma With Administration of Systemic Calcitonin: a Case Report. Selcuk Dent J. 2018;73–9.
Al. PP et. Increased TNF- α , IL-6 and decreased IL-1 β immunohistochemical expression by the stromal spindle-shaped cells in the central giant cell granuloma of the jaws. Med Oral Patol Oral Cir Bucal 2012; 2017;17(1):e56-62.
Anand S, Kv A. An Aggressive Central Giant Cell Granuloma of Mandible in an Older Patient Managed Successfully With Marginal Mandibulectomy and Reconstruction With Submental Island Flap. 2021;13(December 2019):6–13.
Tatiane Fonseca F, Gabriela Madeira A, José Rodrigues Laureano F, Ricardo José de Holanda V, Emanuel Dias de Oliveira e S. Marginal Resection of Mandible for Treatment of Central Giant Cell Granuloma. Int J Oral Dent Heal. 2018;4(2):1–4.
Abu-El-Naaj I, Ardekian L, Liberman R, Peled M. Central giant cell granuloma of the mandibular condyle: A rare presentation. J Oral Maxillofac Surg. 2002;60(8):939–41.
Cavalcante RC, Cotait de Lucas Corso PF, Pinto Lisboa Dias TR, Schramm E, Couto de Souza PH, Barbosa Rebellato NL, et al. Central giant cell granuloma (CGCG) in childhood: surgical treatment by maintaining the tooth germs. Rsbo. 2017;1(1):37.
de Lange J, van den Akker HP, van den Berg H. Central giant cell granuloma of the jaw: a review of the literature with emphasis on therapy options. Oral Surgery, Oral Med Oral Pathol Oral Radiol Endodontology. 2007 Nov 1;104(5):603–15.
Elhag HAO, Babikir MH, Tarakji B. Advantages and disadvantages of surgical and non-surgical treatment of central giant-cell granuloma: A Review of literature. Int J Contemp Dent Med Rev. 2017;1–5.
José de Santana Sarmiento D, Almeida dos Santos J, Helena Marques de Almeida Lima L, Guedes de Lima M, Pina Godoy G. Surgical treatment of central giant cells lesions in the maxilla: Case report. oldfiles.bjorl.org [Internet]. 2011 [cited 2022 Feb 26];77(1). Available from: http://oldfiles.bjorl.org/conteudo/acervo/acervo_english.asp?id=4114
Metgudmath R, Metgudmath A, ... SP-J of the, 2013 undefined. Dilemma in the management of central giant cell granuloma of maxilla. jscisociety.com [Internet]. [cited 2022 Feb 26]; Available from: <https://www.jscisociety.com/article.asp?issn=0974-5009;year=2013;volume=40;issue=1;spage=41;epage=43;aulast=Metgudmath>
Sezer B, Koyuncu B, Gomel M, Günbay T. Intralesional corticosteroid injection for central giant cell granuloma: A case report and review of the literature. Turk J Pediatr. 2005;47(1):75–81.
BAŞAK N, ÖZGÜR SOY URAN B. Nadir Görülen Bir Hastalık: Granüloatozisli Polianjitis Olgusu. Düzce Üniversitesi Sağlık Bilim Enstitüsü Derg [Internet]. 2020 [cited 2022 Feb 26];11(2):257–60. Available from: <https://dergipark.org.tr/en/pub/duzcesbed/issue/61175/825109>
GÜLCAN H, GÜLŞEN U, GÜLŞEN EA. The Use of Corticosteroid in the Treatment of Central Giant Cell Granuloma. Düzce Üniversitesi Sağlık Bilim Enstitüsü Derg. 2021;(May).