



## The Effect of Warfarin on Gene Expression of Biomarker Osteopontin in Fetuses of Rats

Rana K. Abdulsamad<sup>1\*</sup>, Alaa A. Sawad<sup>2</sup> and Faris S. Kata<sup>1</sup>

<sup>1</sup>Department of Biology, College of Education for Pure Sciences, University of Basrah, Iraq.

<sup>2</sup>Department of Anatomy, College of Veterinary Medicine, University of Basrah, Iraq.



CrossMark

**T**HE present study gives an overview of the effect of the administration of warfarin on pregnant rats were exposed orally to warfarin (0.05 mg/kg b. wt. or 0.1mg/kg b. wt.), daily on days zero to 15 of gestation. The pregnant animals were sacrificed on day (20) day of gestation under general anesthesia by a mixture of Xylazine and Ketamine, Collection of blood samples from heart of pregnant rats for biochemical study by using Kit of ELISA technique to estimate the concentration of Osteopontin. Fetuses specimens which were embedded by paraffin were sectioned at 4  $\mu$ m thickness for histopathological and Immunohistochemical techniques were used to compare the relationship of Osteopontin expression to proliferation of intestine and skin in fetuses.

The result appears Positive expression of SPP1 protein in epidermis layer in fetus skin. and epithelial cells of villi of fetus intestine control group, while the treated rats with low doses of warfarin induced intermediate Expression of SPP1 protein in epidermis layer in fetus skin and epithelial cells of villi of fetus intestine, also the treated rats with high doses of warfarin performs weak expression of SPP1 protein in epithelial cells of villi of fetus intestine. It is concluded that Warfarin has negative effect on osteopontin secretion in blood and tissues.

**Keywords:** Osteopontin, Warfarin, Immunohistochemistry.

### Introduction:

The pregnancy period is a critical period during which the organogenesis of fetuses occurs, consequently when the mother is exposed to external impacts such as the wrong use of medicines, it may lead to congenital malformations in fetuses, especially during the first two weeks of pregnancy [1]. Anti-coagulants drugs during pregnancy are required for the treatment of acute thromboembolism. The prescription of anticoagulants during pregnancy must be carefully considered because of the adverse effects in both mother and child. The previous studies showed that the warfarin cross the placenta which causes

anticoagulation of the fetus, leads to bleeding in fetal organs. It can occur hypothetically virtually in any part on the body, and potentially results in fetal death [2]. Warfarin is an oral anticoagulant vitamin K antagonist (VKA) its first type which was established in 1930 by Karl Paul Link, who discovered dicumarol [3]. VKA drugs are 4-hydroxycoumarin derivatives, which exert their anticoagulant effect by inhibiting vitamin K epoxide reductase and, possibly, vitamin KH2 reductase compounds which act by reducing vitamin KH2 levels, thereby the limiting cofactor effect of vitamin K on the  $\gamma$ -carboxylation of the vitamin K-dependent coagulation factors II, VII, IX, and X. VKAs and

the limit effect of anticoagulant proteins, protein C and S, as protein an inhibition depending on the synthesis of vitamin K [4]. Warfarin may cause skin necrosis which it is a serious condition in which subcutaneous tissue necrosis occurs due to an acquired protein C deficiency following the treatment with warfarin [5]. The Osteopontin (OSP) is an acidic, secreted protein recently classified as a member of the SIBLING (Small Integrin-Binding, N-Linked Glycoprotein) family, OPN from mice and humans are encoded by the gene of *Spp1* OPN that initially found prominently in bone, kidney tissue, and the body fluids [6]. Immunohistochemical studies shown its expression in human luminal surfaces of the epithelial cells of several tissue [7].

We believe that further knowledge the effect of warfarin on pregnant rats during the period of gestation on fetuses' development and the effect in level of OPN in serum of pregnant rats and provide a new insight into the role of Osteopontin in the development of fetuses of pregnant mothers treated with Warfarin through measuring OPN expression on fetuses' tissues.

#### **Material and Methods**

A healthy Twenty-four adult virgin female Wistar albino rats (*Rattus norvegicus*) weighing an average of (275±25 g) were used and were bred in the college of Veterinary Medicine University of Basrah in animal house. The adult virgin female rats were assigned randomly into three cages. The animals were left to adapt for one week and then mating with males by (two females for each male) to determine the zero-gestation day by seeing the vaginal plug [8,9]. At zero- day of gestation the pregnant rats were divided into three main groups: The control group (8 pregnant rats) were given a dose of 1ml of drinking water. The second group (8 pregnant rats) were treated with 1ml of low dose of warfarin (0.05 mg/kg b.wt.). The third group was treated with 1ml of high dose of warfarin (0.1mg/kg b.wt.) daily from days (zero- fifteen day) of gestation. The second and third groups (8 pregnant rats) were treated with warfarin daily from day zero to day 15 of gestation (organogenesis period). The chosen doses of warfarin were according to the half-lethal dose of warfarin (58 mg /kg) in the published research. Two different doses of Warfarin (low and high dose) were used [10].

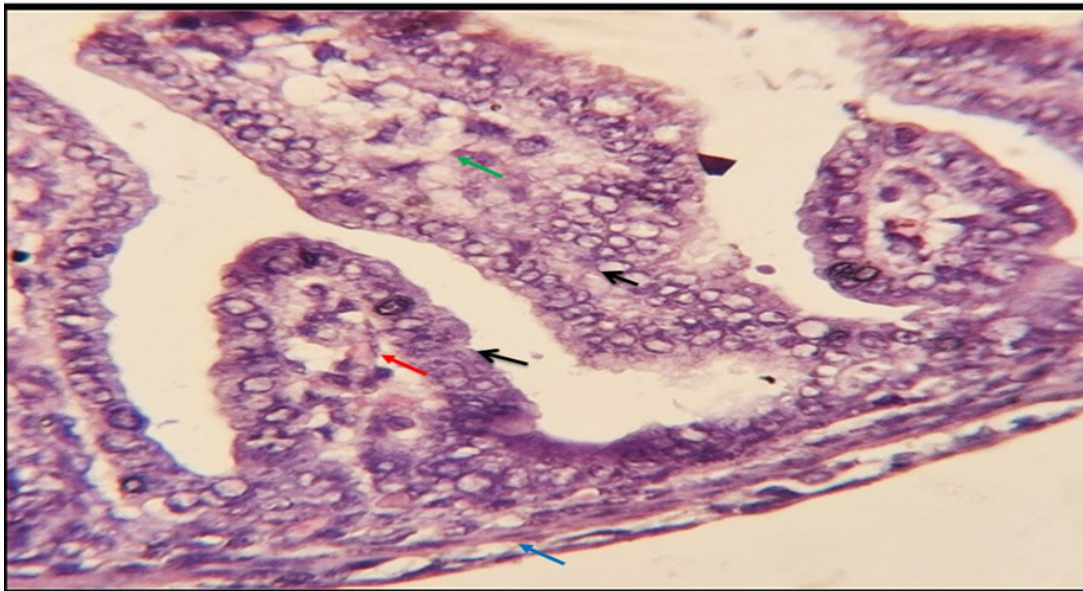
The pregnant animals were sacrificed on day (20) of gestation under general anesthesia by a

mixture of Xylazine (90 mg/kg) and Ketamine (10 mg/kg) [11,12], Collection of blood samples from heart of pregnant rats were placed in a covered gel tube then, the gel tubes were centrifuged at 3,000 r.p.m for 10 minutes [13]. The serum was then immediately transferred into Eppendorf tube until it was used for a biochemical study by using Kit of ELISA technique to estimate the concentration of Osteopontin (Depending on the manufacturer instructions, USA Al-shkairate establishment).

Fetuses' specimens marked Immunohistochemical Labeling of *Spp1* was used as a positive control for Osteopontin expression based on immunohistochemistry kit (Envision FLEX, Dako, K8000, Denmark) to compare between the fetuses treated with low doses of warfarin and the fetuses treated with warfarin at higher doses. Sections were embedded in paraffin and sectioned at a thickness of 4 µm for histopathological changes preserved in paraformaldehyde 4%, with subsequent embedding in paraffin. sections (4 µm thickness) were cut and mounted on glass slides and cleared of paraffin with xylene, followed by hydration in graded concentrations of ethanol (from 100% to 50%). Each slide-mounted tissue section was incubated overnight at room temperature with primary antibody against smooth muscle (Anti-SPP1 Primary Antibody (Polyclonal antibody rabbit Anti-SPP1 Antibody: E-AB-70356, Elabscience, China was used for detection the expression of SPP1 in current study. Antibody diluent was used to dilute the anti-SPP1 primary antibody 100 times (EnVision FLEX Antibody Diluent, Dako, K8006, Denmark). Whereas this phase, the ED-1 primary antibodies were incubated at incubator. Rat fetal samples imbedded in paraffin were sectioned at a thickness of 4 µm, carefully positioned in a water bath, and mounted on positively charged glass slides using a hot plate (CrystalCruz® Electro-Statically Charged Micro Slides, sc-363562, SANTA CRUZ BIOTECHNOLOGY, USA) (K&K HYSH), Korea). The tissue pieces were washed in distilled water before spending five minutes in a Tris-buffered saline (TBS) bath. The tissue samples were put in a glass jar with EnVision™ FLEX Target Retrieval Solution, High pH, DM828, which was preheated to 60 °C and then incubated at 97 °C for 25 minutes. The tissue samples were placed in a glass jar and allowed to cool for 20 minutes at room temperature before being rinsed with distilled water and submerged in a TBS buffer bath for 5 minutes. The excess buffer on the tissue

section was tapped off, and the sections were then carefully cleaned with tissue paper. To guarantee that the reagent was contained only on the tissue section of the glass slide, the tissue sections were circled with wax using a specialized wax pen (Gene Tech Pen, Elabscience, E-BC-R531, China). The tissue pieces were cleaned and submerged for five minutes in two different TBS buffer baths (EnVision FLEX Wash Buffer, SM831). A tissue paper was used to carefully wipe away the excess buffer from the tissue section, before being rinsed, the portions were submerged for five minutes each in two separate TBS buffer baths (EnVision FLEX Wash Buffer, SM831). By gently tapping the slides and wiping a tissue paper around the sections, the extra buffer on the tissue sections was eliminated. The sections were coated with 100 L of diluted anti-SPP1 primary antibody and incubated for one hour at ambient temperature in a humidity chamber. The sections were then rinsed and submerged for five minutes each in two different TBS buffer baths (EnVision FLEX Wash Buffer, SM831). The excess buffer on the tissue sections was tapped off, and the sections were then gently wiped with tissue paper. The tissue sections were then applied with 100  $\mu$ L of secondary antibody labeled to horseradish peroxidase (EnVision FLEX /HRP, SM802) and incubated in a humidity chamber at room temperature for 30 minutes, before the sections

were rinsed and immersed in two change of TBS buffer bath (EnVision FLEX Wash Buffer, SM831) for 5 minutes each. The excessive buffer on the sections were removed by tapping and wiped gently with a tissue paper around the sections. The tissue sections were incubated in a humidity chamber for 10 minutes after being treated with 100 L of newly made DAB+ substrate-chromogen solution (created by adding one drop of EnVision FLEX DAB+ Chromogen (SM827) to one ml of EnVision FLEX Substrate Buffer (SM803)). The sections were then cleaned and submerged for 5 minutes in each of two TBS buffer baths (EnVision FLEX Wash Buffer, SM831). After counterstaining the tissue sections for three minutes with Mayer hematoxylin (Mayer hematoxylin, Bio-Optica, 05-06002/L, Italy), they were rinsed in tap water. After counterstaining the tissue sections for three minutes with Mayer hematoxylin (Mayer hematoxylin, Bio-Optica, 05-06002/L, Italy), they were rinsed in tap water. The tissue samples underwent three dehydration cycles of 70%, 90%, and 100% ethanol alcohol for two minutes each. The tissue pieces were mounted with mounting media (DPX), then wrapped in cover slips after being submerged in two changes of xylene for ten minutes each. A light microscope was used to analyze the tissue sections at 100x and 400x magnifications.



**Fig. 1.** Intestine of fetus 16 days age of control group shows normal mono-layer of epithelial lining cells which appear as columnar cells (black arrow), normal components of the lamina propria (green arrow) normal vasculature (red arrow) in the mucosa. Villi shows normal architecture with no apparent dimorphism, normal submucosa, muscularis and serosa layer of intestine (blue arrow) H&E 500X

### Statistical analysis

Data are presented as mean  $\pm$  standard error of the mean. The experimental unit of comparison for all analysis between different group were determined by one way ANOVA.

### Results

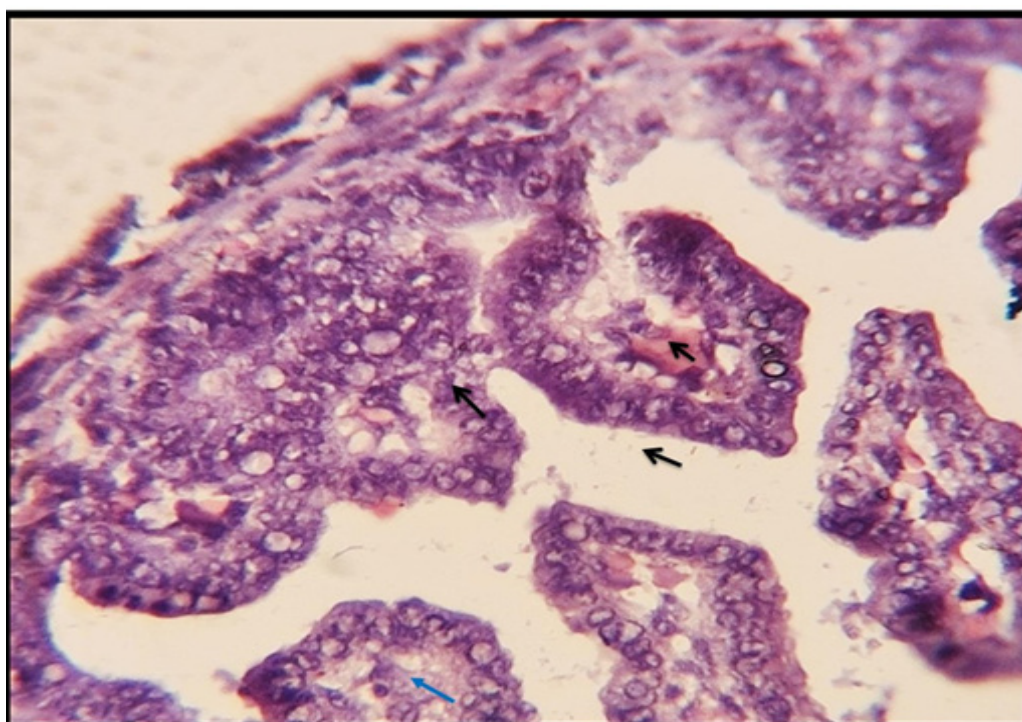
#### *Histopathological changes and Immunohistochemical study result:*

This study obtains the important idea about the effect of warfarin on intestine as shown in Fig. (1) intestine of feti in control group shows normal mono-layer of epithelial lining cells which appear as columnar cells, normal components of the lamina propria and normal vasculature in the mucosa. Villi shows normal architecture with no apparent dimorphism, normal submucosa, muscularis and serosa layer of intestine (black arrow), submucosa layer (large blood vessels, nerve, mucosa secreting gland), muscularized layer (smooth muscle) and serosa layer (blood vessels and nerve) Fig. (1) while intestine of feti treated with warfarin with high dose are shown in Fig. (2), which revealed that the warfarin causes mild congestion on the mucosal layer (lamina

propria) of intestine, while other structures showed normal architecture including villi, epithelial cells appear as mono-layer of columnar cells, other layers including sub-mucosa, muscularis and serosa seemed to be in normal appearance, as illustrated in Fig. 2.

While, in Fig. (3) the intestine of feti which treated with low doses of warfarin shows normal villi architecture, normal columnar epithelial cells, well distributed goblet cells, thin layer of connective tissue consisting the lamina propria containing normal vacuature.

The important idea about the effect of warfarin on skin, the skin layers have three layer the first layer epidermis contain the Squamous Cell Layer (keratin, keratinocytes), the Stratum Granulosum, the Stratum Lucidum and The Stratum Corneum, the second layer dermal (blood vessels, lymph vessels and sweat gland) and third layer hypodermis Sebaceous, oil). In Fig. (4) shows normal epidermis consisting of normal keratin in the stratum corneum, well differentiated cells in the stratum granulosum, normal cells in the stratum basali, normal dermal structure and normal



**Fig. 2.** Intestine of fetus of warfarin treated group, high dose shows normal architecture of the villi, epithelial cells appear as mono-layer of columnar cells (black arrow), lamina propria shows mild congestion of the vasculature (blue arrow), other layers including sub-mucosa, muscularis and serosa appear with in normal appearance (H&E, 500X).

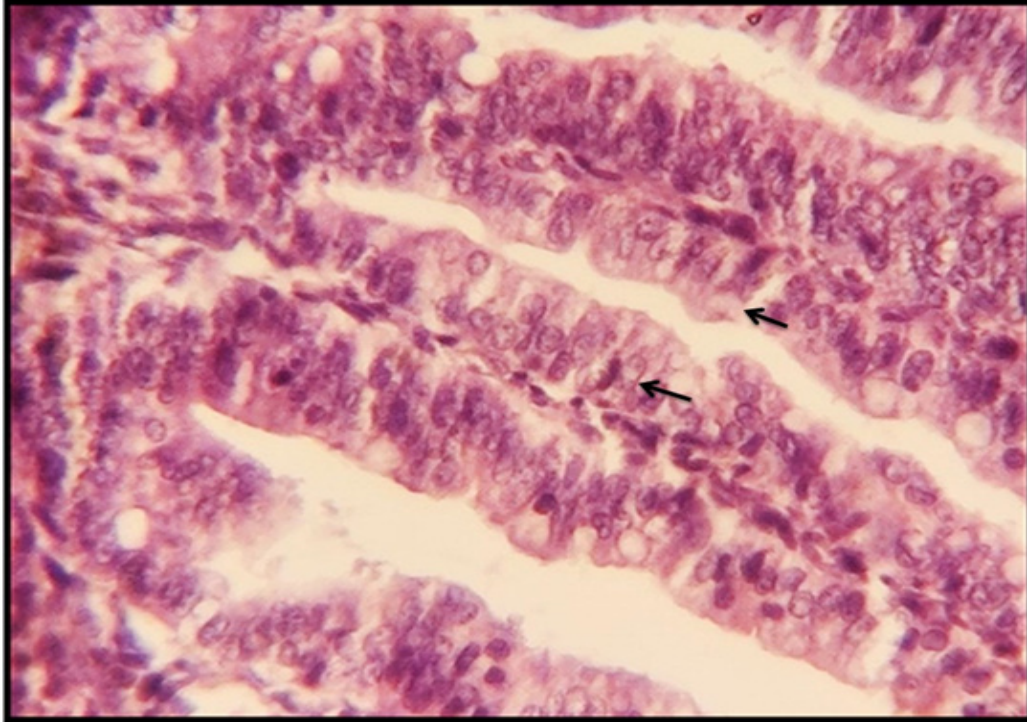


Fig. 3. Intestine of fetus of warfarin treated group, low dose shows normal Villi architecture, normal columnar epithelial cells, well distributed goblet cells (red arrow), thin layer of connective tissue consisting the lamina propria containing normal vasculature (black arrow), H&E, 500X.

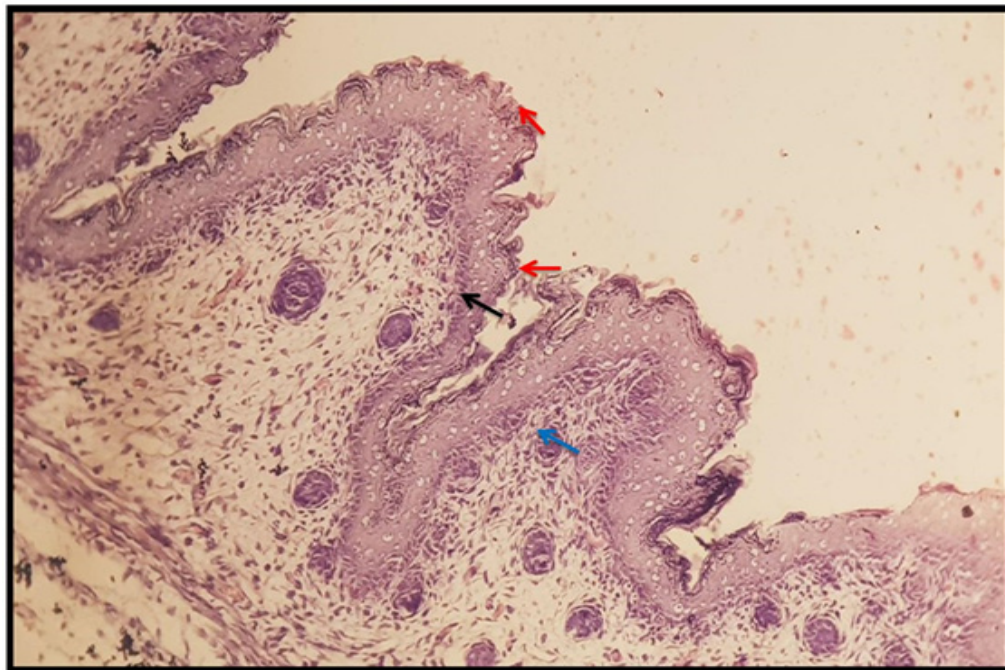


Fig. 4. Skin of fetus of control group shows normal epidermis consisting of normal keratin in the stratum corneum, well differentiated cells in the stratum granulosum (red arrow), normal cells in the stratum basale (black arrow), normal dermal structure and normal hypodermis (blue arrow), normal components of appendages (H&E, 125X)

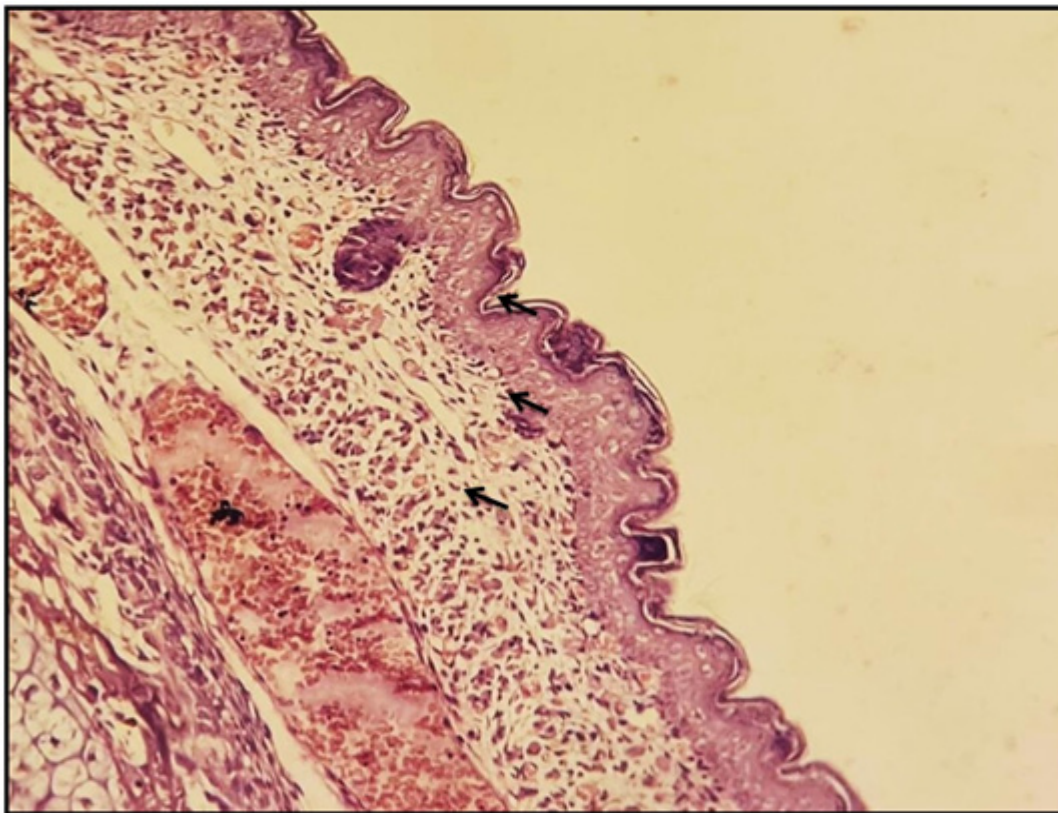
hypodermis (blue arrow), normal components of appendages, while the result in Fig. (5) skin of fetu (20 day) of gestation which treated by warfarin low dose shows congestion and edema on dermal layer (the subcutaneous veins, edema of the subcutaneous tissue), also skin of fetus (20 day) of gestation in treated with high dose in Fig. (6) warfarin shows marked congestion and edema.

The results of Immunohistochemical section in Fig. (7) of 20-day-old fetus of control was show positive expression of SPP1 protein (arrow) in epidermis layer in fetus skin, while SPP1 expression in in Fig. (8) 20-day-old fetus of low dose warfarin treated rat was show Intermediate expression of SPP1 protein in epidermis layer in fetus skin and Intermediate Expression of SPP1 protein in epithelial cells of villi of fetus intestine But the results of Immunohistochemical section in Fig. (9) of 20-day-old fetus of high dose warfarin treated rat was appeared Weak expression of SPP1 protein (arrow) in epidermis layer in fetus skin and Weak Expression of SPP1 protein (arrow) in epithelial cells of villi and crypt of fetus .

3-2-Estimation of biomarker Osteopontin in the serum of pregnant rats treated with warfarin: The results of study in Table (1) show significant decrease in osteopontin in the serum of pregnant rats in both treated group with low doses of warfarin and high doses of warfarin in both (20) day of gestation at level ( $p < 0.05$ )

### **Discussion**

Our study has shown for the first time the effect OPN for inhibitory on development of fetuses. The results in Immunohistochemical section in fetuses of rats show Positive expression (Weak) of SPP1(osteopontin) protein in epidermis layer in fetus skin and appeared SPP1(osteopontin). Expression (Weak) in epithelial cells of villi of fetus in intestine treated which treated with low dose warfarin Whereas the results of Immunohistochemical section in fetuses of rats treated with high dose warfarin appeared weak expression of SPP1(osteopontin) protein in epithelial cells of villi and crypt of fetus intestine and appeared weak expression of SPP1 protein in epidermis layer in fetus skin, compared to the



**Fig. 5. Skin of fetus of warfarin treated group, low dose shows congestion of the subcutaneous veins (black arrow), edema of the subcutaneous tissue (blue arrow) H&E 125X**

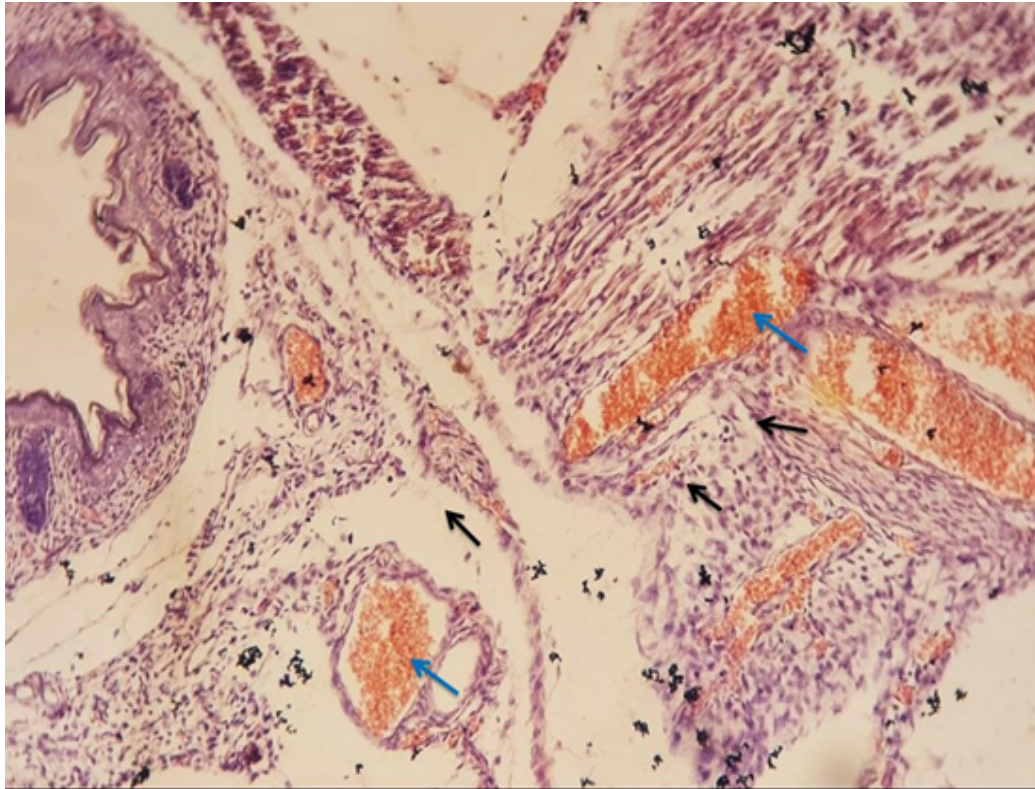


Fig. 6. Skin of fetus 16 days age treated with high dose warfarin shows marked congestion (blue arrow) edema of the subcutaneous tissue (black arrow) edema, still epidermal structures show normal components as mentioned in the Fig. (4) H&E, 125X.

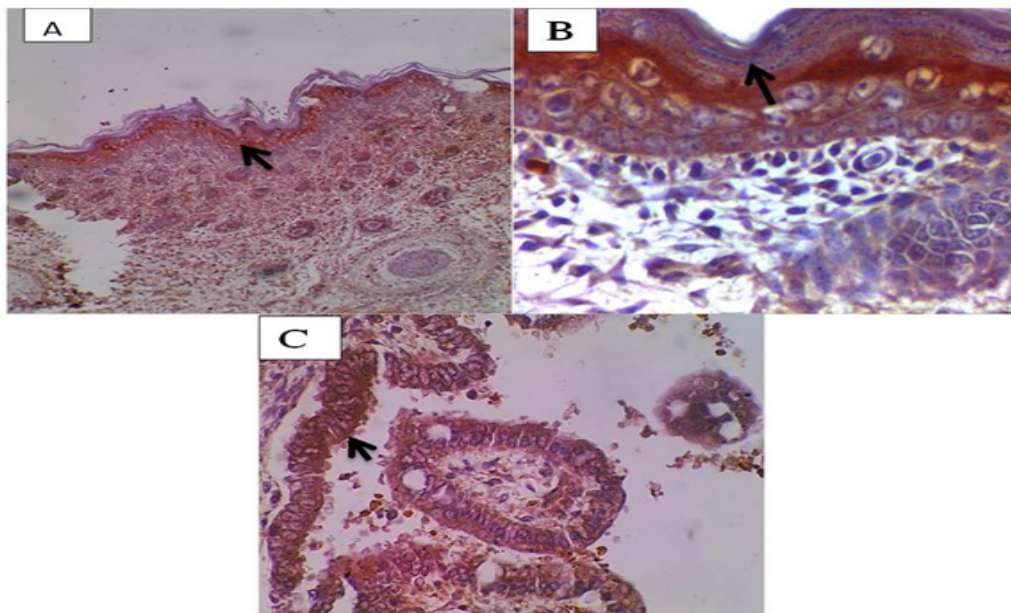
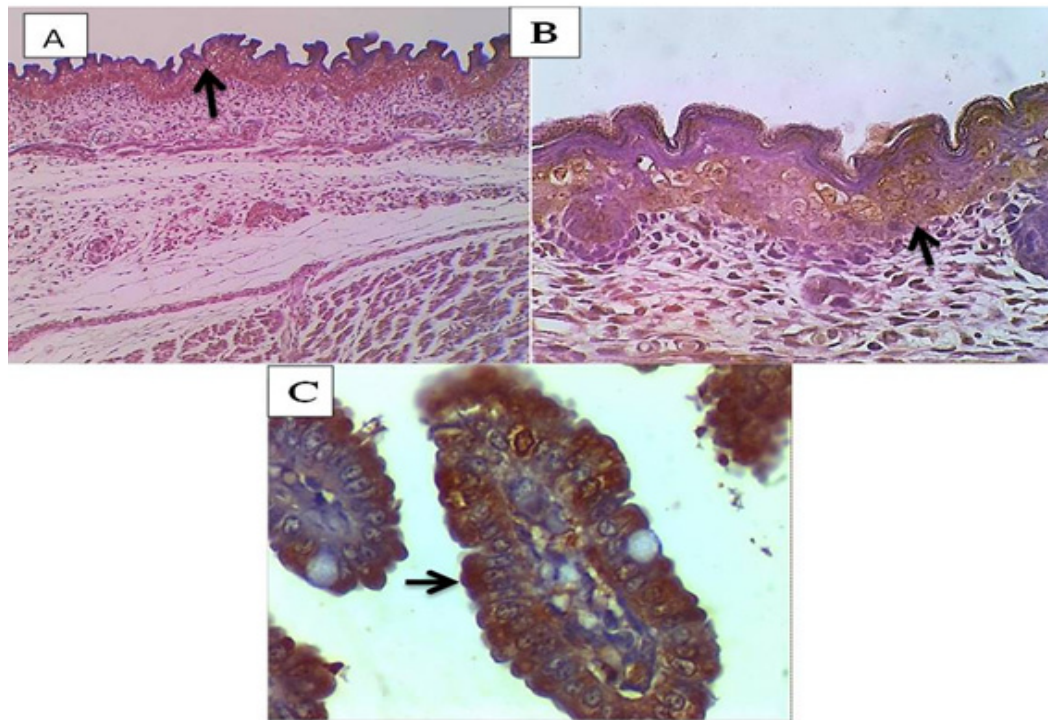
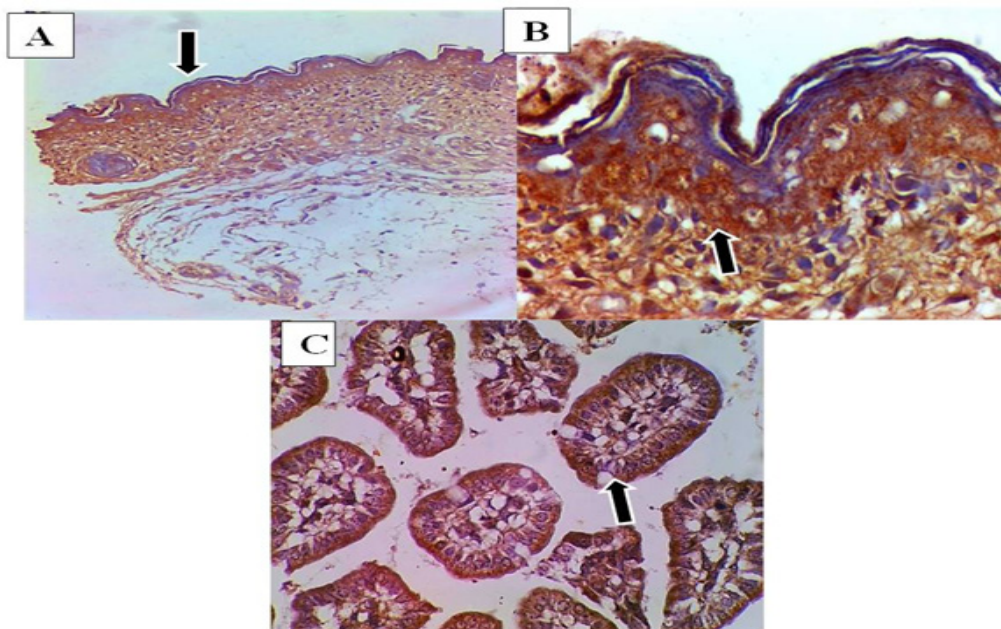


Fig. 7. Photomicrograph of SPP1 expression in 20-day-old fetus of control rat. A&B/ Positive expression of SPP1 protein (arrow) in epidermis layer in fetus skin. C/ Positive Expression of SPP1 protein (arrow) in epithelial cells of villi of fetus intestine. Hematoxylin and DAB. A: 100x and B, C and D: 400x.



**Fig. 8.** Photomicrograph of SPP1 expression in 20-day-old fetus of low dose warfarin treated rat. A&B/ Intermediate expression of SPP1 protein (arrow) in epidermis layer in fetus skin. C/ Intermediate Expression of SPP1 protein (arrow) in epithelial cells of villi of fetus intestine. Hematoxylin and DAB. A: 100x and B, C and D: 400x.



**Fig. 9.** Photomicrograph of SPP1 expression in 20-day-old fetus of high dose warfarin treated rat A&B/ Weak Expression of SPP1 protein (arrow) in epithelial cells of villi and crypt of fetus intestine. C /Weak expression of SPP1 protein (arrow) in epidermis layer in fetus skin. Hematoxylin and DAB. A: 100x and B, C and D: 400x



**TABLE 1. The SPP1 Expression Score Result.**

Group	Score	Expression
Control 20-days-old Fetus	3	Strong
Low-dose Warfarin 20-days-old Fetus	1-2	Weak to Intermediate
High-dose Warfarin 20-days-old Fetus	1	Weak

**TABLE 2. The mean value of Osteopontin at(20) ) days of gestation.**

Name of group	Mean $\pm$ S.D of Osteopontin (20 day)/(pg/ml)n=8
Control	2389.51 $\pm$ 201.48 <sup>a</sup>
(Low Dose (0.05mg/kg	1028.23 $\pm$ 56.08 <sup>b</sup>
(High Dose (0.1mg/kg	1093.44 $\pm$ 0.93 <sup>c</sup>

The small letter (a) refers to significant value at level of  $P \leq 0.05$ .

control group which appear Positive expression of SPP1(osteopontin) protein in epidermis layer in fetus skin and positive expression of SPP1 protein in epithelial cells of villi of fetus intestine. These results match our results in detecting the level of (osteopontin) in the serum of pregnant mothers treated with high and low dose of warfarin, compared with the group of pregnant mothers. The results show significant decrease in osteopontin in the serum of pregnant rats in both treated group with low doses of warfarin and high doses of warfarin in both (20) day of gestation at level ( $p < 0.05$ ) the serum was measuring by using ELISA technique. The study agree with Chang et al.[7] .Another study [14] explain increase of OPN expression is important in differentiated and development of intestine which strongly suggest that OPN: play important roles in intestinal proliferation and maturation, brain myelination, and neurodevelopment, because of OPN act in mineralized tissues and have important immune system functions[15,16], So OPN binds directly to hydroxyapatite, calcium oxalate, and calcite crystal surfaces [17] when decrease of OSP which may induces to increased extracellular phosphate in both physiological and pathological mineralization [18]. One possibility for changes in the mineral-inhibiting potency of OPN would be that warfarin treatment affects the phosphorylation state of OPN [19]. Study has shown agreement with Immunohistochemical study that explain the role of OSP expression

in development human luminal surfaces of the epithelial cells of several tissues and organs like the gall bladder, lung, gastrointestinal, urinary [6]

The histological results intestine of fetus (20 days) age of control group shows normal villi while intestine of fetus of warfarin, in treated group, high dose shows mild congestion of the lamina propria while the in intestine of fetus of warfarin treated group, low dose shows normal villi these result similar to Mirkov et al. [20]. the change of intestine is unclear reason but the relative deficiency in vitamin K dependent clotting factors causing congestion tendency as seen in This study appear the effect of warfarin on skin of treated fetus compare with the control group which shows normal keratin, normal keratinocytes in the epidermis, normal dermal structure also the result skin of fetus treated by warfarin with low dose shows congestion of the subcutaneous veins, edema of the subcutaneous tissue, This result agrees with Abdul-Jabar et al.[21] that the skin of a fetus (20 days old) treated with a high dose of warfarin exhibits marked congestion. the effect of warfarin in skin may be because of decrease in the functional activity and synthesis of coagulant factors II, VII, IX, and X, in addition to a transient early decrease in levels of the naturally occurring anticoagulants protein C and S, may be its action on vitamin K-dependent pathways. When warfarin is started, protein C rapidly drops along with a drop in factor VII levels. Factor IX

decreases more slowly, then factor X, protein S, factor II, and lastly factor X. This may result in a paradoxical hypercoagulable environment that encourages the development of microthrombi in cutaneous and subcutaneous venules, according to Ageno *et al.* [22].

### Conclusion

Our results suggest that Warfarin has negative effect on osteopontin secretion in blood and tissue.

### Acknowledgement

The authors are immensely grateful to Dr. Mukhallad Ramdhan, College of Medicine, University of Misan, for his comments on an earlier version of the manuscript.

### Conflict of interest

The authors have no conflicts of interests to declare.

### Funding statement

There is no financial disclosure.

### Ethical approval

All experimental protocols were approved under the Physiology Department, College of Veterinary Medicine, University of Basrah, Iraq and all experiments were carried out in accordance with approved guidelines.

### References

- Mosby, Inc., Mosby's Dictionary of Medicine, Nursing and Health Professions. 10<sup>th</sup> ed. St Louis, MO: Elsevier, 1746(2017).
- Bauer, K.A. Use of anticoagulants during pregnancy and postpartum. *UpToDate [Internet]* <https://www.medilib.ir/uptodate/show/1342> (2016).
- Campbell, H.A., Roberts, W.L., Smith, W.K. and Link, K.P. Studies of the hemorrhagic sweet clover disease. I. The preparation of hemorrhagic concentrates. *J. Biol. Chem.*, **136**,47–55(1940).
- Tie, J.K. and Stafford, D.W. Structural and functional insights into enzymes of the vitamin K cycle. *J. Thromb. Haemost.*, **14**(2), 236–247 (2016).
- Abutaki, F.H., Alfaraj, D., Alshahrani, A. and Elsharkawy, T. Warfarin-Induced Calciphylaxis in a COVID-19 Patient. *Cureus.*, **12**(12), e12249(2020). [PMC free article: PMC7767840] [PubMed: 33391959].
- Fisher, L.W., Torchia, D.A., Fohr, B., Young, M.F. and Fedarko, N.S. Flexible structures of SIBLING proteins, bone sialoprotein, and osteopontin. *Biochem. Biophys. Res. Commun.*, **280**,460–465(2001). [PubMed] [Google Scholar].
- Chang, P. L., Harkins, L., Hsieh, Y. H., Hicks, P., Sappayatosok, K., Yodsanga, S. and Ho, K. J. Osteopontin expression in normal skin and non-melanoma skin tumors. *Journal of Histochemistry & Cytochemistry*, **56**(1), 57-66(2008).
- Sawad, A. A. and Al-Asadi, F. S. Comparative Study on the Time of Appearance of Primary Ossification Centers in the Skeleton of Laboratory Mice Embryo Al- Qadisiyah. *Journal of Veterinary Medicine Sciences*, **5** (1),1-9(2006).
- Shabab, Z. A., Al-Zobidy, A. M., Al-Eidany, A. H. and AL-Masoudi, W.A. Antimitotic Study of Acetyl Salicylic Acid (Aspirin) on Male Rats (*Rattus Rattus*). *International Journal of Drug Delivery Technology*, **11**(2),632-634 (2021).
- ECHA (European Chemical Agency). «Proposal for Harmonised Classification and Labelling, FORMALDEHYDE.» 31 October (2011).
- Al Malaak, M. K., Almansour, N. A. A. and Hussein, Z. M. Histopathological study on maternal pancreas, placenta and fetal pancreas at 18<sup>th</sup> day postgestation of streptozotocin induced maternal diabetic rats (*Rattus norvegicus*), and the effect of n-butanolic extract of celery seeds (*Apium graveolens*). *Al-Qadisiyah Medical Journal*, **14**(26), 40-59(2018).
- Salman, H. A., Ebraheem, M. K. and Majeed, S. K. The effect of ordinary benzene in the brain of adults female of laboratory mice. *Journal of International Academic Research for Multidisciplinary*, **1**-(4)3 (2015). ISSN: 2320-5083,
- Al Saeed, A. H. and Jori, M. M. Study of physiological and histological changes in rabbits induced with hepatic coccidiosis. *Journal University of Kerbala*, **15** (1), scientific, pages, 1-13 (2017).
- Nystrom, T., Duner, P. and Hultgardh-Nilsson, A. A constitutive endogenous osteopontin production is important for macrophage function and differentiation. *Exp. Cell Res.*, **313**(6), 1149–1160(2007). [PubMed] [Google Scholar].
- Ashkar, S., Weber, G.F., Panoutsakopoulou, V., Sanchirico, M.E., Jansson, M., Zawaideh, S., Rittling S.R., Denhardt, D.T., Glimcher, M.J. and Cantor, H. Eta-1 (osteopontin): an early component of type-1 (cell-mediated) immunity. *Science*, **287**(5454), 860–864 (2000). doi: 10.1126/science.287.5454.860.
- Giachelli, C.M., Speer, M.Y., Li, X., Rajachar, R.M. and Yang, H. Regulation of vascular calcification: roles of phosphate and osteopontin. *Circ. Res.*, **96**,717–722 (2005).
- Asplin, J.R., Arsenault, D., Parks, J.H, Coe, F.L. and Hoyer, J.R. Contribution of human uropontin to inhibition of calcium oxalate crystallization. *Kidney Int.*, **53**, 194–199(1998).

- 
- Steitz, S.A., Speer, M.Y., Curinga, G., Yang, H.Y., Haynes, P., Aebbersold, R., Schinke, T. Karsenty, G. and Giachelli, C.M. Smooth muscle cell phenotypic transition associated with calcification. Upregulation of Cbfa1 and downregulation of smooth muscle lineage markers. *Circ. Res.*, **89**(12),1147–1154 (2001). doi: 10.1161/hh2401.101070.
- Frenzel, D. F., Borkner, L., Scheurmann, J., Singh, K., Scharffetter-Kochanek, K. and Weiss, J. M. Osteopontin deficiency affects imiquimod-induced psoriasis-like murine skin inflammation and lymphocyte distribution in skin, draining lymph nodes and spleen. *Experimental Dermatology*, **24**(4), 305-307(2015).
- Mirkov, Ivana, et al. «Intestinal toxicity of oral warfarin intake in rats. *Food and Chemical Toxicology*, **94**, 11-18 (2016).
- Abdul-Jabar, H.B., Geroulakos, G., Philpott, N. and Fareed, J. Warfarin induced skin necrosis: a case report. *Clin. Appl. Thromb. Hemost.*, **12**,101–104(2006). [PubMed] [Google Scholar].
- Ageno, W., Gallus, A., Wittkowsky, A. W., Mark, C., Elaine, M. Hylek and Gualtiero, P. Antithrombotic therapy and prevention of thrombosis, 9<sup>th</sup> ed: American College of Chest Physicians evidence-based clinical practice guidelines. *Chest.*, **141**(2) (Suppl), e44S–e88S (2012). [PMC free article] [PubMed] [Google Scholar].

## تأثير الوافارين في التعبير الجيني للمؤشر الحيوي الاوستيوبونتين في اجنة الجرذان

رنا خلف عبد الصمد\*<sup>١</sup> ، علاء عبد الخالق السواد<sup>٢</sup> و فارس شاكر كاطع<sup>١</sup>

<sup>١</sup> قسم علوم الحياة - كلية التربية للعلوم الصرفة - جامعة البصرة - البصرة - العراق.

<sup>٢</sup> قسم التشريح - كلية الطب البيطري - جامعة البصرة - البصرة - العراق.

تعطي الدراسة الحالية لمحة عامة عن تأثير إعطاء الوافارين على الفئران الحوامل التي تعرضت عن طريق الفم للوافارين (٠,٠٥ مجم / كجم بالوزن أو ٠,١ مجم / كجم بالوزن) يومياً في الأيام من صفر إلى ١٥ من الحمل. تم التضحية بالحيوانات الحامل في الأيام (٢٠) من الحمل تحت التخدير العام بمزيج من الزيلازين والكيثامين وجمع عينة الدم من قلب الفئران الحوامل لغرض دراسة الكيمياء النسيجية المناعية. تم تقسيم عينات الاجنة التي تم تضمينها بواسطة البارافين بسبك ٤ميكرومتر لتقنية التشريح الجراحي واستخدمت تقنية الكيمياء النسيجية المناعية لمقارنة علاقة تعبير أوستيوبونتين مع تكاثر الأمعاء والجلد في الاجنة حيث تظهر النتيجة تعبيراً إيجابياً عن بروتين أوستيوبونتين في أمعاء الجنين ، بينما يظهر الجرذ المعالج بجرعة منخفضة من الوافارين تعبيراً متوسطاً لبروتين في طبقة البشرة في جلد الجنين والخلايا الظهارية الزغابات المعوية للجنين ، وكذلك أظهرت نتائج الجرذ المعالج بجرعة عالية من الوافارين يظهر ضعف التعبير عن بروتين في الخلايا الظهارية للزغابات من أمعاء الجنين .

الاستنتاجات: تشير النتائج الى ان الوافارين له تأثير سلبي على أفرز في الدم والأنسجة.