

Newcastle disease in pigeon review article

Muhammادتahir A. Abdulrasool, Waleed Majeed Seger

Department of Pathology and Poultry Diseases, College of Veterinary Medicine, University of Basrah.

Corresponding Author Email Address: muhammad.tahir@uobasrah.edu.iq

ORCID ID: 0000-0001-6378-0700

DOI: [10.23975/bjvetr.2023.178292](https://doi.org/10.23975/bjvetr.2023.178292)

Received: 22 Nov. 2022 Accepted: 25 Jan. 2023.

Abstract

Newcastle disease (ND) is a viral disease of poultry and other bird species like pigeon (*Columba livia*), it characterizes as devastating and contagious and it has been distributed worldwide. ND in pigeons is caused by pigeon paramyxovirus type 1 (PPMV-1) which is an antigenic and host variant of the avian paramyxovirus serotype 1 (APMV-1), the disease in pigeons is termed paramyxovirus and cause nervous signs with high mortality usually in the bird with kidneys infected with viscerotropic strains, and neural signs appeared individually. PPMV-1 was initially detected by hemagglutination activity (HA) and confirmed with hemagglutination inhibition assay (HI), and molecular-based techniques. Serological diagnosis of paramyxovirus is necessary because of the similarity of the PPMV-1 infection with sodium chloride poisoning, pigeon herpes virus infection (PHV), and ornidazole overdose that cause same neurological signs. PPMV-1 infection can be controlled effectively by vaccination by specific vaccines associated with good biosecurity aspect

Key words: PPMV-1, pigeon paramyxovirus type 1, pigeons, ND.

Definitions and Synonyms

Newcastle disease (ND) is a contagious and infectious viral disease of avian species caused by a virus of avian paramyxovirus serotype 1 (APMV-1) that effecting chickens, and affecting most domestic birds including pigeons (1). The infection is an

established cause mortality of high range in the chicken industry, resulting in massive economic losses (2). In pigeons it's called paramyxovirus and caused by antigenic "pigeon variant" of (APMV-1) (3).

Historical information on paramyxovirus infections in pigeons

ND is a critical, economic viral disease causing, in some outbreaks, high mortality reaches 100 %, so it is listed with the A-List diseases of the World Organization for Animal Health, List A is those diseases characterized by high transmission, and their incidence is of great importance for those who deal with the commerce of animals (1). ND in pigeons is termed paramyxovirus caused by antigenic "pigeon variant" of (APMV-1) called pigeon paramyxovirus serotype 1 (PPMV-1) (3).

The characterization of PPMV-1, which was first isolated from pigeons in Iraq in 1978, was described by (3). The eastern part of Europe and North Africa then became infected with the virus that spread from the Middle East area and 1981-1983, the virus spread throughout Europe and the world (4).

Etiology

ND in pigeons is caused by PPMV-1, which is an antigenic and host variant of APMV-1, which belongs to the Paramyxoviridae family, subfamily Avulavirinae and genus (Deltabaculovirus, Orthoavulavirus, and Paraavulavirus) (5).

The Molecular Structure of PPMV-1

The paramyxovirus genome is a non-segmented, single-stranded, negative sense, RNA genome, composed of approximately 15000 nucleotides that encode eight viral proteins: structural proteins such as Nucleoprotein (NP), phosphor protein (P), Matrix (M), Fusion (F), Hemagglutinin-Neuraminidase (HN) and Large RNA polymerase (L), and nonstructural proteins such as V and W, the V and W proteins are

additional proteins formed by the insertion of non-templated G residue into P gene ORF during P gene transcription by a process called RNA editing by viral RNA polymerase (figure 1)(6). PPMV-1 strain can be divided into classes I and II according to the genome size and sequence analysis. Class I contains a single genotype, while Class II viruses are the most virulent, and approximately eaten genotypes are identified. Genotypes I to IV Viruses are primary sub lineages with a genome of 15,186 nt in size, while the viruses of (V to XVII) have a genome of 15,192 nt in size. furthermore, Genotype VI is split into sub genotypes VIa to Vii (7).

Most viruses from pigeons are belonging to genotype VI of Class II, particularly sub-genotype VIb (8). Because of an antigenic variant of APMV-1, PPMV-1 has a universal spread of ND infections in pigeons (8). The F proteins of PPMV-1 strains have a motif at the F2/F1 cleavage site,¹¹²G/R-R-Q-K-R-F¹¹⁷, which is thoroughly associated with the velogenic strains (9).

Course of infection

With the PPMV-1 infection in pigeons, the incubation period varies from several days to a few weeks. paramyxovirus mainly occurs with similar clinical signs of diseases with ND viruses of the neurotrophic velogenic form (10). However, some field cases that currently occur are caused by strains of a viscerotropic group that show a particular renal affinity; therefore, polyuria with polydipsia are the first symptoms that appeared, followed by neural symptoms

which manifest individually in the birds (11). The occurrence varies by about 50%, with mortality not overtaking 10%. When secondary bacterial or parasitic infections are associated, the mortality rate may exceed 30% (10). PPMV-1 infection is mainly associated with pigeon circovirus infection (PiCV) (3).

Torticollis (twisting of the head and neck 180°), paralysis of legs and wings as a neural sign with imbalance, and difficulties in food intake most commonly appear during the infections, and sometimes, infected birds have bloody or watery diarrhea in case of kidney infection. Abnormal feather development when the infection occurs during molting; feathers appear fragile, deformed, and poorly developed (10).

Clinical signs and Pathology

ND is a critical problem in avian species, including pigeons. In pigeons, paramyxovirus-1 (PMV-1) infection, ideally, causes high morbidity and mortality rates of an average of 80% (11). Infected pigeons with natural and experimental outbreaks showed greenish-white diarrhea with nervous signs, including wings and legs paralysis, neck paresis, tremor of the head, rotation for one side, and incoordination(12). Experimentally inoculated pigeons showed respiratory signs, including labored breathing, respiratory distress, coughing, and rales. Also, conjunctivitis with lacrimation ended in the blindness of the infected pigeon(13). In experimental infection with

paramyxovirus, gross lesions include hemorrhages and swelling in the brain, proventriculus, liver, spleen, and kidneys, and also, there is catarrhal enteritis and visceral congestion(14). In natural infection, the gross lesions of ND include swelling and hyperemia of the kidneys and changes in the bursa of fabricius and thymus (10).

Neurological symptoms such as wings paresis or legs, torticollis, disturbed equilibrium, pecking aside seeds (Figure 2), and digestive signs are often observed with no respiratory symptoms; A distinctive digestive form is seen progressively more frequently and consists of persistent diarrhea without nervous symptoms; Broken feathers, Poorly developed remiges, and badly grown barbs and barbules may be seen when infection occurs during the molt (10). Histopathological changes were shown in the brain, trachea, lungs, liver, spleen, and kidneys of the pigeons affected with paramyxovirus-1, including hyperplastic changes and mononuclear infiltration cells, especially lymphocyte(13,14). The prevalent histopathological changes in kidneys were chronic tubular necrosis and interstitial nephritis. In contrast, in the brain, the dominant histopathological lesions were perivascular lymphocytic cuffing, gliosis, and degeneration of Purkinje cells (10)

Diagnosis of PPMV-1 Infection

Oropharyngeal, and cloacal swabs from live pigeon, or tracheal swabs and pieces of brain, lungs, liver, spleen, intestine, and kidneys as samples from dead pigeon should be taken and set in a mixture of phosphate-buffered saline (PBS) with

antibiotics. After homogenizing, the samples are centrifuged and the stuck are inoculated into the allantois cavity of SPF embryonated chicken eggs of 10 days old incubation. Then the inoculated eggs are incubated for 4-7 days or until the embryos die. After that, the allantois fluids harvested are tested with a hemagglutination activity (HA) test using chicken RBCs(15,16). Carrying out HA assay only is insufficient to correctly identify the PPMV-1, as all avian paramyxoviruses serotypes and avian influenza viruses (AI) show hemagglutination activity. So, the hemagglutination inhibition (HI) test is recommended to be performed using a monospecific antiserum for the ND virus (17). Serological techniques used to detect the antibody titers are of restricted diagnostic value, that depends on the flock's immune status. Office International des Epizooties recommends using the HI method to detect specific antibodies of the ND virus, which does not indicate a current infection and can be a post-vaccinal immune response only (16). The distinction between virulent and non-virulent strains of PPMV-1 is possible by SYBR Green and a pair of degenerate primers and the results depend on melting curve analysis of the rRT-PCR product (18). The non-virulent strains have a melting temperature (T_m) ranging from 80.00 to 83.80°C, while the T_m of the strains mesogenic and velogenic is above 83.80°C. This technique is considered an alternative to the TaqMan rRT-PCR when using 2-3 pairs of primers. Different types of TaqMan probes in one reaction are requisite

to distinguish serotypes of NDV, which significantly raises the test cost (3).

Disease control

After the biosecurity standards, which include controlling rodents, disinfection of all equipment before use, ensuring to use of healthy food, quarantining of new birds, and others, Inactivated oil-based vaccines are used as a prophylaxis of paramyxovirus in pigeons (19). By subcutaneous injection method, the vaccines are administered in several vaccination programs (20). The LaSota strain is one of the strains of paramyxoviruses that the vaccines are commonly based on despite the antigenic differences between LaSota and PPMV-1 strains (19).

On the other hand, despite using the LaSota strain vaccine, PPMV-1 in some countries was considered enzootic in pigeons, so the homologous vaccine is an appropriate solution for controlling PPMV-1 infection(19). However, the cases of breaking post-vaccination immunity are sometimes increased due to immunosuppression associated with prevalent pigeon circovirus (PiCV), adeno virus and herpes virus infections (3). Due to the low immunogenic level of live vaccines and the probability of the spread of the vaccine virus by carrier pigeons to unvaccinated areas, live vaccines do not involve the immunoprophylaxis of PPMV-1 infection in pigeons (17). However, the vaccination does not prevent paramyxoviruses from occurring or PPMV-1 replication but only prevents the incidence of clinical signs (21).

Final consideration

ND is found in nearly all domesticated birds, including pigeons. The high mortality rate highlights the economic impact of the diseases. In pigeon the disease likely appeared as in other birds and characterized of nerves signs and caused by an antigenic

and host variant of APMV-1 called pigeon paramyxovirus serotype 1 (PPMV-1). For disease control, biosecurity guidelines and many vaccination programs were described.

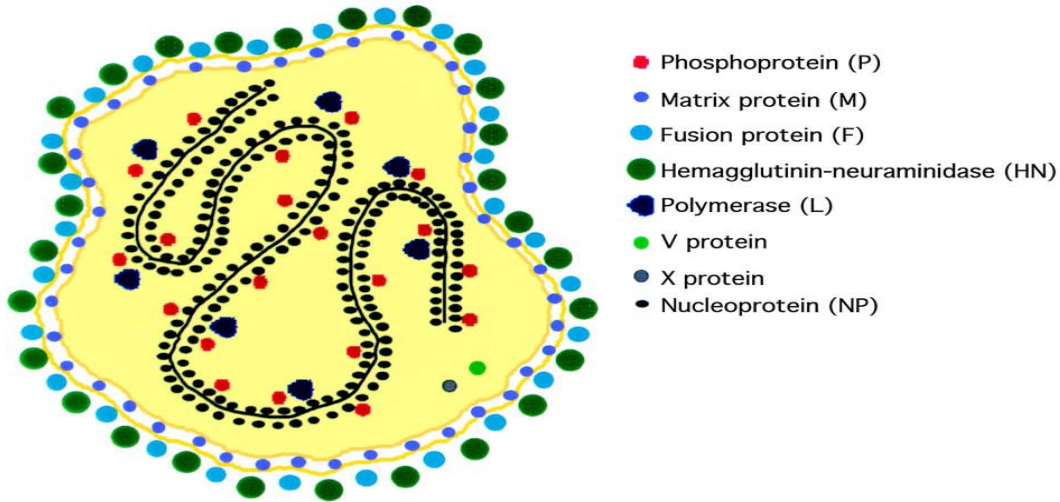


Figure 1 Newcastle disease virus structure (6)



Figure 2 Neurological signs, disturbed equilibrium PPMV-1infection (10)

References

1. OIE. (2013). Manual of Diagnostic Tests

- and Vaccines for Terrestrial Animals. *OIE Terrestrial Manual, May*, 1–104.
2. Sadiq, M. B., & Mohammed, B. R. (2017). The economic impact of some important viral diseases affecting the poultry industry in Abuja, Nigeria. *Sokoto Journal of Veterinary Sciences*, *15*(2), 7. <https://doi.org/10.4314/sokjvs.v15i2.2>
 3. Pestka, D., Stenzel, T., & Koncicki, A. (2014). Occurrence, characteristics and control of pigeon paramyxovirus type 1 in pigeons. *Polish Journal of Veterinary Sciences*, *17*(2), 379–384. <https://doi.org/10.2478/pjvs-2014-0056>
 4. Alexander, D. J., Russell, P. H., Parsons, G. E. M. E. A. E., Ballouh, A., & K. Cernik, B. Engstrom, M. Fevereiro, H.J.A. Fleury, M. Guittet, E.F. Kaleta, U. Kihm, J. Kusters, B. Lomniczi, J. Meister, G. Meulemans, K. Nerome, M. Petek, S. Pok, L. S. & B. T. (1985). Antigenic and biological characterisation of avian paramyxovirus type 1 isolates from pigeons-an international collaborative study. *Avian Pathology*, *14*(3), 365–376. <https://doi.org/10.1080/03079458508436238>
 5. Amarasinghe, G. K., Ayllón, M. A., Bào, Y., Basler, C. F., Bavari, S., Blasdel, K. R., Briese, T., Brown, P. A., Bukreyev, A., Balkema-Buschmann, A., Buchholz, U. J., Chabi-Jesus, C., Chandran, K., Chiapponi, C., Crozier, I., de Swart, R. L., Dietzgen, R. G., Dolnik, O., Drexler, J. F., Kuhn, J. H. (2019). Taxonomy of the order Mononegavirales: update 2019. *Archives of Virology*, *164*(7), 1967–1980. <https://doi.org/10.1007/s00705-019-04247-4>
 6. Phale, S. (2018). Newcastle Disease Virus: Structural and Molecular Basis of Pathogenicity. *Medicinal Chemistry*, *08*(08), 202–204. <https://doi.org/10.4172/21610444.1000514>
 7. Wei, T., Deng, Q., Li, H., Pan, C., Zhai, G., Yuan, Y., Cheng, E., Zhang, Y., Mo, M., Huang, T., & Wei, P. (2018). Molecular characterization of two novel sub-sublineages of pigeon paramyxovirus type 1 in China. *Archives of Virology*, *163*(11), 2971–2984. <https://doi.org/10.1007/s00705-018-3950-38>.
 9. Wang, J., Liu, H., Liu, W., Zheng, D., Zhao, Y., Li, Y., Wang, Y., Ge, S., Lv, Y., Zuo, Y., Yu, S., & Wang, Z. (2015). Genomic characterizations of six pigeon paramyxovirus type 1 viruses isolated from live bird markets in China during 2011 to 2013. *PLoS ONE*, *10*(4), 1–12. <https://doi.org/10.1371/journal.pone.0124261>
 10. Marlier, D., & Vindevogel, H. (2006). Viral infections in pigeons. *Veterinary Journal*, *172*(1), 40–51. <https://doi.org/10.1016/j.tvjl.2005.02.026>
 11. Ren, S., Wang, C., Zhang, X., Zhao, L., Wang, X., Yao, W., Han, Q., Wang, Y., Fan, M., Gao, X., Xiao, S., Wang, X., & Yang, Z. (2017). Phylogenetic and pathogenic characterization of a pigeon paramyxovirus type 1 isolate reveals cross-species transmission and potential

- outbreak risks in the northwest region of China. *Archives of Virology*, 162(9), 2755–2767.
<https://doi.org/10.1007/s00705-017-3422-1>
12. Xiang, B., You, R., Kang, Y., Xie, P., Zhu, W., Sun, M., Gao, P., Li, Y., & Ren, T. (2019). Host immune responses of pigeons infected with Newcastle disease viruses isolated from pigeons. *Microbial Pathogenesis*, 127(July 2016), 131–137. <https://doi.org/10.1016/j.micpath.2018.11.049>
 13. Khammas, E. J. (1981). Study of Some Aspects of ND in Experimentally Infected Birds. thesis.
 14. Shaheen, S., Anjum, A. D., & Rizvi, F. (2005). Clinico-pathological observations of pigeons (*Columba livia*) suffering from Newcastle disease. *Pakistan Veterinary Journal*, 25(1), 5–8.
 15. Al-mubarak, F. T. M., Ghanim, A. F., Thwiny, H. T., & Younus, I. K. (2020). Molecular and serological identification of newcastle disease virus propagated in embryonated chicken eggs. *Basrah Journal of Veterinary Research*, 19(3), 241–247.
 16. Epizooties, O. O. I. des. (2018). Manual of Diagnostic Tests and Vaccines for Terrestrial Animals. In *Manual of Diagnostic Tests and Vaccines for Terrestrial Animals*. 6th ed. 964–983.
 17. , Śmietanka, K., & Minta, Z. (2011). Newcastle disease. In Mazurkiewicz M (ed) Poultry diseases. Uniwersytet Przyrodniczy we Wrocławiu, Wrocław 361–372.
 18. Nidzworski, D., Rabalski, L., & Gromadzka, B. (2011). Detection and differentiation of virulent and avirulent strains of Newcastle disease virus by real-time PCR. *Journal of Virological Methods*, 173(1), 144–149. <https://doi.org/10.1016/j.jviromet.2010.12.015>
 19. Amer, M. I.S., El-Bagoury, G.F. and Khodeir, M. H. (2013). Evaluation of the immune response of pigeons to ND and pigeon paramyxovirus vaccines. *Benha Veterinary Medical Journal*, 25, 148–156.
 20. Talib, D. Y., & Thwiny, H. T. (2020). Assessment of immunity induced by newcastle disease virus vaccines and determine the best vaccination program in broiler chicken. *Basrah Journal of Veterinary Research*, 19(3), 149–162.
 21. Alexander, D. J. (2011). ND in the European Union 2000 to 2009. *Avian Pathology*, 40(6), 547–558

مقال مراجعة مرض نيوكاسل في الحمام

محمد طاهر عبد الرزاق عبد الرسول ،وليد مجيد صكر
فرع الامراض وامراض الدواجن ،كلية الطب البيطري ،جامعة البصرة،البصرة،العراق.

الخلاصة

مرض نيوكاسل (ND) هو مرض فيروسي يصيب الدواجن وأنواع الطيور الأخرى ومن ضمنها الحمام (*Columbi livia*)، ويتميز المرض بأنه مدمر ومعدي وهو منتشر في جميع أنحاء العالم. العامل المسبب لمرض نيوكاسل الحمام في الحمام هو فايروس البارامكزو (paramyxovirus) من النوع المصلي رقم 1 (PPMV-1) والذي يكون متغيرا عن العترة الفايروسية التي تصيب الدجاج والمعروفة بال (avian paramyxovirus (serotype 1 (APMV-1)). يسمى المرض في الحمام بال (paramyxovirosis) ويسبب علامات عصبية مع ارتفاع معدل الهلاكات. الهلاكات العالية عادة تكون في الطيور المصابة بالكلى بالسلالات الحشوية الشديدة الضراوة والعلامات العصبية ظهرت بشكل فردي. تم اكتشاف الفايروس في البداية عن طريق اختبار التلازن الدموي ((hemagglutination activity (HA)) وتم تأكيد الإصابة باستخدام اختبار تثبيط التلازن الدموي ((hemagglutination inhibition assay (HI)) ، والتقنيات الجزيئية (molecular) الأخرى. التشخيص المختبري لمرض نيوكاسل الحمام ضروري جدا بسبب تشابه المرض مع تسمم كلوريد الصوديوم، عدوى فيروس هريس الحمام (PHV)، والجرعة الزائدة من الرونيديازول (مضاد للالوي) التي تسبب نفس العلامات العصبية. يمكن السيطرة على فايروس نيوكاسل الحمام بشكل فعال عن طريق التلقيح مع الاهتمام بجوانب الأمن الحيوي الجيدة.

الكلمات المفتاحية: نيوكاسل الحمام، فايروس بارامكزو الحمام النوع المصلي رقم 1، نيوكاسل.