

# Efficacy of rubber band ligation of hemorrhoids grade I-III in a single session: A prospective study from 2018-2020

Assad Mohammed Kadhim<sup>1</sup>, Madhi Hashim Otaiwi Altaraikhim<sup>2</sup>, Adil G. Fadhil<sup>1</sup>

<sup>1</sup> Department of Surgery, College of Medicine, University of Basrah, Basrah, Iraq

<sup>2</sup> Department of Dentist Medicine, Al- Kunooz University College, and Al-Mawaneeh Teaching Hospital, Health directorate Basrah, Basrah, Iraq

## Abstract

**Background:** Hemorrhoids are one of the most common diseases in the world, with a high prevalence that includes all age groups and both sexes. Rubber band ligation (RBL) is a non-invasive, non-operative treatment that can be done in an outpatient.

**Objectives:** The study was conducted to determine the effectiveness of (RBL) treatment of hemorrhoids grade I-III and follow-up of these patients to evaluate this type of treatment in terms of symptomatic relief and recurrence of hemorrhoids and its complications.

**Study design:** A prospective, and interventional study was undertaken over the period of 2 years in two private clinics with a sample size of 479 patients with internal hemorrhoids.

**Result:** Out of 479 patients with internal hemorrhoids, 94.8% was male. The success rate was 80.4% and it is a relatively high rate. There were no major complications were noticed in this study, despite of simple minor complication that are encountered in any surgical procedures, include very mild pain (16.2%), retention of urine (14.4%), vasovagal attack (5.2%), mild infection at the site of the procedure (5.6%), thrombosis (5.4%), few drops bleeding (9.6%). All these complications need simple treatments.

**Conclusions:** RBL was easy, non-complicated safe surgical procedure for the treatment of internal hemorrhoids can be done in the outpatient clinic with high rate of successful and minor complications.

*Key words: Hemorrhoid, single session, rubber band ligation*

## Introduction

The hemorrhoids are swollen blood vessels in the anus and are very common disease worldwide, the prevalence varies from country to another, generally it reaches over 50% in the USA, while in UK may reach about 60%-70%<sup>1</sup>. The etiology including; chronic constipation, prolong strain during defecation, hard stool, sedentary lifestyle, type of food and low fiber diet<sup>1-4</sup>. The rubber band ligation is a type of treatment for hemorrhoid with minimum invasive technique that use a rubber band to tying the base of piles<sup>5</sup>. It was the most successful, non-operative method of treating 1st, 2nd and 3rd degree hemorrhoids<sup>6-11</sup>. The hemorrhoid is the normal collection of soft tissue containing artery and venous network, lymphatic and nerve, situated between mucosa and muscular wall of lower rectum and anal canal<sup>2-4</sup>. The advantages of hemorrhoid tissue is to make anal cushion like, to protect mucosa during defecation procedure and straining and also had a role in continence<sup>2, 3, 8</sup>.

The treatment of hemorrhoid, extended from conservative treatment for grade I pile like, use of anal ointments, treatment of constipation and change in lifestyle, to non-operative procedures as rubber band ligation (RBL), infrared coagulation, sclerotherapy, electrocoagulation, and laser hemorrhoidoplasty<sup>8, 12, 13</sup>. Hemorrhoidectomy and stapler hemorrhoidopexy are the two main procedures use for high grade hemorrhoids<sup>12, 13</sup>.

## Patients and methods

### *Study design and setting*

This is a prospective, interventional study, was conducted on 479 selected patients with 1st to 3rd grade hemorrhoids presenting to two private surgical clinic in Basrah. It was carried out over a period of three years from (2018-2020). After taking an informed consent from each patient, a detailed history taken by already designed a questionnaire form; it includes age, sex, occupation, residency, chief complaint and its duration. Clinical examination done by two expert surgeons, the rectal examination was done by using a proctoscope to confirm diagnosis of hemorrhoid and to classify into the grades.

### *Procedure*

The procedure was done by using Barron band ligator<sup>9, 14</sup>, which was present since the sixteenth century until now. In this study it used with some modification, new one preloaded with multiple bands instead of an older one, that need to be loaded for each pile. Another type, with suction maneuver instead of forceps pulling. Here, we use the forceps pulling the dome of each pile and ligation the base. Then take a good amount of tissue. Keep ligation above the dentate line, and ask the patient if he feel any pain, if no pain do firing and ligation. By using quietly large sized proctoscope with inner diameter opening 2.5 cm and outer diameter 3 cm for more and perfect visualization of the anal canal and easily controlling and banding of all piles.

### *Follow up*

The rubber band will induce ischemia, necrosis of ligated tissue, sloughing of tissue occurs and band fall 5-7 days with some bleeding. Advised patient for proper care of anal area,

of good hygiene and prevention of constipation and eating much fluid, and diet with high fiber. Follow up of a patient includes, examination of patients 10 days postoperatively and looking for patient satisfaction, comfortable and you look for complications if occur. Another visit of a patient done one-month later, then every six months for two years.

## Results

The age ranged from 19-67 years, the majority of attendance were male, 454 (94.8%) patients and 25 (5.2%) were female. Pain experienced only in 78 patients (16.2%) from the total attendance. Retention of urine noted in 69 patients (14.4%). Vasovagal attack occurred during an operation in 25 patients (5.2%). While infection at the site of operation noted during the first week after operation seen only in 27 patients (5.6%). Hemorrhoid thrombosis occurred in 26 patients (5.4%), while bleeding per rectum which occurred after 7 days post-operative noted in 46 patients (9.6%).

Recurrence of hemorrhoid, noted in 94 patients (19.6%), 74/94 of them need other ligation session, 13/94 patients treated conservatively, and only 7/94 patients of them need surgical hemorrhoidectomy. (Figure 1)

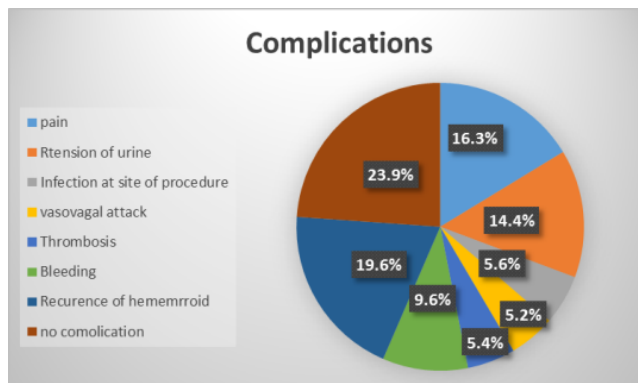


Figure 1. Complications of RBL

## Discussion

Any treatment, especially surgical one, should be safe, especially during the treatment of non-life-threatening diseases such as hemorrhoids, as there is no single treatment is better and different modalities are available depending on several factors including age, general health status, presence of chronic diseases and other factors<sup>10</sup>. The rubber band ligation has been studied in different studies with average success rate is about 75%. In our study, the success rate was high it was about 80%.

Recurrence of hemorrhoid occurs in about 19.6%, however, this rate is acceptable in another modality like HAL, laser, procedures and even stapler hemorrhoidopexy<sup>9</sup>. This result slightly higher than in a study done in Singapore in which the recurrence rate after two years was 16.7%<sup>15</sup>, while it was lower than that observed in a study done in India in which they notice the recurrence rate of hemorrhoids was 31.7%<sup>16</sup>.

The cause of recurrence includes; slipping of band this will occur due to small amount of tissue ligated, or hamper in the gun, prolong straining at defecation or the patient doing the hard work<sup>6, 7, 17</sup>.

In many studies regarding the using of one and multiple sessions ligations of hemorrhoids, they found that there was no much difference between the two approaches, in possibility of complications like bleeding, anal pain, retention of urine and infection and if occurred it can manage it easily<sup>11, 18, 19</sup>. In our study, the complications that encountered were very simple and can be managed easily with simple treatment. Regarding the pain experienced by patient in the first few days post procedure were noted in 16.2% from total patients under study and it is mild in nature need simple analgesic, and result was lower than that observed in studies conducted in Turkey and India in which about (38%, 20% respectively) patients felt pain post the procedure<sup>17, 19</sup>.

Retention of urine occurs in about 14.4% and this was of mild form treated conservatively, and it is higher than that observed in other studies<sup>17, 18, 19</sup>. Vasovagal attack, which was encountered in many surgical procedures, in our study was shown in relatively small patients about 5.2%, which was treated conservatively, it is lower than that in the study in Turkey 10.5%<sup>17</sup>, and it was near the result in Singapore 2.7%<sup>18</sup>. Infection at the site of ligation and hemorrhoidal thrombosis occurred in very low percent in our study 5.6%, and 5.4% respectively.

Bleeding is a very important complication that must be looked for vigorously because sometime it is so severe need an urgent treatment and may be life threatening and if it is continued for a long period of time lead to anemia. In our study bleeding was noted in only 9.6% and it was very mild in form of a few drops of blood stoppe spontaneously. This result was lower than that noted in other studies in Turkey was 15%, and in Singapore was 10.2% and had a few patents developed severe bleeding needed a blood transfusion, and in the Indian study only 10 patients had bleeding<sup>17, 18, 19</sup>.

## Conclusions

Rubber band ligation is safe, effective, and outpatient procedure for grade I-III hemorrhoid with minimal complication, preserve anal sphincter and no change in the anorectal anatomy. It improve symptoms and maintain good quality of life. Although, there is recurrence, but, the rate is acceptable in the comparism with other modalities of treatment.

## References

1. Medscape gastroenterology rubber band ligation update. sept 4, 2017. <https://emedicine.medscape.com/article/1892099-overview>
2. Mobeen A, Ahmed A, Quamri MA, Ansari AN. Clinical Efficacy of Medicinal Leech Therapy in Treating Third- and Fourth-Degree Hemorrhoids. *Journal of Coloproctology* 2021; 41(02): 124-130.
3. Wani AA, Khuroo S, Heer VK, Jain SK, MaqsoodmS, Malik A. Recurrent Hemorrhoids—Efficacy, Utility and Initial Experience with the Use of Stapled Hemorrhoidopexy in Recurrent Hemorrhoids. *Journal of Coloproctology* 2021;41(0):1-5.

4. Davis PR, Lee-Kong SA, Migaly J, Feingold DL, Steele SR. The American Society of Colon and Rectal Surgeons. Clinical practice guideline for management of hemorrhoids.
5. Albuquerque A. Rubber band ligation of hemorrhoids: A guide for complications. *World J Gastrointest Surg.* 2016 Sep 27;8(9):614-620.
6. Damor S, Balat J, Nahar G, Balat H, Vohra A, Patel H. Evaluation of rubber band ligation as outpatient procedure for the treatment of internal hemorrhoid prospective study. *Int J Res Med.*, 2013; 2(1):42-46.
7. Chaleoykitti B. Comparative study between multiple, single RBL in one session for bleeding internal hemorrhoid prospective study. *J Med Assoc Thai.* 2002;85(3):345-50.
8. Johanson JF, Rimm A. Optimal nonsurgical treatment of hemorrhoids: a comparative analysis of infrared coagulation, rubber band ligation, and injection sclerotherapy. *Am J Gastroenterol.* 1992 Nov;87(11):1600-6.
9. Rubber Band ligation of hemorrhoid updates Aug 23 –2019. mayo clinic.
10. Khatri AM, Haider G, Hasnain A, Ahmed MU, Wasty WH, Dawani AP. Can RBL replace hemorrhoidectomy as a treatment of choice of 3rd degree hemorrhoid: A review. *PJMD* 2016;5(1):51-53.
11. Lee HH, Spencer RJ, Beart RW Jr. Multiple hemorrhoidal bandings in a single session. *Dis Colon Rectum.* 1994 Jan;37(1):37-41.
12. Caro A, Olona C, Vicente V, Goncalves C, Jimenez A. Grade 3 hemorrhoidal treatment: rubber band ligation or hemorrhoidectomy-A prospective study. *Ambulatory surgery.*2010; 16(3):56-61.
13. Aghaei AM, Hadavi H, Vahedian M, Poorseyedi P. Comparative study of staging rubber band ligation (RBL) and hemorrhoidectomy in the treatment of fourth degree hemorrhoids. *Ann of Colorec resear.*, 2013;1(2):62-66.
14. Khan AN, Khan NA. A prospective study of outcome from rubber band ligation in third degree haemorrhoids. *J Pak Med Assoc.* 2010;60(11):952-5.
15. Yildiz A. Rubber band ligation on internal hemorrhoid treatment as a safe and effective option. *International Journal of Surgery.* 2019;3(3):282-283.
16. Salati SA. Rubber band ligation of internal hemorrhoids: A study. *Singapore J. Sci. Res.*, 2019; 9(1):20-25.
17. Kombozozos VA, Skrekas GJ, Pissiotis CA. Rubber band ligation of symptomatic internal hemorrhoids: results of 500 cases. *Dig Surg.* 2000;17(1):71-6.
18. Alubaidi K, Clarke G, Jamil A, Ghareeb E. Single session, multiple band ligation for hemorrhoids. *Surgical Science*, 2016;7(5):230-234.
19. Nikam V, Deshpande A, Chandorkar I, Sahoo S. A prospective study of efficacy and safety of rubber band ligation in the treatment of Grade II and III hemorrhoids—a western Indian experience. *Journal of Coloproctology.* 2018;38(3):189-193.

---

**Corresponding Author:****Asaad Mohammed Kadhim****Basrah, Iraq****Medicalresearch22@yahoo.com**