

Original Article

The Histopathological and Oxidative Stress Profiles in Japanese Quails (*Coturnix japonica*) Induced by Dietary Lead

Abd AL-Zahra Ali, R^{1*}, Rasmi Huwait, A. J², Issa Abed, R³, Faisal Majeed, M²

1. Department of Pathology and Poultry Disease, Faculty of Veterinary Medicine, University of Basrah, Basrah, Iraq

2. Department of Anatomy and Histology, Faculty of Veterinary Medicine, University of Basrah, Basrah, Iraq

3. Department of Clinical Laboratory Sciences, Faculty of Pharmacy, University of Basrah, Basrah, Iraq

Received 12 July 2022; Accepted 6 August 2022

Corresponding Author: jchr.editor@gmail.com

Abstract

In their native habitat, avians are exposed to external toxicity factors, the most prominent of which are chemical lead compounds that threaten human and animal health. The goal of this investigation was to estimate the adverse effects of lead acetate ($\text{Pb}(\text{CH}_3\text{COO})_2 \cdot (\text{H}_2\text{O})_3$) on the health status of Japanese quail (*Coturnix japonica*). 18 adult male Japanese quails (*Coturnix coturnix japonica*) were employed in this investigation. After two weeks of acclimatization, the birds were randomly divided into three groups: the control group received no Pb^{+2} , the Low Dose Group received 50 mg/kg of Pb^{+2} as lead acetate $\text{Pb}(\text{CH}_3\text{COO})_2 \cdot (\text{H}_2\text{O})_3$ in the diet, and the High Dose Group received 100 mg/kg of Pb^{+2} as lead acetate $\text{Pb}(\text{CH}_3\text{COO})_2 \cdot (\text{H}_2\text{O})_3$ in the diet, for 30 days. Results showed that the Pb bioaccumulation was recorded at the highest values in the liver compared with the kidney, and as expected, the ranges of the lead accumulation were significantly higher in the animals who received 100 mg/kg Pb compared with animals who received 50 mg/kg Pb and the control group. In the high dose group, serum content showed significantly increased levels ($P \leq 0.05$) of aminotransferase enzymes (ALT and AST), glucose, creatinine, and uric acid levels compared to other groups, while antioxidant enzymes (CAT, GSH, and GSH-PX) levels in the liver and kidney were significantly reduced ($P \leq 0.05$). The results showed that the MDA appeared to be significantly increasing ($P \leq 0.05$) in the high dose group compared to the other groups. Compared to the low dose and control groups, the high dosage group produced substantial histological abnormalities in the liver and kidney.

Keywords: Dietary Lead Toxicity, Coturnix Japonica, Liver, Kidney

1. Introduction

Lead (Pb) is a common metal and one of the first human-discovered metals. The distinct characteristics of lead, such as ductility, high malleability, softness, low melting point, and corrosion resistance, have led to its widespread use in various industries, including automobiles, paint, ceramics, and plastics (1). As a result, the presence of free Pb^{+2} ions in biological processes and the inert environment has increased significantly. Lead is considered a hazardous occupational toxin with well-known toxicity effects.

Lead's inability to biodegrade is the main cause of its long-term survival in the environment. Lead poisoning in humans and animals is a big concern worldwide. Lead poisoning is an especially dangerous threat and has the potential to have long-term health consequences, it is known to alter several biological functions, most notably in the central nervous, hematopoietic, hepatic, and renal systems, resulting in significant diseases (2, 3). Oxidative stress is generated by a mismatch between free radical production and the biological system's ability to quickly detoxify reactive

intermediates or repair oxidative stress-induced damages (4). It has been recognized as an important mechanism of lead poisoning. The initiation of oxidative stress occurs as a result of two separate pathways acting concurrently under the impact of lead: first, the formation of ROS such as hydroperoxides (HO_2), singlet oxygen, and hydrogen peroxide (H_2O_2), and second, the depletion of antioxidant reserves (5). Because avians are significantly more resistant to clinical lead poisoning than other mammalian species, lead accumulation in eggs with no apparent clinical sickness in the bird may be significant, posing a potential public health danger in these unmanaged flocks, in addition to the above. Because their biology is well understood, birds are ideal for biomonitoring, they live a relatively long time, and depending on the species, they feed at various levels of the food chain. As a result, birds are one of the most acceptable indicators for determining heavy metal levels in the environment (6). The current study aimed to investigate the histopathological and oxidative stress profiles on male Japanese quail's hepatic and renal systems that experienced dietary lead toxicity.

2. Materials and Methods

2.1. Study Design and Experimental Procedure

Adult male ($n=18$) of Japanese quails (*Coturnix coturnix japonica*) were used in this study. After two weeks of acclimatization, the birds were randomly divided into three groups: the control group received no Pb^{+2} , the Low Dose Group received 50 mg/kg of Pb^{+2} as lead acetate $\text{Pb}(\text{CH}_3\text{COO})_2(\text{H}_2\text{O})_3$ in the diet, and the High Dose Group received 100 mg/kg of Pb^{+2} as lead acetate $\text{Pb}(\text{CH}_3\text{COO})_2(\text{H}_2\text{O})_3$ in the diet, for a period of 30 days. The diet formulation consisted of the following ingredients: Corn (35%), soybean meal (35%), wheat grain (15%), corn gluten (9%), calcium diphosphate (1%), calcium carbonate, DL-methionine, lysine hydrochloride, common salt, L. threonine, and other vitamins and minerals were added in the dietary composition. Birds were housed under standard

controlled conditions ($30\pm 3^\circ\text{C}$), relative humidity (30-45%), and a 12 h light-dark cycle. The birds were given free access to chow and drinking water during the experiment.

2.2. Sample Preparation and Detecting

The lead bioaccumulation in the liver and kidney tissues was determined using the MOOPAM standard method as previously described (ROPME, 1999).

2.3. Biochemical Analyses

The aspartate aminotransferase (AST), alanine aminotransferase (ALT), and glucose were analyzed using commercial kits on a computer process-controlled multi-parametric auto-analyzer (mindray analyzer device BC- 3000 plus made in china). Creatinine (CR) concentrations in the blood were determined using a modified version of Larsen's kinetic Jaffé reaction (7). The method for testing uric acid in plasma was a modification of the uricase method first described by Bulgar and Johns (8) and afterward modified by Kalckar (9). A set of liver and kidney tissue (1 g /15 ml buffer) was homogenized in phosphate buffer (0.1 M, pH 7.4); this homogenate was divided into aliquots to determine the enzyme activity level of CAT, GSH, and GSH-Px. The Cytosolic catalase activity (CAT), (GSH), and glutathione peroxidase (GSH-PX) level in tissue was established by the spectrophotometric method described by Goth (10), (11, 12) respectively. The malondialdehyde (MDA) generated in the tissue indicated how lipids are oxidized to synthesize lipid peroxides as the main product. MDA levels were commonly calculated using the spectrophotometric approach described by (13).

2.3. Histology Study

Each Japanese quail bird was sacrificed after being anesthetized by inhaling vaporized chloroform solvent. Specimens were clarified, and the liver and kidney samples were isolated and fixed in 10% formalin. Then, they were dehydrated in an ethanol-graded series, then cleared in xylene, and incorporated into paraffin blocks, sections were cut

to a thickness of (5 μ m), and all sections were stained with the standard hematoxylin and eosin (H&E) staining technique (14).

2.4. Statistical Analysis

SPSS 18.0 was used to conduct the statistical analysis, the one-way ANOVA was performed, and the statistical tests of Least Significant Difference (LSD) were used, while the significant p-values were less than $P \leq 0.05$.

3. Results

3.1. Lead Bioaccumulation

The concentrations of Pb in the liver and kidney of the bird groups are given in table 1. The higher values ($P \leq 0.05$) were recorded in the High Dose Group during the 30 days of the experiment compared with other groups.

Table 1. Showing levels of lead (μ g/g DW) in liver and kidney tissues in the different experimental groups after the exposure period (30 days)

Organs	Experiment Group		
	Control group	Low Pb group	High Pb group
Liver	NS	1.78*	3.87*
Kidney	NS	0.98*	1.87*

*statistically significant differences ($P \leq 0.05$) in comparison to the control group

3.2. Serum Biochemical Parameters

The ALT, AST, glucose, creatinine, and uric acid values of the blood serum are presented in figure 1 A-E. The ALT level was significantly increased ($P \leq 0.05$) in serum of a low and high Pb group (50 and 100 mg/kg feed), respectively, compared to the control group after 15 and 30 days of experiment time, while AST enzyme level in the low and high Pb dose groups was a higher significant ($P \leq 0.05$) after 30 days in comparison to the control group. The glucose level appeared significantly increase ($P \leq 0.005$) only by a high dose after 15 days of experiment time. The serum

creatinine (CR) was at elevated levels ($P \leq 0.05$) in birds after 15 and 30 days of experiment time in the low and high Pb groups compared to the control group. The uric acid values were increased significantly ($P \leq 0.05$) only in the high Pb group during 15 and 30 days of experiment time. CPK levels appeared to change significantly ($P \leq 0.05$) in birds in low and high Pb groups at 15 and 30 days of experiment time.

3.3. The Oxidative Stress Factors

Figure 2F-M showed the CAT, GSH, GSH-PX, and MDA values analyzed in the liver and kidney tissues. The CAT, GSH, and GSH-PX values in the liver and kidney were significantly lower in the high Pb group (100 mg/ kg feed) than in the other group after 30 days of the experiment. MDA levels in liver and kidney tissue are the highest ($P \leq 0.05$) in the lower and higher Pb groups (50 and 100 mg/ kg feed), respectively, after 30 days of experiment time compared to other times and control groups.

3.4. The Histological Analytic

The control group's liver and kidney histological examination showed typical architecture (Figure 1 and 2A). The Low Dose Group exhibited sinus dilation, hepatic cell hypertrophy, and degeneration, but the high Pb group exhibited severe hepatic histological abnormalities, including hepatic cell hypertrophy, bleeding, acute congestion, sinus dilation, pyknotic hepatic nuclei, and necrosis (Figure 1B, 1C, and 1D). The histological changes in the renal tissue showed slightly markers, represented by glomerulus atrophy, degeneration of renal epithelium cells, and necrosis of renal tubular cells (Figure 2B), while the histological changes were more pronounced higher Pb group, noticed glomerulus atrophy, degeneration, and necrosis of tubular epithelium, hemorrhage, and severe congestion, and infiltration inflammation cells (Figure 2C and 2D).

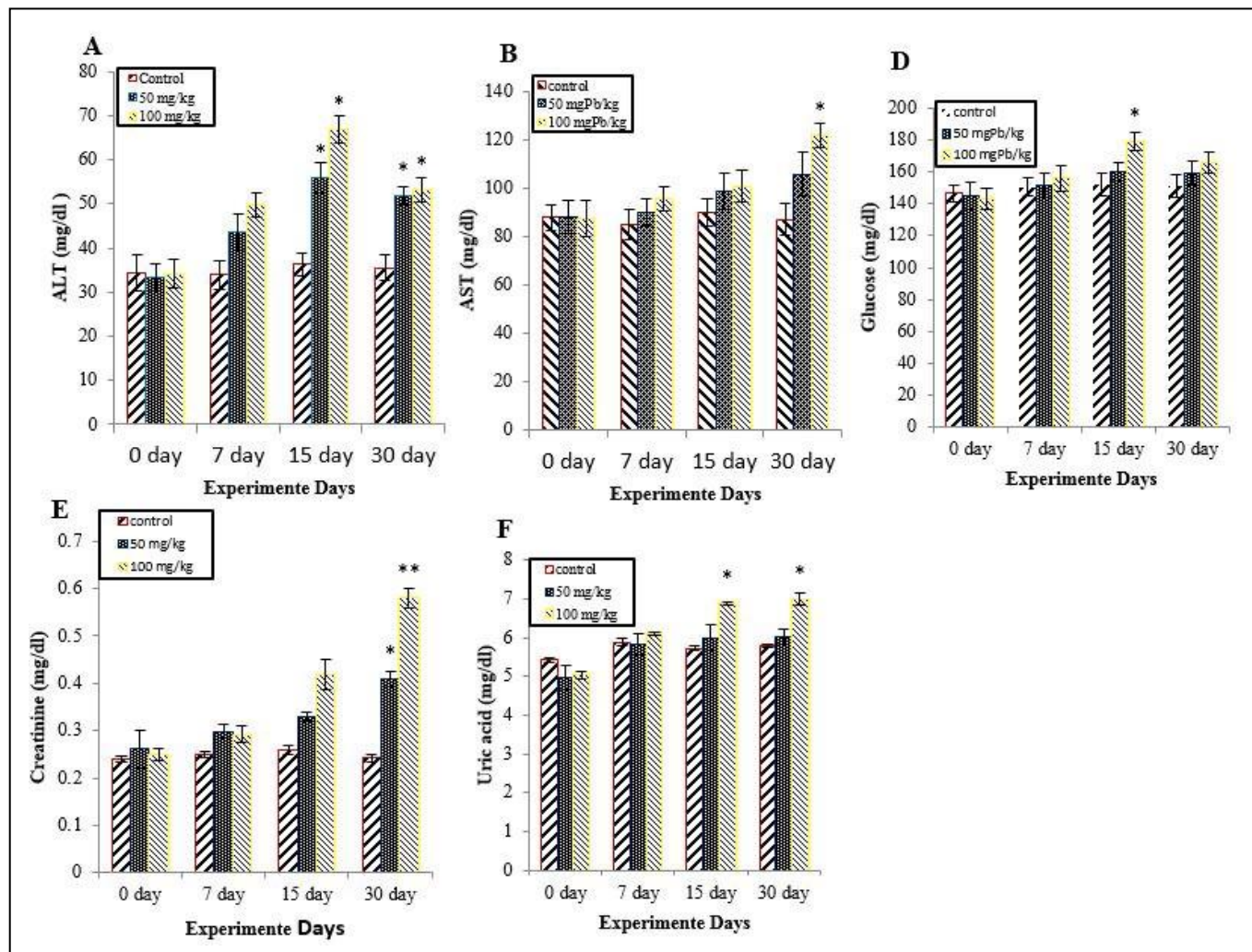


Figure 1. A, B, C, D, and E: Effect of lead toxicity on the biochemical feature of experimental group's serum. The data is shown as the mean (\pm) standard deviation (SD). The asterisks (*) and (**) indicate significances from the control group ($P \leq 0.01$ and $P \leq 0.05$) respectively

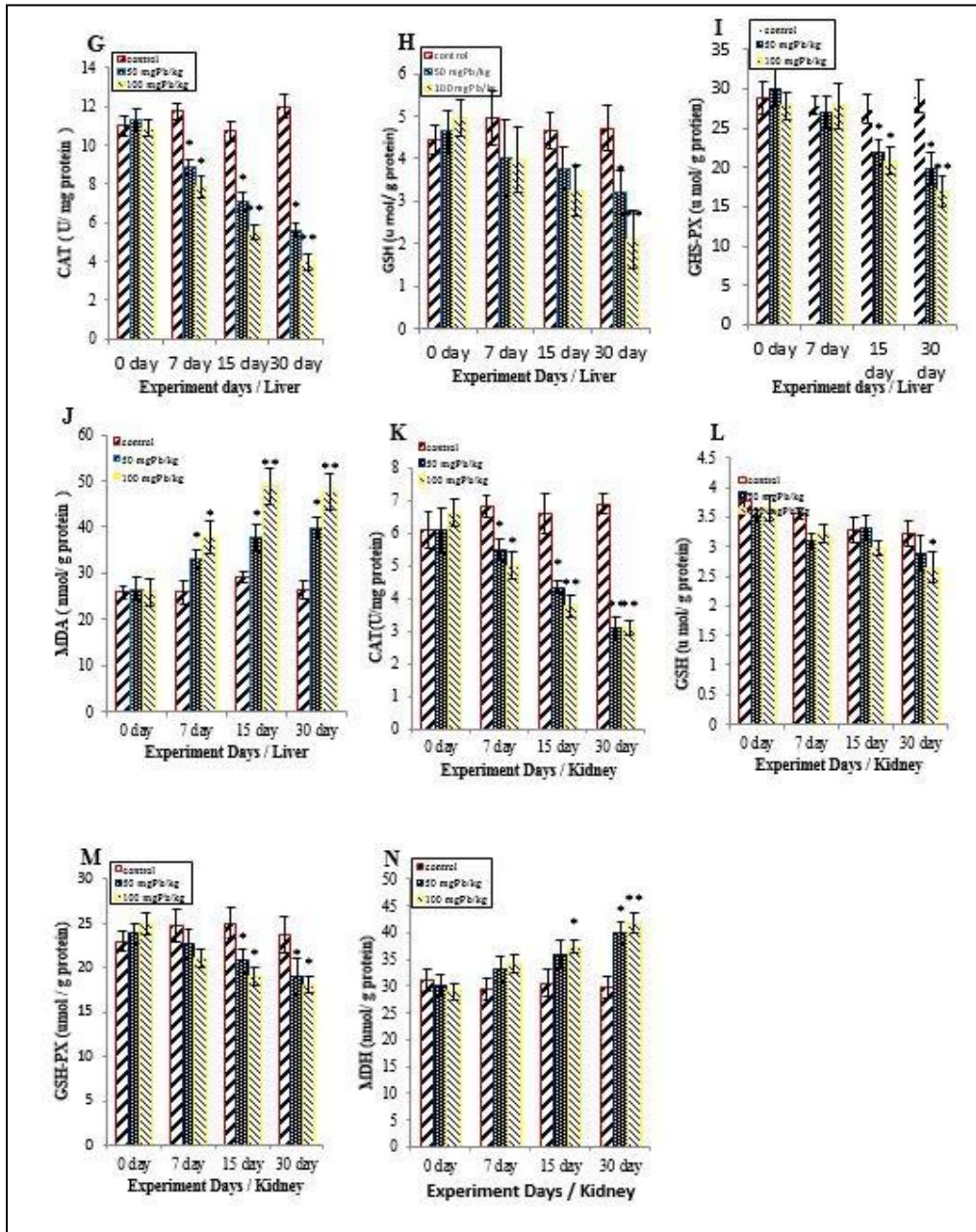


Figure 2. G, H, I, J, K, L, M, and N: Effect of lead toxicity on oxidative stress parameters in Liver and kidney tissues of experimental groups. The data is shown as the mean (±) standard deviation (SD). The asterisks (*) and (***) indicate significances from the control group ($P \leq 0.05$ and $P \leq 0.01$) respectively

4. Discussion

Pb is a hazardous metal that produces oxidative stress by forming reactive oxygen species (ROS), which has been identified as a driving force behind (Pb+2) toxicity (15). According to the results of this study, lead toxicity led to a significant increase ($P \leq 0.05$) in ALT and AST enzyme levels, glucose, creatinine, and uric acid values in the blood serum, whereas the oxidative stress parameters including CAT, GSH, and GSH-PX enzyme in the liver and kidney appeared to decrease significantly ($P \leq 0.05$), and the MDA values increased significantly ($P \leq 0.05$). According to Richardson (16), the higher AST and ALT levels may be due to liver injury, as evidenced by histological alterations such as hepatic degeneration and necrosis, as well as an increase in the number of Kupffer cells in the liver (17). Recent research shows that the variations in enzyme activity are linked to the result of hepatotoxicity (18, 19). Suljevic, Handzic (20) found that lead exposure alters serum biomarkers in *Coturnix japonica* birds, which is congruent with the results of the present study. These alterations in serum analytes have been linked to liver damage caused by metallothionein, a protein generated within the liver with a high affinity for heavy metals, which allows the lead metal to be distributed rapidly in the hepatic tissue resulting in hepatotoxicity (21). The lead toxicity demonstrated a significant values increase in blood glucose, creatinine, and uric acid in *Coturnix japonica* treated with a 0.4 mg/kg diet meal of lead acetate for twenty-one days; These findings are consistent with those of our study, Furthermore, increased glucose levels in the lead groups could be due to a variety of factors, including lead metal poisoning, reduced carbohydrate metabolism, increased cell energy requirement, cellular ATP reduction, or even lower acetyl-cholinesterase levels, while a high creatinine and uric acid level could indicate glomerular filtration and renal disease (22). Pb poisoning has been documented to cause oxidative stress and enhance the generation of reactive oxygen species (ROS), resulting in structural cell damage and lipid peroxidation (23). Many of the body's endogenous

and exogenous antioxidant (enzymatic or non-enzymatic) systems eliminate free radicals. CAT and GSH-Px are enzymatic antioxidants, whereas glutathione (GSH) is a non-enzymatic antioxidant (24). The results of the current study were similar to Kou, Ya (25), which mentioned that the hepatic tissue of quail males and females subjected to lead poisoning, CAT, and GPx activities was dramatically reduced. According to Almasmoum, Refaat (26), the drinking water containing (1g /L) of $Pb_3(OH)_4(CH_3COO)_2$ caused a dramatically increased ($P \leq 0.05$) MDA concentration in the hepatic and renal tissue in the rats. Excess free radicals are created in conditions such as cytotoxic stress, causing histological structural alterations and cell malfunction (27). Usually, the kidney and liver are the main organs for lead deposition in birds (28). This is consistent with our results, which showed that histological alteration in the liver and kidney of the high Pb dose toxicity groups were significantly altered than other groups. Lead may interact with proteins and enzymes in the hepatic and renal interstitial tissue, interfering with the antioxidant defense mechanism and resulting in the generation of reactive oxygen species (ROS), which may mimic the inflammatory response, necrosis, and Pyknotic nuclei of the liver and renal cells (29). Cell necrosis and vacuolization caused by lead toxicity, as shown by the present study, were revealed previously by other investigations such as (30). In fact, from our view, which represents our own opinion, we think that the necrosis of the liver and renal tissue cells caused by prolonged lead exposure may indicate oxidative stress on these cells caused by glutathione deficiency. Lead increases the phagocytic activity of sinusoidal cells by raising the number of Kupffer cells, according to the findings of this study. The injury to the hepatic tissue caused by lead intoxication may be connected with the Kupffer cells hyperplasia, which may constitute a detoxifying defensive mechanism and contribute to hepatic oxidative stress. Increased autophagy in hepatic and renal tissue also aids in removing deposited lead and its metabolites, with lysosomes involved in

intracellular breakdown into small metabolic products (31).

Authors' Contribution

Study concept and design: R. A. A. A.

Acquisition of data: A. J. R. H.

Analysis and interpretation of data: R. I. A.

Drafting of the manuscript: M. F. M.

Critical revision of the manuscript for important intellectual content: R. A. A. A. and A. J. R. H.

Statistical analysis: A. J. R. H.

Administrative, technical, and material support: R. I. A.

Ethics

All the ethical standards were approved by the ethics committee of the University of Basrah, Basrah, Iraq.

Conflict of Interest

The authors declare that they have no conflict of interest.

References

- Abbasi NA, Jaspers VL, Chaudhry MJ, Ali S, Malik RN. Influence of taxa, trophic level, and location on bioaccumulation of toxic metals in bird's feathers: a preliminary biomonitoring study using multiple bird species from Pakistan. *Chemosphere*. 2015;120:527-37.
- Flora SJS, Flora G, Saxena G. Chapter 4 - Environmental occurrence, health effects and management of lead poisoning. In: Casas JS, Sordo J, editors. *Lead*. Amsterdam: Elsevier Science B.V.; 2006. p. 158-228.
- Pearce JM. Burton's line in lead poisoning. *Eur Neurol*. 2007;57(2):118-9.
- Flora SJ. Arsenic-induced oxidative stress and its reversibility. *Free Radic Biol Med*. 2011;51(2):257-81.
- Flora SJS. Nutritional Components Modify Metal Absorption, Toxic Response and Chelation Therapy. *J Nutr Environ Med*. 2002;12(1):53-67.
- Burger J, Gochfeld M. *Habitat, population dynamics, and metal levels in colonial waterbirds: a food chain approach*: CRC Press; 2016.
- Larsen K. Creatinine assay by a reaction-kinetic principle. *Clin Chim Acta*. 1972;41:209-17.
- Bulgar HA, Johns HE. The determination of plasma uric acid. *J Biol Chem*. 1941;140:427.
- Kalckar HM. Differential spectrophotometry of purine compounds by means of specific enzymes; determination of hydroxypurine compounds. *J Biol Chem*. 1947;167(2):429-43.
- Goth L. A simple method for determination of serum catalase activity and revision of reference range. *Clin Chim Acta*. 1991;196(2-3):143-51.
- Lawrence RA, Burk RF. Glutathione peroxidase activity in selenium-deficient rat liver. *Biochem Biophys Res Commun*. 1976;71(4):952-8.
- Sedlak J, Lindsay RH. Estimation of total, protein-bound, and nonprotein sulfhydryl groups in tissue with Ellman's reagent. *Anal Biochem*. 1968;25(1):192-205.
- Placer ZA, Cushman LL, Johnson BC. Estimation of product of lipid peroxidation (malonyl dialdehyde) in biochemical systems. *Anal Biochem*. 1966;16(2):359-64.
- Luna LG. *Manual of histologic staining methods of the Armed Forces Institute of Pathology*. 3rd ed. New York: McGraw-Hill; 1968.
- Qu W, Du GL, Feng B, Shao H. Effects of oxidative stress on blood pressure and electrocardiogram findings in workers with occupational exposure to lead. *J Int Med Res*. 2019;47(6):2461-70.
- Richardson JA. Implications of toxic substances in clinical disorders. In: Harrison G, Lightfoot T, editors. *Clinical Avian Medicine*: Palm Beach, FL: Spix Publishing; 2006. p. 713-5.
- Patra RC, Rautray AK, Swarup D. Oxidative stress in lead and cadmium toxicity and its amelioration. *Vet Med Int*. 2011;2011:457327.
- Alijagic A, Islamagic E, Focak M, Suljevic D. Effects of trivalent and hexavalent dietary chromium on blood biochemical profile in Japanese quails. *Bulg J Vet Med*. 2018;21(4).
- Suljevic D, Islamagic E, Corbic A, Focak M, Filipic F. Chronic cadmium exposure in Japanese quails perturbs serum biochemical parameters and enzyme activity. *Drug Chem Toxicol*. 2020;43(1):37-42.
- Suljevic D, Handzic N, Focak M, Lasic I, Sipovic F, Sulejmanovic J, et al. Lead Exposure Influences Serum Biomarkers, Hepatocyte Survival, Bone Marrow Hematopoiesis, and the Reproductive Cycle in Japanese Quails. *Biol Trace Elem Res*. 2021;199(4):1574-83.
- Wong DL, Merrifield-MacRae ME, Stillman MJ. Lead(II) Binding in Metallothioneins. In: Astrid S, Helmut

- S, Roland KOS, editors. Lead: Its Effects on Environment and Health. Berlin, Boston: De Gruyter; 2017. p. 241-70.
22. Hamidipour F, Pourkhabbaz H, Banaee M, Javanmardi S. Bioaccumulation of Lead in the Tissues of Japanese Quails and Its Effects on Blood Biochemical Factors. *Iran J Toxicol.* 2016;10(2):13-21.
23. Alagawany M, Abd El-Hack ME, Farag MR, Elnesr SS, El-Kholy MS, Saadeldin IM, et al. Dietary supplementation of *Yucca schidigera* extract enhances productive and reproductive performances, blood profile, immune function, and antioxidant status in laying Japanese quails exposed to lead in the diet. *Poult Sci.* 2018;97(9):3126-37.
24. Moussa Z, Judeh ZMA, Ahmed SA. Non-enzymatic exogenous and endogenous antioxidants. In: Das K, Das S, Biradar MS, Bobbarala V, Tata SS, editors. *Free Radical Medicine and Biology.* 2020.
25. Kou H, Ya J, Gao X, Zhao H. The effects of chronic lead exposure on the liver of female Japanese quail (*Coturnix japonica*): Histopathological damages, oxidative stress and AMP-activated protein kinase based lipid metabolism disorder. *Ecotoxicol Environ Saf.* 2020;190:110055.
26. Alasmoum H, Refaat B, Ghaith MM, Almainani RA, Idris S, Ahmad J, et al. Protective effect of Vitamin D3 against lead induced hepatotoxicity, oxidative stress, immunosuppressive and calcium homeostasis disorders in rat. *Environ Toxicol Pharmacol.* 2019;72:103246.
27. Liu HN, Liu Y, Hu LL, Suo YL, Zhang L, Jin F, et al. Effects of dietary supplementation of quercetin on performance, egg quality, cecal microflora populations, and antioxidant status in laying hens. *Poult Sci.* 2014;93(2):347-53.
28. Yuan C, Song HH, Jiang YJ, Azzam MMM, Zhu S, Zou XT. Effects of lead contamination in feed on laying performance, lead retention of organs and eggs, protein metabolism, and hormone levels of laying hens. *J Appl Poult Res.* 2013;22(4):878-84.
29. Johar D, Roth JC, Bay GH, Walker JN, Krocak TJ, Los M. Inflammatory response, reactive oxygen species, programmed (necrotic-like and apoptotic) cell death and cancer. *Rocz Akad Med Bialymst.* 2004;49:31-9.
30. Nehru B, Kaushal S. Alterations in the hepatic enzymes following experimental lead poisoning. *Biol Trace Elem Res.* 1993;38(1):27-34.
31. Neyrinck A. Modulation of Kupffer cell activity: physio-pathological consequences on hepatic metabolism. *Bull Mem Acad R Med Belg.* 2004;159(5-6):358-66.