

# ASSESSMENT OF PAIN AND BLEEDING IN THE FIRST POSTOPERATIVE DAY FOLLOWING COBLATION TONSILLECTOMY

## Rafid Yaseen Jabbar Almaid

MB,ChB, MRCS ENT (Glasgow), DO-HNS (Glasgow), Jordanian Board of Otolaryngology, Head & Neck Surgery. ENT lecturer, Basrah College of Medicine, Basrah, IRAQ.

### Abstract

There are different techniques for tonsillectomy other than traditional such as; cold steel technique, bipolar diathermy, and nowadays the new plasma technology which is known as coblation (controlled ablation) tonsillectomy.

This study aimed to assess the first 24 hours postoperative pain and bleeding after coblation tonsillectomy.

Fifty patients aged between 4-10 years who underwent coblation tonsillectomy were included in this prospective descriptive study, the main indications for tonsillectomy were; recurrent tonsillitis and obstructive sleep apnoea.

The results showed that no bleeding at all within the first 24 hours with significant reduction in feeling of pain after.

In conclusion, coblation tonsillectomy is a promising technique to perform tonsillectomy.

*Key words: tonsillectomy, methods, coblation, bleeding, pain*

### Introduction

The palatine tonsils are considered as a part of Waldeyer's ring and they comprise the largest portion of this ring. Tonsils are located in the lateral wall of the oropharynx between anterior and posterior pillars<sup>1</sup>. At present, the main indications for tonsillectomy are; recurrent tonsillitis and obstructive sleep apnoea (OSA)<sup>2</sup>. Tonsillectomy is the most common surgical procedure in ENT practice; there are various techniques of surgical intervention such as laser tonsillectomy, harmonic scalpel, cryosurgical technique, cold steel technique, electrocautery and the new coblation technology.

Interestingly, the word coblation means controlled ablation; it utilizes a new plasma technology to create precise plasma field energy to ablate the soft tissue with significant low thermal destruction to the nearby soft tissue. Plasma field is created via high density energy within an electrical conductive solution such as normal saline. Using the

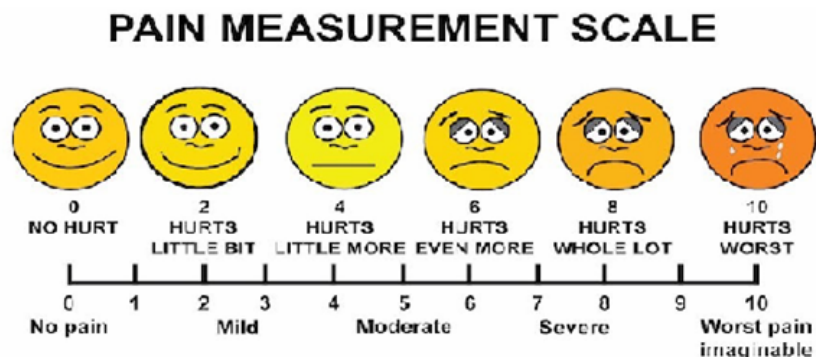
EVAC 70 Wand will result in ablation of only 100-200 micrometers thickness around the electrode. Nowadays, the coblation technology is also used for adenoidectomy, inferior turbinate surgeries, laryngeal lesions, in addition to sinus and snoring procedures<sup>3</sup>.

### Patients and methods

This research is a cross-sectional prospective descriptive study which was performed from March 2018 till March 2019. During this time, 50 patients who were 4-10 years old were assessed postoperatively for pain and bleeding. All patients were presented to author private clinic in Basrah, Iraq with recurrent tonsillitis and OSA.

Data were recorded on a specifically designed paper which included; name, age and gender of the patients. In addition, the assessment of the patient's pain by a measurement scale which depends on facial expressions as shown in figure 1.

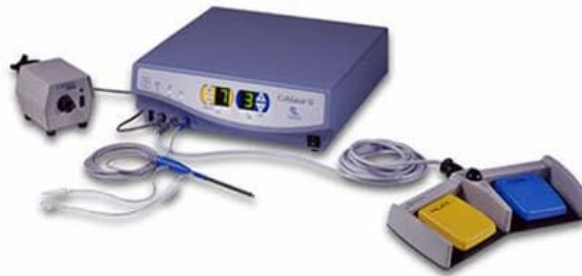Figure 1:



Furthermore, the paper assessed pain and bleeding in the two different time scales; the first assessment was done in the first 8 hours and the second one at the end of day.

Regarding the procedure, a Smith & Nephew Coblator II surgery system was used to perform the operation (figure 2).

Figure 2: Smith &amp; Nephew Coblator II surgery system



Under general anesthesia with endotracheal intubation and the patient in supine position, Boyle Davis mouth gag was inserted and Darffin biopids were applied. Tonsillar clip was used to retract the tonsil medially then a tonsillar pillar incision was created by coblator wand. After that, dissection of the tonsil was progressed toward the tonsillar capsule with separation of the tonsil superiorly towards the inferior pole. Finally, hemostasis was completed by coblator wand coagulation( figures 3-5).

Figure 3: Making an incision by coblator wand.

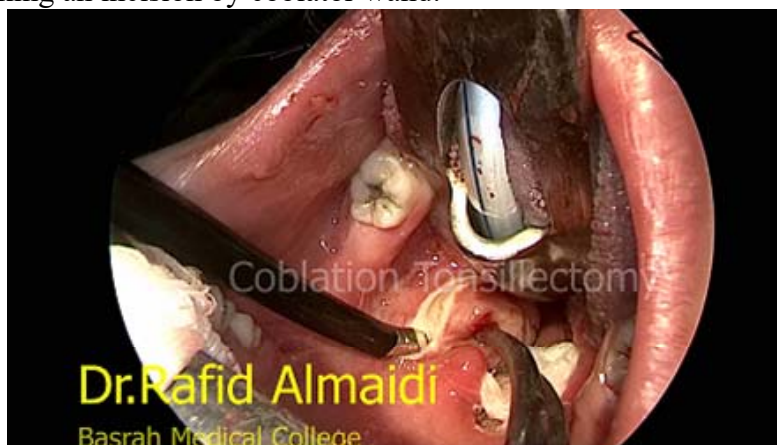

Figure 4: Dissection of the tonsil from the lateral wall of the oropharynx.

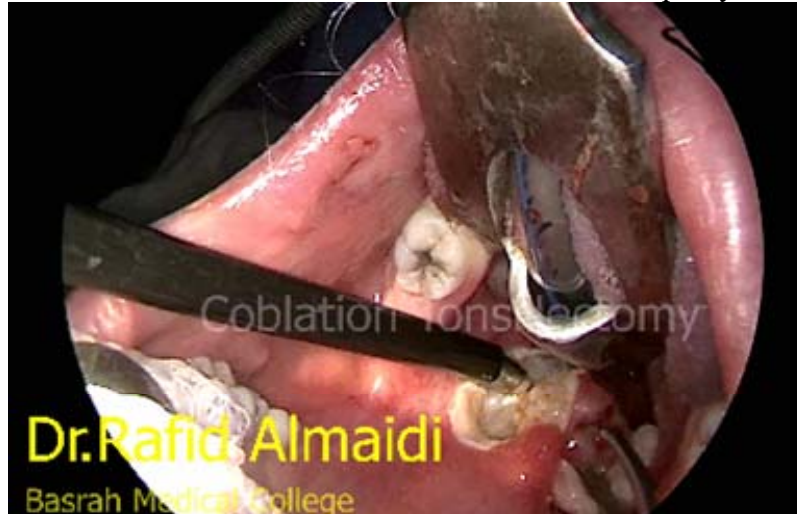
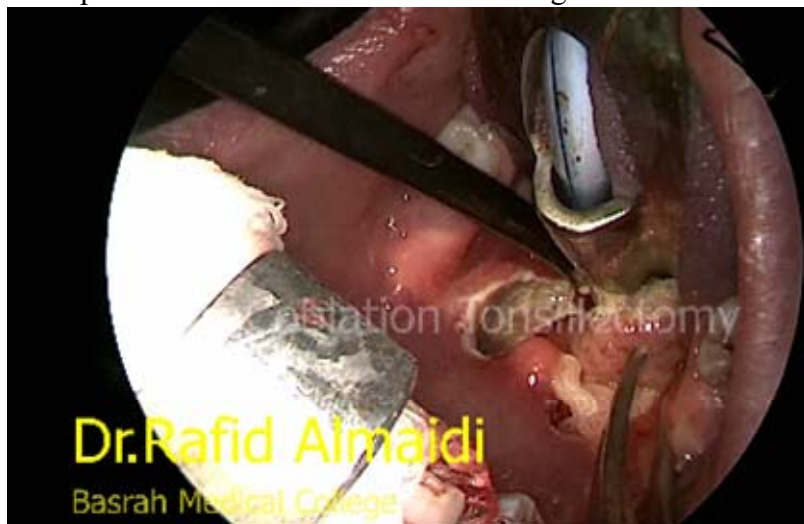
Figure 5: The complete excision of the tonsil without ligation.



**Results**

Fifty patients participated in this study; they were 22 males and 28 females, their

age ranged from 4-10 years with an average of 7 years and a standard deviation of 1.9.

**Table I: Comparison of the pain score in the first 8 hours and after 16 hours.**

At 8 hours (mean±SD)	After 16 hours (mean±SD)	P value
3.00 ±1.11	3.35±1.2	0.254

Wilcoxon Signed Rank

According to the table I, the patients post coblation tonsillectomy experienced pain in a range of 3.00±1.1 which corresponds to mild to early moderate in the first 8 hours while the pain does not relatively increased after 24 hours to reach to 3.35±1.2 which also corresponds to mild to moderate score .

Ultimately, there is no significant statistical difference observed between the average pain scale at 8 hours and after 16 hours postoperatively.

In addition, all patients included in this study didn't have post tonsillectomy bleeding in the 1st 24 hours.

## Discussion

Recently, the main absolute indications for tonsillectomy are; recurrent acute tonsillitis and obstructive tonsillar hyperplasia. The acute attack of tonsillitis usually characterized by severe sore throat, fever (oral temperature of at least 38.3C), dysphagia, and generalized systemic upset for at least 5 days. The recurrent tonsillitis should be 4–7 episodes of acute tonsillitis in 1 year or 5 attacks for 2 consecutive years or 3 episodes per year in 3 consecutive years<sup>4</sup>.

The other concern in the obstructive tonsillar hyperplasia is; obstructive sleep apnoea, failure to thrive, or congestive cardiac failure from Cor Pulmonale<sup>5</sup>.

There are many techniques for tonsillectomy such as cold steel dissection, bipolar diathermy or combination of the previous techniques. Generally, the cold steel technique is accompanied by less pain but more bleeding during surgery with significant risk of primary haemorrhage while bipolar diathermy dissection associated with less intraoperative bleeding but it is a painful postoperatively with the increase the chance of secondary haemorrhage. In the other hand, the coblation tonsillectomy in children is near a bloodless surgery with little pain after surgery as well as there is still a risk for secondary bleeding but the experienced users of coblation technology in UK

confirms the safety of coblation surgery for tonsillectomy regarding the bleeding issue and with less postoperative pain<sup>6</sup>.

A significant clinical point related to tonsillectomy is postoperative bleeding which is either primary (within 1st 24 hours mainly 1st 8 hours) and is usually due to inadequate hemostasis at the time of surgery or by the slipping of ligatures (cold steel technique) or secondary bleeding, this occurs usually 5-10 days after the surgery and the usual cause is infection because of inadequate swallowing<sup>7</sup>. In general, post-operative pain in coblation technology is less significant especially in the first three days after surgery<sup>8</sup>.

Finally, this study found no primary bleeding which confirms the international studies and safety guidelines. In addition, pain assessment using child face simile scale is very effective in this purpose which indicates the pain level that was mild to early moderate, this helps the child to start oral feeding after the operation effectively and also the early postoperative recovery with reduction of hospitalization time of and early return back to school.

Conclusion: The coblation tonsillectomy is bloodless procedure if performed by experienced surgeon with less immediate post-operative pain and therefore this technique is recommended to school aged children.

## References:

1. Yelizaveta Shnyder, Kelvin C. Lee, Joseph M. Brenstien. management of Adenotonsillar diseases, Chapter 20 , P.340 , Current diagnosis and treatment of otolaryngology (2008).
2. PL Dhingra & Shruti Dhingra, Diseases of ear ,nose and throat, & head and neck surgery, tonsillectomy ,Chapter 93 , P.428 , 2014 .
3. Exclusively coblation plasma technology Smith & Nephew coblation plasma technology (brochure).
4. Surgical indications of tonsillectomy, clinical and operative methods in ENT and head and neck surgery, Produl Hazarika, Dipak Ranjan Nayak, (2005), P.164 .
5. Surgical indications of tonsillectomy , clinical and operative methods in ENT and head and neck surgery, Produl Hazarika, Dipak Ranjan Nayak (2005), P.165.
6. Tonsils and adenoids, Logan Turners, 2016, P.537.
7. Tonsillectomy, Diseases of the ear, nose and throat, Hall&colmans, 2001, P.180.
8. Post-operative pain following coblation tonsillectomy, randomized clinical trial, Nastasha Polites, ANZ Journal of surgery, Volume 76, Issue 4, 2006.