

## A case series on bullous pemphigoid like scabies: A diagnostic challenge

Dooha K Alhamdi<sup>1</sup>, Khalil I Alhamdi<sup>2</sup>

From <sup>1</sup>Lecturer, Consultant Dermatologist, Department of Medicine, College of Medicine, University of Basra, Basra, Iraq, <sup>2</sup>Professor, Consultant Dermatologist Head, Department of Dermatology, Basra Medical College, University of Basra, Basra, Iraq

### ABSTRACT

Scabies is an ectoparasitic infection caused by *Sarcoptes scabiei* var. *hominis* in humans. Accurate figures of the prevalence of scabies are difficult to obtain, it seems to affect around 100–300 million people worldwide. Scabies is usually transmitted by close intimate physical contacts, such as the sharing of a bed or prolonged hand-holding. Scabies mites survive for 24–36 h outside of human bodies. Itching is the most obvious manifestation of scabies, which is usually sparing the face in adult classic scabies. The onset occurs 3–4 weeks after acquiring the infection. Bullous pemphigoid-like scabies is one of the atypical and rare forms of scabies that may be overlooked and mismanaged, where only 44 cases worldwide with this mode of presentation were reported. Here, we reported a series of three cases of bullous pemphigoid-like scabies, which presented with nocturnal itching and vesiculobullous lesions that are to the best of our knowledge the first cases reported in our country.

**Key words:** Atypical, Bullous pemphigoid, Histopathology, Scabies

Scabies is an ectoparasitic infection caused by *Sarcoptes scabiei* var. *hominis* in humans. Copulation occurs in a small burrow dogged by the female. The burrow is inclined downwards into the epidermis and is not limited to the stratum corneum. The lifespan of the mite is about 4–6 weeks in which each female lays around 40–50 eggs during its lifespan. Eggs hatch after 3–4 days into larvae. The larvae mature into adult mites in about 4 days [1]. Adult females can survive in the body of a host for up to a month. The mites show a preference for specific sites in which to dig their burrows and avoid areas with a high number of pilosebaceous follicles [2]. In the common form of scabies, the average number of adult female mites on an individual is about 12 [1]. Accurate figures of the prevalence of scabies are difficult to obtain, it seems to affect around 100–300 million people worldwide [1].

To the best of our knowledge, 44 cases of bullous pemphigoid-like scabies had been reported worldwide. Here, we present a case series of three cases of atypical scabies that mimic bullous pemphigoid clinically and histologically that may be overlooked and mismanaged which were the first cases reported in our country to increase clinical awareness of this rare atypical presentation of common skin diseases.

### CASE SERIES

#### Case 1

An 81-year-old male patient presented with generalized nocturnal itching with vesiculobullous lesions located mainly at the finger webs and sides of the fingers for 8 weeks duration. The bullae were tense, itchy, and arising from apparently normal skin. Some of the bullae were ruptured leaving a crusted surface. On the trunk and proximal parts of extremities, the lesions were more or less annular and oval itchy, erythematous urticated lesions with moist crusted surfaces. Few scattered tense bullae were seen with no mucus membrane and face involvement (Fig. 1). The family history was negative, the patient had no systemic diseases, and he was on no treatments. Nikolsky and Hansen signs were negative. He was diagnosed clinically as bullous pemphigoid with poor unremarkable response to systemic and topical steroids. Relevant laboratory and serological investigations revealed no evidence of any systemic diseases.

Histopathological examination of biopsied intact blister showed sub epidermal cleft with lymphocytic and moderate eosinophil cellular perivascular infiltrates (Fig. 2). The suspicion of bullous scabies was considered, for which systemic ivermectin (12 mg once weekly for 2 successive weeks) was given and topical ivermectin was applied to the whole body once weekly for 2 weeks with a drying agent along with a systemic antihistamine.

**Correspondence to:** Dooha K Alhamdi, Department of Medicine, Basra Medical College, Albradhia, Basra, Iraq. doha.ismail@uobasrah.edu.iq

© 2022 Creative Commons Attribution-NonCommercial 4.0 International License (CC BY-NC-ND 4.0).


Access this article online	
Received - 10 June 2022 Initial Review - 27 June 2022 Accepted - 15 July 2022	Quick Response code 
DOI: ***	

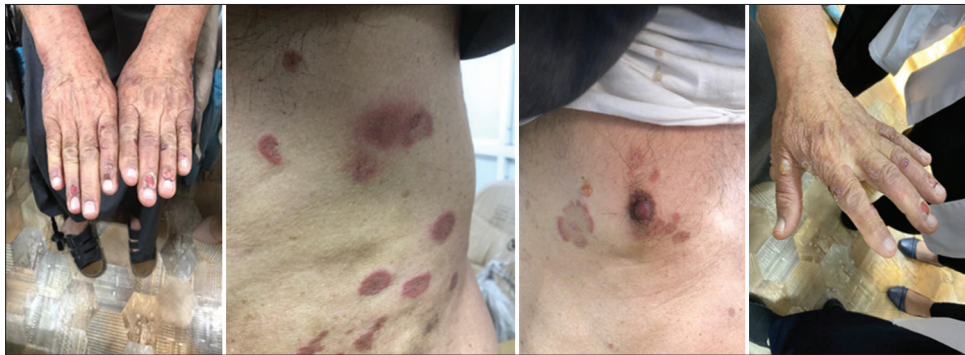

Figure 1: Images of the patient before treatment (Case 1)

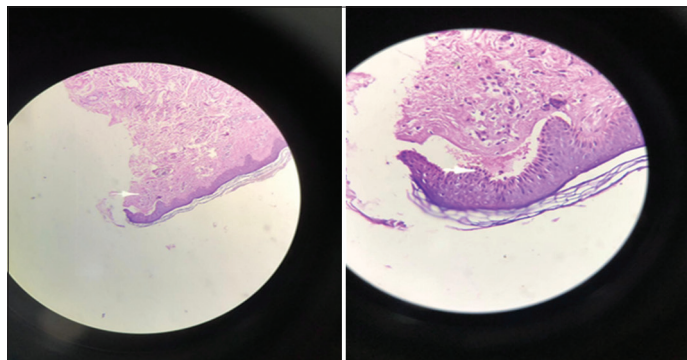


Figure 2: Histopathological examination revealed subepidermal cleft with lympho eosinophilic infiltrate (Case 1)

On re-examination 2 weeks later, no more itching was reported with complete resolution of bullous and non-bullous skin lesions leaving post-inflammatory hyperpigmentation (Fig. 3).

### Case 2

A 73-year-old female patient presented with intensely itchy tense bullae located at the hands, particularly at or nearby the finger webs with no mucus membrane and face involvement for the last 6 weeks (Fig. 4). Itching is more severe at night. She was diagnosed clinically as localized bullous pemphigoid for which she was given oral systemic steroid (40 mg of prednisolone daily) along with potassium permanganate as a drying agent with topical steroid creams. Bullae resolved, but itching persists and once the steroid was stopped, bullae recurred at the same sites with the appearance of new ones. Family history of nocturnal itching without vesiculobullous lesions is positive among other family members. Nikolsky and Hansen signs were negative. History, clinical examination, relevant laboratory, and serological investigations revealed no evidence of any systemic diseases apart from hypertension treated by bisoprolol. Skin biopsy from intact bullae showed sub epidermal cleft with perivascular lymphocytic and eosinophilic infiltrates. The epidermis was normal.

The history and clinical presentation raised the possibility of bullous scabies, for which she was given systemic ivermectin (12 mg once weekly for two successive weeks) with topical potassium permanganate and topical ivermectin once weekly for the whole body for 2 weeks. After 2 weeks, no more lesions were seen with the resolution of all lesions without itching.

### Case 3

A 43-year-old female patient presented with localized itchy erythematous excoriated skin lesions with tense vesiculobullous involving mainly the sides of fingers for four weeks duration with no mucus membrane and face involvement (Fig. 5a). The itching was more severe at night and did not respond to topical and systemic steroids and systemic antihistamines. On clinical basis, the patient was considered a case of localized bullous pemphigoid. Family history was positive among two other family members but without vesiculobullous lesions. The patient neither complained of any systemic diseases nor taking any drugs. Nikolsky and Hansen signs were negative. Skin biopsy was taken from one of the bullae where histopathological examination showed sub epidermal cleft with the admixture of lymphocytic and eosinophilic infiltrates. She was treated as a case of bullous scabies with topical and systemic ivermectin along with systemic antihistamine and topical drying agents. On follow-up 2 weeks later, the patient had no more itching. Skin examination revealed healing of bullae and other skin lesions (Fig. 5b).

### DISCUSSION

Scabies is a common infectious skin disease affecting people of low socioeconomic status residing in overcrowded places and institutions like prisons. It is usually transmitted by close intimate physical contacts, such as the sharing of a bed or prolonged hand-holding. Scabies mites survive for 24–36 h at room conditions (21°C and 40–80% relative humidity) outside of the human body [1]. Allergic sensitivity (both immediate and delayed-type hypersensitivity reported to be involved) to the mite or its products seems to play an important role in determining the development of all the lesions except burrows, and in producing pruritus [1]. Susceptibility or resistance to *S. scabiei* infection shows a degree of genetic predisposition. This is postulated to correlate susceptibility to severe disease with the dominance of an IgE-driven Th2 response or resistance to the infestation by an interferon- $\gamma$  dominated Th1 response [3].

Itching is the most obvious manifestation of scabies, which usually spares the face in adult classic scabies. It is generally worst when the patient is warm and at night. The onset occurs 3–4 weeks after acquiring the infection, but when reinfestation, the symptom

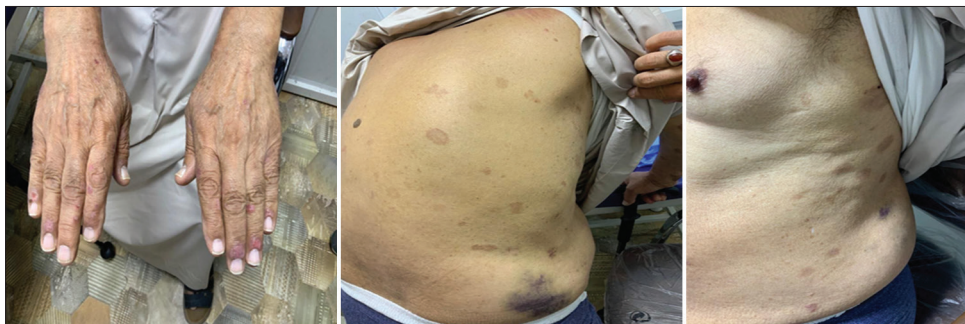

Figure 3: Images of the patient after treatment (Case 1)

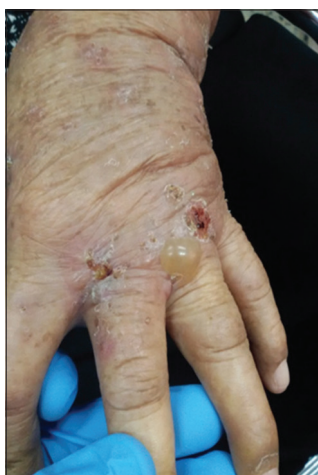

Figure 4: Image of the patient before treatment (Case 2)

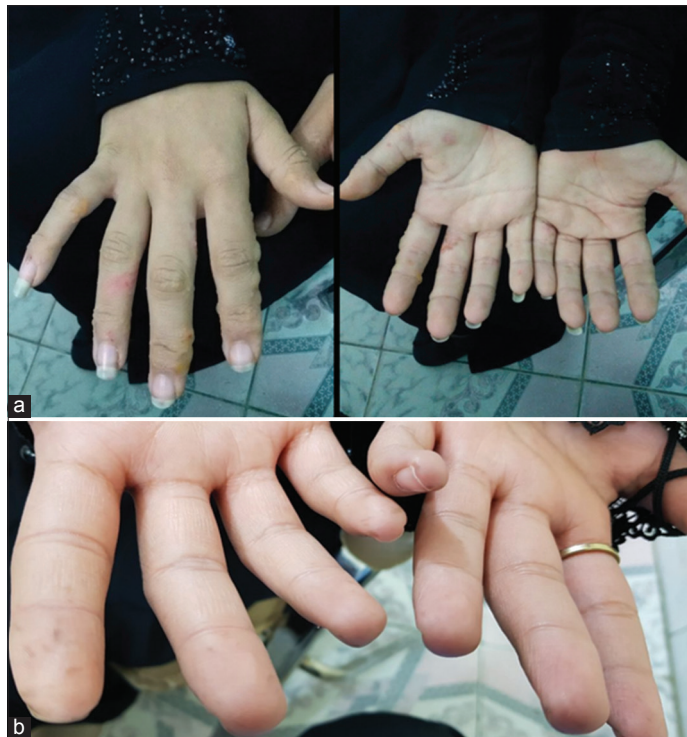

Figure 5: Images of the patient. (a) Before treatment; and (b) after treatment (Case 3)

occurs immediately [4]. There are many atypical forms of scabies that are very difficult to diagnose [5]. These atypical forms include scabies of the scalp, nodular scabies, scabies mimicking

immunologically mediated diseases such as bullous pemphigoid, urticaria, chronic lymphocytic leukemia, B-cell lymphoma with monoclonal infiltrate, CD30+ lymphoid proliferations, necrotizing vasculitis, and lupus erythematosus [5].

There are several studies that suggest a seasonal variation in scabies [1]. They explained this variation by the “herd immunity” theory which suggests that after an epidemic of scabies, there is a degree of immunity so that there will be no further epidemic until a new, susceptible population has arisen [1]. All age groups and both sex are equally affected, but it becomes more frequent in the elderly in residential and nursing home environments [1]. All ethnic groups are susceptible, but some studies suggested that black Americans appeared to be less susceptible [1], this difference is probably related to customs and social factors rather than inherent susceptibility.

Bullous scabies is a rare mode of presentation worldwide where only 44 cases were reported in the literature. It is said to affect males more than females [6], the majority of them are elderly, distributed mainly on the extremities and the trunk [6]. In this report, bullae were distributed mainly at the hands, finger webs, sides of the fingers, and the trunk in all three cases, which is consistent with that reported in other studies. Bullae may develop at the same time or after the appearance of scabetic lesions [7-9]. The age of the reported cases ranged between 45 and 81 years, which is similar to that reported by other studies. The exact mechanism of bullous development in a scabetic patient is not well known, although many possible explanations were suggested. Either it is attributed to superadded secondary bacterial infection by *Staphylococcus aureus* or it may result from direct trauma or the release of lytic enzymes by the scabetic mites that may change the basement membrane zone with subsequent production of autoimmune antibodies with subsequent release of cytokines and other inflammatory mediators [10]. In addition, it is reported that mite proteins may cross-react with basement membrane antigens resulting in autoimmune antibodies that activate immunoreaction with subsequent cleft formation and production of bullae [10]. Bornhovd and others believed that the persistence of scabies might result in a specific immune response that activate T-helper 2 cells causing an increase in interleukin 5 and eosinophilia that led to bullous formation [10].

The histopathological examination showed sub epidermal cleft with an admixture of lymphocytes and eosinophils inflammatory cells, which simulate that of bullous pemphigoid. Although direct

and indirect immunofluorescence was not done for our patients because these investigations, unfortunately, are not available in our locality we believed that failure of response to systemic and topical steroids among our patients, which are the cornerstone therapeutic option for bullous pemphigoid, and the remarkable improvement in itching and the resolution of all vesiculobullous and other scabetic lesions within 2 weeks treatment of antiscabetic drugs confirmed the diagnosis of bullous scabies.

### CONCLUSION

Bullous scabies should be considered in any patient with vesiculobullous lesions mostly affecting the extremities and trunk, particularly those not responding to systemic and topical steroids even when the histopathological examination revealed bullous pemphigoid such as like features and antiscabetic therapeutic trial is advisable.

### ACKNOWLEDGMENT

We would like to thank all patients who agreed to participate in this case report work. We also greatly thankful to the scientific, ethical approval committee and the institutional research board who licensed our project and gave the green light to complete the work.

### REFERENCES

1. Gentiane M, Pascal D, Olivier C. Arthropods. In: Christopher E, Jonathan B, Tanya B, Robert C, Daniel C, editors. Rook's Textbook of Dermatology. 9<sup>th</sup> ed. Hoboken, New Jersey: Wiley Blackwell; 2016. p. 1-55.
2. Burgess I. Sarcoptes scabiei and scabies. Adv Parasitol 1994;33:235-92.
3. Walton SF. The immunology of susceptibility and resistance to scabies. Parasite Immunol 2010;32:532-40.
4. Chosidow O. Scabies and pediculosis. Lancet 2000;355:819-26.
5. Chosidow O. Clinical practices. Scabies. N Engl J Med 2006;354:1718-27.
6. Luo DQ, Huang MX, Liu JH, Tang W, Zhao K, Sarkar R. Bullous scabies. Am J Trop Med Hyg 2016;95:689-93.
7. Said S, Jay S, Kang J, Liem WH, Jensen JL, Jeffes EW. III Localized bullous scabies: Uncommon presentation of scabies. Am J Dermatopathol 1993;15:590-3.
8. Slawsky LD, Maroon M, Tyler WB, Miller OF. Association of scabies with a bullous pemphigoid-like eruption. J Am Acad Dermatol 1996;34:878-9.
9. Konishi N, Suzuki K, Tokura Y, Hashimoto T, Takigawa M. Bullous eruption associated with scabies: Evidence for scabetic induction of true bullous pemphigoid. Acta Derm Venereol 2000;80:281-3.
10. Ansarin H, Jalali MH, Mazloomi S, Soltani-Arabshahi R, Setarehshenas R. Scabies presenting with bullous pemphigoid-like lesions. Dermatol Online J 2006;12:19.

*Funding: None; Conflicts of Interest: None Stated.*

**How to cite this article:** Alhamdi DK, Khalil I. Alhamdi KI. A Case Series on Bullous Pemphigoid like Scabies: A Diagnostic Challenge. Indian J Case Reports. 2022; July 22 [Epub ahead of print].