

INDUCED THE C₂₂H₁₉CL₂NO₃ CYPERMETHYREIEN PESTICIDES ON HISTOLOGICAL ALTERNATION FOR THE LIVER OF ALBINO MICE (MUS MUSCULUS)

Saphia Al –Aitte¹, Maysoon Hussein Zain², Alaa S.Kathim³

^{1,2}Health and Medical

Technical College,

Southern Technical University,

Community Health Department

³College of Education of Al OQurba /

University of Basra, biology dept.

ABSTRACT

Purpose: The aim of the study is to clarify the dangerous of Pyrethriod chemical pesticides, cypermethyreien ,as it had clear effects on the liver cells of albino mice, so it use in homes to kill insects and in garden may cause harm to humans, so mice were a vital indicator of its impact on human health

Method: Preparation of hepatic sections the liver is removed, the liver is washed to remove the blood for several times then it is passed with a series of 70% ethyl alcohol And complete the method of tissue sections.

Result: All sections were examined under microscope, where they indicated alternation in low and high doses. Included hepatic sinus, necrosis, enlargement of hepatocyte, dilation of the central vein and venous congestion. The hepatic portal and show vacuolar degeneration, which means that the changes are sever and an indication of the toxicity of pesticide , and this differences appears to be significant compared with control

Conclusion: The study showed the effect of the toxicity of pesticide on the hepatocyte .The effects were significant in damages according to the

Key word: Albino mice , histological changes , pesticide , toxicity , C₂₂H₁₉Cl₂NO₃

I. INTRODUCTION:-

The term pesticides is used for chemical compounds that control agricultural pests, which agricultural groups are exposed to during their infection with various types of insects ,worms, and fungi and control them, as the use of pesticides increase the efficiency of the soil, increase the agricultural yield and meet the growing needs of the population(1).Therefore, agricultural technology is working on the Optimal use of these pesticides ,as the main targets for them is the targeted pests ,but it goes beyond that to other types of non-target species such as fish and birds that drink polluted water ,as pesticides leak from field and forms into riverbed, affecting the fish and their environment in which the live ,in addition to that they contribute to the elimination of mice and rats or using a method spraying the pesticides on the leaves of plant on which mice and rats live and feed as a result ,these pesticides accumulate on the surface of leaves (2). The concept of pesticides toxicity is called the ability of the pesticides toxicity can cause damage .The toxicity of preyrethyriod pesticides that are considered harmful compounds to human and animals , as cypermethyreien is used increasing controlling household garden pests, the toxicity of cypermethyreien is transmitted through the food chain through the biological transmission (3), and this what happens to rats , so it is distinguished by its ability to accumulate quickly ,so the effectiveness of this accumulation is estimated to cause pathological damage to the tissues of the animal, thus the toxic changes of this pesticide cypermethyreien on albino mice have been studied as an indicator of the human health effects in short-term or long-term exposure ,that extend its damage on various body system. Several authors have studies

many of the physiological changes to which albino mice are exposed to various types of pesticides. including the pesticide cypermethyrien. The effect on blood values (4.5.6) was discussed . (7,8) indicated in his work the impact of pesticide on the immunity of mice, as shown by a study on the Biochemical values during exposure to mice to doses of pesticide (9) on the Reproductive system changes during exposure to mice to doses of pesticide Lufenuron (10.11) .Several authors have indicated by many studies on Histopathological differences of organs of laboratory Albino mice exposed to different pesticides .12,13). So the current study aim to investigated the hazard of cypermethrin on pathohistological alternations of liver organ of both sexes , males and females exposed to sub lethal doses , as many researches didn't address to study the histological changes of both sexes to gather of its importance in comparing between them

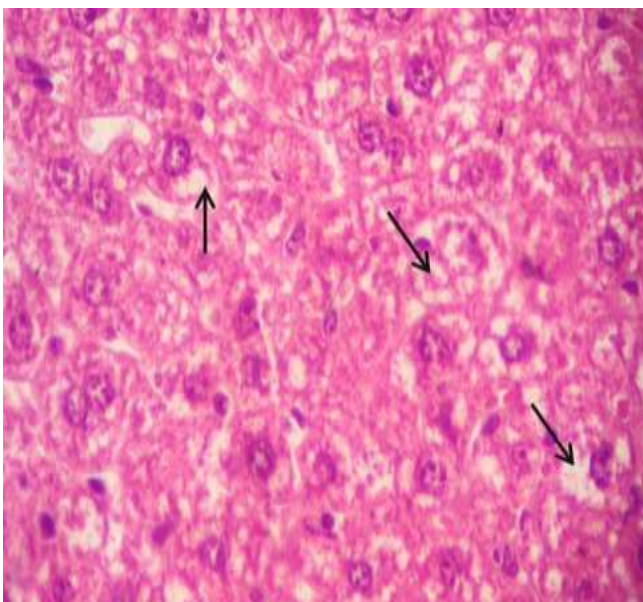
II. METHOD

Tests animals:- samples from males and females of Albino mice were brought to animal house by buying them from the center of animal house in the department of biology .The experimental was carried out in the animal house of the department of community health Technologies of Southern Technical University , where the samples accliminazied under laboratory conditions at temperature (25±2)and 12hdaylight cycle .They were adept for a period 2 weeks in special cejats and feed with and water was a available libitum .

Experimental Test :-The samples of Albino mice were separated specialized cejats with grouping each one containing (6) samples with (5) replicates (n=30) for both sexes ..Samples were treated with sub lethal doses s of cypermethrin C₂₂H₁₉Cl₂NO₃ insecticides (2.5mg/kg and 4.5mg/kg) for 5 weeks of exposure. The dose is given cardiac intraperitoneally injections 2-3 times per week, the control group was untreated with doses of pesticide, but these doses were given as distilled water

Preparation of hepatic sections:- After the exposure period is over , the samples are anesthetized and in a dissection dish .During the autopsy the liver is removed , the liver is washed to remove the blood for several times then it is passed with a series of 70% ethyl alcohol .And complete the method of tissue sections according to the method of (14).

Results The results of the microscopic examination of sections of the liver of mice of the control group showed that it consists of hexagonal lobules, and is centered in each lobule and a central vein, as ,of around which hepatocytes are Arranged in the form of strips in a radial system . These strips are separated from each other with small areas that represent the sinusoids and lined with a single non-continuous layer of epithelial cells. Kupffer cells were also diagnosed in the walls of the sinusoids (Figure 1).



(1) section in the liver of mice in the control group showing the structure of liver. Note the Kupffer cells (arrows), hepatic sinusoidal cells (arrowheads), and the 400X (H&E)(Star (.central vein

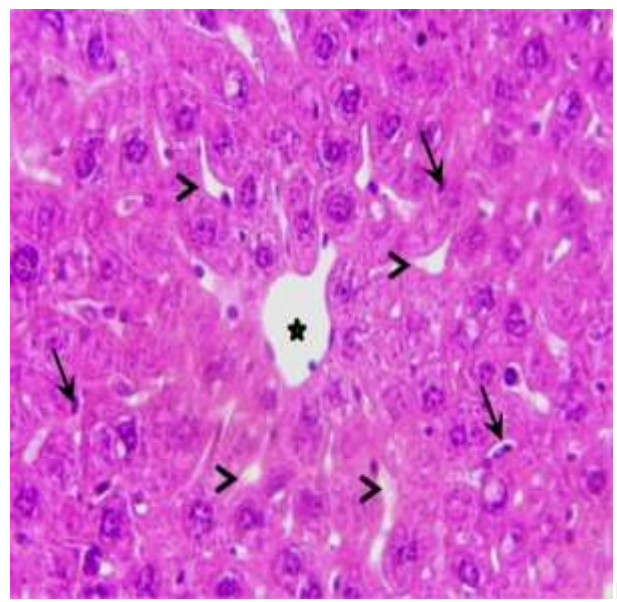


Figure (1) section in the liver of mice in the control group showing structure of the liver. Note the Kupffer cells (arrows), hepatic sinusoidal cells (arrowheads), and the 400X (H&E)(Star (.central vein

Low dose group liver 2.5 mg / kg:

The results of the histological examination of the liver of mice treated with the low dose of Alpha-Cypermethyrien showed slight changes compared to the high dose group represented by the occurrence of vacuole degeneration in the cytoplasm of some hepatocytes Fig. (2) follicular congestion, and the occurrence of fibrosis (3 and 4). And the increase of Kupffer cells (Fig. 4), a lobule in the nuclei of some hepatocytes, the emergence of vacuoles in the cytoplasm of some hepatocytes (Fig. 5), enlargement of hepatocytes (Fig. 5 and 7), expansion of the central vein (Fig.Centr (Figure 7).Changes from vascular degeneration in the cytoplasm and hypertrophy in hepatocytes .

High dose group liver of 4.75 mg / kg:

Histological sections of the livers of animals treated with the high dose showed pathological changes compared to the control group, and these changes were represented by the occurrence of congestion of blood congestion (Fig. 8). Cases of vacuolation were diagnosed in the cytoplasm of hepatocytes (Figures 9, 10, 11 and 12), and these hepatocytes suffered from large areas of necrosis (shapes), as necrosis of some hepatocytes was observed spreading between the portal area with degenerative cells and the hepatocytes passed Those who suffer necrosis with a set of changes at the level of the nucleus and cytoplasm ending with the death of cells and it seems that these changes begin with vacuolation in the cytoplasm of the cell (figure), while in others it has been observed that the shape of the nuclei changes and appears irregular in shape shape (Figures 13 and 14) or looks like a lobule (Fig. 15) Then the cytoplasm has completely dissolved and the nucleus appears to swim in the middle of the cell or one of its sides, and during that the nuclear material of the nucleus decays from the middle towards the nuclear envelope, then part of the membrane disintegrates .plasma necrosis events ended with the complete dissolution of the cell leaving in place the remnants of dead cells , severe hemorrhage in the portal space (figure), the appearance of vacuoles in the cytoplasm of hepatocytes, enlargement of some of them (form), loss of the normal shape of some hepatocytes and the emergence of other cells loving the acid pigment with degeneration And pronounced necrosis (form) .

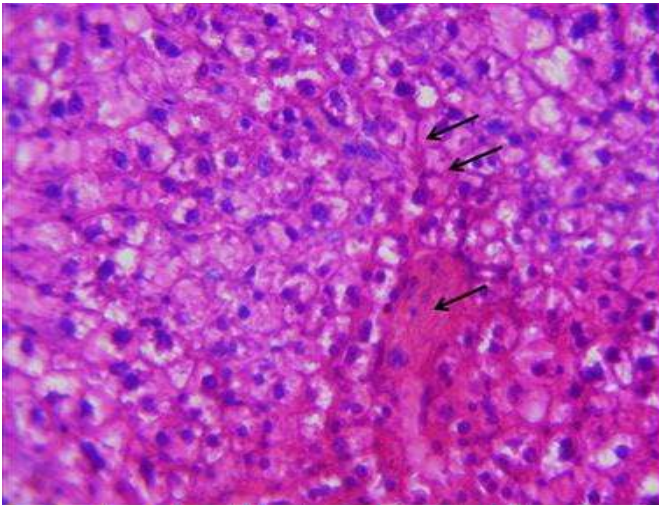


Figure (3) livers of mice in the low dose group showing congestion of the follicles and the fibrous septum (arrows) (H&E) 400X

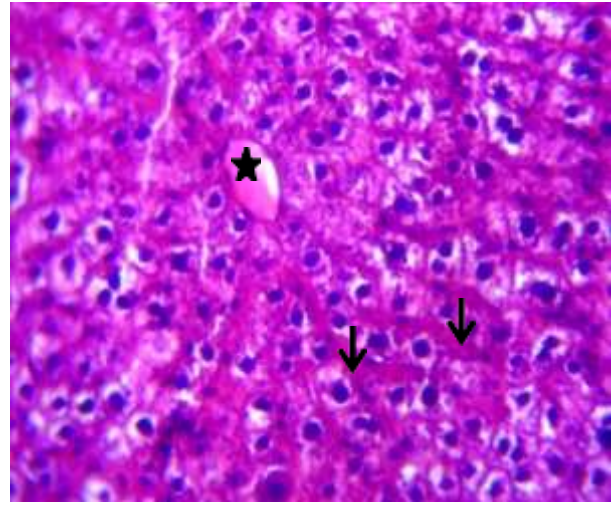


Figure (4) rat liver of the low dose group shows congestion of the follicles (arrows) and the collection of fluid in the central vein (H&E) 400X.

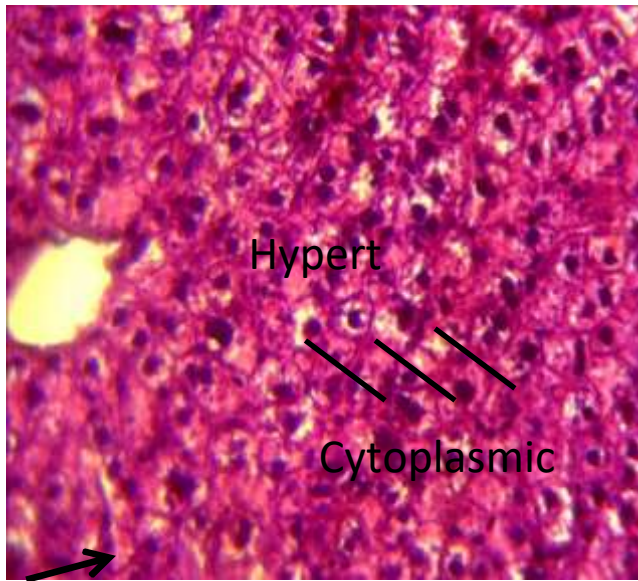


Figure (5) rat liver of the low dose group shows vacuole degeneration in the cytoplasm of some cytoplasmic vacuolation, hypertrophy of some hepatocytes and micronucleus lobes of some cells (arrow) H&E. 400X

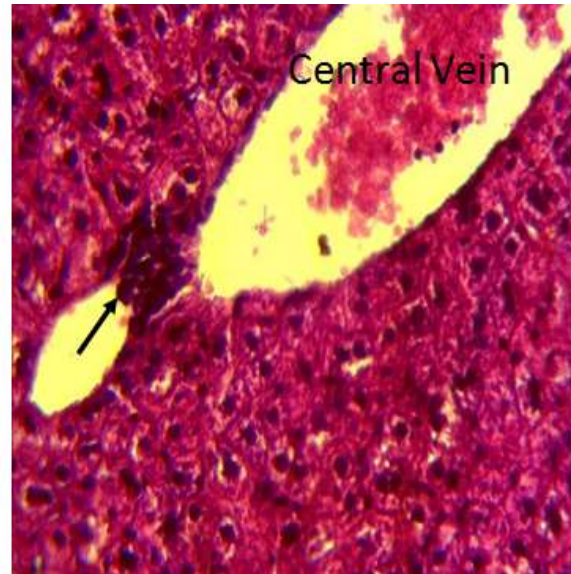


Figure (6) rat livers of low dose group, showing the central vein dilatation and infiltration of inflammatory cells (arrow) (H&E)) 400X.

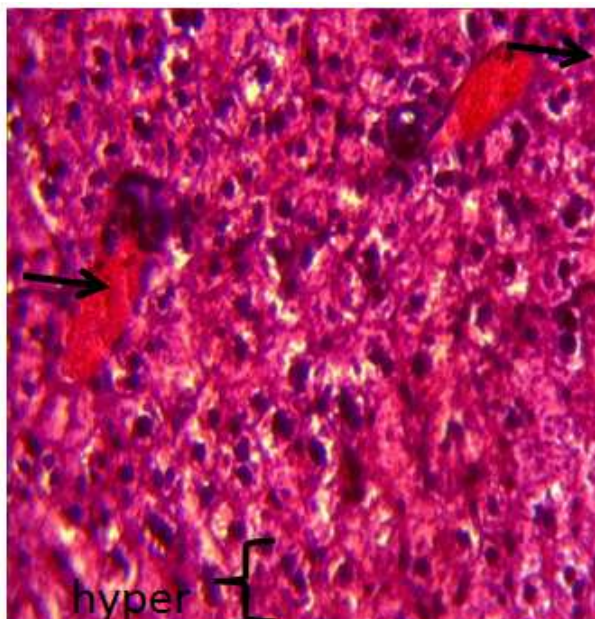


Figure (7), rat liver of the low dose group, shows hypertrophy and central vein congestion (arrows) H&E 400X.

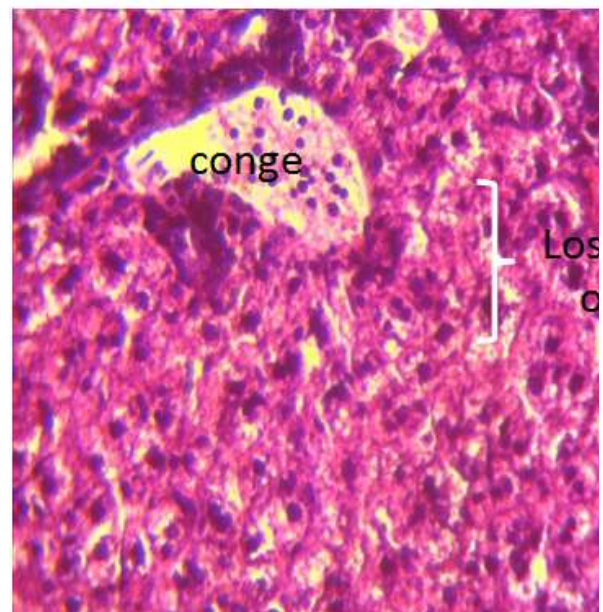


Figure 8) Mouse livers of high dose group showing congestion and loss of the lost normal shape (H&E)) 400x

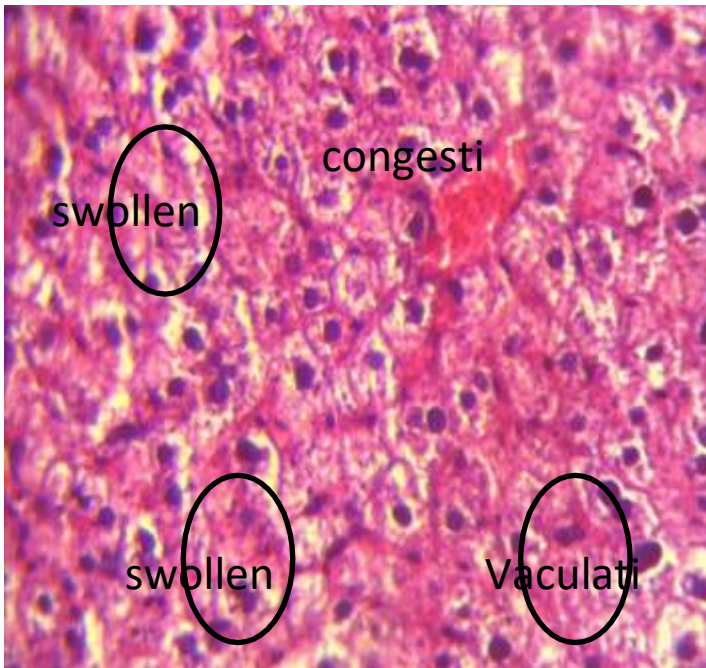

Figure (9) mice liver of the high dose group shows vacuole degeneration in the cytoplasm of some sytoplasmic vacuolation and swelling of some swollen hepatocytes (H&E)

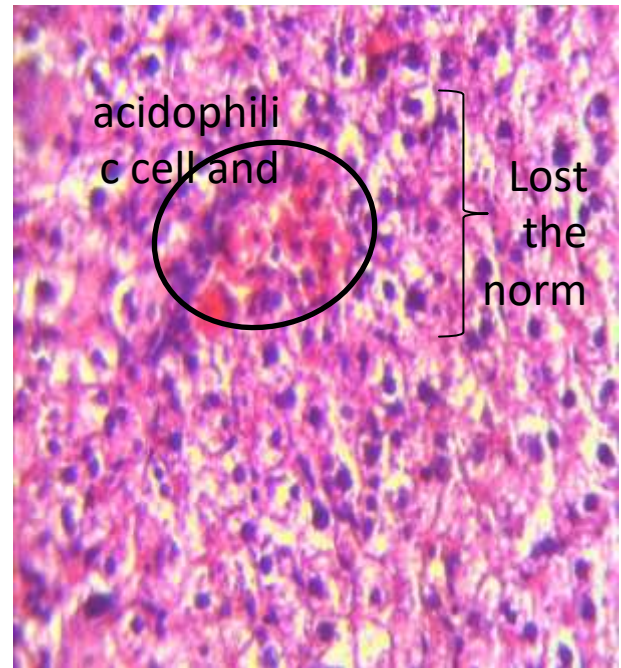


Figure (10) mice livers of the high dose group illustra eosinophilia hepatocytes with acidophilic hepatocytes at necrosis and loss of the normal arrangement of hepatocyte Lost the normal str. hepatocytes (H&E) 400X.

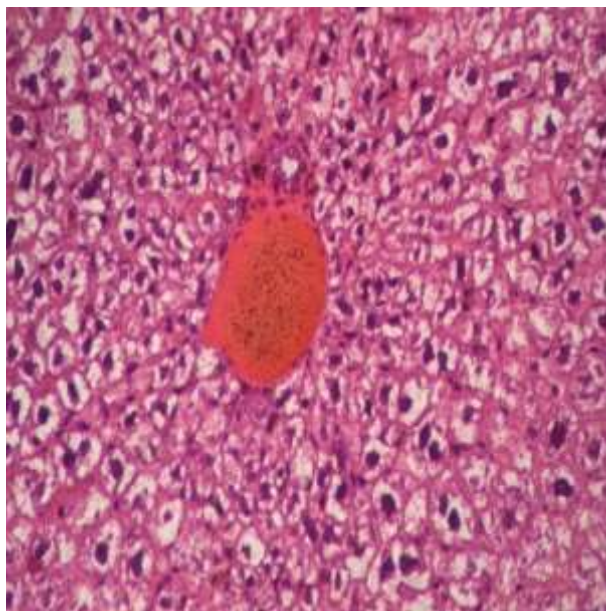


Figure (11) section in the liver of mice of high dose group showing hepatic portal vein congestion (asterisk) and vacuole degeneration of hepatocytes around the portal space (arrows) and necrosis of some hepatocytes (arrowheads) (H&E) 400X

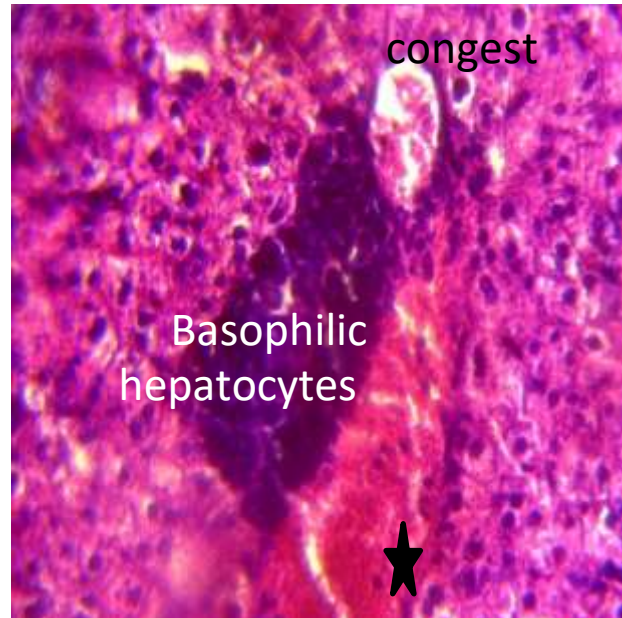


Figure (12) mice livers of high dose group showing hepatic portal vein congestion, acute hemorrhage (asterisk) and basal stain-loving cells (H&E) 400x

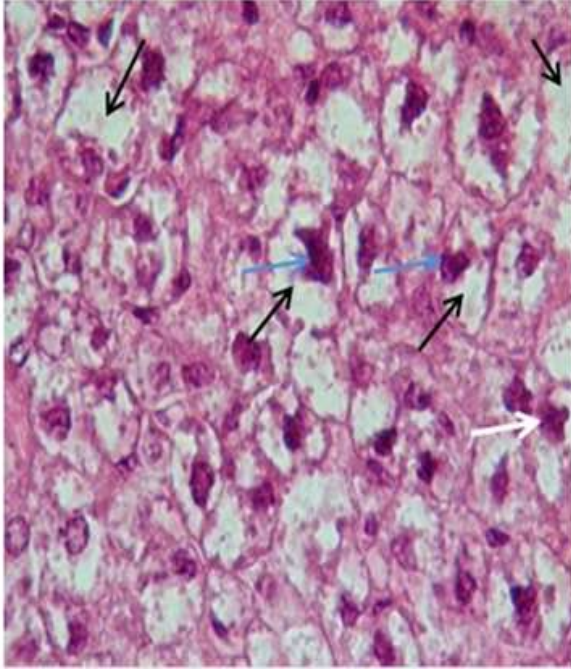


Figure (13) mouse liver of high dose group shows the enlargement of the nuclei of some hepatocytes and the change in the shape of the nucleus to the irregular shape (arrow) (H&E) 1000X.

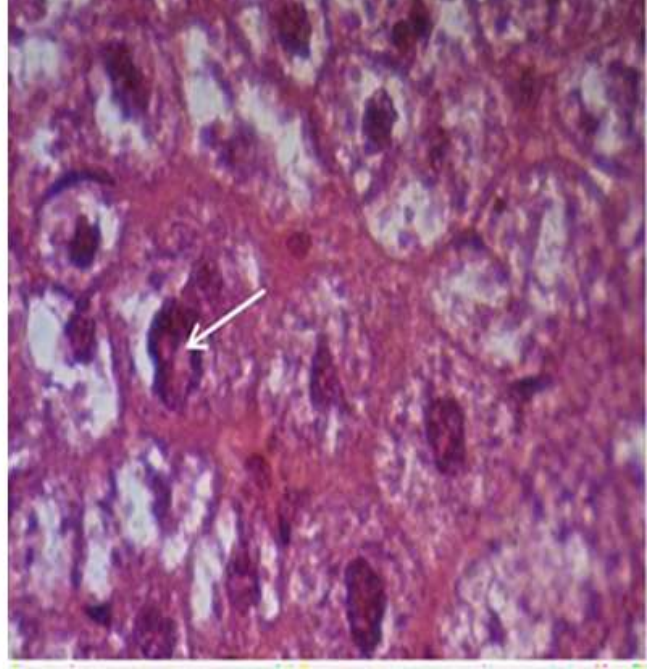


Figure (14) The livers of mice in the high dose group shows changes in the nuclei of cells (blue arrows) that suffer from vacuole degeneration (black arrows), so some of them appear dark in color, as well as changing their shapes from spherical to irregular shape and some appear lobular (white arrow) . (H&E) 1000X

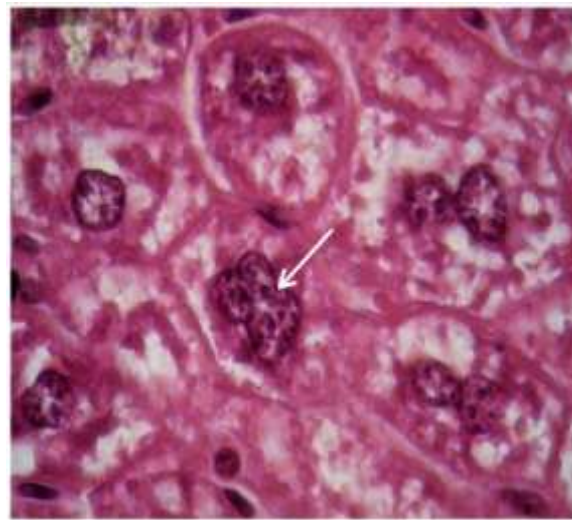

Figure (15) mouse livers of high dose group showing an enlarged section of the 1000X Hepatic Nucleus Lobes.

III. CONCLUSION

The study showed the effect of the toxicity of pesticide on the hepatocyte .The effects were significant in damages according to the dose .It also showed changes in cells haps , abnormalities in their nuclei, and the appearance of cytoplasmic vacuoles .

IV. DISCUSSION

Cypermethrin (CP) is a Pyrethriod insecticide used as an insecticide in large-scale commercial agricultural applications as well as. Cypermethrin is highly toxic to human , It has harmful effects on human health, causing

itching of the skin and eye irritation, In addition to its effect on animals, including laboratory mice, which were used to show the effects of the pesticide as a biomarker on its effects on humans. They have observed its effects on the reproductive system, births, the nervous system and tissue changes, and this is what is indicated(15,16)) One study also showed that cypermethrin works to cut the communication gap between cells, which has an active role in the process of tissues growth.(17) ,and its effects on the nervous system. animals , fish, bees, Pesticides have a clear effects on the damage they cause to the tissues structure of the liver organs in albino mice exposed to low and high doses for cypermethrin pesticide for a period 5 weeks . The tissue sections of control not treated with pesticide appears in a natural structure that did not show any changes (Fig1). These changes included in the liver of 2,5mg/kg dose group , represented by congestion in the hepatic sinuses, ,infiltration of hepatocytes an increase Kupffer and accumulation in the vitreous fluid in the hepatocyte cells in female and male of albino mice in as shown (Figures 2,3) .(18) . The present study showed that the hazards caused by toxicity of pesticide are different .In its effect according to the dose to which animal is exposed compared with control , and this recorded a significant difference , as it began with the appearance of vacuolar degeneration and hypertrophy cells and these effects as shown in(Fig 3,4) and this is what indicated by .(19,20) , and another study where .(21)indicated in his study on the liver of albino mice that low dose also contribute to changes the tissues composition from degeneration of hepatic cell and congestion of cytoplasm.. Also , the low and high doses hypertrophy of hepatocytes and vascular of cytoplasmic of hepatocytes cells in female and male of albino mice , the follicles and the fibrous, which considered as an indicator by toxicity of pesticide in the liver tissues and the damage of the vitality of this active organ in the body is the center of the most metabolic and immune process and store glycogen energy .(22) .(Figures 5,6,7)show congestion in the central vein and infiltration of some infilimentary cells and this also indicated by .(23) during his study on the hazard of pesticide on the liver showed were congestion blood vessels, hemorrhage, infiltration, vasodilatation, hypertrophy , where the congestion is caused by the congestion of blood in the liver as result hepatic vessel that carries blood to the outside , the entering congestion lead to lower blood pressure entering the liver , thus the hepatic cells are damage because they don't get their need from the blood .(24) , Therefore , congestion leads the hypertrophy of hepatocytes ,central vein dilatation and infiltration of inflammatory cells, some hepatocytes and micronucleus lobes of some cells, this similar with finding by .(25) and also these properties described by .(26) during his study the effect of carbofuron pesticide on the liver tissues of albino mice , and also these properties described by .(27) . Examined Histopathological alternation such as hypertrophy of hepatocytes and Hepatocellular degenerative and

REFERENCES

- 1 Isra Mahmood , Sameen Ruqia Imadi , Kanwal Shazadi , Alvina Gul , and Khalid Rehman Hakeem Effects of Pesticides onEnvironment: Toxicopathological changes on Wistar rat after multiple exposures to acetamidridhttps://www.researchgate.net/publication/28604219Springer International Publishing Switzerland 2016.
- 2 Henshaw Uchechi OKOROIWU, Iwara Arikpo IWARA. Dichlorvos toxicity: A public health perspective. Interdiscip Toxicol. 2018; Vol. 11(2): 129–137.
- 3 S. Mondal, R. C. Ghosh, S.S. Karmam2 and Kamal Purohit. Toxicopathological changes on Wistar rat after multiple exposures to acetamidrid Available at ww.veterinaryworld.org/Vol.7/November-2014/5.pdf.Exposure to Insecticide, Carbosulfan Caspian J. Env. Sci. 2006, Vol. 4 No.1 pp. 67~70
Kingsley C. Kanu 1,*,Solomon N. Ijioma 2 andOdudu Atiata 1. Haematological, Biochemical and Antioxidant Changes in Wistar Rats Exposed to Dichlorvos Based Insecticide Formulation Used in Southeast Nigeria Toxics 2016, 4(4), 28; https://doi.org/10.3390/toxics4040028.
- 4 K.c.Patrick -Iwuany anwu, C.C Onyemaenu.M.O.Wegwu and E.O.Ayalogu . Hematotoxic Effects of Diets contaminated with Petroleum Products (kerosene and Petrol)in Wistar Albino Rats .Research Journal Of Environmental Toxicology 40):134-140,2010.
- 5 Saphia .Ali Aitte And Maysoun Hussein. Zain 2019 Study Of Changes In Blood Parameters And Calculation Of PCT, MPV And DPW For The Platelets Of Laboratory Females And Males Of Albino Mice During Exposure To Doses Of Pyrethroid Pesticide (Alphacypermethrin) Journal Of Pharmacy And Biological Sciences Volume 14, Issue 2 Ser. I (Mar – Apr 2019), PP 71-78.
- 6 Mohamed Mohany , Gamal Badr*, Inas Refaat and Mostafa El-Feki. Immunological and histological effects of exposure to imidacloprid insecticide in male albino rats . African Journal of Pharmacy and Pharmacology Vol. 5(18), pp. 2106-2114, 15 November, 2011.
- 7 . Mansour, S.A., Heikal, T.M., Mossa, A.H. and Refaie, A.A. TOXIC EFFECTS OF FIVE INSECTICIDES AND THEIR MIXTURE ON MALE ALBINO RATSJ. Egypt. Soc. Toxicol. (Vol. 39: 85-94 July. 2008).
- 8 Ibtisam Khalaf Abd ali, Thekra Atta Ibrahim , Asraa Dawod Farhan, Mohammed Nsaif bbasStudy of the effect of pesticide 2,4-D on the histological structure of the lungs in the albino mice (Mus musculus) J. Pharm. Sci. & Res. Vol. 10(6), 2018, 1418-1421.
- 9 Wesam. Basal*, Abdel RahmanT.Ahmed, AyaA. Mahmoud & Amel R. OmaLufenuron induces reproductive toxicity and genotoxic effects in pregnant albino rats and their fetuses. Scientific Reports volume 10, Article number: 19544 (2020)
- 10 Eman Ahmad Alaa-Eldin, Dalia Abdallah El-Shafei & Nehal S. Abouhashem Individual and combined effect of chlorpyrifos and cypermethrin on reproductive system of adult male albino rats.Environmental Science and Pollution Research volume 24, pages1532–1543 (2017).
- 11 M.A.A.Mamun, I.J.Illa , K.M.F.Haque and Z.Ferdous Histological study of the effects of cypermethrin on liver and kidney tissues of mice model. Journal of Pharmacy and Biological Sciences Volume 9, Issue 5 Ver. II (Sep -Oct. 2014), PP 121-128. 1.2). In the next higher dose T3, necrotic hepatocy.
- 12 Rasha Abdel-Ghan1 Ebaa Mohammed, Shimaa Anis, and Waleed Barakat . Impact of Exposure to Fenitrothion on Vital Organs in Rats. Journal of Toxicology Volume 2016 |Article ID 5609734 | https://doi.org/10.1155/2016/5609734.
- 13 . Gretchen L.Humason, 1971.Animal Tissue Techniques 3rd ed .W.H. Freeman and company in USA press. Pp:641
- 14 Hu, JX; Li, YF; Li, J; Pan, C; He, Z; Dong, HY; Xu, LC (2011). "Toxic effects of cypermethrin on the male reproductive system: With emphasis on the androgen receptor". Journal of Applied Toxicology. 33 (7): 576–585. doi:10.1002/jat.1769. PMID 22147539.
- 15 16.Singh, AK; Tiwari, MN; Upadhyay, G; Patel, DK; Singh, D; Prakash, O; Singh, MP (2012). "Long term exposure to cypermethrin induces

nigrostriatal dopaminergic neurodegeneration in adult rats:

- 16 Tateno, C.; Ito, Seiichi; Tanaka, Mina; Yoshitake, Akira; et al. (1993). "Effects of pyrethroid insecticides on gap junctional intercellular communications in Balb/c3T3 cells by dye-transfer assay". *Cell Biology and Toxicology Journal*. 9 (3): 215–222. doi:10.1007/BF00755600. PMID 8299001.

- 17 19.Fathia A. Khogali*, Jameela B. Sheikh, Shafiga Abdel Rahman, Afaf A. Rahim and Maha H. Daghestani. Histopathological and Hematological Effects of Dimethoate 40EC on Some Organs of Albino Mice. *J. King Saud Univ.*, Vol. 18, Science (2), pp. 73-87, Riyadh (1426H./2005).
- 18 Persis, V.T., and Kalaiarasi, J.M.V. "Histopathological Responses of *Mystus vittatus* to Chronic Sublethal and Acute Lethal Toxicity of an Organophosphate Pesticide." *J. Expt Zoo India*, 4, No. 1 (2001), 103-108.
- 19 21.Ali Abd Alkadhim , JawadKadhim Farisr Efficiency of Hesperidin Against Liver Fibrosis Induced by Thioacetamide in Rats *Annals of R.S.C.B.*, ISSN:1583-6258, Vol. 25, Issue 5, 2021, Pages. 01-07.
- 20 El-Sayed M. A. El-Damaty; Abdel-Razik H. Farrag; Gamal Rowayshed and Hany M. Fahmy. Biochemical and Histopathological Effects of Systemic Pesticides on Some Functional Organs of Male Albino Rats, *Journal of Applied Sciences Research*, 8(11): 5459-5469, 2012.
- 21 23.Balkan, S. and T. Akta, 2005. Study on the liver functions in rats exposed to benomyl. *Journal of Biological Sciences*, 5(5): 666-669.
- 22 Atteq. M. J. Alarami* Histopathological Changes in the Liver and Kidney of Albino Mice on Exposure to Insecticide, Dimethoate *Int.J.Curr.Microbiol.App.Sci* (2015) 4(7): 287-300.
- 23 P. G. RASGELE1*, M. OKTAY2, M. KEKECOGLU3 and F. D. G. MURANLI4 . The Histopathological Investigation Of Liver In Experimental Animals After Short-Term Exposures To Pesticides , *Bulgarian Journal of Agricultural Science*, 21 (No 2) 2015, 446-453.
- 24 R. Ksheerasagar, M. Hiremath, B. Kaliwal, Durational exposure of car-bosulfan induced effect on kidney, biochemical contents and enzyme activities in albino mice, *World J. Sci. Technol.* 1 (2011).
- 25 .Çetin, A., Çiftçi, O., & Otlu, A. (2016). Protective effect of hesperidin on oxidative and histological liver damage following carbon tetrachloride administration in Wistar rats. *Archives of medical science : AMS*, 12(3), 486-493.
- 26 Hassina Khaldoun-Oularbi, Noura Bouzid, Soumia Boukreta, Chahrazed Makhlof, Fariza Derriche, Nadia Djennas Thiamethoxam Actara® induced alterations in kidney liver cerebellum and hippocampus of male rats *J Xenobiot* . 2017 Dec 21;7(1):7149.
- 27 .Nusrat Bano, Rahila Najam Histopathological and biochemical assessment of liver damage in albino Wistar rats treated with cytotoxic platinum compounds in combination with 5-fluorouracil *Arch Med Sci* 2019; 15 (4): 1092-1103.
- 28 Ali Abd Alkadhim , JawadKadhim Farisr Efficiency of Hesperidin Against Liver Fibrosis Induced by Thioacetamide in Rats *Annals of R.S.C.B.*, ISSN:1583-6258, Vol. 25, Issue 5, 2021, Pages. 01-07.
- 29 .Heba Youssef S, Zidan Azza HM Histopathological and biochemical effects of acute & chronic tramadol drug toxicity on liver, kidney and testicular function in adult male albino rats. *Forensic Res Criminol Int J*. 2016;2(4):138-144.
- 30 .Selamoglu, G. and M.T. Akay, 2000. Histopathological effects of the pesticide combinations on liver, kidney and testis of male albino rats. *Pesticides*, 15: 253-262.
- 31 .Afshare, S. A.; Farshid. R. Heidari and M. Ilkhanipour. 2008. changes in the liver and kidney tissues of Wistar albino rats exposed to fenitrothion *Toxicol Ind Health* . 24. (9):581-586
- 32 Dharmender Sharma, Gurinder Kaur Sangha .Triazophos induced oxidative stress and histomorphological changes in liver and kidney of female albino rats. *Biochemistry and Physiology* 110 (2014) 71-80.
- 33 Zerín, T., Islam, A., Gulnazar, S., Farjana, N. E., Begum, M. A. ., & Sadia, H.-E. (2021). Identification and Antibiotic Susceptibility of Blood Culture Isolates from Rajshahi, Bangladesh. *Journal of Scientific Research in Medical and Biological Sciences*, 2(2), 1-10. <https://doi.org/10.47631/jsrmb.v2i2.264>
- 34 Hadeer, A. A., & AL-Kaisie, B. I. (2018). Pathological and biochemical study on liver of male mice intoxicated with thioacetamide. *JEZS*.6(1): 1436-1441.
- 35 Bhelonde, J.J. (2001) Toxicopathological studies on danitol (fenpropathrin 10% EC) in rats. M.V.Sc Thesis Submitted to Indira Gandhi Krishi Vishwavidyalaya, Raipur, Chhattisgarh.
- 36 M. Saiful Islam1*, M. Mizanul Hoque2 Clinico-haematological and histopathological features of the Swiss albino mice *Mus musculus L.* in response to chronic cypermethrin exposure. *Sch.*
- 37 Chakraborty, B., Labh, S. ., Rani, R. ., & Bhattacharjee, S. . (2021). Biodiversity and Management Status of Chharia beel in Northern Bangladesh. *Journal of Scientific Research in Medical and Biological Sciences*, 2(2), 63-80. <https://doi.org/10.47631/jsrmb.v2i2.232>
- 38 Maha W Abou Nazel 1, Madiha M Talha 2, Hoda M Khalifa 1 o Histopathological Effects of Some Essential Oils on Liver and Kidney of Male Albino Mice *Bull High Inst Public Health* 2014; 44(2):88-97. 88.
- 39 45 Yasir Arfata*, Nasir Mahmoodb, Muhammad Usman Tahirc, Maryam Rashidd, Sameer Anjume, Fan Zhaoa, Di-Jie Lia, Yu-Long Suna, Lifang Hua, Chen Zhihaoa, Chong Yina, Peng Shanga, Ai-Rong Qianaa Key. Effect of imidacloprid on hepatotoxicity and nephrotoxicity in male albino mice, *Toxicology Reports* journal homepage : www.elsevier.com/locate/toxrep
- 40 Shaimaa M. M. Saleh, Tasneem A. Elghareeb, Mohamed A. I. Ahmed, Ibrahim A. Mohamed & Hosam A. Ezz El-Din. Hepato-morphology and biochemical studies on the liver of albino rats after exposure to glyphosate-Roundup. *The Journal of Basic and Applied Zoology* (2018) 79:48