



Clinical and biochemical (PH level) effects of platelet-rich fibrin on skin pedicle graft healing

1269

Muhammad J. Muhammad¹, Rafid M. Naeem² Alaa A. Ibrahim²

^{1*} Post-graduate student at the Department of Surgery and obstetrics, College of Veterinary Medicine, Basra University, Basra-Iraq.

A staff member at the Veterinary Hospital in Thi-Qar, Ministry of Agriculture, Thi-Qar – Iraq.

² Department of Surgery and obstetrics, College of Veterinary Medicine, Basra University, Basra, Iraq.
muhammadsurgery@gmail.com

Abstract

Objective: Surgical Procedures with skin damage range from scaling and planning to complex procedures such as skin graft surgery. Healing following such damage is crucial to predicting the prognosis of the treatment. **Aim:** The study aimed to investigate the impact of allogenic PRF on skin pedicle graft in treating experimental avulsion wounds from a clinical and biochemical standpoint (PH level). **Materials and method:** The experiment was performed on 15 adult female goats aged between 7-8 months and weighing 18-20 Kg. Surgery was performed under heavy sedation and created complete aseptic conditions, 2 skin marks (2×2 cm) on both sides of the trunk region of the animal. Two full thickness of the blotchy skin is cut carefully. Advancement or sliding flaps (2×6 cm) are harvested parallel to the least tension lines and slid over the adjacent wound. These wounds are allocated into two groups, the first one as the control group and the second group treated with autogenic platelet-rich fibrin. The two groups are represented in each goat. The edges of the wounds were closed by 2-0 nylon monofilament sutures. **Results:** Clinical examination showed the amount of wound exudation in the treated group significantly increased compared to the control group. The swelling of the grafts in the treated group disappeared within the next three postoperative days. However, in the control group, it was greater and remained for a longer period, as it continued until the seventh day. **Biochemically**, PH levels were greater in the surgically treated group on days five, seven, and fourteen after surgery than in the control groups. There was also a considerable rise in the control group. But on day twenty-one, there was no significant difference between the control and normal groups. Still, the pH level in the treated group rose significantly. **Conclusion:** PRF accelerates the inflammatory stage, speeding up the proliferation stage, and promotes the healing process. PRF may increase the pH level in the pedicle grafts and restore a normal environment in the wound.

Key Words: gout, pedicle graft, PRF, wound, acidity.

Number: 10.14704/nq.2022.20.7.NQ33155

Neuro Quantology 2022; 20(7):1269-1277

Introduction

A wound is a breach in the integrity of the skin caused by physical damage or disease. Most animals suffer wounds, and most wounds heal without incident. However, some wounds heal extremely slowly or never, and these wounds are more complicated. (Cullum, *et al.* 2016).

Wounds may be compared to "large biological building sites" where decomposition of dead tissue intercalates with the formation of new structures of extracellular matrix and a covering layer of epithelium. To finish this healing process, the wound must have a high metabolic rate. (Tottoli, *et al.* 2020 and Schneider, *et al.* 2007).

Healing a wound is a complicated process that can be broken down into three distinct stages that

follow one another in sequential order. These phases are known as the hemostatic and inflammatory phase, the proliferative phase, and the remodeling and maturation phase. Cytokines and growth factors that are secreted at the wound site play a significant role in the wound healing process and are tightly regulated by it. (Ozgok *et al.* 2021).



Platelets are cells that play an important part in wound healing, and they are the main source of the growth factor complex responsible for the bulk of the natural wound healing process. Platelets aid in clot formation and restrict the local loss of lymph and blood. They also stimulate angiogenesis in wound healing and play a critical role in delivering more than 20 growth factors required for tissue regeneration by activating mesenchymal cells. Some proteins, such as thrombin, promote platelet degranulation to generate these factors. (Giannobile, 1996 and Greenwell, 2001).

Platelet-rich biomaterials, such as platelet-rich plasma (PRP) and platelet-rich fibrin (PRF), have been the subject of research in both clinical and laboratory settings about their potential advantages in treating wounds. Platelet-rich fibrin is a kind of fibrin matrix produced by centrifuging fresh whole blood. It is a second-generation platelet concentration that Choukroun first defined. (Choukroun, *et al.* 2006 and Choukroun, *et al.* 2001).

Platelet-rich fibrin (PRF) is a recent platelet-based biomaterial that has the potential to be a revolutionary regenerative therapy for wounds of various etiologies. PRF is characterized as a biodegradable scaffold containing enhanced levels of platelets and leukocytes that may release high concentrations of bioactive structural proteins and functions as a time-release healing hemoderivative. (Soares, *et al.* 2021).

Aim of study

The study aimed to evaluate the effect of allogenic PRF on skin pedicle graft to treat experimental avulsion wounds, the evaluations Performed included clinical and acidity (PH level).

Methods

The experiment was conducted on 15 adult female goats, aged between 7-8 months and weighted 18-20 Kg; the animals were kept under similar conditions in management in the animal house for one week for adaptation.

Before surgery, ten millilitres of blood were taken from the jugular vein (Figure 1). Then, the blood was centrifuged for 14 minutes at 1500 rpm, and immediately transferred the blood to a 10 mL sterile plastic tube (PRF Tube; without anticoagulant, evacuated tube). There are three

layers in the product that arises from centrifugation. Platelet-poor plasma (PPP) is at the top, followed by a PRF clot in the center and RBCs at the bottom of the tube (Figure 2 a, b). After centrifugation, the fibrin clot and red blood cells connected to it are scraped from the tube and discarded (figure 3). (Mhaske *et al.* 2018).

Surgery was performed under heavy sedation and complete aseptic conditions, 2 skin marks (2×2 cm) were created on both sides of the trunk region of the animal. Two full thickness of the marked skin is cut carefully. Advancement or sliding flap (2×6 cm) are harvested parallel to the lines of least tension and are then slid over the adjacent wound. These wounds are allocated into 2 groups, the 1st one as the control group (without local treatment) and the second group treated with autogenic platelet-rich fibrin as PRF-treated groups. The 2 groups are represented in each goat. The edges of the wounds were closed with a simple interrupted pattern by a 2-0 nylon monofilament suture. The occlusive dressing was used to protect the grafts from dryness and infection (figure 4 a, b, c).

Clinically wound assessment post-surgery was performed as the following considerations: The general health condition of the animal, Swelling, and exudates. The exudates scores were estimated as non (1), light (2), moderate (3), and heavy (4). While swelling scores are classified into non 0, mild 1, and obvious 3 (Nikkhah, *et al.* 2013).

The level of acidity was detected at the period 5th, 7th, 14th and 21th days post-surgery. The procedure was carried out by spraying normal saline at the site of skin (treated, control, and normal skin), then the strips of PH detector were put on the skin surface, the color of the PH strip turn to different colors according to the acidity of the skin sites as we mentioned before. The result colors were compared with a standard color leaflet to detect the number of PH levels (Figure 5).

Results were expressed as mean values standard errors. Data were statistically analyzed by independent samples T-test using a statistical software program (SPSS for windows version 22, USA) Differences were considered significant at ($P \leq 0.05$).

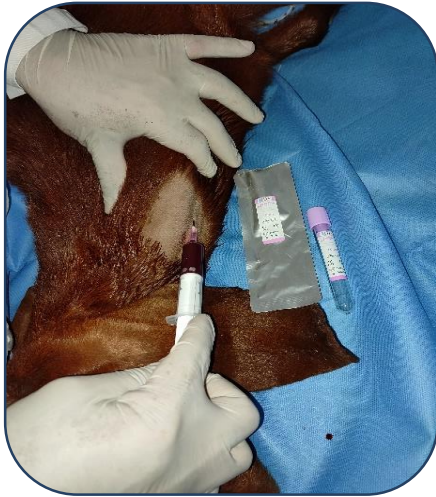

Figure 1: a collection of the venous blood from the jugular vein

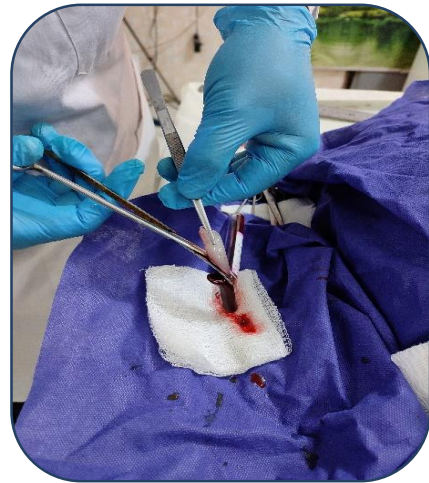

Figure 3: the PRF glue was isolated from the blood

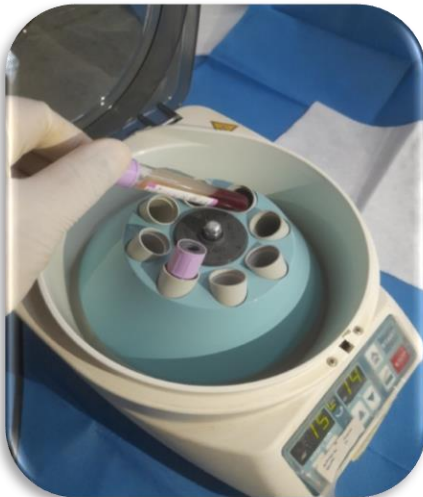

Figure 2a: centrifugation of the blood sample with 1500 rounds per 14 minutes

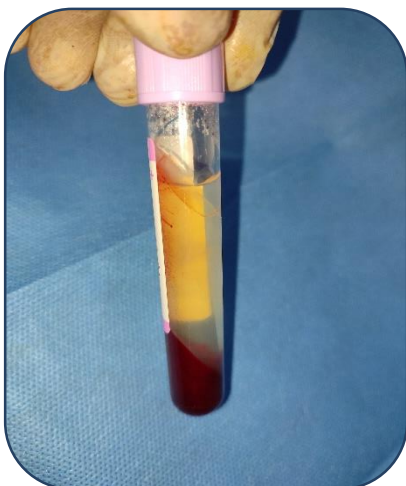

Figure 2b: the accumulation of PRF inside the tube after centrifugation

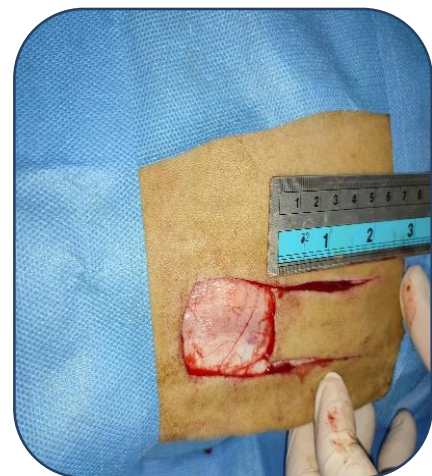

Figure 4a: skin pedicle flap will be done by 2 parallel incisions

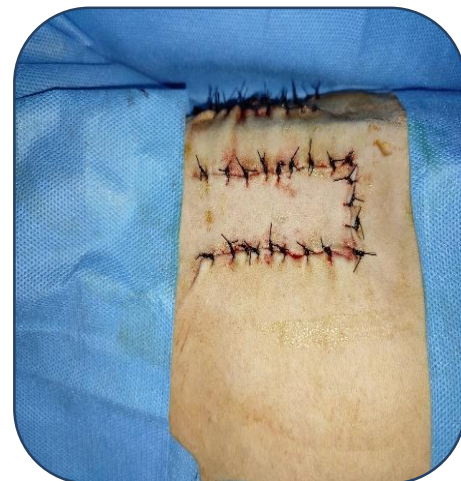

Figure 4b: Suturing of the pedicle flap was complete with a simple interrupted suture pattern

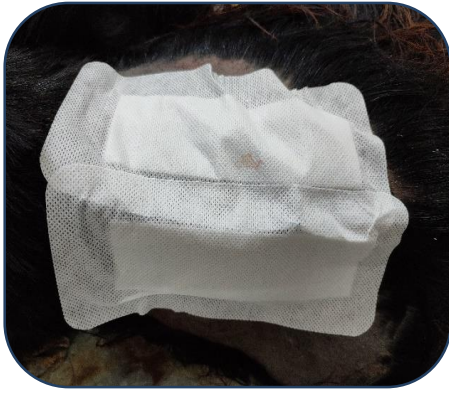

Figure 4c: the site of surgery was covered by wound dressing

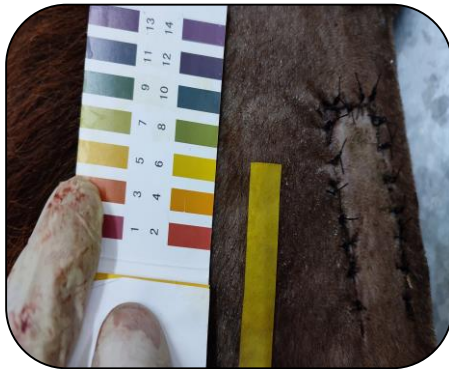

Figure 5: measuring the level of acidity by using PH test paper

Results

Clinical evaluations

After surgery, there was no change in the animal's appetite. On the day after the operation, the temperature of all animals increased by one degree and then reverted to normal.

On the first postoperative day, fluid exudation with minimal blood was noted at the wound site in the treated group, but a minor quantity of blood was observed in the control group. On days two, three, and four post-surgeries, it was noticed that there was no blood in the exudates and that exudation in the treated wounds progressively decreased. However, on the third day, fluid exudates disappeared from the control wounds. (Figure 6, table 1).

The treated group of wounds showed swelling in the patch skin region on the first and second day, however, the edema subsided within three days. In contrast, the swelling in the control group was higher and lasted longer, since it persisted until the seventh day. (Figure 7, table 2).

PH levels evaluation

On the fifth, seventh, and fourteenth days after surgery, the acidity results showed a significant difference between the three groups (normal, control, and PRF-treated groups) (figure 8 table 3). The result of the PH level in the treated group was significantly higher as compared to the other groups. In addition, the control group was significantly increased more than normal. However, on the twenty-first day after surgery, the results showed that there was no significant difference between the control and normal groups, but there was a significant increase in the pH level in the treated group.

In the same group within the different periods of taking pH measurements, the results of the control group showed no significant differences in 5, 7, and 14 days after surgery. But it decreased at 21th day.

However, in the treated group, there is no significant difference in PH levels during periods 5, and 7 days after the surgery, but there were significant decreases in periods 14 and 21 days after the surgery.

Discussion

The importance of treating wounds comes from the risk of infection due to the size of the avulsion portion from the skin, which is often produced by attacks by predators, industrial equipment, or car accidents. (Pavletic 2018).

This study aimed to determine the effect of allogenic PRF on skin pedicle grafts used to treat experimental avulsion wounds. Clinical acidity (pH) assessments were conducted.

The goat's body is elegant, sturdy, and covered with hair, allowing it to quickly locate food on the ground and even climb bushes to eat leaves and buds. However, his capacity to get sustenance may lead to skin injuries, some of which are very difficult to treat. Due to the dearth of research conducted on farm animals (big animals) as opposed to laboratory animals such as rabbits and rats, goats are deemed suitable for surgical skin tests. (Breeze et al.2013).

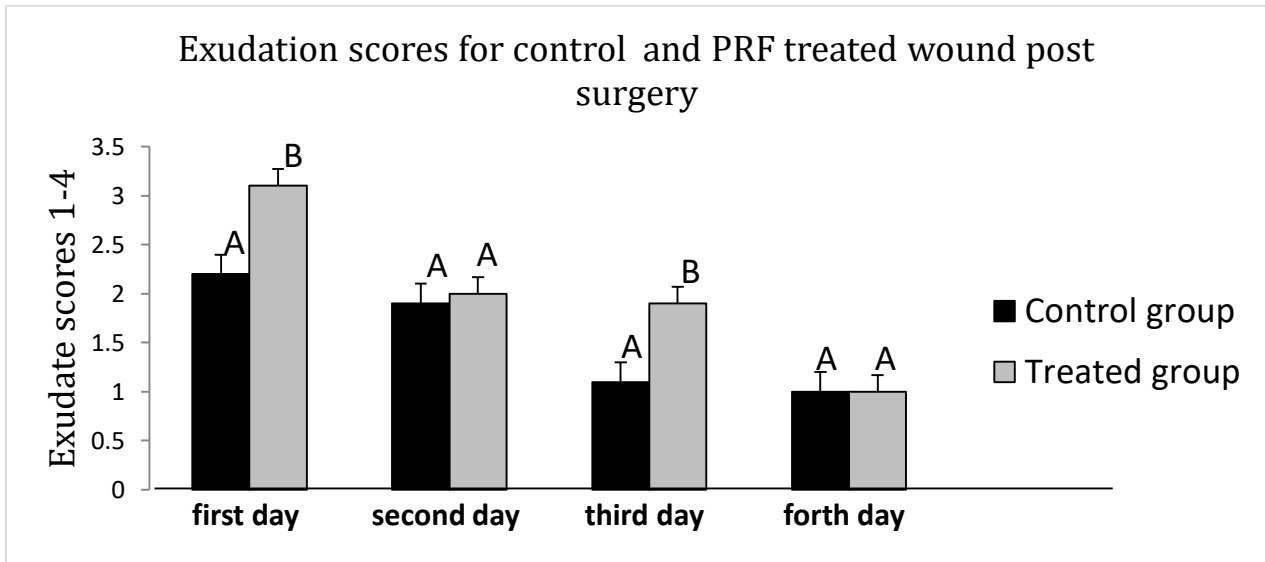


Figure 6: the clinical study showed the exudates scores for skin grafts of Control and PRF treated groups wounds during (1, 2, 3, and 4 days post-surgery). ^{ABC} Different letters among groups indicate significant differences (P < 0.05).

Table 1: the clinical study showed the scores for skin grafts of Control and PRF treated groups' wounds (1, 2, 3, and 4 days post-surgery) (means and standard errors).

Groups	1 st day	2 nd day	3 rd day	4 th
Control	2.2±0.2 ^A	1.9±0.17 ^A	1.1±0.1 ^A	1.0±0.0 ^A
PRF	3.1±0.17 ^B	2.0±0.14 ^B	1.9±0.1 ^B	1.0±0.0 ^A

ABC Different letters within each column indicate significant differences (P < 0.05).

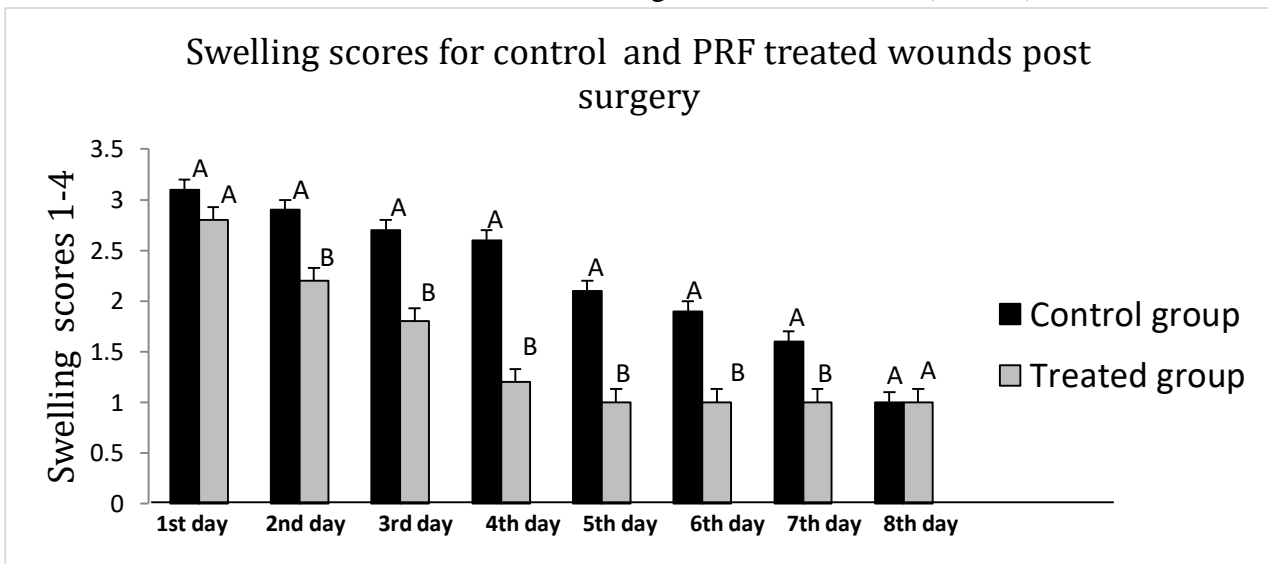


Figure 7: the clinical study showed the Swelling scores for skin grafts of Control and PRF treated groups (1-8 days post-surgery). ^{ABC} Different letters among groups indicate significant differences (P < 0.05).

Table 2: the clinical study showed the swelling scores for skin grafts of Control and PRF treated groups (1-8 days post-surgery) (means and standard errors).

Group	1 st day	2 nd day	3 rd day	4 th day	5 th day	6 th day	7 th day	8 th day
Control	3.1± 0.1 ^A	2.9± 0.1 ^A	2.7± 0.15 ^A	2.6± 0.16 ^A	2.1± 0.1 ^A	1.9± 0.17 ^A	1.6± 0.16 ^A	1.0± 0.0 ^A
PRF	2.8± 0.13 ^A	2.2± 0.13 ^B	1.8± 0.13 ^B	1.2± 0.13 ^B	1.0± 0.0 ^B	1.0± 0.0 ^B	1.0± 0.0 ^B	1.0± 0.0 ^A

1274

ABC Different letters within each column indicate significant differences (P<0.05).

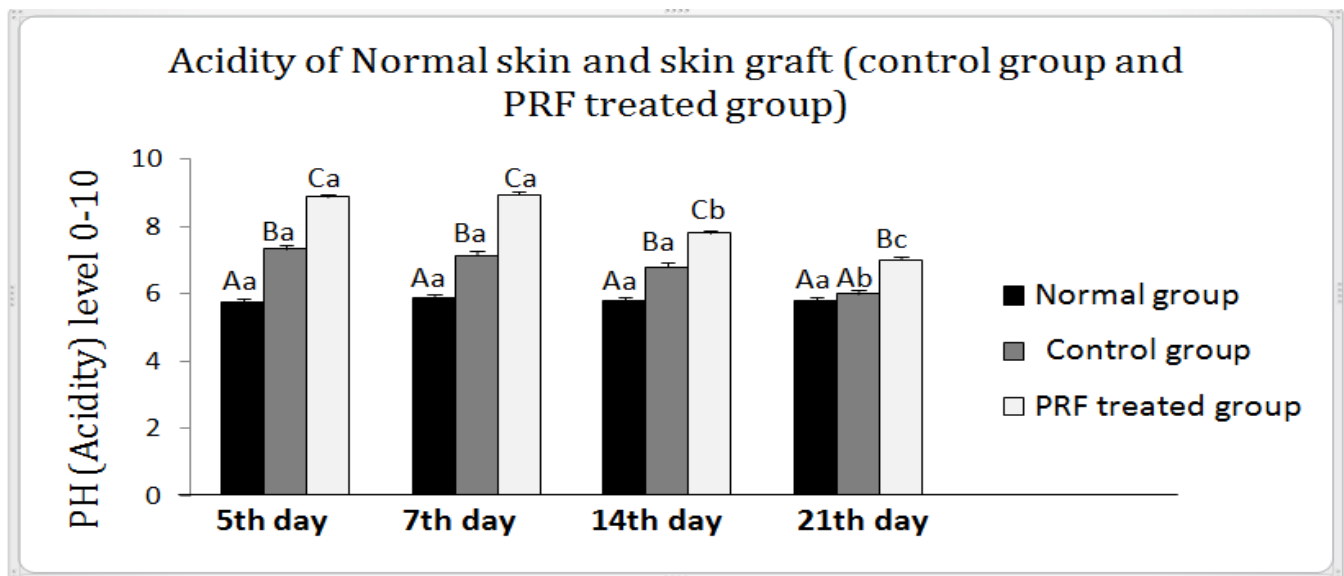


Figure 8: the clinical study showed the PH levels (Acidity) for Normal skin and skin grafts of Control and PRF treated groups during different periods post grafting (5, 7, 14 and 21 days post-surgery). ABC Different letters among groups indicate significant differences (P< 0.05). abc Different letters within the group indicate significant differences (P<0.05).

Table 3: levels of PH (Acidity) for Normal skin and skin grafts of Control and PRF treated groups during different periods post grafting (5, 7, 14 and 21 days post-surgery) (means and standard errors).

Groups	5 th day	7 th day	14 th day	21 th day
Normal	5.73±0.11 ^{Aa}	5.86±0.09 ^{Aa}	5.8±0.13 ^{Aa}	5.8±0.2 ^{Aa}
Control	7.33±0.12 ^{Ba}	7.13±0.09 ^{Ba}	6.8±0.13 ^{Ba}	06±0.1 ^{Ab}
PRF	8.86±0.09 ^{Ca}	8.93±0.06 ^{Ca}	7.8±0.13 ^{Cb}	07±0.1 ^{Bc}

ABC Different letters within each column indicate significant differences (P<0.05). abc Different letters within each row indicate significantly

Clinical examination showed the amount of wound exudation in the treated group was a significant increase compared to the control group. However, these exudates are shown in acute wounds in the normal range of inflammatory stage period. Therefore, these excessive healthy acute exudates induced by PRF promote the healing process in the treated group.

Wound fluid and wound drainage are other names for exudates. An inflammatory reaction is triggered, and the capillaries become more permeable when there is a breach in the skin. Exudates are formed when serous fluid escapes into the wound bed. In addition to water, electrolytes, nutrients, proteins, inflammatory mediators, proteases, growth factors, white blood cells, and microbes, exudates include many other substances. It is an important aspect of wound healing because it helps keep the site wet and encourages epithelial cell migration. Exudates are essential for healing because they include growth agents and nutrients, and the wet environment promotes autolysis (the separation of necrotic tissue from healthy tissue). (Nichols, 2016).

In the treated group, the swelling disappeared within the next three postoperative days. However, in the control group, the swelling was greater and remained for a longer period, as it continued until the seventh day.

As a result of the release of vasoactive amines and histamine-rich granules from mast cells, this stage is characterized clinically by redness, heat, swelling, and pain. These mast cell mediators induce surrounding arteries to become leaky, so facilitating the effective transport of neutrophils to the site of damage through the vasculature. Because the veins become permeable, fluid also flows into the affected region, producing swelling and pressure-related discomfort. (Goldberg and Diegelmann, 2010; Broughton, *et al.* 2006 and Cutting, *et al.* 2015).

In 2019, Alkhalifa and Sharifi stated that tissue edema is an inevitable biologic process. Edema peaks a few days after surgery and remains as long as biological healing processes are active.

As we knew in the treated group, we added PRF, which is rich in the inflammatory cell, growth factors, and fibrin, this result in acceleration of the debridement or inflammatory stage and speeding up the proliferation stage, this result agreed with Ding, *et al.* 2017.

The pH value indicates the concentration of H⁺ ions in solution inside the interstitial milieu of wounds. It ranges from 0 and 14. The optimal pH value for chemical reactions is determined by endogenous and external variables, such as the surrounding temperature. The pH value is a significant predictor of the metabolism during wound healing and, thus, a critical parameter for treatments in wound care. (Kuo *et al.* 2020).

On the fifth, seventh, and fourteenth days after surgery, the PH level in the treated group was significantly higher as compared to the other groups. In addition, the control group was significantly increased more than normal. However, on the twenty-first day after surgery, there was no significant difference between the control and normal groups, but there was a significant increase in the pH level in the treated group.

The results showed that the PRF was observed to be alkaline and alkalinity increased on day 5. Hence, it may be beneficial in wound healing for the cases where a large area of tissue is removed, and the tissue needs more O₂ consumed for metabolism and regeneration then the wound pH lowers significantly. The PRF may increase pH and may restore normalcy. This result may disagree with (Nagaraja, *et al.* 2019), they considered the APRF have acidic PH through an invitro study.

Inflammation, proliferation, and maturation are often referred to as the three phases of wound healing. The blood coagulates and creates a temporary plug in the first minutes or hours after damage, the inflammatory phase's early stage. Since blood has a pH of around 7.4, the wound's pH would be extremely near to this level. However, as wound healing occurs, the pH of the wound changes. At this point, the wound has

healed and the pH has returned to normal. The proliferation and migration of various cell types are influenced by (local) pH in this wound healing scenario. Keratinocytes and fibroblasts, two kinds of wound healing cells, proliferate best at an acidic pH range of 7.2 to 8.3. The matrix metalloproteinases of the enzyme are essential for the health of both kinds of cells. Degrading zinc-dependent enzymes play an important role in cell migration by destroying the extracellular matrix in front of migratory cells. In vivo, these enzymes have pH optimums of around 8. (Sirkka, et al. 2016).

In 2017, Bennison et al. stated that the wounds characteristically have a neutral to alkaline pH existing in the pH range of 6.5 to 8.5 while chronic wounds exist at a range of 7.2 to 8.9. however, our results showed that the PH of the treated group reach 8.9 on day 5 post-surgery but the clinical evaluations of these wounds expose no signs of a chronic wound. we assumed the inflammatory stage was accelerated by PRF treatment and the proliferative stage was already begun.

In 2016, Jones found that the pH range between 7.2 and 8.3 is ideal for keratinocyte and fibroblast growth, which documented this range. Unlike dermal fibroblasts, epidermal keratinocytes can withstand a significantly broader pH range. Furthermore, epidermal keratinocytes demonstrate the best migration from ex vivo skin explants at a pH of 8.55. This is consistent with previous research that found a higher pH to be beneficial for the survival of skin grafts after burn injuries. Keratinocyte growth, viability, and migration are hampered in an environment with a low pH. showed that a low pH hinders multilayer epidermal regeneration using keratinocyte/fibroblast 3D skin constructions. Greatly slowed migration at pH 6.5 compared to pH 7.4, and this difference was seen between the two. This suggests that keratinocytes may not be recruited in sufficient numbers owing to a decreased pH near the wound borders. As a result, the epidermal barrier cannot be repaired.

Blatt et al. proved in 2022 that PRF has an

antibacterial impact against bacteria in anaerobic environments, such as a dental root canal or a local pyoderma gangrenosum. It illustrates PRF's ability to modify pH levels even in anaerobic environments. By these findings, the current research demonstrated that the average pH level of PRF matrices began at 8.9, but decreased throughout time, demonstrating the ability of PRF to optimize pH levels at wound healing sites.

Within the different periods of taking pH measurements, the control group showed no significant differences in 5, 7, and 14 days after surgery, lastly, it decreased in 21th day. However, in the treated group, there was a significant decrease in periods 14 and 21 days after the surgery.

Bennison et al. (2017) demonstrate that open wounds have a neutral to alkaline pH range of 6.5 to 8.5, but chronic wounds have a pH range of 7.2 to 8.9 In addition, Jones et al. (2015) supported that, as wounds proceed through the phases of healing, a change toward an acidic pH takes place.

Conclusion

1. PRF produces excessive healthy acute exudates which promote the healing process
2. Clinically, PRF accelerates the debridement or inflammatory stage and speeds up the proliferation stage
3. The PRF was observed to be alkaline and it may increase the pH level in the pedicle grafts and restore a normal environment in the wound.

Acknowledgement

The authors acknowledge the assistant prof. Dr Rafid N. Majeed

References

- Alkhalifa, R. M. N., & Sharifi, D. (2018). *Evaluation of the Frozen Tendon Graft Covered with Mesenchymal Cell Derived from Bone Marrow and Platelet Rich Plasma (PRP) in Maintaining the Normal Length of Tendon in Sheep Lamb*. PhD thesis, University of Tehran Faculty of Veterinary Medicine.
- Bennison, L. R., Miller, C. N., Summers, R. J., Minnis, A. M. B., Sussman, G. & McGuinness, W. (2017). The pH of wounds during healing and infection: a descriptive literature review. Volume 25 Number 2, *Wound Practice and Research*, pp: 63-69.
- Blatt, S., Schröger, S. V., Pabst, A., Kämmerer, P.

- W., Sagheb, K. & Al-Nawas B. (2022). Biofunctionalization of Xenogeneic Collagen Membranes with Autologous Platelet Concentrate-Influence on Rehydration Protocol and Angiogenesis. *Biomedicines*, 10(3) pp:706.
- Breeze, J., James, G. R., & Hepper, A. E. (2013). Perforation of fragment simulating projectiles into goat skin and muscle. *Journal of the Royal Army Medical Corps*, 159(2), 84–89.
 - Broughton, G., Janis, J. & Attinger, C. (2006). The basic science of wound healing. *Plast Reconstr Surg*, 117:12S.
 - Choukroun, J., Adda, F., Schoeffler, C., & Vervelle, A. (2001). The opportunity in perio-implantology: The PRF.
 - Dohan, D. M., Choukroun, J., Diss, A., Dohan, S. L., Dohan, A. J., Mouhyi, J., & Gogly, B. (2006). Platelet-rich fibrin (PRF): a second-generation platelet concentrate. Part II: platelet-related biologic features. *Oral surgery, oral medicine, oral pathology, oral radiology, and endodontics*, 101(3), e45–e50.
 - Cullum, N., Buckley, H., Dumville, J., Hall, J., Lamb, K., Madden, M., Morley, R., O'Meara, S., Goncalves, P. S., Soares, M., & Stubbs, N. (2016). Wounds research for patient benefit: a 5-year programmed of research. NIHR Journals Library. Southampton (UK): *NIHR Journals Library*; (Program me Grants for Applied Research, No. 4.13.) *Scientific summary*.
 - Cutting, K. F., Vowden, P. & Wiegand, C. (2015). Wound inflammation and the role of a multifunctional polymeric dressing. *Wounds International*, Vol 6, Issue 2, pp: 41-46.
 - Ding, Y., Cui, L., Zhao, Q., Zhang, W., Sun, H. & Zheng, L. (2017). Platelet-Rich Fibrin Accelerates Skin Wound Healing in Diabetic Mice. *Ann Plast Surg*. 79(3): e15-e19
 - Giannobile, W. V. (1996). The potential role of growth and differentiation factors in periodontal regeneration. *J Periodontol*, 67, p. 545e53.
 - Goldberg, S. R. & Diegelmann, R. F. (2010). Wound Healing Primer. *Surg Clin N Am*, 90 pp: 1133–1146.
 - Greenwell, H. (2001). guidelines for periodontal therapy. *American Academy of Periodontology*. 72, pp. 1624-1628.
 - Jones, E. M. (2016). An Investigation into the Significance of Tissue pH and Biofilms on Wound Healing, Ph.D. Thesis, *University of Liverpool*. 255 pages.
<https://livrepository.liverpool.ac.uk/3001674/>
 - Kuo, S. H., Shen, C. J., Shen, C. F., & Cheng, C. M. (2020). Role of pH Value in Clinically Relevant Diagnosis. *Diagnostics (Basel, Switzerland)*, 10(2), 107.
 - Mhaske, N., Fernandes, C., Rajhans, N. & Fernandes, G. (2018) The role of leucocyte- and platelet-rich fibrin (L-PRF) in periodontal regeneration: A review article. *Mouth Teeth*
 - Nagaraja, S., Mathew, S., Rajaram, R. B., Pushpalatha, C., Abraham, A., & Chandanala, S. (2019). Evaluation of Histological and pH Changes in Platelet-Rich Fibrin and Platelet-Rich Fibrin Matrix: A In vitro Study. *Contemporary clinical dentistry*, 10(4), 652–657.
 - Nichols, E. (2016). Wound assessment part 2: exudates. *Wound Essentials*, vol 11 no 1, pp: 36-41.
 - Nikkhah, D., Dheansa, B., Bosanquet, D., Rangaraj, A., & Richards, A. (2013). Topical steroids for chronic wounds displaying abnormal inflammation. In *The Annals of The Royal College of Surgeons of England* (Vol. 95, Issue 6, pp. 448–448). Royal College of Surgeons of England
 - Ozgok Kangal MK, Regan JP. (2021). *Treasure Island (Wound Healing)*: StatPearls Publishing May 9.
<https://www.ncbi.nlm.nih.gov/books/NBK535406/>
 - Pavletic, M. M. (2018). *Atlas of small animal wound management and reconstructive surgery* (M. M. Pavletic, Ed.; 4th ed.). John Wiley & Sons.
 - Schneider, L. A., Korber, A., Grabbe, S., & Dissemond, J. (2007). Influence of pH on wound-healing: A new perspective for wound therapy? In *Archives of Dermatological Research* (Vol. 298, Issue 9, pp. 413–420).
 - Sirkka, T., Skiba, J.B. and Apell, S. P. (2016). Wound pH depends on actual wound size. *physics. med-ph*. arXiv:1601.06365. Cornell University. 13 pages.
 - Soares CS, Dias IR, Pires MA, Carvalho PP. (2021). Canine-Origin Platelet-Rich Fibrin as an Effective Biomaterial for Wound Healing in Domestic Cats: A Preliminary Study. *Vet Sci*.8(10):213.
 - Tottoli, E. M., Dorati, R., Genta, I., Chiesa, E., Pisani, S., & Conti, B. (2020). Skin wound healing process and new emerging technologies for skin wound care and regeneration. In *Pharmaceutics* (Vol. 12, Issue 8, pp. 1–30). MDPI A