

# EFFECT OF VITAMIN D3 SUPPLEMENTATION ON SOME PHYSIOLOGICAL, PATHOLOGICAL AND IMMUNOHISTOCHEMICAL PARAMETERS ON THIOACETAMIDE INDUCED LIVER FIBROSIS IN MALE RATS

Ali H. Al-Ashour<sup>1</sup>, Iqbal A. Al-Rufaei<sup>2</sup>, Maha K. Al-Mallak<sup>3</sup>

<sup>1</sup>Department of Biology, College of Science, University of Basrah, Basrah, Iraq. E-mail: asa882603@gmail.com

<sup>2</sup>Department of Biology, College of Science, University of Basrah, Basrah, Iraq. E-mail: eqbal.hazam@uobasrah.edu.iq

<sup>3</sup>Department of Biology, College of Science, University of Basrah, Basrah, Iraq. E-mail: Khalilmaha73@gmail.com

## ABSTRACT:

**Background:** The aim of this study was to determine some physiological and biochemical parameters in liver fibrotic rats, and fibrotic rats treated with vitamin D3 such as lipid profile (TC, TG, HDL, LDL, VLDL), antioxidative enzymes (MDA, CAT, GPx) and evaluation the role of Matrix metalloproteinase (MMP-13) expression in rats livers tissue by immunostaining, so present study designed to demonstrate the importance of vitamin D3 as antifibrotic and antioxidant agent reduced liver fibrosis complications. **Methods:** Rats were injected (IP)with (150) mg/kg/BW of (TAA) given three times/ week for 8,12 and 14 weeks to induced liver fibrosis whereas, vitamin D3 was given three times/ week with a dose of 0.5mg/100g/BW, blood and liver biopsy was collected from each rat in all experimental groups. **Results and discussion:** The obtained results revealed that there was significant increased ( $P<0.05$ ) in Triglycerides(TG) and VLDL level in (TAA) treated group at 12 weeks period compared with control group, whereas a significant increased ( $P<0.05$ ) in total cholesterol, triglyceride, low density lipoprotein and very low density lipoprotein (TC,TG, LDL and VLDL) was obtained in TAA treated rats at 14 weeks period, data showed that there was significant increased ( $P<0.05$ ) in high density lipoprotein (HDL) in TAA+ vitamin D3 group post (14) weeks compared to control group ,while exhibited significant decreased ( $P<0.05$ ) in (TC, TG, LDL and VLDL) levels at the same period compared to TAA group, moreover Malondialdehyde (MDA) antioxidant enzyme concentration recorded significant increase at ( $P<0.05$ ) in fibrotic rats after (8,12 and 14) weeks compared with control group, whereas rats co treated with both TAA+ vitamin D3 showed significant decreased ( $P<0.05$ ) in (MDA) level compared with TAA group. Also Glutathione peroxidase (GPX)level was significantly decreased ( $P<0.05$ ) in fibrotic rats (TAA) group during (14) weeks period compared with control group , while (TAA + vitamin D3) group showed significant increased ( $P<0.05$ ) in GPx level compared with TAA group at (12&14) weeks. However, Catalase enzyme (CAT) level was significantly decreased ( $P<0.05$ ) in TAA group at (12 and 14) weeks compared with control group while there was increased significantly ( $P<0.05$ ) in CAT level in rats co treated with TAA+ vitamin D3 at 12&14 weeks compared with (TAA) group, Biochemical data referred to significant decrease in MMP-13 enzyme concentration in rat serum of fibrosis group compared with control group but there was significant increase in MMP -13 concentration when D3supplemntation used with TAA that clarified the importance of this agent in prevent liver fibrosis complications.

**Keywords:** Matrix Metalloprotenase-13, Thioacetamide, Vitamin D3, Antioxidant Enzymes.

## I. INTRODUCTION

Liver fibrosis is the most common final step of chronic liver diseases ,the pathogenesis includes hepatic tissue damage as a result of noxious, activation of immune cells and hepatic stellate cells, then synthesis of fibrotic extracellular matrix (ECM) components leading to scar formation , there are two types of liver fibrosis , acute

liver fibrosis (ALF) caused by accumulation of (ECM) proteins in which collagen was excessively produced by fibrocytes lead to liver dysfunction, and chronic liver fibrosis (CLF) caused by hepatitis virus infections, nonalcoholic fatty liver disease (NAFLD) especially nonalcoholic steatohepatitis (NASH), as well as primary biliary cholangitis (PBC) (Roderfeld, 2018). In healthy liver homeostasis of extracellular matrix (ECM) is sustained by a precisely regulated permanent turn-over directed by a group of enzymes called matrix metalloproteinases (MMPs) and their specific inhibitors (Giannandrea & Parks, 2014; Robert *et al.*, 2016).

## II. MATERIALS AND METHODS

**Experimental animals:** The experiments was conducted at the animal house of science College–University of Basrah, where (54) healthy adult males Wistar albino rats (*Rattus norvegicus*), age (12-15) weeks with average weight ( $225 \pm 25$  gm) were used. The animals were kept under unified standard environmental conditions at temperature (24-28°C), 12 hr photoperiod (by the use of two fluorescent lamps) and the humidity rate was about (50 %). They were acclimatized for 3 weeks in polyethylene cages with hygienic bed (6 rats) per cage before the start of the experiment. All rats were fed standard laboratory pellets and clean water was provided by *add libitum*, throughout the experimental period (Al-Mallak, 2004).

**Preparation of Thioacetamide solution and Vitamin D3:** Thioacetamide (TAA) stock powder and Vitamin D3 tablets (10,000) IU were used to prepared the suitable amounts and doses according to the following formula:

$$C1V1 = C2V2 \text{ (C = Concentration, V = Volume)}$$

TAA doses (150) mg/kg /BW were prepared by dissolving (702) mg of (TAA) powder with 18 ml of normal saline to get each (1ml) of prepared solution have (39) mg of TAA according to Wallace *et al.* (2015) and then the calculated doses were done according to body weight (BW) of each rat.

Vitamin D3 doses were prepared by dissolving (1) tablet of vitamin D3 (10,000) IU with (62.5) ml of Dimethyl sulphoxide (DMSO) to get each (0.25) ml of prepared solution have (0.5) µg/100g/BW of vitamin D3 according to Abramovitch *et al.* (2015), then the calculated doses were done according to body weight of each rat.

**Experimental design:** Fifty four adults male rats of about 3 months age, weighting about ( $225 \pm 25$  g) were used in this experiment, rats were separated and divided randomly into (3) equal groups (18 rats in each group) with (6) rats for each period (8, 12, 14) weeks post treated as following:

- 1 **Group one (Control group):** In which rats were injected intraperitoneally (IP) with normal saline (1 ml) twice / week along experiment periods (8, 12, 14) weeks).
- 2 **Group two (liver fibrosis group):** In which rats were injected (IP) with (150) mg/kg/BW of TAA dissolved in normal saline then (1ml) of this solution was given three times / week for 8, 12 and 14 weeks to induced liver fibrosis (Wallace *et al.*, 2015).
- 3 **Group three (treated group):** Rats in this group were injected (IP) with the same dose of (TAA) about 150 mg/kg/BW to induced liver fibrosis, at the same time treated with 0.5 µg/100g/BW of active form vitamin D3 dissolved in DMSO, then (1ml) of this prepared solution given three times weekly for 8, 12 and 14 weeks (Abramovitch *et al.*, 2015).

**Sacrificed the experimental rats:** The experiment continued for (8, 12, 14) weeks, the animals were weighed on zero days (pretreatment) and at the end of the experiment (before scarified), all rats from each group (control, induced and treated) were randomly sacrificed after being anesthetized with overdose of chloroform post each period (8, 12, 14) weeks, the liver was examined for macroscopically observations like pale color, rough surface with spots patches, wrinkle, and congestion, then weighed with an electronic balance, the values expressed as (mean  $\pm$  SD), all samples collected as follow.

**Collection of blood:** Rats in all experimental groups were sacrificed at the end of each periods (8, 12, 14) weeks, after anesthesia with chloroform, suitable cut in the rat abdomen was done, the samples of blood were collected from the heart by heart puncture with use of disposable syringes of (3-5) cc capacity, blood allowed to clot through leaving it at room temperature for (15-30) min, (5) ml of blood was poured into jelly test tubes free from

anticoagulant and centrifuged at 3500 rpm for 10 min to separate serum which then transferred to Eppendorf tubes and stored at -20°C for biochemical tests (Cray *et al.*, 2009).

Serum used to estimate the biochemical parameters such as total cholesterol, HDL – cholesterol, LDL – cholesterol, Triglyceride (TG), VLDL and antioxidants (CAT, GPx, MDA) by spectrophotometer.

**Tissue samples:** Specimens from livers of rats in each experimental group was dissected post (8, 12, 14) weeks, washed with normal saline to removed blood and tissue debris then, cut into suitable size of specimens and transferred to fixed with (10%) formalin fixative to processing for histological examination.

### III. RESULTS

#### Effect of (TAA) and Co-treatment with (TAA) and Vitamin D3 on Lipid Profile Determination in Male Rats

Results showed significant increase ( $P < 0.05$ ) of (TG) and (VLDL) level in liver fibrosis rats group at 12 weeks period compared with the control group, the mean value was reached to (66.53±10.26) and (13.3±2.05) compared to normal value (49.08±6.79) (9.88±1.27) mg/dl respectively.

Data post 14 weeks period recorded significantly increase in (TC, TG, LDL and VLDL) level at ( $P < 0.05$ ) that the mean value was (79.49±9.24), (73.74±11.81), (59.97±8.87) and (14.38±1.81)mg/dl compared to control group that the mean values was (61.22±8.93), (48.68±5.77), (28.88±12.03) and (9.76±1.23) mg/dl while except HDL showed significant decreased at ( $P < 0.05$ ) that the level was (33.89±1.68) in liver fibrosis group (TAA) compared to control rats.

Also results during 14 weeks period revealed to an increased significantly ( $P < 0.05$ ) in (HDL) in rats from (TAA+ vitamin D3) group and compared with control group that the mean value was (48.19±7.9) and (42.23±2.58) mg/dl respectively, but TC, TG, LDL and VLDL showed significant decreased at ( $P < 0.05$ ) compared to TAA group.

**Table 1.** Effect of (TAA) and co-treatment with (TAA) and vitamin D3 on lipid profile determination in male rats

Groups Parameters	TC(mg/dl)	TG(mg/dl)	HDL(mg/dl)	LDL(mg/dl)	VLDL(mg/dl)
Control (8 weeks)	62.23±9.39	49.69±6.53	42.38±4.17	29.78±12.15	9.93±1.3
TAA (8 weeks)	67.9±15.03	53.76±7.77	40.09±5.34	38.54±16.14	10.73±1.54
TAA+V.D (8 weeks)	65.94±5.65	49.11±10.02	47.58±8.57	28.18±14.5	9.81±2
Control (12 weeks)	63.44±10.26	49.08±6.79	41.98±3.79	29.65±12.02	9.88±1.27
TAA (12 weeks)	70.83±6.59	66.53±10.26	38.61±2.29	45.51±9.24	13.3±2.05
TAA+V.D (12 weeks)	66.32±15.28	55.75±4.52	48.19±7.9	27.71±11.57	9.58±1.93
Control (14 weeks)	61.22±8.93	48.68±5.77	42.23±2.58	28.88±12.03	9.76±1.23
TAA (14 weeks)	79.49±9.24	73.74±11.81	33.89±1.68	59.97±8.87	14.38±1.81
TAA+V.D (14 weeks)	57.52±8.18	47.93±9.67	51.76±3.82	16.9±6.16	11.14±0.9

Different letters indicate significant differences among groups at ( $P \leq 0.05$ ).

#### Effect of (TAA) and co-treatment (TAA) and vitamin D3 on serum malondialdehyde (MDA), Glutathione peroxidase (GPx) and Catalase (CAT) in male rats

Our data showed significant increase at (P<0.05) in MDA concentration in (TAA) treated group at 8,12 and 14 weeks compared with control the concentration more significant post 14 weeks that the value was (4.88±1.15) µm/L, moreover treated with vitamin D3 caused significant decrease in MDA level compared to (TAA) group.

Glutathione activity (GPx) was significantly decreased at (P<0.05) in the serum of (TAA) group during experimental period (14) weeks compared to control group that the enzyme level was (1.47± 0.37) and (2.88±0.58) U/L.

Whereas the rats treated with vitamin D3 was given with (TAA) , there was significance increasing in (GPx) enzyme activity compared to (TAA)group post 12&14 weeks periods of experiments the mean level of enzyme was (3.56±0.86, 3.53±0.61, 3.51±0.52)U/L and (2.26±0.51, 1.47±0.37) U/L respectively. (CAT) enzyme activity showed significantly decreased at (P<0.05) in rats of (TAA) group through (12 and 14) weeks post induction, the lowest value was (1.1±0.42) µm/min/ml post 14 weeks of liver fibrosis induction compared to the normal level at the same period (2.41± 0.43) µm/min/ml, moreover vitamin D3 treated subgroup referred to increase in (CAT) enzyme activity compared with TAA group.

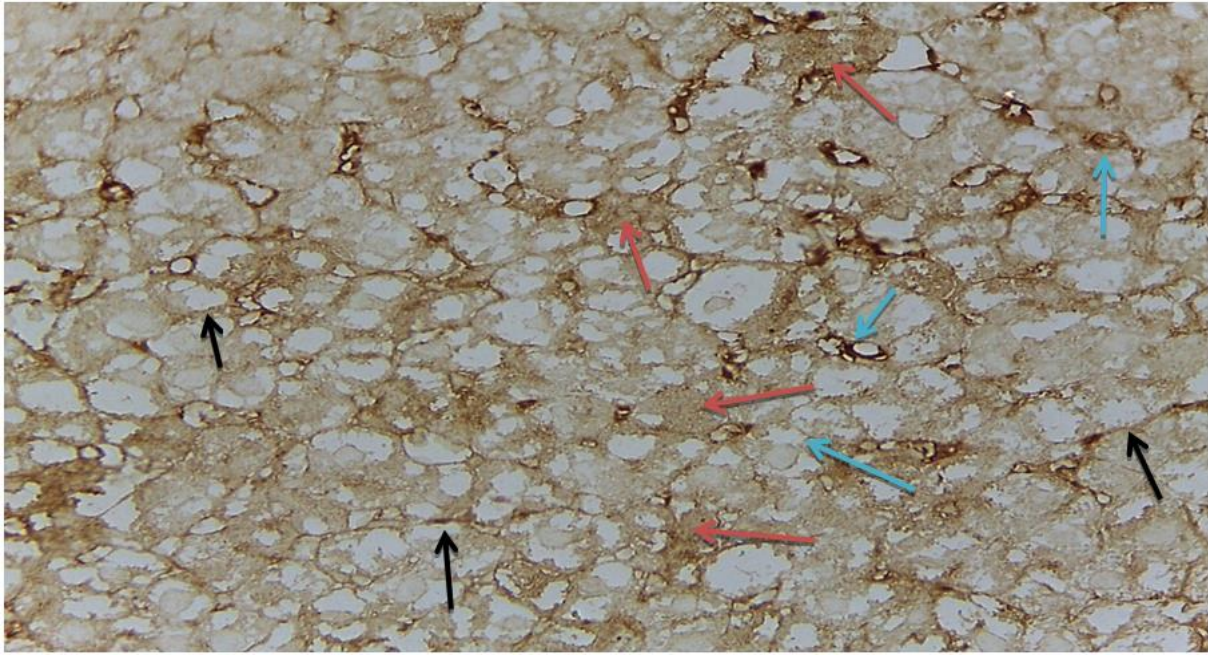
**Table 2.** Effect of (TAA) and co-treatment (TAA) and vitamin D3 on serum malondialdehyde (MDA), Glutathione peroxidase (GPx) and Catalase (CAT) in male rats

Groups Parameters	MDA(µm/L)	CAT(µm/min/ml)	GPx (U/l)
Control (8 weeks)	0.05± 0.08 b	2.42±0.44 ab	2.89±0.59
TAA (8 weeks)	2.42±1.15 a	2.01±0.2 b	2.53±0.85
TAA+V.D (8 weeks)	0.35±0.43 b	2.77±0.2 a	3.56±0.86
Control (12 weeks)	0.06 0.1 b	2.31±0.26 a	2.67±0.55 ab
TAA (12 weeks)	3.66±1.01 a	1.56±0.43 b	2.26±0.51 b
TAA+V.D (12 weeks)	0.11±0.02 b	2.56±0.24 a	3.53±0.61 a
Control (14 weeks)	0.04±0.04 b	2.41±0.43 a	2.88±0.58 a
TAA (14 weeks)	4.88±1.15 a	1.1±0.42 b	1.47±0.37 b
TAA+V.D (14 weeks)	0.12±0.01 b	2.45±0.41 a	3.51±0.52 a

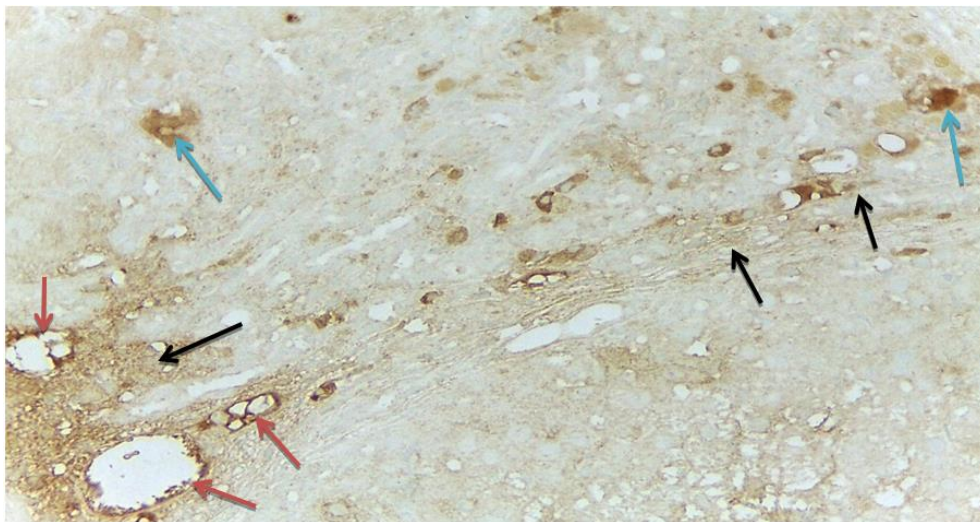
Different letters indicate to significant differences among experimental groups at (P≤0.05).

### Immunohistochemistry examination of MMP-13

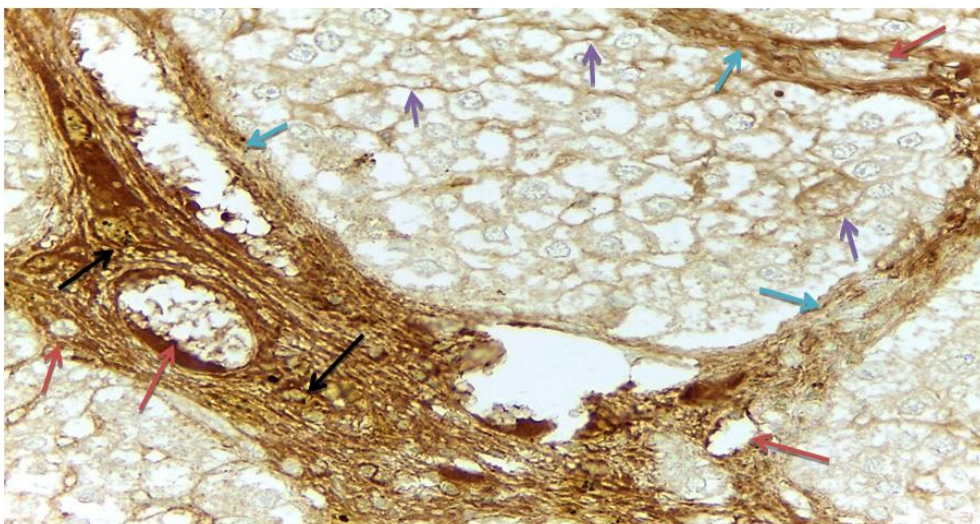
Semi quantitative expression was established by immunostaining of (MMP13) , results referred to normal , equal distribution of this metalloproteinase at hepatocytes cell membranes, kupffer cells and around periportal regions as brownish stain, and this clear, obvious in all sections related to rats liver of control group, in addition positive mild staining in lobules and sinusoids, results also determined the expression of interstitial collagenase (MMP-13) in liver sections from rats with liver fibrosis induced by (TAA) intoxication at various periods (8,12,14) weeks by (IHC) staining, on the other hand sections from recovery phase (treated with VD3 ) during resolution of TAA- induced rat liver fibrosis revealed to an enhanced in MMP13 during these periods (8,12,14) weeks.



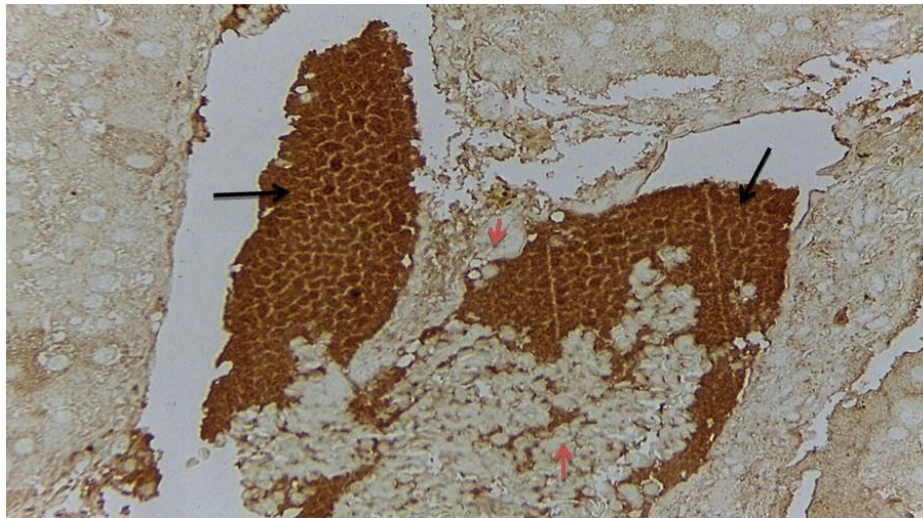
**Fig. 1.** Immunostaining of MMP-13 in liver tissue of control rat showed brown staining at hepatocytes cell membrane ( ), within sinusoids ( ) and kupffer cells ( ).(x10).



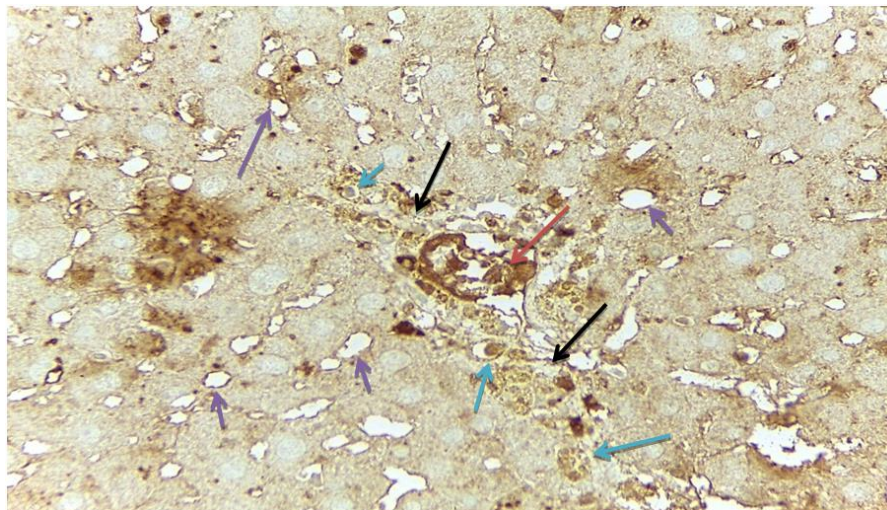
**Fig. 2.** Minimal immunostaining of MMP-13 in liver tissue of liver fibrosis group post (8) weeks of induction showed positive staining of MMP-13 on extracellular matrix ( ), around portal ducts ( ) and macrophage( ).(x10)



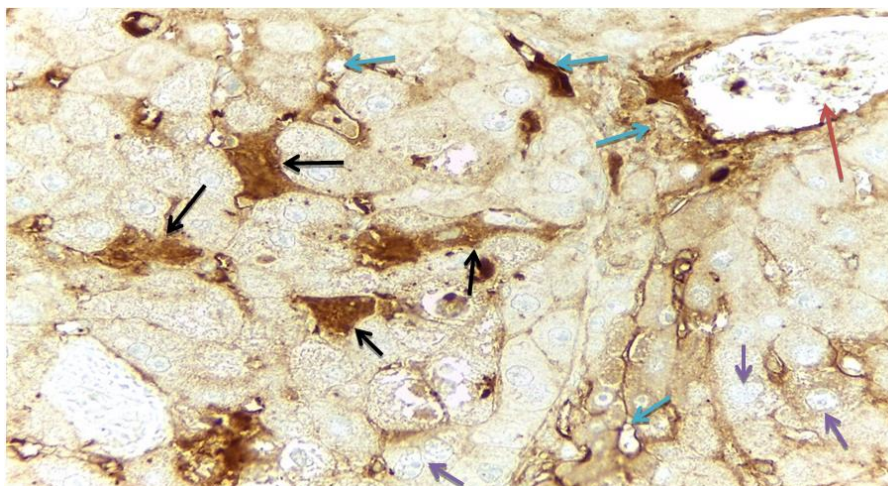
**Fig. 3.** Immunostaining results of MMP-13 in liver tissue of the group post (12) weeks of liver fibrosis induction showed positive strong staining in extracellular matrix ( ), around portal ducts ( ) within thick fibers ( ) and around hepatocytes ( ). (x40).



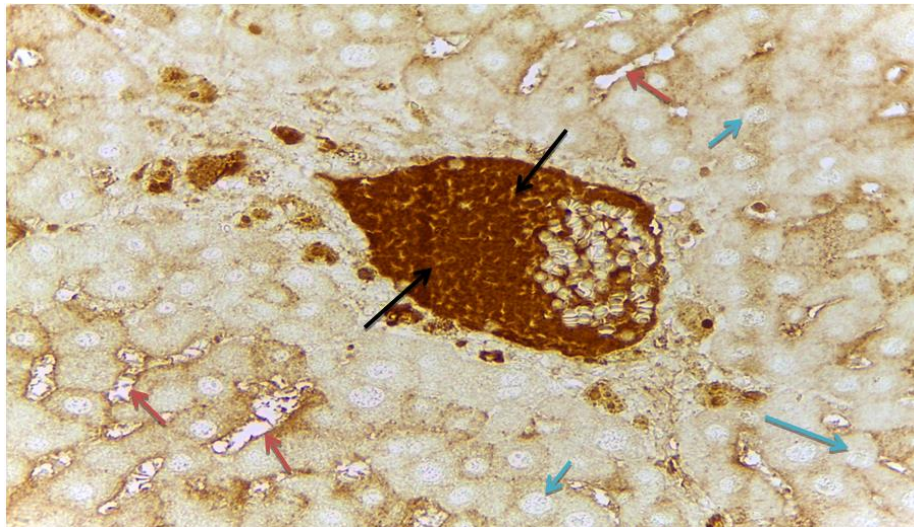
**Fig. 4.** Section in rat liver post (14) weeks of fibrosis induction stained immunohistochemically showed positive staining of MMP-13 in hepatocytes ( ) and tissue fragments ( ) (x40).



**Fig. 5.** Immunostaining result of liver tissue from rat treated with (VD3) post (8) weeks of liver fibrosis showed moderate staining of MMP-13 within extracellular matrix ( ), portal duct ( ), macrophages ( ) and hepatocytes boundaries ( ).(x40)



**Fig. 6.** Immunostaining result on MMP13 in liver tissue from the group treated with (VD3) post (12) weeks of liver fibrosis showing dense stain in the mesenchymal cells ( ), around the portal duct ( ), in the extracellular matrix ( ) and hepatocytes boundaries ( ).(x40).



**Fig. 7.** Immunostaining result on MMP13 in liver tissue from the group treated with (VD3) post (14) weeks of liver fibrosis showing strong positive stain ( ) in portal duct, within sinusoids ( ) and normal negative stain of hepatocytes. (x40).

#### IV. DISCUSSION

The increase in the level of (MDA) observed in the various target organs could be linked to the generation of free radicals, resulting in the peroxidation of membrane lipids (Macdonald *et al.*, 2010).

Antioxidant enzymes are sensitive to cells severe damage, the decrease in SOD, GPx, and CAT levels indicates severe liver injury, therefore, antioxidant activity and the inhibition of reactive oxygen species (ROS) production are important in preventing hepatopathies, the body has effective defense mechanisms to prevent and neutralize free radicals, this action is accomplished through regulating endogenous antioxidants such as GPx, SOD, and CAT, the balance between ROS production and antioxidant defense system of these enzymes is disturbed as a result of oxidative stress which disrupts cellular functions and causes liver damage and necrosis (Mahmood zadeh *et al.*, 2017).

Our study in agreement with other recent research pointed that liver fibrosis lead to significantly intensified serum level of TC, TG and LDL-C, while it significantly declined serum HDL-C when compared to the normal control, that CCl4 increased lipid profile through cellular oxidative stress, and the free radicals derived from this toxic substance causes hepatic lesions, increase of oxidative stress enhances the influence of non-essential fatty acids, which in turn, increase the serum and tissue levels of TC and TGs this elevation of lipid biomarkers and accumulation of fat vacuoles reflect the liver function impairment, particularly on lipid metabolism and led to deposition of lipid droplets resulted liver steatosis (Abdel-Sattar *et al.*, 2020).

Hepatic lipid accumulation is the result from an imbalance by increased lipid availability, increased circulating free fatty acid (FFA) uptake or de novo lipogenesis and decreased lipid disposal (reduced FA oxidation or TG-rich lipoprotein secretion) accompanied with lipoperoxidative stress and hepatic injury, 1,25(OH)2D3 against HFD-induced hepatic steatosis is related to the inhibition of lipogenesis and the promotion of FA oxidation in rat liver (Yin *et al.*, 2012).

Endo *et al* (2011) found that MMP-13 play a critical role in regression process of hepatic cirrhosis, MMP-13 has a highly specific ability to degrade insoluble fibrillar type 1 collagen in human and rodents, it reduced severe fibrous bands in CCL4 induced hepatic cirrhosis via induction of MMP-2 and MMP-9 following an increase in exogenous MMP-13 expression and this play critical role in matrix pathophysiology depending on stage of liver fibrosis. VDR was highly expressed in quiescent HSCs, its expression decreased up to 40% during activation, addition of 1, 25(OH)2D3 to activated HSCs stimulated VDR expression, vitamin D3 suppressed HSC proliferation and tissue inhibitor metalloproteinase 1 (TIMP-1) and lead to a down regulation of collagen Ia1

expression, treatment with 1,25 (OH)2D3 significantly reduced (ECM) deposition and lowered the fibrotic score in TAA-induced liver fibrosis (Abramovitch *et al.*, 2011).

## V. CONCLUSION

Present results referred to vitamin (D3) as bioactive, protective agent reduced the complications of liver fibrosis and regarded it as important factor in liver parenchyma regeneration and repairing ,Matrix Metalloproteinase 13(MMP-13) level associated with liver fibrosis and regarded it as diagnostic factor, its level alter during (8,12,14) weeks post fibrosis induction, Strong association between pathophysiological parameters changes and liver fibrosis and cirrhosis was established such as lipid profile (TC,TG,HDL,LDL,VLDL), antioxidative enzymes(MDA, CAT, GPx).

## REFERENCES

- 1 Abramovitch, S., Dahan-Bachar, L., Sharvit, E., Weisman, Y., Tov, A. B., Brazowski, E., & Reif, S. (2011). Vitamin D inhibits proliferation and profibrotic marker expression in hepatic stellate cells and decreases thioacetamide-induced liver fibrosis in rats. *Gut*, 60(12), 1728-1737.
- 2 Abramovitch, S., Sharvit, E., Weisman, Y., Bentov, A., Brazowski, E., Cohen, G., & Reif, S. (2015). Vitamin D inhibits development of liver fibrosis in an animal model but cannot ameliorate established cirrhosis. *American Journal of Physiology-Gastrointestinal and Liver Physiology*, 308(2), G112-G120.
- 3 Al-Malak, M. (2004). Histopathological and Histochemical of small intestine infected with giardiasis in human and experimental models. PHD. Thesis.
- 4 Abdel-Sattar, A.R., Abo-Saif, A.A., & Aboyoussif, A.M. (2020). Nicorandil and atorvastatin attenuate carbon tetrachloride-induced liver fibrosis in rats. *Immunopharmacology and Immunotoxicology*, 42(6), 582-593.
- 5 Cray, C., Rodriguez, M., Zaias, J., & Altman, N.H. (2009). Effects of storage temperature and time on clinical biochemical parameters from rat serum. *Journal of the American Association for Laboratory Animal Science*, 48(2), 202-204.
- 6 Endo, H., Niioka, M., Sugioka, Y., Itoh, J., Kameyama, K., Okazaki, I., & Watanabe, T. (2011). Matrix metalloproteinase-13 promotes recovery from experimental liver cirrhosis in rats. *Pathobiology*, 78(5), 239-252.
- 7 Giannandrea, M., & Parks, W.C. (2014). Diverse functions of matrix metalloproteinases during fibrosis. *Disease models & mechanisms*, 7(2), 193-203.
- 8 Mahmoodzadeh, Y., Mazani, M., & Rezagholizadeh, L. (2017). Hepatoprotective effect of methanolic *Tanacetum parthenium* extract on CCl4-induced liver damage in rats. *Toxicology reports*, 4, 455-462.
- 9 Macdonald, I.O., Olusola, O.J., & Osaigbovo, U. A. (2010). Effects of chronic ethanol administration on body weight, reduced glutathione (GSH), malondialdehyde (MDA) levels and glutathione-s-transferase activity (GST) in rats. *New York Science Journal*, 3(4), 3947.
- 10 Roderfeld, M. (2018). Matrix metalloproteinase functions in hepatic injury and fibrosis. *Matrix Biology*, 68, 452-462.
- 11 Robert, S., Gicquel, T., Victoni, T., Valença, S., Barreto, E., Bailly-Maître, B., & Lagente, V. (2016). Involvement of matrix metalloproteinases (MMPs) and inflammasome pathway in molecular mechanisms of fibrosis. *Bioscience reports*, 36.
- 12 Wallace, M.C., Hamesch, K., Lunova, M., Kim, Y., Weiskirchen, R., Strnad, P., & Friedman, S.L. (2015). Standard operating procedures in experimental liver research: thioacetamide model in mice and rats. *Laboratory animals*, 49(1\_suppl), 21-29.
- 13 Yin, Y., Yu, Z., Xia, M., Luo, X., Lu, X., & Ling, W. (2012). Vitamin D attenuates high fat diet-induced hepatic steatosis in rats by modulating lipid metabolism. *European journal of clinical investigation*, 42(11), 1189-1196.