

## ORIGINAL ARTICLE

# The Toxic Effect of Oral Gavaged of Sodium Benzoate (SB) on Adult Male Rabbits

Nawras A. Alwan<sup>1</sup>, Alia M. Kudayer<sup>2</sup>, Eman Aboud Al-Masoudi<sup>1</sup>

<sup>1</sup> Department of Physiology, Pharmacology and Chemistry, College of Veterinary Medicine, University of Basrah, Basra, Iraq

<sup>2</sup> Department of Anatomy and histology, College of Veterinary Medicine, University of Basrah, Basra, Iraq

## ABSTRACT

**Introduction:** A common problem throughout the history has been food spoilage and most of this spoilage is caused by the microorganism's activity or reactions enzymatically during the food storage. Therefore, using of chemical materials that prevent or/ and delay spoilage of foods and may led to great success of these compounds against wide ranges of pathogens. Sodium benzoate (SB) is one of the synthetic additives that are widely used in the food industry. This research was aimed and designated to detect the negative impact of long inoculation the benzoate of sodium (SB) on lung and heart histology in rabbits. **Methods:** : Twelve animals were randomly divided into two groups, 6 rabbits/group. G1: (Control group) administrated distilled water only, group 2: inoculated by SB (120 mg / kg BW/ day) for thirty days. **Results:** T: in the results appeared a significant increase of plasma MDA and liver enzymes values combined with sharp decrease ( $P < 0.05$ ) of GPx in rabbits after prolong inoculation of SB. Histologically, noticeable cytopathic effects were recorded in tissues of lungs and heart of rabbits in SB group contrast to control. **Conclusion:** It can be concluded that the long-term consuming of SB can cause a serious cellular damage in the vital organs that affecting liver and kidneys function which consequently threating health status of human and animals.

**Keywords:** Sodium benzoate, Vitamin C, Lungs, Heart, Liver enzymes

## Corresponding Author:

Nawras A. Alwan, HIGH EDUCATION QUALIFICATION? PHD? MASTER?

Email: nana.alwan98@gmail.com

Tel: +942-07800417760

## INTRODUCTION

Sodium benzoate (SB) is one of the synthetic additives that are widely used in the food industry (1). The neutralization of benzoic acid with sodium hydroxide was produced the sodium benzoate. Benzoate of sodium is mainly used as a preservative in beverages, fruit products, chemically leavened, baked goods and condiments. The disadvantage of SB is the off-flavor that the importance of many foods a reason due to their have inhibitory effects on yeast, so it couldn't used in products of yeast-leavened (2). Nevertheless, SB is recommended as a preservative for numerous food products at an optimum level (0.1-0.5%) in different countries (3,4). Sodium benzoate is used preferably as a preservative at pH range of (4-5) in many food products (2, 4). Despite

the wide use of SB in preserved or processed food products, a serious adverse effect has been reported that threaten human health (5). Therefore, the designated this study to highlight the further negative effects of S.B as a food additive on the tissues and the liver enzymes of as a vital biomarkers of adult rabbits.

## MATERIALS AND METHODS

### Animals and their housing:

Twelve adults of male rabbits weighted about (205.00 ± 19.00 g) used in this research, and kept in house of animal for the College of Veterinary Medicine, University of Basrah, Iraq under constant condition of environment for two weeks to acclimatization at the experiment before beginning. Ad libitum, the food and drinking water were provided throughout the experiment.

### Experimental Design:

Animals (male rabbits) randomly were divided into 2 groups as following:

**G 1 (control group):** 6 adult male rabbits given distilled water (4 ml/animal/day) orally by gavage for thirty days.  
**G 2 (S.B group):** 6 adult male rabbits given S.B (120 mg/Kg BW/ daily) (6) dissolved in 4 ml distilled water orally by gavage for thirty days (7).

**Blood samples Collection:**

In the end of study (at day 31), the rabbits were euthanized by diethyl-ether. The collection of blood samples directly by cardiac-puncture putting in clean dry test tube after centrifugation separated the serum and stored at (-20°C) till biochemical analyses. Lungs and heart organs were severed immediately and fixation in 10% neutral buffered formalin for histological study (8).

**Measurements of biochemical parameters:**

Some biochemical parameters were measurements in the serum by using especially enzymatic kits as follow: Measurements of serum Malondialdehyde (MDA): Malondialdehyde is the main end product of lipid peroxidation will be implemented on the serum as described by Yagi (9), this method based on measure by the spectrophotometer. Thiobarbituric-Acid (TBA.) which reacts with malondialdehyde for form formation Thiobarbituric-acid substance reactively.

**Measurements of Glutathione Peroxidase activity (GPX):**

This enzyme glutathione peroxidase is determined by assay GPx kit (10).

**Estimation of Aspartate aminotransferase (U/I) and Alanine aminotransferase (U / I):** these parameters were measured by special kits (11-13).

**Estimation of Serum alkaline-phosphatase (U/I):** This method was doing by use the colorimetric determination of alkaline phosphatase (ALP) activity (14,15).

**Statistical-Analyses:** Statistical analyses were done by the AVOVA. All the results were expressed as (mean ± standard deviation) (M± SD.). Means of the all groups were compared using independent T-test. ‘p’ value of ≤0.05 was considered statistically significant changes (16).

**RESULTS**

The effects of 30 days oral administrated of SB on adult male rabbits are represented in Tables (I and II). The levels of serum peroxidation of lipid constituted by (MDA) were increment significantly (p < 0.05) in SB. group comparison to control group and also a significant (p < 0.05) decrement in GPX activity was recorded mainly in SB. group in contrast to control group (Table I).

Effect of 30-days oral administration of SB on

**Table I: The effects of 30 days oral administrated of SB on adult male rabbits (The levels of serum peroxidation of lipid constituted by (MDA))**

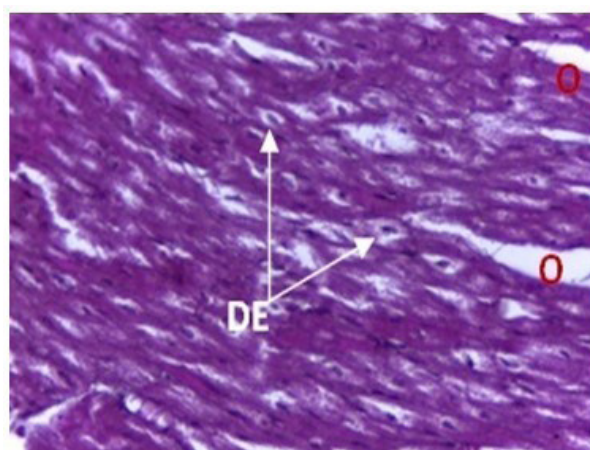
Parameters	MDA.	GP <sub>x</sub> .
Groups	(U/I)	(U/I)
(no.=6)		
G1 (Cot)	5.65 ± 0.30 <sup>b</sup>	374.66 ± 20.23 <sup>a</sup>
G2 (SB. 120mg)	9.61 ± 0.75 <sup>a</sup>	285.20 ± 13.88 <sup>b</sup>

**Table II: Effect of 30-days oral administration of SB on concentrations of ALT, AST and ALP in serum**

parameters	ALT	AST	ALP
Groups	(U / I)	(U / I)	(U / I)
(n=6)			
G1 (Cot)	20.40± 5.00 <sup>b</sup>	25.02± 4.13 <sup>b</sup>	15.93± 2.32 <sup>b</sup>
G2 (SB. 120mg)	36.69± 6.54 <sup>a</sup>	41.67± 5.43 <sup>a</sup>	20.77± 1.80 <sup>a</sup>

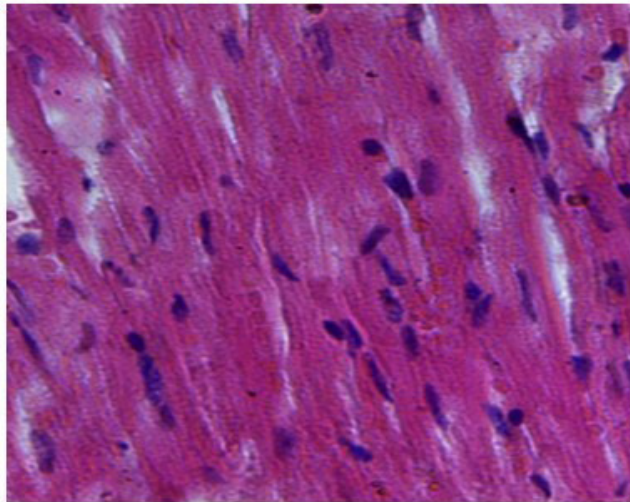
concentrations of ALT, AST and ALP in serum showed in (Table II). The data of results have indicated that were significantly (p < 0.05) increases in concentrations of these parameters in SB-group (G2) compared to G1 (cot-group).

Histopathologically, the results in the present-study revealed marked cellular changes in heart and lungs tissues of rabbits after prolong oral administration of SB. Swelling of myocardial cell, inflammatory cells infiltration, and interstitial oedema and myocytic degeneration with small size nucleoli were dominantly observed in the heart tissues of SB group (Fig. 1). However, normal myocyte and fibers arrangement have

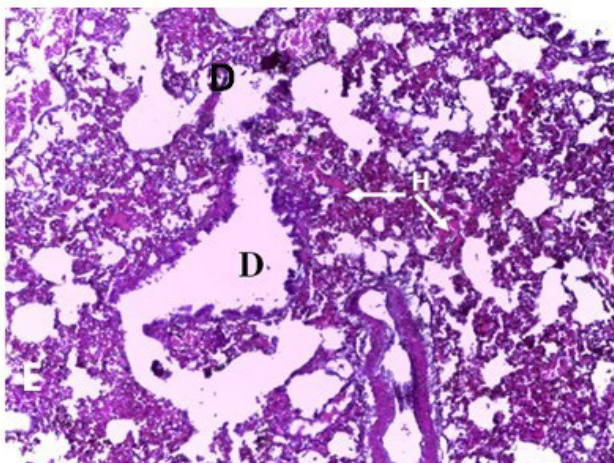


**Fig 1: The heart tissues of SB group**

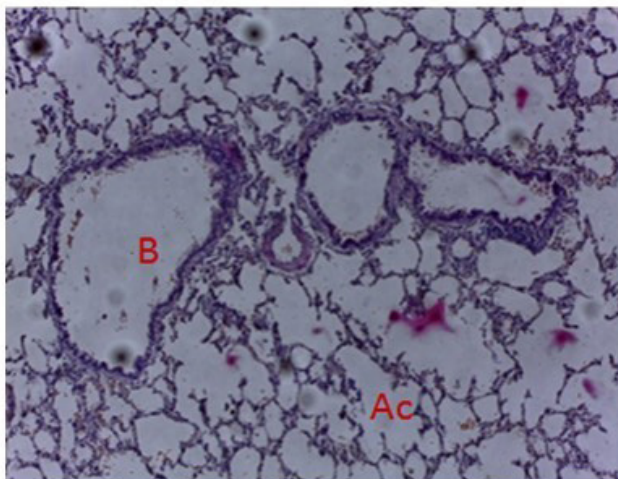
seen in control group (Fig. 2). Bronchial and alveolar dilation were also observed in lung tissues of SB group combined with hemorrhage in alveolar wall, profuse inflammatory cell infiltration into alveolar lumen and bronchiole, in addition to the appearance of exudates in the lumen of alveolar wall (Fig. 3). While control group has appeared normal in all the histological structure (Fig. 4).



**Fig 2: The normal myocyte and fibers arrangement**



**Fig 3: The lumen of alveolar wall**



**Fig 4: The histological structure**

## DISCUSSION

Nowadays, SB is used widely as preservative in the food and in industries of pharmaceutical and cosmetics as a synthetic additive. As a chemical product, SB has disadvantages by inducing many cellular damages that threat human and animal's health. Recently, numerous studies were that make on the use of ingredients naturally with many different-goals in the foods and have achieved for many success, but there is still need for more study and research on food industry (1, 17). Here in the present study revealed the effect of SB on liver enzymes and on tissues of heart and lung in laboratory rabbits. The advantages used of the rabbit as a model are as follows this animal is very docile and non-aggressive, and therefore easy to handle and monitor. They are bred on a large scale and are very economical compared to the cost of large animals.

A significant increase of MDA concentration in group administered orally with SB is often due to oxidative stress condition. In fact that the lipid peroxidation increased under diabetic and other conditions can be resulted from this combination leading to increase cellular oxidative stress as a result of depletion the antioxidant scavenger system. These changes cause the increase of MDA and decrease of SOD and CAT (Antioxidants enzymes) (18). This finding indicates increased lipid peroxidation that is producing from breakdown of poly unsaturated fatty-acids and also considered as one of the manifestations of freely radicals which induced cytotoxicity. This result is compatible with the results of Dibnath & Mandal (19) and Ojo et al. (20) who reported increase levels of MDA in serum and testis of male rat's administered by SB.

Based on the results of the current study, serum levels of AST and ALT were found to be significantly elevated suggesting alteration in the function of liver and kidneys after prolonged SB consuming. Similar findings have reported by Oyewole et al. (21). Moreover, the elevation of serum ALT and AST reflect a liver damage because these enzymes assessed for liver function. Metabolism of sodium benzoate may be occurs by living organisms can ultimately make an active compound which is reacts with DNA that leads to genetically changes of cells structure and it has adverse effects on division of cells (22- 25).

Exposure in a short-term to SB can lead to skin irritation and also in eyes and respiratory tract, while repeated contact or/and prolonged may produce high skin sensitization (26). Thus, using high doses of SB might release prostaglandin and histamine, changes in gastric mucus secretion and induce gastric ulcers (27, 28). Researches have also reported the reaction between benzoic acid and ascorbic acid in the presence of metal catalysts in soft drinks and fruit juices that leads to the formation of benzene (29). For humans, urticaria, rhinitis, asthma or anaphylaxis have been reported

following inhalation, oral or dermal exposure to benzoic acid or sodium benzoate. The symptoms shown shortly after exposure and disappeared after and within a few hours (30- 32).

Microscopically examination of histological section of heart and lung organs revealed marked cellular changes in these tissues in female rabbits after prolong oral administration of SB. include swelling of myocardial cell, inflammatory cells infiltration, and interstitial oedema and myocytic degeneration with small size nucleoli were dominantly observed in the heart tissues of SB group (Fig. 1 and 2). These results may be due to the ROS which responsible of to damaging all cellular macromolecules including the polyunsaturated fatty acids, carbohydrate of membrane proteins and DNA potentially producing impairment of cellular functions (33). The cellular membrane of lung and heart are rich in poly unsaturated fatty acids, therefore they are susceptible to oxidative stress and sensitive to ROS (34). These results also similar to that reported by Bakar and Aktac (35) showed when compared to control group, vacuolation and nucleus losses, pyknotic nuclei, irregular hepatocyte cell columns, hypertrophic hepatocyte, degeneration and disorganization of histological section mainly liver and also observed membrane injury in the apical surface of tubular cells and tubular cells lost nuclei, degeneration of glomerular structure, basal membrane injury and visceral epithelial injury showed in renal section. These results agreed with previous studies have shown that administration of SB could alter the histological architecture for different organs: like Kehinde et al. (36) reported that the histological section of testes appeared alter in sperm quality and function, the histological section of testes in group treated with SB showed distorted spermatogenic cells and seminiferous tubules, deleterious basement membrane with lumen vacuolation while the group treated with combination of SB and Vit.C appeared disrupted of basement membrane, hyperplasia of Sertoli cells, deleterious lumen, degeneration of interstitium and disruption of spermatogenic cells while in group treated with Vit.C only showed normal testicular tissues with hyperplasia of Sertoli cells.

Several studies criminalize sodium benzoate to be responsible for hyperactivity in children (37), genotoxicity (38), teratogenicity and high mortality in zebrafish fetuses (39). In addition, it can also cause cirrhosis in many tissues (40), muscle damage and cancer (41) and lead to altered morphological structure of lymphocytes and membrane damage in mice (42). These alterations in the tissues may be also due to increase the lipid peroxidation and produce large amounts of ROS and RNS as free radicals lead to increase the activity of antioxidative systemic action as a causes described by Mazin et al. (43) and Khodaei et al. (45)

## CONCLUSION

The long-term consuming of SB has a serious adverse effect represented by inducing a cellular damage that affecting liver and kidneys function. Therefore, irregular consuming of SB's preserved or processed food should be controlled and more deep studies should be urgently attempted to find safer and/or natural food additive for maintaining human and animal's health status.

## ACKNOWLEDEMENT

We need to thank you for our appreciation to all staff in the Biochemistry lab. and Histopathology laboratories, Veterinary Medicine College, Basra University in assistance for technical and also we need for many gratitude and thanks to Assist. Prof. Dr. Wessam Monther Mohammed Saleh who cooperated with us for completely this research. This project was supported by researchers own selves.

## REFERENCES

- 1- Shahmihammadi M.; Javadi M. and Nassiri-Asl, M. An Overview on the Effects of Sodium Benzoate as a Preservative in Food Products. *Biotech. Health. Sci.* 2016. In press (In press):e35084.
- 2- Friedman L.J. and Greenald C.G. Food additive. In: *kroschwitzJ, Howe-Grant M., Eds. New York, NY, Wiley and sons. 1994; Pp: 805-833.*
- 3- Ibekwe S.E.; Uwakwe A.A. and Monnv M.O. Effect oral intake of sodium benzoate on some hematological parameter of Wister albino rats. *Sci. Res. Essays.* 2007; 2:006-009.
- 4- Tawfek N.; Amin H.; Abdalla A. and Fargali S. Adverse effects of some food additives in adult male albino rats. *Curr. Sci. Intern.* (2015); 4(4): 525-537.
- 5- Kubota K. and Ishizaki T. Dose-dependent pharmacokinetics of benzoic acid following oral administration of sodium benzoate to humans. *Euro. J. of Clini. Pharm.* 1991; 41:363-368.
- 6- Ibekwe S.E.; Uwakwe A.A. and Monnv M.O. Effect oral intake of sodiumbenzoate on some hematological parameter of Wister albino rats. *Sci. Res. Essays.* 2007; 2:006-009.
- 7- Khan I.S; DarK. B.; Ganie, Sh. A. and Ali N. Toxicological impact of sodium benzoate on inflammatory cytokines, oxidative stress and biochemical markers in male Wistar rats. *Drug and chemical toxicology.* (2020).<https://www.researchgate.net/deref/https%3A%2F%2Fdoi.org%2F10.1080%2F01480545.2020.1825472>
- 8- Luna L.G. Manual of; histologic staining methods of the armed forces institute of pathology. 3 rd. ed. McGraw-Hill, New York, NY. 1968.
- 9- Yagi K. Serum malondialdehyde measurements. *Free Rad. Antiox. Prot.* 1998; 108:101-106.
- 10- Flohй L. and Gьnzler W.A. Assays of glutathione

- peroxidase. *Metho. Enzymol.* 1984;105:114-121.
- 11- Schumann, G. and Klauke, R. New IFCC reference procedures for the determination of catalytic activity concentrations of five enzymes in serum: Preliminary upper reference limits obtained in hospitalized subjects. *Clin. Chim. Acta*, 2003; 327(1-2): 69-79.
  - 12- Tietz, N.W. *Textbook of clinical chemistry*. 3rd ed. C.A. Bruits E.R. Ashwood W.B. Saunders, 1999; Pp.:676-684.
  - 13- Young R.J.C. *Foucault on race and colonialism*. New Form. 1995; 25:57-65.
  - 14- Tietz N.W. *Clinical guide to laboratory test*. 4th ed. Publ. U.S. 2006; 638-9ET: 1062-1065.
  - 15- Tietz N.W. *Textbook of clinical chemistry*. 3rd ed. C.A. Bruits E.R. Ashwood W.B. Saunders. 1999 ; Pp.:676-684.
  - 16- Abo-Allam R.M. *Data statistical analysis using SPSS Program*. 1st ed. Publ. for the U. Cairo. 2003
  - 17- Anand S.P. and Sati N. Artificial preservative and their harmful effects: looking toward nature for safer alternatives. *Anand and Sati, IJPSR*. 2013; 4(7): 2496-2501.
  - 18- Hussein H.K.; Elnaggar M.H. and Al-Dailamy J.M. Protective role of vitamin C against hepatorenal toxicity of fenvalerate in male rats. *Glob. Adva. Res. J. of Envir. Sci. and Toxic.* 2012; pp.: 60-65.
  - 19- Dibnath, D. and Mandal, T.K. Study of Quinalphos (An Environmental estrogenic insecticide) formulation induced change of testicular tissue and antioxidant defense system in Sprague-Dewley Albino rats. *J. of Applied. Toxicol.* 2000; 20:197-204.
  - 20- Ojo O.O.; Kabuta F.R.; Bello M. and Babayo V. Inhibition of paracetamol-induced oxidative stress in rats of extracts of lemongrass (*Cymbrogeon citratesl* and free tea (*Camellia sincnsis*) in rats. *Afr. J. of Biotech.* 2006; 5:1227-1232.
  - 21- Oyewole O.I.; Dere F.A. and Okoro O.E. Sodium benzoate mediated hepatorenal toxicity in wistar rat: modulatory effects of *Azadirachat indica* (Neem) leaf. *Euro. J. of Med. Plan.* 2012; 2(1):11-18.
  - 22- Afshar M.; Moallem S.A.; Taheri M.H.; Shahsavan M.; Sukhtanloo F. and Salehi F. Effect of long term consumption of sodium benzoat before and during pregnancy on growth indexes of fetal balb/c mice. *Mod Care J.* 2013; 9(3):173–180.
  - 23- Beyoglu D. and Idle J.R. The glycine deportation system and its pharmacological consequences. *Pharmacol. Ther.* 2012; 135(2):151–167.
  - 24- Toth B. Lack of tumorigenicity of sodium benzoate in mice. *Fundam. Appl. Toxicol.* 1984 ;4(3 Pt 1):494–6. [PubMed: 6745539].
  - 25- Oyanagi K.; Kuniya Y.; Nagao M.; Tsuchiyama A. and Nakao T. Cytotoxicities of sodium benzoate in primary culture of hepatocytes from adult rat liver. *Tohoku. J. Exp Med.* 1987; 152(1):47–51.
  - 26- do Nascimento F.I.; Schosler P.; Santos F.L.; Melecchi M.I.; Rodrigues Vale M.G. and Bastos Caramao E. Selective extraction of benzoic acid from landfill leachate by solid-phase extraction and ion exchange chromatography. *J. Chromatogr. A.* 2004; 1027(1-2):167–70. [PubMed: 14971499].
  - 27- Kreindler J.J.; Slutsky J. and Haddad Z.H. The effect of food colors and sodium benzoate on rat peritoneal mast cells. *Ann Allergy.* 1980; 44(2):76–81. [PubMed: 6153872].
  - 28- Schaubsluger W.; Becker W.M.; Schade U.; Zabel P. and Schlaak M. Release of mediators from human gastric mucosa and blood in adverse reactions to benzoate. *Int. Arch. Allergy Immunol.* 1991; 96(2):97–101.
  - 29- Gardner L.K. and Lawrence G.D. Benzene production from decarboxylation of benzoic acid in the presence of ascorbic acidanda transition-metal catalyst. *J. Agric. Food Chem.* 1993; 41(5):693–5.
  - 30- IUCLID. IUCLD Data Sheet: benzoic acid, creation date: 23/10/95. 1996; pp.: 63.
  - 31- IPCS. Benzoic acid and sodium benzoate, CICAD number 26. Published by the World Health Organisation, Geneva. 2000; ISBN 92 4 153026 X.
  - 32- Oyewole O.I.; Dere F.A. and Okoro O.E. Sodium benzoate mediated hepatorenal toxicity in wistar rat: modulatory effects of *Azadirachat indica* (Neem) leaf. *Euro. J. of Med. Plan.* 2012; 2(1):11-18.
  - 33- Al-Damegh M.A. Stress-induced changes in testosterone secretion in male rats: role of oxidative stress and modulation by antioxidants open. *J. of Ani. Sci.* 2014; 4:70-78.
  - 34- Ghosh D, Das VB, Mallick M and Debnath I. Testicular gametogenic and steroidogenic activities in cyclophosphamide treated rats: A correlative study with testicular oxidative stress. *Drug Chem. and Toxic.* 2002; 25:282-292.
  - 35- Bakar E and Aktac, T. Effect of sodium benzoate and citric acid on serum liver and kidney tissue total sialic acid level an ultrastructure study. *J. Appl. Biolsci.* 2014; 8(2):9-15.
  - 36- Kehinde OS, Christianah OI. and Oyetunji OA. Ascorbic acid and sodium benzoate synergistically aggravates testicular dysfunction in adult Wistar rats *Int. J. Physiol. Pathophysiol. Pharmacol.* 2018; 10(1):39-46.
  - 37- Beezhold BL, Johnston CS, Nochta KA. Sodium benzoate-rich beverage consumption is associated with increased reporting of ADHD symptoms in college students a pilot investigation. *J. Atten. Disord.* 2014;18:236–241.
  - 38- Pongsavee M. Effect of sodium benzoate preservative on micronucleus induction, chromosome break, and Ala40Thr superoxide dismutase gene mutation in lymphocytes, *Biomed. Res. Int.* 2015:1-5.
  - 39- Chen Q, Huang N, Huang J, Chen S, Fan J, Li J Ch, and Xie F. Sodium benzoate exposure downregulates the expression of tyrosine hydroxylase and

- dopamine transporter in dopaminergic neurons in developing Zebrafish. *Birth Defects Res.* 2009; (Part B) 86:85–91.
- 40- Kaboğlu A. and Aktaz TA. Study of the effects of the sodium benzoate on the mouse liver. *Biol Brat.* 2002; 57(3): 373-80.
- 41- Johnson W, Bergfeld WF, Belsito DV, Hill RA, Klaassen CD, Liebler DC, Marks JG, Shank R C, Slaga Th J, Snyder P W, and Andersen FA. Safety assessment of benzyl alcohol, benzoic acid and its salts, and benzyl benzoate. *Internat. J of Toxicol.* 2017; 36(Supplement 3) 5S-30S.
- 42- Redouane D, Bouferkas Y, Bouferkas Y, Guendouz M. and Guendouz M. Assessment of a sub-chronic consumption of sodium benzoate (E211) on male reproductive functions in Swiss mice. *Biosciences Res.* 2019;16(1):287-298.
- 43- Mazin, Sh.; Alwan, N.A. and Al-Masoudi, E.A. A study of toxic effect of sodium benzoate, Vit.C alone and their combination on reproductive functions of adult male rabbits. *Basrah J. of Veteri. Res..* 2018; 17(3): 533-543.
- 44- Khodaei F, Kholghipour H, Hosseinzadeh M, Rashedinia M. Effect of sodium benzoate on liver and kidney lipid peroxidation and antioxidant enzymes in mice. *J. Rep. Pharma. Sci.* 2019; 8:217-223.