

# The impact of ZnO Nanoparticles on the liver and lung tissues in mice

**Azhar Abdul Jabbar Ameen**

*College of Sciences, Department of Biology, Basrah University, Iraq.*

---

## Abstract

According to the distinctive physical and chemical properties, nanoparticles were used in several care products, cosmetics, sunscreens, drug delivery systems, and for therapeutic purposes, among the most common nanotechnology in consumer and medical products are (ZnO NPS), so aimed the present study to investigate an inflammatory impact of ZnO NPs on the mice's liver and lung. Materials and methods: it used twelve male mice of *Mus musculus*, injected (i.p) a treated group with ZnO NPS (400 mg/kg) for 20 days, as for the control was injected with 0.5 ml of physiological solution 20 days. Results: ZNO NPS caused infiltration of inflammatory cells in different areas of both liver and lung tissues, significantly increased mmp12 gene expression in both the tissue of liver and lung. From these results, we can conclude that the zinc oxide nanoparticles caused a histopathological change in the liver and lung thus its inflammatory effect is obvious tissue through the infiltration of inflammatory cells.

Keywords: ZnO NPS, gene expression, tissue, inflammatory cell

## 1-Introduction:

A human can exposure to ZnO nanoparticles in professional environments via the ZnO synthesis, industrialization of ZnO products, and also through consumers products, therefore it is necessary to know and recognize the harmful effects that ZnO NPS can cause (Niels et al, 2019).

The nanoparticles size ranges about 1-100 nanometers, that have a diameter mean and their dimensions about 10-9 nm and because of their small size, they have many important features such as physical, electric, chemical, mechanical, as well as magnetic characteristics, for example, they able to enter freely to the cells (shatha, 2020).

Several of the nanoparticles as, ZnO NPs contain important qualities so that they are used in various important manufacture, which includes food additives, also the ZNO NPS is used for cattle and humans as a dietary supplement because the ZnO induced the immune system and acts as an anti-inflammatory factor (shatha, 2020).

Further, a large set of evidence indicates that the nanoparticles are cause toxicity to mammalian cells or cause other harmful effects to them, therefore, there is a need to evaluate their toxicity (Hakima et al., 2015).

The ZnO nanoparticles have distinctive physicochemical properties, so, they can easily reach the immune tissues and cells via several ways as an injection, ingestion, uptake of skin, and inhalation. the administration of ZnO NPs by oral can cause severe harm to some organs like the heart, lung, liver, and kidney, and, therefore, lead to inflammation. As well as, exposure to ZnO in vitro leads to release the (ROS) (Kim et al, 2014).

With the rapid growth of nanotechnology and increasing exposure to nanoparticles (NPS), there is a need to evaluate their toxicity. Thus, nanotoxicology emerged, Metal oxide NPs belongs to a family of nanomaterials that have been manufactured for both industrial and household applications, the Zinc oxide nanoparticles have a highly applicable and among the most commonly used metal NPs (Moushira et al,2019).

Many research indicated that the ZnO nanoparticles, catalysis the reactions of the inflammatory through the release of ROS via oxidative stress, and generation the inflammatory cytokines (Min,2016).

The Aim: The present research focused on concerning the inflammatory effect of ZnO-NP on liver and lung.

**2-Material and method:**

The Male mice *Mus musculus* L were raised at the laboratory, at 20-25 C and light/dark cycle for twelve-hour during the year. it utilized twelve males, their age range about (11-12) week and with weighing (25-30) gram, the mice were divided into 2 groups: (control and the treatment groups), the control included (6) male and the treated group consist of (6) mice. the Control was injected with 0.5 ml of the physiological solution (0.9%), a treatment group was injected with a half ml of Zinc oxide NPS (400 mg/kg) for 20 sequential days, and the males of both control and treatment groups were killed on 20 th day, and removed the liver and lungs then were fixed in a Bounis solution and prepared for histological examination. (Humason, 1972).

**Real-time PCR**

Six male mice were used for a qPCR analysis, 3 males for the control group, and 3 male mice treated with 400 mg/kg for 20 days. The tissues of the liver and lung that were insulated for the experiment of real-time PCR, were frosted in a deep freeze to the time the experiment was carried out. cellular RNA was insulated of the treated and untreated tissue utilizing a Kit of Promega. then were evaluated the quality and quantity of the RNA that was isolated through using a Nanodrop spectrophotometer. the cDNA had prepared from reverse-transcribed of the RNA and it was utilized as the template for the amplified PCR, by utilizing the kit of reverse transcriptase, The PCR was implemented at volume 25  $\mu$ L of the reaction system, which contained half  $\mu$ L of every primer as in (table 1), reagent of syber green (12.5  $\mu$ L), cDNA template (5  $\mu$ L), and -Nuclease-free water (6.5 $\mu$ L). After obtaining primary data from the results, were calculated the gene expressions values by the 2- $\Delta$ ct method.

Table (1) The primers used for real time- qPCR.

Gene	Sequences (5' 3') of Primers	Product size (bp)
MMP12-F	CCA AGC ATC CGA TCT GGT AT	184

MMP12-R	GGT CAA AGC CAG CAT CA	
---------	------------------------	--

R: Reverse\* \*F: Forward

### Statistical analysis

The program of statistical Statical Package for the Social Sciences (SPSS) version 22 had utilized for statistical analysis of the data, in the present study had been utilized a T-test for analysis of the gene expression data, was adopted at  $P \leq 0.05$  (Weinberg and Abramowitz,2015).

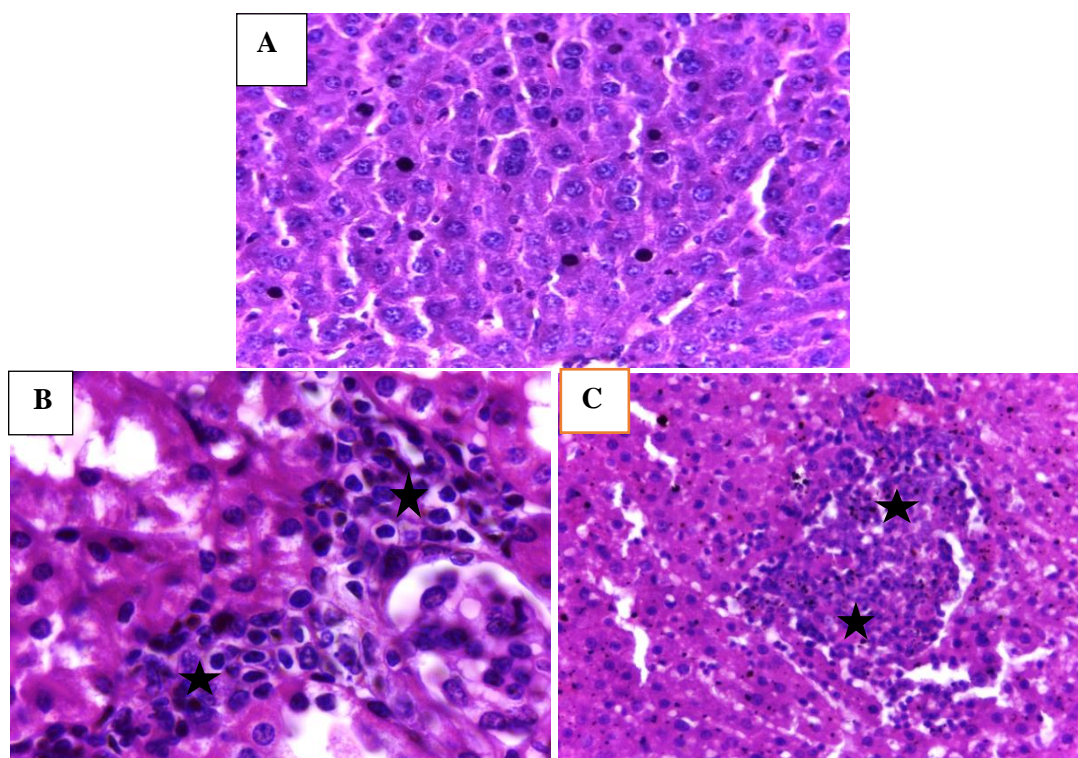
### The results

#### Histopathological impacts of ZnO NPS at the liver and lung laboratory mice:

##### The Liver

Histologically, the liver consists of six lobules and the central vein is concentrated in every lobule. Around this vein, the hepatocytes are arranged radially. the single central nucleus is located in the hepatic cell, and the semi-sinusoid has separated the streaks from each other. Figure 1 (A).

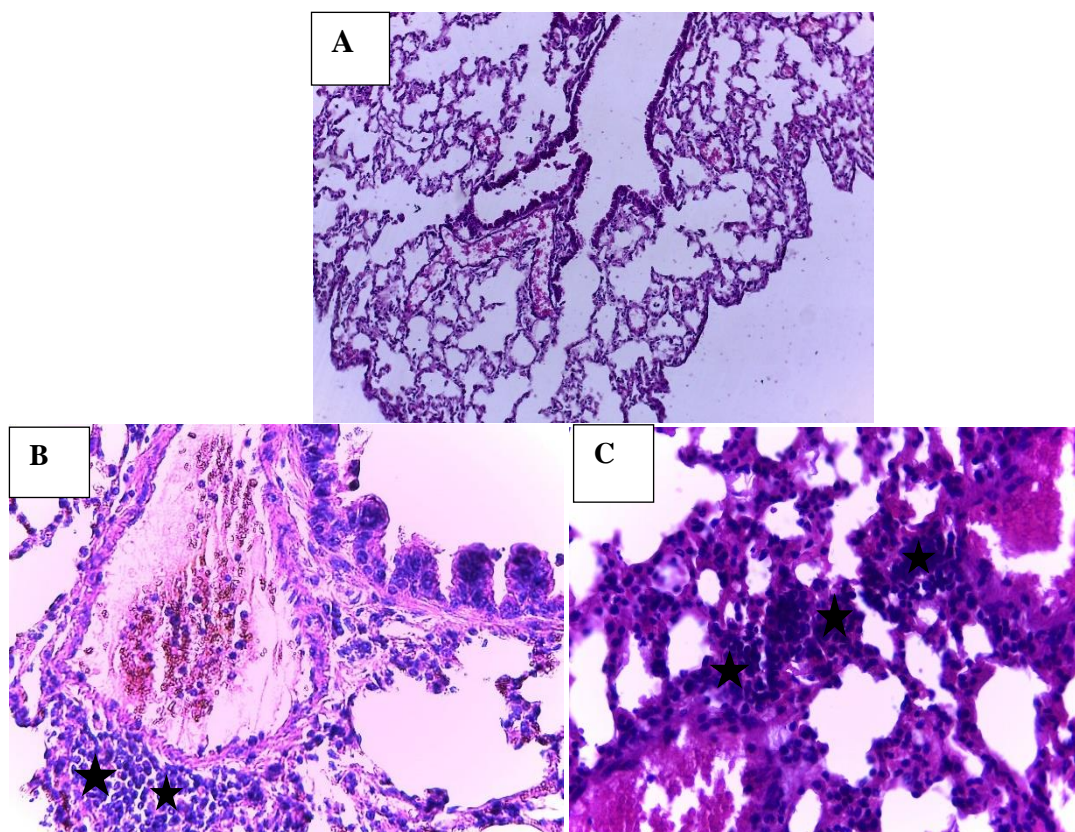
The histological sections of the liver's mice clarified infiltration of inflammatory cells when were injected with ZnO NPS at 400 mg/kg for 20 days compared to a liver of the control group mice.



**Fig (1):** A histological section of the mice liver treated with ZnO NPS 400 mg/kg for 20 days. H&E. A: Control 40x. B: the histological section in treated mice liver shows infiltration of inflammatory cells (star).100X. C: the histological section in the treated mice liver explains infiltration of inflammatory cells (star).40X.

A lung is composed of a set of alveoli, which a simple squamous epithelial tissue with two kinds of cells, the squamous cells which consist the most of the vesicle's lining, that known as pulmonary alveolar type 1(AT1), and the rest cells that obviously appear at the vesicle corner, which are less of the first type and seem with large size. (Fig 2-A).

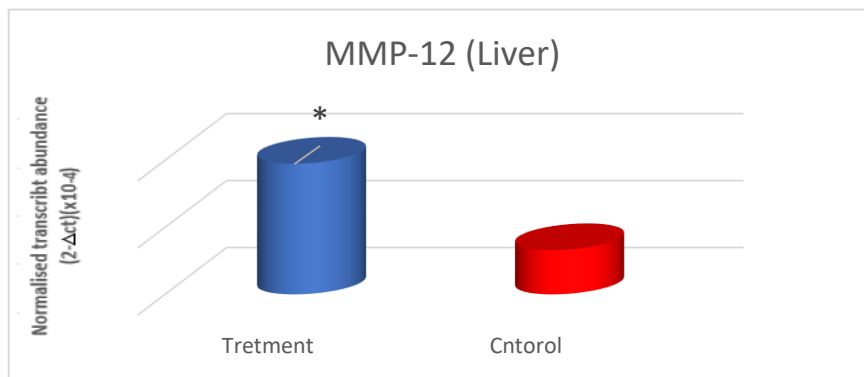
The histological sections of male mice lungs showed infiltration of inflammatory cells when were injected with ZnO NPS 400 mg/kg for twenty days compared to control groups.



**Fig (2)** A histological section of the treated lung mice with ZnO NPS 400 mg/kg, for 20 days. H&E. A: Control 10x. B and C: the section of treated mice lung explains infiltration of inflammatory cell (star). 40X.

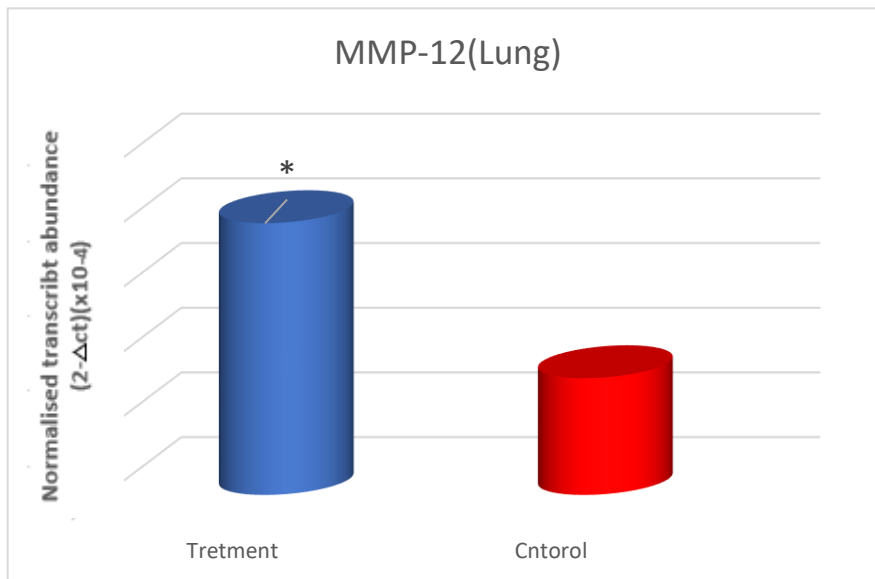
### 3-2: The impact of ZnO NPS on gene expression of MMP12 by Real-time qPCR

The results of gene expression demonstrated an increase significantly in MMP12 gene expression at the liver and lung with ZnO NPS 400 mg/kg at the period of twenty days, in comparison to the control group at  $p \leq 0.05$ . (Fig. 3 and 4).



(Fig:3) the gene expression of MMP12 in the liver

\* Indicate a significant difference between control and treatment ( $p \leq 0.05$ ).



(Fig:4) the gene expression of MMP12 in the lung

\* Indicate a significant difference between control and treatment ( $p \leq 0.05$ ).

### Discussion

Through a different method to which laboratory animals to ZnO nanoparticles were exposed that comprised the injection, cage, inhalation, and through feed or water resulted in histopathological changes, among those changes: inflammation or infiltration of inflammatory cells (Soheili et al., 2013). The finding of the present study confirmed that the ZnO NPs injection cause infiltration of inflammatory cells similar to previous studies. The liver is considered a major organ to get rid the body from toxic and strange materials, the liver is affected by the strange materials through complex reactions of the

metabolism process, eventually, it results in abnormal effects in the liver tissue (Somayeh and Zahra, 2016).

The presence of ZnO nanoparticles in the extracellular material might cause harm to cells, therefore the body treats them as foreign substances, which results in the infiltration of the inflammatory cells to a target organ (Shatha,2020).

The cytokinin considers as chemotaxis of inflammatory cells, which can release from the damaged cells and /or their adjacent cells to the harm site (Linlin et al., 2018). That's can interpret the infiltration of inflammatory cells to tissues of the liver and lung.

The findings of the current study demonstrated a significantly increased level of the MMP12 gene expression in the tissues of both the liver and lung and this is completely in agreement with (Starodubtseva et al., 2011; Guanghong et al., 2015).

The MMP12 gene reflects a presence of inflammation in the liver and lung, it is known that the MMP12 gene is a bioindicator for the presence of inflammation (Adnan et al., 2017, shatha ,2020).

The Matrix metalloproteinases are proteolytic enzymes are also called matrix metalloproteinases (MMPs), the action of MMPs is degrading of extracellular matrix ECM (are a complicated network of the glycosaminoglycan and modified proteins) (Baker et al., 2002).

MMPs includes the MMP-12, which is a 54 kDa proenzyme that was processed to the 45 kDa and then a 22 kDa active forms, the MMP-12 is major generated by macrophages, it proved to be associated with the diseases of inflammatory, also the MMP12 appears to involved obviously in acute and chronic diseases especially the pulmonary inflammatory diseases (Mikel et al, 2019).

MMP12 also is related to several pathologic conditions, such as emphysema, atherosclerosis, and rheumatoid arthritis (Shapiro, 2003). a change in the action of these enzymes leads to a lot of diseases, like cancer disease (Baker et al., 2002).

The previous studies in vivo and in vitro confirmed, the nanoparticles and nanoparticles oxides have stimulation or inhibited effects, as their stimulating effect depending on several factors, like the size of the nanoparticles and a cellular model which used in the experiment, as well as, many research indicated that nanoparticles have an induced effect on activity or expression of MMP (Magdalena et al.,2018).

The increased gene expression of MMP12 may be due to its participation in the inflammatory response through the TNF activation, as for the other MMP-12 proinflammatory properties is their ability to stimulate neutrophil recruitment and production of the cytokine, and hemokine (Dean et al., 2008).

Several genes of MMPs had a very decreased gene expression in physiological cases, on the other hand, there are various molecules such as NPS that can induce its expression (Ning et al.,2017).

The stimulating effect of the NPS increases the mRNA level, the inducing effect of the NPS may result in the stimulate of the inflammation that related to the pro-inflammatory proteins level increased, also was seems that the MMP12 increased is linked to the excess production of ROS (Magdalena et al., 2018).

### **Conclusions**

ZnO NPS caused inflammation in both tissues of the liver and lung through the infiltration of inflammatory cells in different areas of both tissues, and MMP12 gene expression increased significantly at the tissues of the liver and lung, as the MMP12 gene, is a bioindicator for the presence of inflammation.

### **Reference**

- Adnan, N.; Qiuwei, P. and Mirza, S. B.** (2017). Matrix metalloproteinases (MMPs) in Liver\_Diseases. *J Clin Exp Hepatol*, 7(4): 367–372.
- Baker, A.H.; Edwards, D.R. and Murphy, G.** (2002). Metalloproteinase inhibitors: biological actions and therapeutic opportunities. *J Cell Sci*, 115(19):3719–27.
- Dean, J. H.; Cox, C. L.; Bellac, A. D.; Amanda, E. S. and Christopher M. O.** (2008). Macrophage-specific metalloelastase (MMP-12) truncates and inactivates ELR CXC chemokines and generates CCL2, -7, -8, and -13 antagonists: potential role of the macrophage in terminating polymorphonuclear leukocyte influx. *Blood J.*, 112(8):3455-64.
- Ning, C.;Min, H. and Raouf, A. K.** (2017). Biochemical and Biological Attributes of Matrix Metalloproteinases. *Prog Mol Biol Transl Sci.*, 147: 1–73.
- Guanghong, L.; Zhuangjun, W.; Erik, L.; Stephanie, M.;Omar, A.; Michel, B. and Xiaoning, B.** (2015). Enhanced expression of matrix metalloproteinase-12 contributes to Npc1 deficiency-induced axonal degeneration. *Exp Neurol.*, 269: 67–74.
- Hakima, Z.; Serge, R.; Wee, Y.; Czajka, M.; Sawicki, K.; Sikorska, K. and Popek, S.** (2015). Toxicity of titanium dioxide nanoparticles in central nervous system. *Toxicol. In Vitro*, 29(5): 1042–1052.
- Humason, GL.** (1972). *Animal's tissue techniques*,3rd edition. W H Freeman and Company

- Kim C, Nguyen H, Ignacio RM, Kim J, Cho H, Meang E, Kim Y, Kim M, Park B, Kim S** (2014). Immunotoxicity of zinc oxide nanoparticles with different size and electrostatic charge. *International Journal of Nanomedicine* ,9(2) :195—205.
- Linlin, C.; Huidan, D.; Hengmin, C.; Jing, F.; Zhicai, Z., and Ling Z.** (2018). Hepato-renal toxicity of oral sub-chronic exposure to aluminum oxide and/or zinc oxide nanoparticles in rats. *Oncotarget*, 9(6): 7204–7218.
- Magdalena C.; Krzysztof, S. and Lucyna, S.** (2018). Effect of nanoparticles on expression and activity of matrix metalloproteinases. *Nanotechnology J*, 7 (6): 541–553.
- Mikel, A.; Eunate ,G.; Matej, V. et al** (2019). Article MMP-12, Secreted by Pro-Inflammatory Macrophages, Targets Endoglin in Human Macrophages and Endothelial Cells *International Int J Mol Sci.* 20(12): 3107.
- Min-Ho Kim** (2016). Biological effects of zinc oxide nanoparticles on inflammation, *TANG [HUMANITAS MEDICINE]* , 6 (4 ) : 23.1-23.6
- Moushira Zoheir, Amira Medwar, Amany Solaiman and Neama Elbanaway** (2019). Histological Study of the Effect of Zinc Oxide Nanoparticles on the Cardiomyocytes of Adult Male Albino Rats with Reference to the Role of Mitochondria *Personal non-commercial use only*, 42(3)
- Niels, H; Ferial, R.; Nicklas, R.; Anne, Saber; Petra, J.; Stefan, B. et al** (, 2019). Acute phase response and inflammation following pulmonary exposure to low doses of zinc oxide nanoparticles in mice, *Nanotoxicology* 13 (9): 1275-1292.
- Shatha, Q.Kadhim** (2020) The effect of ZnO NPS on some physiological and histological parameters in laboratory mal mice *Mus Musculus L.* thesis.
- Soheili, S.; Saeed, M.; Attaollah, S.; Masoud, G.** (2013). Histopathological Effects of ZnO Nanoparticles on Liver and Heart Tissues in Wistar Rats. *Adv. Biores*, 4 (2): 83- 88.
- Somayeh, S. and Zahra, H.** (2016). The Effect of Short-term Intraperitoneal Injection of Fe<sub>2</sub>O<sub>4</sub>Zn Nanoparticle on Liver Enzymes and Tissue in Male Wistar Laboratory Rats. *International Journal of Medical Research & Health Sciences*, 5 (12):92-100.
- Starodubtseva, V.; Vasilievich, S.; SobolevAnna, S. and Anna, S.** (2011). Genes expression of metalloproteinases (MMP-1, MMP-2, MMP-9, and MMP-12) associated with psoriasis. *Genetika*, 47(9):1254-61.