

WOUNDS MANAGEMENT AND TREATMENT EFFECT OF QUERCUS GALL

Huda K. KHASSAF¹

University of Basrah, Iraq

Zainab A. SHEHAB²

University of Basrah, Iraq

Fatin L. KHAPHI³


University of Basrah, Iraq


Abstract


Quercus is one of the species of oak found in Asian countries. This plant includes a variety of medicinal components. Tannin is the major ingredient found in around half to seventy percent of galls. The wound healing activity of a hot water extract of *Quercus* gall was investigated in this study. The effect of water extract of the shade-dried gall of *Quercus* on wound healing was investigated using incision wound models at dose level of 300 mg/kg. Our study applied on 16 male rabbits classified to 2 groups: Control group (treated by application of normal saline directly on the wound once daily), *Q.* extract treated group (received direct application of 300 mg/kg of extract onto the skin once a day) each group subdivided to 2 subgroup 7 and 14 days treatment each one have 4 animals. Wounds healing score, macroscopic and histologic examination were performed to determine the substantial favorable effect of the extract on wound healing. The plant showed a definite, positive effect on wound healing by showing considerable progress in healing ($P < 0.05$) and in characteristics such as wound healing score, the experimental group outperformed the control group. Wound healing was also improved in histopathological examinations with a significant increase in the granuloma tissue, which exhibited the capacity to improve the process of wound healing in treated rabbits with extensive re-epithelialization, collagen deposition, and cellular infiltration as comparison with non-treated group. *Quercus* could be a potential alternative treatment for wounds, according to this study.

Keywords: *Quercus*, Tannin, Wound Healing, Rabbits, incision wound.

 <http://dx.doi.org/10.47832/2717-8234..1123>

¹  Huda.khassaf@uobasrah.edu.iq, <https://orcid.org/0000-0002-8251-2776>

²  dr.zaenb_alkatrani@yahoo.com, <https://orcid.org/0000-0002-4826-1002>

³  Fatin.Khaphi@uobasrah.edu.iq, <https://orcid.org/0000-0002-2107-7192>

Introduction

Wounds are still a major public health issue that affects people all over the world. The primary goal of wound management and treatment is for wounds to heal quickly and epithelialize, preventing contagion and minimizing dynamic consequence (1). Wound cure is a complex method. It begins with inflammation, which leads to the production of granulation tissue and scar remodeling in the early stages (2). Within 1 to 2 days of damage, epidermal cells along the wound's margin begin to proliferate. Granulation tissue invades the wound gap on the fourth day following injury, and numerous new capillaries form through new stroma (3, 4). Skin remodeling is the final stage. Collagen is regimented by fibroblasts and creates an ordered connection to boost incision stretchy force during this phase (5). Numerous investigations have been carried out on the biological activity of traditional herbs for therapeutic purposes (6). These plants' biological activity is linked to their bioactive chemicals, which have physiological effects on the human body. Because polar chemicals are easily extracted using polar solvent, The polarity of the solvent plays an important role on the extraction of active compounds. The little tree *Quercus* Olivier is found throughout Greece, Asia Minor, and Iran, *Quercus* galls are commonly used as an astringent, gargle, and enema (7). *Quercus* galls have been utilized in oriental traditional medicine to treat inflammatory disorders for millennia in Asian countries. Q. is a traditional herb with a lot of therapeutic potential and antioxidant and antibacterial properties. The type of solvents employed will determine the appropriate solvents for extracting the target chemical. However, owing to their low toxicity and high extraction yield ethanol and water are extensively employed solvents, and their polarity may be controlled in advance by combining them at a certain ratio (8). The preference for hot water as a solvent can be used for bigger doses of herb and safety in infusions and decoctions. It has been used as a traditional medicine in Asian countries for millennia to treat inflammatory diseases, and as a herbal drink to treat women after childbirth in Malaysia to restore the uterine wall's elasticity (9). Aside from that, it can manage tonsil inflammation by utilizing as a mouth antiseptic of hot water extract of Q. and it can cure swelling or inflammation by directly applying it to the skin. Furthermore, this plant has shown excellent outcomes in cosmetics.

MATERIALS & METHODS

Extraction

The peels of the *Quercus* plant were washed with running water and then placed on filter papers in a suitable air stream with continuous stirring to dry them and prevent them from rotting. After that, it crushed and the dry powder was kept until use, Preparation of aqueous extracts, Al-Mansour method (1995) was followed in preparing aqueous extracts (10). Taking 10 g of the powder for the studied plant and placed in a 500ml beaker contains distilled water at a temperature 50°C and mix with an electric mixer for 15 minutes and then filter the mixture Filter papers and take the filtrate the papers in opaque bottles in Refrigerate until use.

Wound protocol

The Animal Ethic Committee has given their approval; rabbits (8–10 weeks old, 1250–1500 g) were accustomed to criterion habitation and feeding. sixteen adult Individual rabbit cages with a 12-hour light-dark cycle and constant temperature (22°C) were employed. The animals were anesthetized with intraperitoneal injections of xylazine hydrochloride (10 mg/kg) and ketamine hydrochloride (25 mg/kg) prior to being wound. The femur's dorsal region was totally shaved and iodine sterilized. A surgical blade was used to make 1x2 incision wounds on the upper femur area of each animal. Each rabbit had a full-thickness wound with a diameter of 1 cm created by removing the dorsum skin. Scalpel, straight scissors, and Adson forceps were among the tools we used (11). The wounds were exposed

to the outside environment because they were left naked. The animals classified in to 2 groups (8 rabbits in each one) Control group (received normal saline directly on the wound once daily), treated group received water extract (300 percent w/v) by applied topically to each animal's wounds, Each group subdivided to 7 and 14 days treated subgroups . Therapy was given on a daily basis until the wound healed. Each animal group's wounds (n = 8) were photographed and the wound size was measured using the computational software Image on days 0, 3, 7, and 14.

Histopathological Study

After the end of treatment period of each group (7 and 14 days) animals were anaesthetized to obtain the skin sample with depth about 2cm. Percent buffered formalin was used to repair the removed tissue. Each sample was placed in a paraffin block and thinly sliced at 2.5 m before being stained with hematoxylin and eosin. The experiment included a pathologist who examined the slides under a light microscope to assess the severity of histopathological abnormalities.

Statistical analysis

The mean and standard deviation (mean SD) are used to express all data. The statistical analysis was carried out using the SPSS (version 16) statistical software tool. An analysis of variance (ANOVA) was used to assess the data, followed by a post hoc multiple comparison. $P < 0.05$ was used to determine statistical significance.

RESULTS

Wounds at 0, 3, 7, and 14 days were photographed Figure 1., the time it took for complete healing, or epithelialization, was comparable to the control group, granulation development are all marked, the macroscopic exam show gradual significant improvement in the wound healing by decrease the wound circumstances. At all times application of Q. extract enhanced wound healing commencing on the 3rd day, with significance attained on the 7th day.

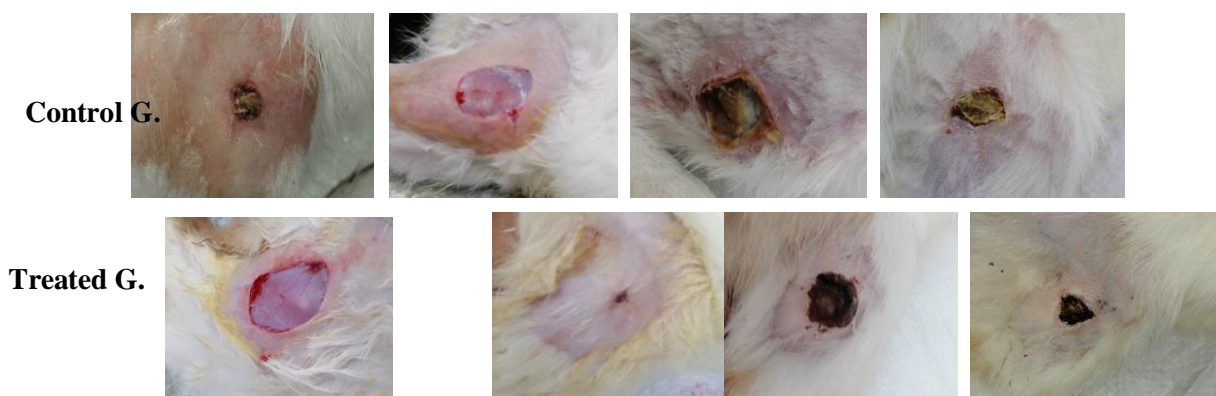


Figure 1: Macroscopic exam of wounds at 0, 3, 7 and 14 day of the study in the control and extract treated group.

As shown in Table 1, each wound was given a score ranging from 0 to 1.7 and a mean score for each group was determined. The average wound healing scores of the different groups were then compared. The mean wound surface in the treated group differs significantly from the control group in day 7, but in 3 and 14 day from treated animal there is no significant differences at ($P \leq 0.05$) as compared with control group. Also there is significant difference in wound healing score in control and treated group at the three examined periods.

Table 1. Effect of extract on wound healing at the 3rd, 7 and 14 days

Groups	Wound Healing Score		
	3rd day	7 day	14 day
Control G.	1.73±0.08A^a	1.21±0.07A^a	0.73±0.31A^c
Treated G.	1.40±0.08B^a	0.53±0.05 B^b	0.13±0.08B^c
LSD	0.69	0.44	0.44

Histological pictures wound tissues showed partial epithelialization and limited cellular infiltration on day 7. in control group, whereas wounds treated with Q. showed nearly complete re-epithelialization and obvious cellular infiltration. In contrast, there were no noticeable effects in the control group after 14 days. Group treated wounds on day 14 reveal a substantial number of cell migration, particularly fibroblast cells, as well as collagen deposition and blood vessel formation at the wound site. *Quercus* (H&E 200)-treated animals, on the other hand, had a thin, well-formed epidermis with hair follicle production in the dermis and no inflammatory cells in a well-organized dermis.. as showing in Fig.2.

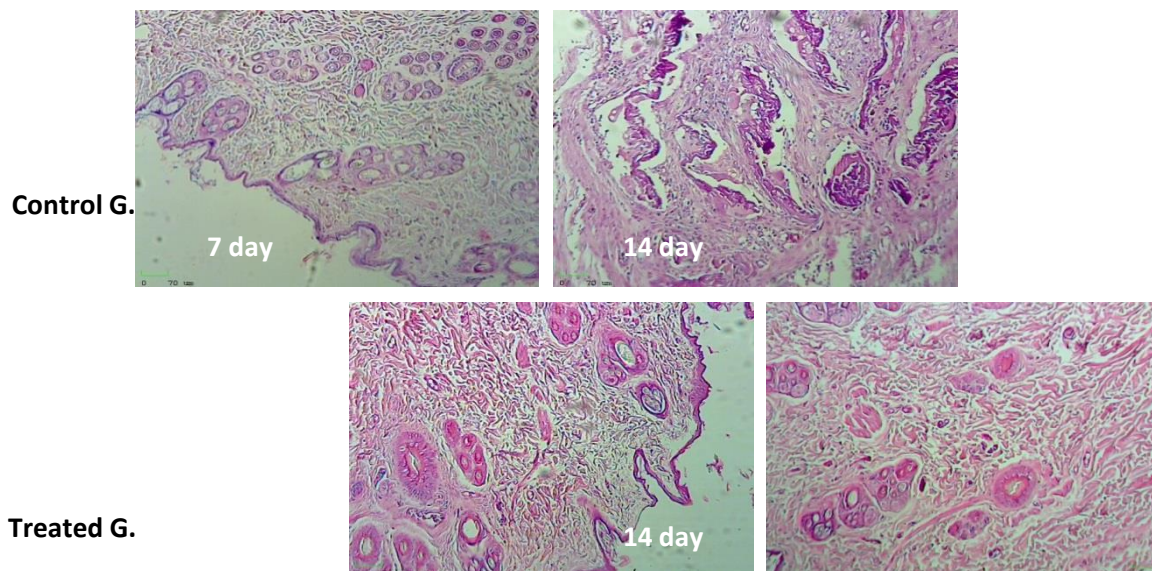


Figure 2: Histopathology of wounds at 7 and 14th day of the study in the control and extract treated group.

DISCUSSION:

The goal of wound healing is to restore the wounded tissue as closely as possible to its original structure, because skin is a complex tissue; a full-thickness cut causes harm to a variety of organizations (12). The wound surface closure results in our study revealed that the mean wound surface in the 7th day was greater in the group treated with Q. gall extracts than in the control group. In a wound incision model, rabbits treated with Q. extract showed significant wound healing activity. In this group, there was a considerable decrease in the duration of epithelialization and the wound closure ratio. Q. extract also aided re-epithelialization and the formation of new blood vessels.

The activity of Q. for promoting wound healing in rabbits could be due to the biological features of gallic acid, which is the extract's major component (13). The wounds treated with Q. improved due to better inflammatory cell homeostasis, oxidative reaction, and cellular function. Also tannins as a main component of Q. plant help wounds heal by scavenging

free radicals and encouraging wound contraction, angiogenesis, and fibroblast production (14). Many previous experiment results showed that Q. oil extract has strong antibacterial activities which are most likely due to the bioactive chemicals found in this plant. This discovery sheds light on the use of oil extract in the treatment of bacterial-caused skin irritation. (15), in our study we focusing on provide the water extract dosage form as alternative and good competitor in wounds treatment field.

CONCLUSION

The treatment effect of hot water extract of Q. gall have been mentioned in the present study. Since no clinical study supporting these ideas was found, they are considered as notions for further studies, leading to potential new drugs dosage form of this endemic natural product. The current study confirms that wound healing is demonstrated in an animal model. More research is needed to demonstrate the effects of Q. gall hot water extract on human wound healing.

References

1. Atiyeh BS, Costagliola M, Hayek SN, Dibo SA. Effect of silver on burn wound infection control and healing: review of the literature. *Burns* 2007; 33:139-148.
2. Bastos ML, Houly RL, Conserva LM, Andrade VS, Rocha EM, Lyra Lemos RP. Antimicrobial and wound healing activities of *Piper hayneanum*. *J. Chem. Pharm. Res* 2011; 3:213-222.
3. Al-Waili N, Salom K, Al-Ghamdi AA. Honey for wound healing, ulcers, and burns; data supporting its use in clinical practice. *ScientificWorldJournal* 2011; 11:766- 787.
4. Laplante AF, Moulin V, Auger FA, Landry J, Li H, Morrow G, et al. Expression of heat shock proteins in mouse skin during wound healing. *J Histochem Cytochem* 1998; 46:1291-1301.
5. Rawat S, Gupta A. Development and Study of Wound Healing Activity of an Ayurvedic Formulation. *Asian J Res Pharm Sci* 2011; 1:26-28
6. Mohemmadi Z. *Int J Pharma Bio Sci.* 2011; 2(1): 609-615.
7. Goli AH, Barzegar M, Sahari MA. *Food Chem.* 2004; 92: 521-525.
8. Zarnowski R, Suzuki Y. *J Food Comp Anal.* 2004; 17: 649-656.
9. Samuelson G. *J Pharm.* 1992; 79: 86
10. Al-Mansour, Nasser Abd Ali (1995. Effect of extracts Different from deer antler, *luteaibicella (Martyniaceae)* in the life performance of the whitefly PhD thesis. Bemisiatabacci (Genn) Philosophy - Mechanism of Science - University of Basrah, 126 pages.
11. Mandl I, Maclennan JD, Howes EL. Isolation and characterization of proteinase and collagenase from *Cl. histolyticum*. *J Clin Invest.* 1953;32 (12):1323-9. doi: 12.1172/JCI102861. [PubMed: 13109000].
12. Harish BG, Krishna V, Santosh Kumar HS, Khadeer Ahamed BM, Sharath R, Kumara Swamy HM. Wound healing activity and docking of glycogen-synthase-kinase-3-beta-protein with isolated triterpenoid lupeol in rats. *Phytomedicine.* 2008;15(9):763-7. doi: 10.1016/j.phymed.2007.11.017. [PubMed: 18222664].
13. Kaur G, Athar M, Alam MS. 2008. *Quercus infectoria* galls possess antioxidant activity and abrogates oxidative stress-induced functional alterations in murine macrophages. *Chemico-Biological Interactions* 171:272-282 DOI 10.1016/j .cbi. 2007.10.002.
14. Lai HY, Lim YY, Kim KH. Potential dermal wound healing agent in *Blechnum orientale* Linn. *BMC Complement Altern Med* 2011; 11:62.
15. Parekh J, Jadeja D, Hanlin R. *Turkish J Bio.* 2005; 29: 203-210.