ARTICLE IN PRESS

Materials Today: Proceedings xxx (xxxx) xxx

Contents lists available at ScienceDirect

Materials Today: Proceedings

journal homepage: www.elsevier.com/locate/matpr

First record of ciliophora (Orchitophryidae) isolated from CSF samples of patients with meningitis in Thi-Qar province south of Iraq

Bassad A. AL-Aboody [a,*], Muslim Abdulrahman Mohammed Altooma [b], Adnan Issa AL-Badran [b]

[a] Department of Biology , College of Science . University of Thi-Qa, Iraq
[b] Department of Biology , College of Science, University of Basrah, Iraq

ARTICLE INFO

Article history:
Received 15 May 2021
Accepted 23 May 2021
Available online xxxx

Keywords:
CSF
Orchitophryidae
Mesanophrys
Ciliophora
Thi-Qar / Iraq

ABSTRACT

In September 2020 when we were investigating about opportunistic free living amoeba in patients with meningitis in Thi –Qar province south of Iraq, throughout examination the CSF which was cultured on NN Agar medium. It was surprisingly we found the ciliates protozoa (Orchitophryidae) in both stages, vegetative and cystic, after that the ciliates were isolated and cultured in vitro and then morphological, molecular and virulence characterizations were studies. The results of morphological study revealed that these ciliates were similar to *Mesanophrys* sp. whereas the sequence of rDNA of studied ciliate with accession numbers being given. in NCBI LC621170.1 was show (86.04%) homology identity to *Mesanophrys* sp. 18S rRNA gene (accession number MN260367.1). but show (98.56%) and (97.92%) homology identity to Orchitophrydiae 18S rRNA gene (accession number EF023919.1 and EF023549.1), that may be this ciliates in our study is a new species for *Mesanophrys*. In addition experimental infection confirmed that *Mesanophrys* like ciliates was the pathogen that infected human. In summary this study represent the first record of the ciliophora Orchitophryidae (*Mesanophrys* like ciliates) as a human pathogen from Thi-Qar province / Iraq.

Selection and peer-review under responsibility of the scientific committee of the Emerging Trends in Materials Science, Technology and Engineering.

1. Introduction

Orchitophryidae ciliates are belonging to the class : oligohymenophorea , subclass : scuticociliatia and order : philasterida , they are tiny ciliates and widely distributed in marine environments . This family have four genera including : *Metanophrya, Paranophrys, Orchitophrya and Mesanophrys* [1]. The morphology of *Orchitophrya* ciliates was similar to *Mesanophrys* ciliates in some cases , which often causes difficulty in classification [2]) . *Mesanophrys* ciliates can live freely in sea water or sediment invade the haemolymph of crustaceans and cause the death of blue crab [3].

Systemic infection of ciliates parasites have been reported from many organisms such as fish (Munday *et al.* 1997 ;Iglesias *et al.*, 2001),sea stars[4,5] ,bivalve molluscs[6,7,8]) and farmed swimming crab [9]) .

The belief prevailed that *Balantidium coli* is the only member of the ciliate phylum known to be pathogenic to human but recently many cases of infections in human with ciliates were recorded, in the urine of patient with chronic prostatitis , renal microlithiasis and acute cystitis were found the ciliate protozoa Colpoda spp. [10],(] B. and first recorded of the ciliophoran *Trichophrya piscium* as a human pathogen from Basrah , Iraq [11],(B. Al Hayani 2018) .

The present finding documents the first record of ciliophora (Orchitophryidae) from CSF samples of meningitis patients, a systemic parasitic ciliate infection was discovered in two individual human with meningitis during investigations into opportunistic free living amoebae in Thi-Qar province ,one case from a female patient 5 months old and the second case from a male patient 5 years old),(B.

2. Material and methods

2.1. Sample collection

One ml of CSF collected from eight patients there age ranged between 5 month to 10 years they were suspected to be infected with meningitis but showed a negative bacterial cultured in laboratory of bacteriology in Bint AL-Huda teaching hospital and Ibn AL-Btar private laboratories in Thi-Qar province south of Iraq ,

* Corresponding author.
E-mail address: bassadalaboody_bio@sci.utq.edu.iq (B.A. AL-Aboody).

https://doi.org/10.1016/j.matpr.2021.05.486
2214-7853/
Selection and peer-review under responsibility of the scientific committee of the Emerging Trends in Materials Science, Technology and Engineering.

the CSF was cultured on non– nutrient agar medium(NN-agar) and incubated in 26 C^0 and 37C^0 and followed up daily examination of wet a mount slide for four week . After four days ciliates were found in the culture with the same shape in two samples only.

2.2. Ciliate isolation and cultivation

The ciliates with the same shape were discovered in to CSF culture by microscopic examination , in order to establish a monoclonal culture the ciliate isolated from CSF culture and cultured in NN-agar medium added to it Page amoeba saline (PAS) incubated in 4C^0 ,20C^0 and 37C^0 to determined the optimum temperature for growth),(B. .

2.3. Morphological observation

The cultured ciliates were observed and photographed using imaging microscope .

2.4. Experimental infection

.

3. Preparation of ciliate for injection

Ciliate trophozoites were scraped from agar surface by a cotton swab after 2–3 days and then the liquid phase of the culture was transported to sterile plain tubes and centrifuged at 5000 rpm for one minute . The supernatant was discarded and the ciliates were washed twice with 1 ml of sterile PBS and finally re-suspended in 1 ml of sterile PBS , the number of ciliate trophozoites were calculated by haemocytometer),(] B. .

4. Infection of animals

4.1. Animals

12 male of white mice (Mus musculus /Bulb / c) were divided in to three groups, four mice in each group weighting approximately 25–35 gm , the animals were bred in special cages in the animals house of the college of science / Thi- Qar university),(B. .

The animals injected as following :

1-First group : A wound on the left femur was made using a sterile blade , the wound was contamination with ciliate trophozotes (10^5 per animal) by a sterile syringe .

2- Second group : It was injected intraperitoneal with ciliate trophozotes (10^5 per animal) .

3- Third group : Injected with normal saline as negative control .

After 27 days of infection , mice were killed by ether ,part of brain cultivation on NN-agar medium at 20 C^0 . The remaining part of mice brain and liver were fixed in 10% formalin for histological study .

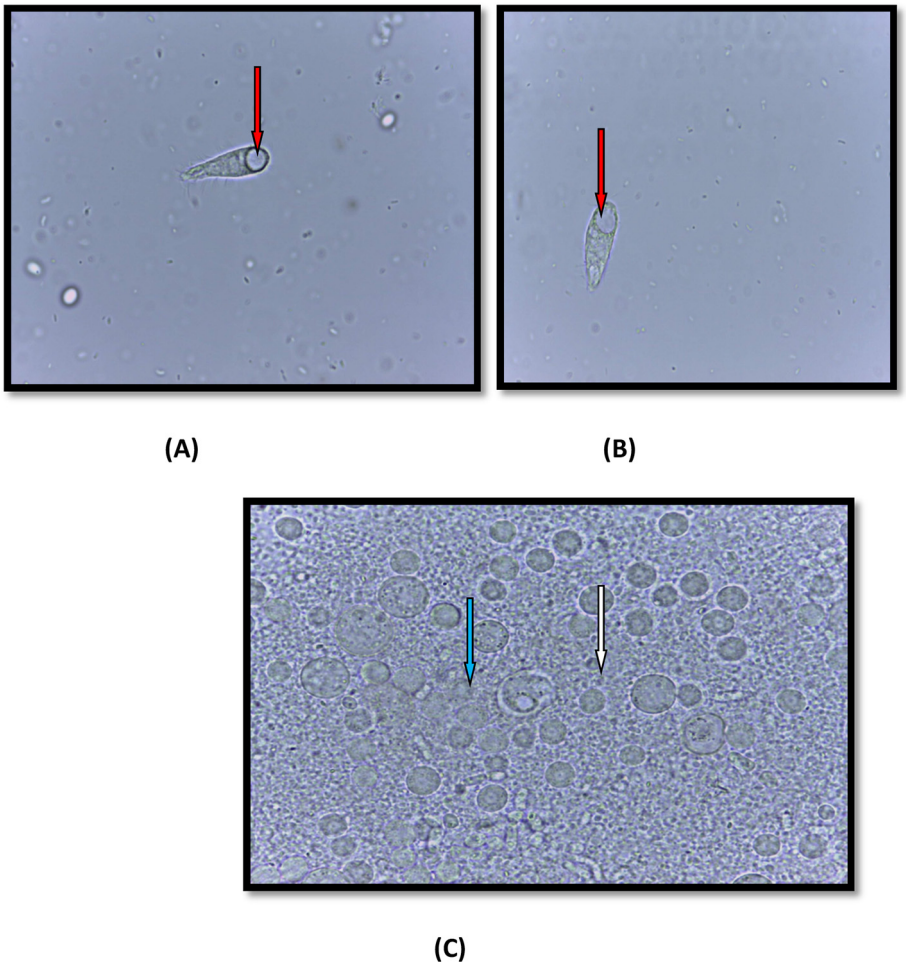

Fig. 1. Images of a live ciliate from an in vitro culture (unstained)100X : (A & B) trophozoite stage note the contractile vacuole (red arrow) and the granular appearance of the cytoplasm : (C) encystations (blue arrow) and cyst stage(whit arrow) . (For interpretation of the references to colour in this figure legend, the reader is referred to the web version of this article.)

4.2. Tissue preparation and histology :

Tissue preparation was made according to Drury et al. [12] :

A small piece of the targeting organs (brain and liver) of the infected mice was kept in 70% ethanol till tissue preparation .

5. DNA isolation and sequencing

Genomic DNA (gDNA) of ciliates in CSF culture , brain and liver tissues of infected mice was extracted by using gSYNC ™ DNA Extraction kit , Geneaid . Korea , and done according to company instructions . Conventional PCR was done for 18S rRNA using a set specific two primers designed by Dopheide et al. [13] : 384F (YTB GAT GGT AGT GTA TTG GA) 1147R (GAC GGT ATC TRA TCG TCT TT) of common ciliophora. according to the following protocol :

Initial denaturation 95C^0 for 10 min and 35 cycle of 35 sec at 95C^0 , 35 sec at 55 C^0 and 40 sec at 72 C^0 followed by 10 min final extension at 72 C^0 ,PCR product was electrophoresed on 1.5% agarose gel and visualized by UV, the PCR products (750 bps) were sent to Macrogene company (South Korea) for sequencing . The sequences were analyzed by BLAST comparison with previously published sequences which were derived from the GenBank database.



Fig. 2. Agarose gel electrophoresis image that show the PCR product(750 bps)t analysis of 18S ribosomal RNA gene from genomic DNA of ciliophora from clinical samples : Where M: Marker (2000–100 bp) lance (1,2) positive samples of CSF culture and lance (4,5,) positive samples of infected brain tissue (6) positive sample of infected liver tissue .

6. Results

6.1. Ciliate morphology

Two phases (trophozoite and cyst) of ciliates were observed in the culture. .Trophozoite was melon – shaped with a tapered anterior end and a rounded posterior ,it has long cilia , live ciliates were very active and flexible continually moving forward and stopping to change direction . They have a contractile vacuole at the posterior end and an oral apparatus at the anterior end , ciliate cell were between 40 and 55 μm in length and 12.5–15 μm in width with one macronucleus and one micronucleus ciliate had a densely ciliated oral area . The cyst of the ciliate was spherical with thick cyst wall , the mean diameter of cyst was 22.5–25 μm . Fig. 1.

6.2. PCR and sequences analysis

The conventional PCR using the common ciliophora two primers (384F & 1147R) that amplified a portion of 18S rRNA gene yield a 750 bp product was positive for ciliophora in CSF culture , brain tissue and liver tissue of infected mice Fig. 2. Following sequencing and analysis of the CSF culture and brain tissue PCR products Blast results indicated that the sequence of rDNA of ciliate with accession numbers being given in NCBI LC621170.1 was show (86.04%) homology identity to *Mesanophrys* sp. 18S rRNA gene (accession number MN260367.1). but show (98.56%) and (97.92%) homology identity to Orchitophrydiae 18S rRNA gene (accession number EF023919.1 and EF023549.1). Fig. 3

6.3. Experimental ecology of temperature

The results showed that ciliate . could grow normally in the temperature of 20 C^0 and 37 C^0 , ciliates entered the exponential growth period on the 3rd day reached the maximum density on the 7th day and it can remain active on the NN-agar until the 20th day after cultivation.

Score	Expect	Identities	Gaps	Strand
1099 bits(595)	0.0	613/622(99%)	0/622(0%)	Plus/Plus

```
Query  1    GGTTCGATTCCGGAGAGGGAGCCTGAGAAATGGCTACCACATCTAAGGAAGGCAGCAGGC  60
Sbjct  365  ............................................................  424

Query  61   GCGTAAATTACCCAATCCTAATTCAGGGAGGTAGTGACAAGAAATAACAACTCGGACCTC  120
Sbjct  425  ............................................................  484

Query  121  ACACGAGGTTACGAGATTGCAATGAGAACAATTTAAACCTCTTATCGAGTAACAATTGGA  180
Sbjct  485  ............................................................  544

Query  181  GGGCAAGTCTGGTGCCAGCAGCCGCGGTAATTCCAGCTCCAATAGCGTATATTAAAGTTG  240
Sbjct  545  ............................................................  604

Query  241  TTGCAGTTAAAAAGCTCGTAGTTGAAAATCTGGCCGGTGCTACTCTCGGCTCCCTGAGTC  300
Sbjct  605  ............................T...............GT...T..............  664

Query  301  GGTGTAGCGCCTGGTCATCCGTACGGGAAACTAGCTCGACCTTCACTGGTCGGCTAGTGG  360
Sbjct  665  ..CTC....................T.......................................  724

Query  361  ATCGTACACTTTACTTTGAAAAAATTAGAGTGTTTCAGGCAGGCAATTGCTTGGATACTG  420
Sbjct  725  ...A.......................................................  784

Query  421  TAGCATGGAATAATGGAATAGGACTTTGACCTATTTGTTGGTTTCTCGAGGTCAAAGTAA  480
Sbjct  785  ............................................................  844

Query  481  TGATTAATAGGGACAGTTGGGGGCATTCGTATTTAATTGTCAGAGGTGAAATTCTTGGAT  540
Sbjct  845  ............................................................  904

Query  541  TTTTTAAAGACGAACTTATGCGAAAGCATTTGCCAAGGATGTTTTCATTAATCAAGAACG  600
Sbjct  905  ............................................................  964

Query  601  AAAGTTAGGGGATCAAAGACGa  622
Sbjct  965  ........................  986
```

Fig. 3. NCBI BLAST Multiple sequence alignment analysis that show single nucleotide in Orchitophrydiae.

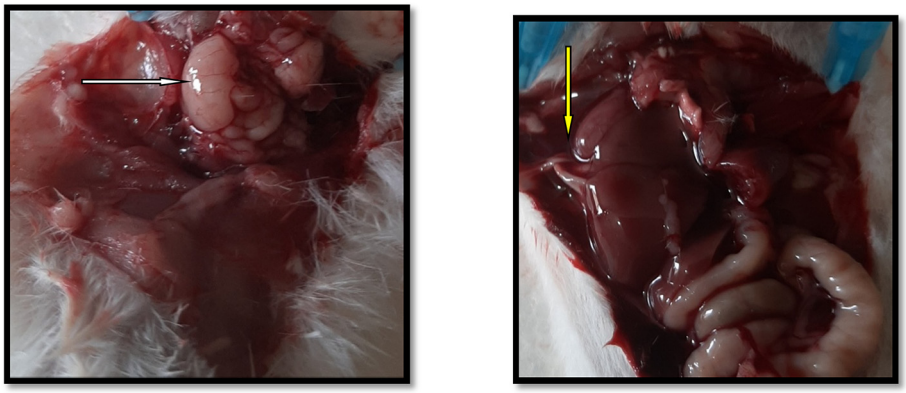

(A) (B)

Fig. 4. Organs of infected mice (A) swelled Brain (whit arrow) , (B) hepatomegaly **(yellow arrow)**. (For interpretation of the references to colour in this figure legend, the reader is referred to the web version of this article.)

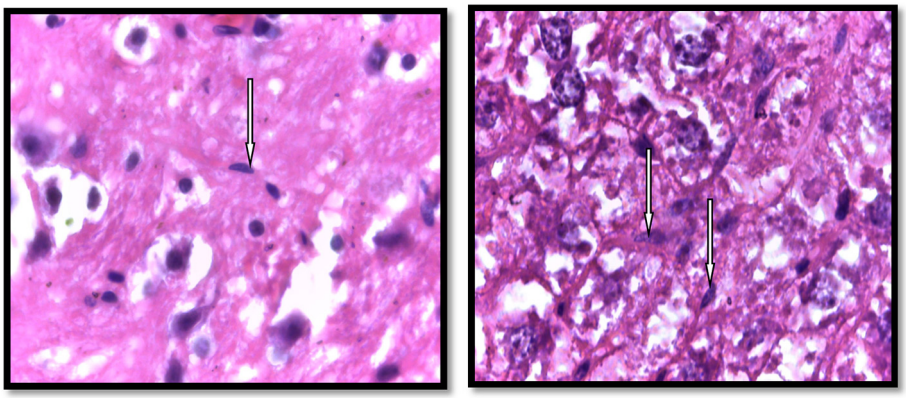

(A) (B)

Fig. 5. Its showing ciliates in different tissues within infected mice (whit arrow) (A) Brain tissue (B) Liver tissue . H& E staining 100X.

6.4. Experimental infection

Clinical signs : The affected mice showed abnormal behavior compare with non affected mice such as fear ,imbalance and lack of movement were noted .

After dissection of infected mice appeared obvious swelling within brain as well as hepatomegaly ,were only noted in first group Fig. 4. Histopathological examination confirmed that infected mice had systemically infection with ciliates where present within examined tissues (brain & liver) Fig. 5.

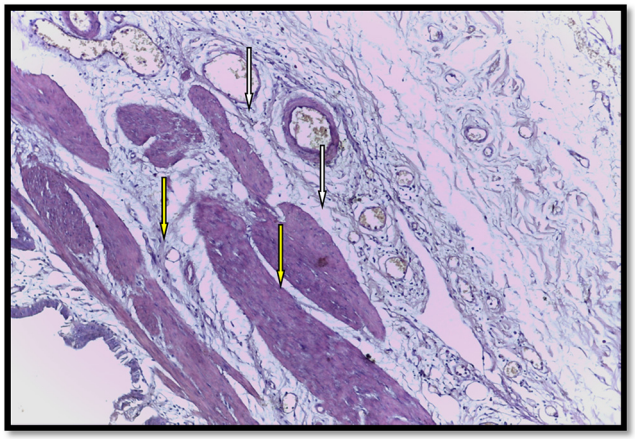

Fig. 6. Histopathological changes in the brain tissue of infected mice showing vacuolated parenchymal in cell cerebral cortex (yellow arrow) and dilation of smal blood (whit arrow.) H&E staining 10X . (For interpretation of the references to colour in this figure legend, the reader is referred to the web version of this article.)

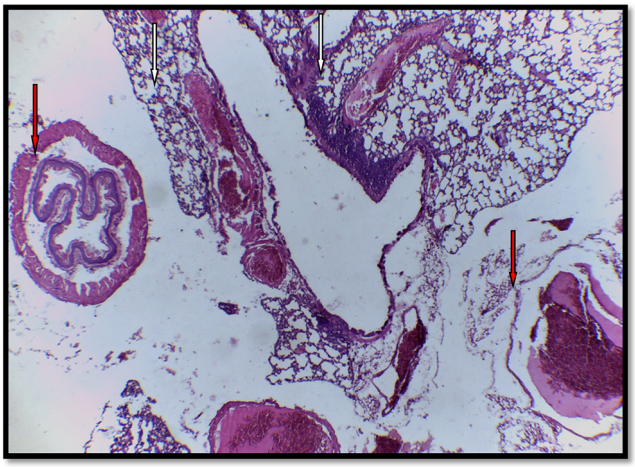

Fig. 7. The arachnoid matters as a part of brain tissue in infected mice appeared with congestion(whit arrow) and great dilation in arteries(red arrow) . H&E staining 4X . (For interpretation of the references to colour in this figure legend, the reader is referred to the web version of this article.)

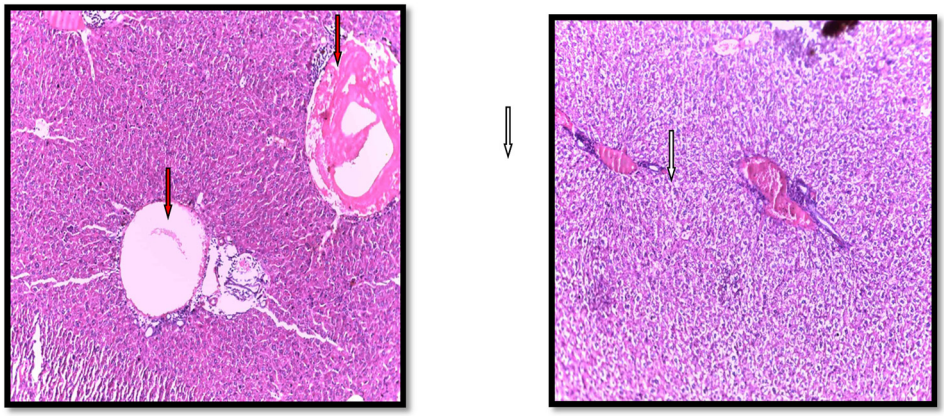

(A) (B)

Fig. 8. This microphoto of liver section which is infected with ciliates (A) dilatation of blood vessels(red arrow) . H&E staining : 10X (B) congestion of blood vessels(whit arrow) 4X. (For interpretation of the references to colour in this figure legend, the reader is referred to the web version of this article.)

€Histological structure of infected brain showing parenchymal cell in cerebral cortex underwent from vacuolation especially in pyramidal neurons and pyknosis in glial cells as well as it could be noted dilation of small blood vessels within cortical tissue Fig. 6, in addition, the congestion and great dilation in arteries within arachnoid matters were observed moreover the hemorrhage within arachnoid parenchyma was obviously recognized Fig. 7.

entral hepatic . Furthermore disorganization of liver paranchymal tissue Fig. 8.

7. Discussion

In this study *Mesanophrys* sp. like ciliates was iolated for the first time from CSF samples from patients with meningitis from Thi-Qar province / Iraq. We were investigating about opportunistic free living amoeba , throughout examination the cultured CSF on NN Agar medium . It was surprisingly we found the ciliates protozoa (Orchitophryidae) in both stages, vegetative and cystic ,. in two samples among eight samples of CSF , it observed through microscopic examination . In this study that the ciliates were isolated and cultured in vitro and then morphological ,molecular and virulence characterizations were studies .

In this study microscopic examination showed that the morphological characteristics of live the ciliates from cultured CSF was similar to genus *Mesanophrys* belong to family orchitophryidae . The ciliates had a pointed anterior and a rounded posterior with a granular structure of the cytoplasm and one macronucleus and one micronucleus, it's length was between 40 and 55 μm and 12.5–15 μm in width , similar to these finding, previous studies also identified *Orchitophrya or Mesanophrys* like ciliates [17,18;9]. .

Indicating the limitation of distinguishing and identifying ciliates by morphological analysis the ciliates can be accurately classified by molecular studies[16]) . In this study the rDNA sequences of the ciliates were amplified and had a high percent identity with Orchitophrydiae family 98.56% and 97.92% but not highly similar to *Mesanophrys* , may be this ciliates in our study is a new species for *Mesanophrys* .

From the experimental infection the ciliates could enter mice through the wound made by artificial cutting. In this study histopathological results showed that *Mesanophrys* like ciliates appeared in the brain and liver tissues of infected mice and causing a sever tissue damage . our study indicate the ciliates opportunistically invade human body by wound and can cause systemic infection .

Few studies have shown that these ciliates may be opportunistic parasites ,Small et al., [18] showed a histophagous ciliates infection was discovered in a number of Nroway lobsters from the clyde sea area, the cultured ciliates and structural features that are morophologically similar to scuticociliate in the genus *Mesanophrys* .

The experimental infection confirmed that *Mesanophrys* sp. was the pathogen that infected farmed crabs in China [9,17]) .

In summary the ciliates parasites isolated from human CSF is morphologically very similar to members of the genus *Mesanophrys* but rDNA sequences of the ciliates were amplified and had a high percent identity with Orchitophrydiae family but not highly similar to *Mesanophrys* ,may be this ciliates in our study is a new species for *Mesanophrys* . It is suggested that these ciliates can be a great threat to human.

Declaration of Competing Interest

The authors declare that they have no known competing financial interests or personal relationships that could have appeared to influence the work reported in this paper.

References

[1] J.C. Thompson, J. Berger, Paranophrys marina n.g., n. sp., a new ciliate associated with a hydroid from the northeast pacific (ciliate : Hymenostomatida), J. Protozool. 12 (1965) 527–531.
[2] W.B. Stickle, E.N. Kozloff, M.C. Henk, The ciliate *Orchitophrya stellarum* viewed as a facultative parasite of asteroid sea stars, Cah. Biol. Mar. 48 (2007) 9–16.
[3] G.A. Messick, E.B. Small, Mesanophrys chesapeakensis n. sp., a histophagous ciliate in the blue crab, Callinectes sapidus and associated histopathology, Invertebrate Biology. 115 (1) (1996) 1–12.
[4] M. Byrne, A. Cerra, T. Nishigaki, M. Hoshi, Infestation of the tes-tes of the Japanese sea star *Asterias amurensis* by the ciliate *Orchitophrya stellarum*: a caution against the use of this ciliate for bio-logical control, Dis. Aquat. Organ. 28 (1997) 235–239.
[5] W.B. Stickle, E.H. Weidner, E.N. KozloV, Parasitism of Leptaste-rias spp. (Echinodermata: Asteroidea) by the ciliated protozoan *Orchitophrya stellarum* (Scuticociliata), Invertebr. Biol. 120 (2001) 88–95.
[6] S.M. Bower, G.R. Meyer, *Stegotricha enterikos* gen. n., sp. n. (ClassPhyllopharyngea, Order Rhynchodida), a parasitic ciliate in the digestive gland of PaciWc oysters (Crassostrea gigas) and its distribution inBritish Columbia, Can. J. Zool 71 (1993) 2005–2017.
[7] R.A. Elston, D. Cheney, P. Frelier, D. Lynn, Invasive orchitophr-yid ciliate infections in juvenile PaciWc and Kumomoto oysters, Cras-sostrea gigas and Crassostrea sikamea, Aquaculture 174 (1999) 1–14.

[8] A.Y. Karatayev, L.E. Burlakova, D.P. Molloy, L.K. Volkova, V.V. Volosyuk, Field and laboratory studies of Ophryoglena sp. (Ciliata:Ophryoglenidae) infection in zebra mussels, Dreissena polymorpha(Bivalvia: Dreissenidae), J. Invertebr. Pathol. 79 (2002) 80–85.

[9] L. Xiao, L. Yuhua, R. Zhiming, Z. Suming, Q. Dong, Y. Youbin, Y. Fei, W. Chunlin, Isolation, characterization and virulence of Mesanophrys sp. (ciliophora : orchitophrydiae) in farmed swimming crab (Protunus trituberculatus) in eastern china, Journal of Fish disease.43(11) (2020) 1419–1429.

[10] C. Costache, S. Bursasiu, C. Filipas, I. Colosi, A Case of ciliate protozoa *Colpoda* spp. (ciliata : colpodidae) detected in human urine. Iranian, J. Parasitol. 6 (4) (2011) 99–104.

[11] A. AL-Duboon, M.A. Disher, First incidence of the ciliophoran fresh water fish pathogen Trichophrya piscium Butschli, 1899 as a human pathogen from Basrah, Iraq. Biological and Applied Envir. Rese. 2 (2) (2018) 154–161.

[12] A.R. Drury, E.A. Walungton, R.S. Camero, Carleton's histological technique, 4th ed., Oxford University Press, London, 1976.

[13] A. Dopheide, L. Gavin, S. Rebecca, L. Gillian, Molecular characterization of ciliate diversity in stream biofilms, Appl. And Environ. Microbiolo. 74 (6) (2008) 1740–1747.

[14] Goggin, C. L., and Murphy, N. E. (2000). Conservation of sequence in the internal transcribed spacers and 5.8 S ribosomal RNA among geographically separated isolates of parasitic scuticociliates (Ciliophora, Orchitophryidae). Diseases of Aquatic Organisms , 40 , 79–83. Gold, K. (1971).

[15] H.J. Small, D.M. Neil, A.C. Taylor, K. Bateman, G.H. Coombs, A parasitic scuticociliate infec-tion in the Norway lobster (Nephrops norvegicus), Journal of Invertebrate Pathology 90 (2005) 108–117.

[16] D. Tautz, P. Arctander, A. Minelli, R.H. Thomas, A.P. Vogler, A plea for DNA taxonomy, Trends Ecol. Evol. 18 (2003) 70–74.

[17] A.T. Jalil, A.H.D. Al-Khafaji, A. Karevskiy, S.H. Dilfy, Z.K. Hanan, Polymerase chain reaction technique for molecular detection of HPV16 infections among women with cervical cancer in Dhi-Qar Province, Materials Today: Proceedings (2021).

[18] A.T. Jalil, S.H. Dilfi, A. Karevskiy, Survey of Breast Cancer in Wasit Province, Iraq, Global Journal of Public Health Medicine 1 (2) (2019) 33–38.

Further reading

[19] Jalil, A. A. T. Epidemiology of cervical cancer and high risk of human papilloma virus in patient. ББК *28.6 З*, *85*(7).

[20] A.T. Jalil, Dilfy, A. Karevskiy, N. Najah, Viral Hepatitis in Dhi-Qar Province: Demographics and Hematological Characteristics of Patients, International Journal of Pharmaceutical Research 12 (1) (2020).

[21] E.H. Mezal, A.F. Yousif, Z.K. Hanan, A.K. Hanan, A. Jalil, Isolation, Assessment of Antimicrobial Sensitivity of Bacterial Pathogens from Post-Cesarean section Infection of patients in Thi-Qar Province, European Journal of Molecular & Clinical Medicine 7 (3) (2020) 958–964.

[22] N.N. Mubark, A.T. Jalil, S.H. Dilfi, Descriptive study of hydatidiform mole according to type and age among patients in was it province, IRAQ. Global Journal of Public Health Medicine 2 (1) (2020) 118–124.

[23] S.H. Dilfy, M.J. Hanawi, A.W. Al-bideri, A.T. Jalil, Determination of Chemical Composition of Cultivated Mushrooms in Iraq with Spectrophotometrically and High Performance Liquid Chromatographic, Journal of Green Engineering 10 (2020) 6200–6216.

[24] A.T. Jalil, COVID-19 most affected age groups and lethality in Europe, Glob. J. Public Health Med 2 (2020) 179–184.

[25] A.T. Jaleel, Survey the prevalence of viral hepatitis A, B, C infection in dhi-qar province (IRAQ). ББК *20.1 А43 Редакционная коллегия: ИБ Заводник (отв. ред.), АЕ Каревский, ОВ Янчуревич*, ОВ Павлова, (2018) 95.

[26] A.T. Jalil, A. Karevskiy, The Cervical Cancer (CC) Epidemiology and Human Papillomavirus (HPV) in the Middle East, International Journal of Environment, Engineering & Education 2 (2) (2020) 7–12.