

COMPARATIVE STUDY BETWEEN OPTIMAL AND REDUCED FORMALIN-BASED FIXATIVE FOR NORMAL AND PATHOLOGICAL TISSUES

SAWSAN SALIH ALHAROON¹, NAWAL MUSTAFA ABDULLAH^{2*}, NADA HASHIM MOHAMED³

¹Department of Pathology and Forensic Medicine, College of Medicine, University of Basrah, Basrah, Iraq. ²Department of Anatomy, Histology and Embryology, Al-Zahra College of Medicine, University of Basrah, Basrah, Iraq. ³Department of Anatomy, Al-Zahra College of Medicine, University of Basrah, Basrah, Iraq. Email: nawal.m2019m@gmail.com

Received: 18 November 2019, Revised and Accepted: 23 December 2019

ABSTRACT

Objectives: This study aims to use an alternative fixative compound with reduced concentration of formalin to minimize the exposure and related side effects.

Methods: Human normal and pathological tissue samples of different organs were immediately immersed in a modified fixative containing formalin, glycerin, ethanol, and hypotonic saline with pH around 7. Two time schedules were used at 8 and 12 h. Tissue samples were undergone routine processing procedure used in histopathological laboratories, scoring of samples was done, tissue sections of new compound fixative were examined for cytoplasmic, nuclear, and architectural properties and compared with 10% neutral buffered formalin (NBF).

Results: Tissue samples treated with modified fixative showed good and acceptable preservation of structural, cellular details with less harmful effects when compared with those preserved with routine 10% (NBF).

Conclusion: The suitability and effectiveness of reduced formalin-based fixative in histological and histopathological routine examination with minimal harmful effects for laboratory worker.

Keywords: Formalin, New fixative, Histopathology, Tissue sections.

© 2020 The Authors. Published by Innovare Academic Sciences Pvt Ltd. This is an open access article under the CC BY license (<http://creativecommons.org/licenses/by/4.0/>) DOI: <http://dx.doi.org/10.22159/ajpcr.2020.v13i2.36400>

INTRODUCTION

Fixation of tissues is necessary for effective dissection, processing, and microscopical inspection of histopathological specimens. Phosphate-buffered formalin (10%) is used long time ago as fixative of choice. Formalin has many characteristic properties such as easy to use, low cost, and good morphological conservation, it infiltrates tissue rapidly and tolerates specific stains [1,2]. Formalin toxicity remains a major threatening factor for laboratory workers due to chronic and long use through daily practice [3].

Formaldehyde is known to have acute and chronic damaging effects on the health of exposed groups such as anatomy students, anatomists, embalmers, cadaver handlers, and pathologists [4-6]. Formalin is absorbed efficiently from the mucous membranes of eyes and respiratory tract causing local irritation, a sudden contact with high doses may cause pulmonary edema while repeated or prolonged contact can lead to allergic manifestations [7-10]. Many studies linked formalin to the high incidence of hematopoietic and lymphoid malignancies among anatomists and embalmers in the United States [11-13]. It may alter gene expression and affect the signaling associated with cancer, inflammatory response, and endocrine system [4,14,15]. Multiple human and animal studies are available in literatures which support the mutagenic, carcinogenic, and teratogenic potential of formaldehyde [16,17].

A number of reports from the International Agency for Research on Cancer and others correlate leukemia to formalin exposure; therefore, strict limits for exposure were monitored worldwide [18-21]. This study aims to evaluate the suitability of reduced formalin compound fixative and to minimize the exposure with reasonable validity and less harmful effects.

METHODS

A compound fixative contains different minimal concentrations of 10% formalin 7 ml in addition to glycerin 5 ml, absolute alcohol 20 ml, and hypotonic saline, the pH is adjusted near 7. Alcohol used for dehydration can cause shrinkage of cells while adding of hypotonic saline is beneficial to reduce the dehydration in addition, glycerin will minimize evaporation, the fixative prepared has a light blue color by adding methylene blue 0.05 g. Buffers such as sodium dihydrogen phosphate monohydrate 4 g and anhydrous disodium hydrogen phosphate 6 g were added. The pH is maintained near 7 and then the solution is completed to 100 ml by adding of hypotonic saline.

Different human histological samples from various sites were arranged into two categories, normal and pathological; fixation was done by two methods, the first using 10% neutral buffered formalin (NBF) and the second by the new fixative, in which samples were directly fixed at two different time schedules; 8 and 12 h then completed by classical conventional tissue processing procedure. Four-micron thickness sections were obtained, stained with hematoxylin and eosin, examined, and scored for nuclear, cytoplasmic, and architectural assessments; the time table for each procedure was linked to both modified and conventional 10% NBF. The nuclear assessment was evaluated by examining the size, membrane maintenance, chromatin pattern, and mitotic entity, while cytoplasmic features were shown for the color, abundance, granules, and mucin, to assess the architectural criteria, the staining properties, integrity of membranes, pigment, and artifacts deposition were observed.

In general, if nuclear, cytoplasmic, or structural features are ill defined, it is considered as poor with score 1, less defined features were given score 2, and score 3 was given for good or well-preserved

tissues (Table 1). For 10% NBF fixative, the nuclear, cytoplasmic, and architectural properties were considered as an absolute fixation (optimal) and given score 3. The results were tabulated and analyzed. $p < 0.05$ is regarded as statistically significant.

RESULTS

Forty-seven normal and pathological samples were fixed in the modified fixative. Among them, 11 cases (23.4%) were breast tissues, 10 cases uterus (21.2%), 10 cases skin (21.2%), 7 cases thyroid (14.8%), 5 cases ovary (10.6%), and 4 cases pancreas (8.5%). Another similar 47 specimens were fixed in 10% NBF.

The architectural, cellular, and nuclear details of normal and pathological tissues fixed in the modified compound were compared with optimal fixative, for the consistency of tissues both illustrate the same features, but for cytoplasmic changes, the comparison showed that only two specimens had faint color and less noticeable cytoplasmic granules at 8 h, Fig. 1 (score 2). Commonly, a good preservative feature was obtained by the new fixative for both normal and pathological specimens at 12 h (score 3). No statistically significant differences were found when it is compared with 10% NBF (Table 2 and Figs. 1-3).

For nuclear changes, the majority of specimens (46) fixed in the new fixative obtained the same nuclear criteria (no nucleoli changes and

constant mitotic figures) at 8 and 12 h. No significant difference was detected when compared with 10% NBF (Table 3 and Figs. 4-6).

Table 1: Score evaluation

Score marks	Quality of fixative
3	Optimal=good
2	Intermediate
1	Poor

Table 2: Comparison of cytoplasmic features between new fixative and 10% NBF

Fixative	Score 3	Score 2	Score 1	p value
10% NBF	47	0	0	4.058
New fixative, 8 h	45	2	0	2.000
New fixative, 12 h	47	0	0	0.131

$p > 0.05$ is N.S, NBF: Neutral buffered formalin

Table 3: Comparison of nuclear changes between new fixative and 10% NBF

Fixative	Score 3	Score 2	Score 1	p value
10% NBF	47	0	0	4.058
New fixative, 8 h	46	1	0	2.000
New fixative, 12 h	47	0	0	0.470

$p > 0.05$ is N.S, NBF: Neutral buffered formalin

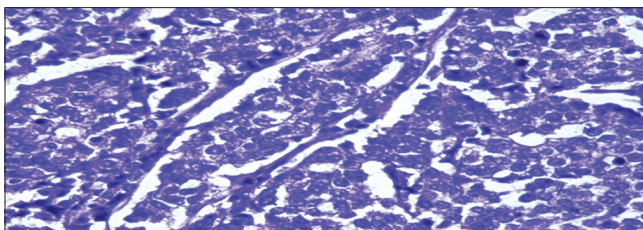


Fig. 1: Histopathological features of pancreatic neuroendocrine tumor - new fixative, 8 h. Hematoxylin and eosin (×40)

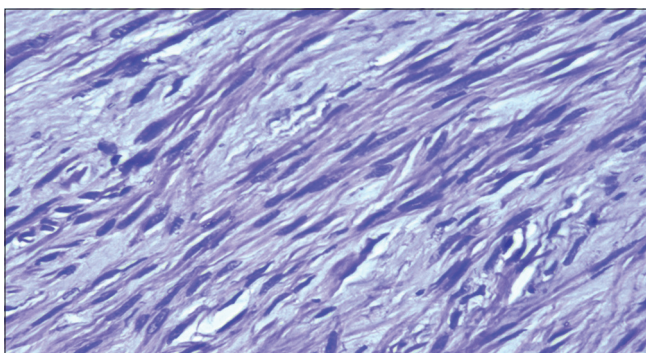


Fig. 2: Histopathological features of uterine leiomyoma (fibroid) - new fixative, 12 h. Hematoxylin and eosin (×40)

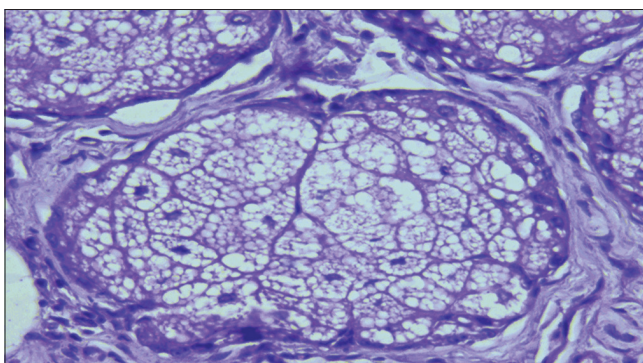


Fig. 3: Histopathological features of normal sebaceous gland of the skin - new fixative, 12 h. Hematoxylin and eosin (×40)

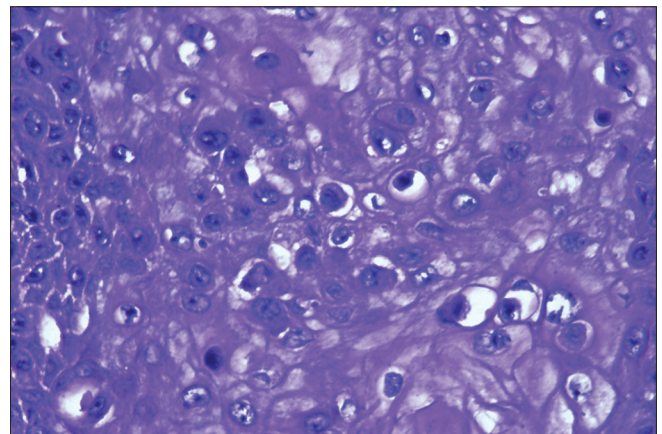


Fig. 4: Histopathological features of skin squamous cell carcinoma - new fixative, 12 h. Hematoxylin and eosin (×40)

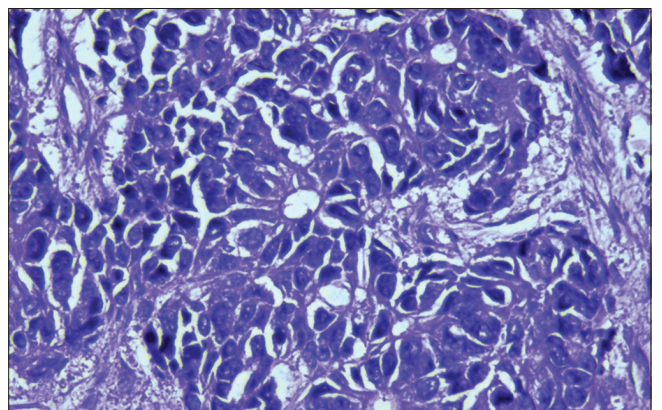


Fig. 5: Histopathological features of ovarian serous adenocarcinoma - new fixative, 12 h. Hematoxylin and eosin (×40)

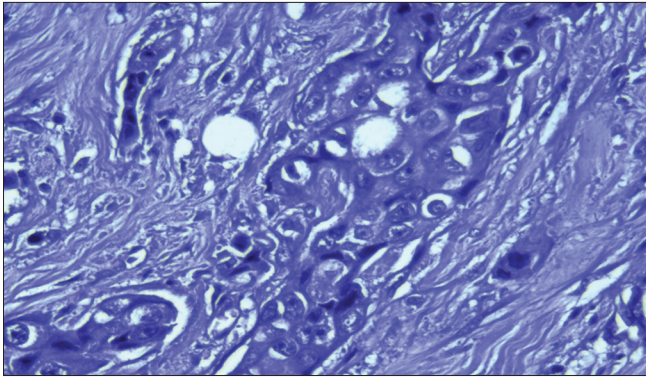


Fig. 6: Histopathological features of breast invasive ductal carcinoma - new fixative, 12 h. Hematoxylin and eosin ($\times 40$)

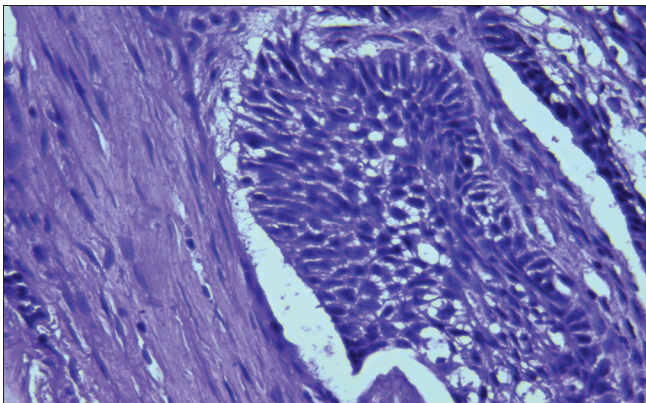


Fig. 7: Histopathological features of skin basal cell carcinoma - new fixative, 12 h. Hematoxylin and eosin ($\times 40$)

Table 4: Comparison between 10% NBF and the new fixative for architectural changes

Fixative	Score 3	Score 2	Score 1	p value
10% NBF	47	0	0	4.058
New fixative, 8 h	47	0	0	2.000
12 h	47	0	0	0.131

$p > 0.05$, NBF: Neutral buffered formalin

Regarding architectural changes, no significant changes (no shrinkage, no pigment deposition, or cracking) at 8 and 12 h were observed (Table 4 and Figs. 7-9).

DISCUSSION

An optimal fixative should be non-toxic with detailed morphology, high-quality histochemical and immunohistochemical staining properties, respectable preservation of nuclear details, and a reasonable price [22].

The toxicity of formaldehyde is evolving as the main issue for its diminishing as a general fixative used in large amounts in histopathology. Laboratory workers are frequently in contact with different formalin concentration and vapor in addition to the role of formalin as chemical carcinogen which should be given attentions. Recently, chromosomal variations have been noticed in laboratory workers of pathological fields [16,23,24].

Many attempts have been tried to replace formalin with other fixatives being harmless and frequently used. A non-cross-linking fixative such as FinFIX (Milestone, Bergamo, Italy) [25] and RCL2 (Alphelys, Plaisir, France) [26] has been proposed as NBF alternatives. Advantages of this type of fixation include quick fixation, dismissal of carcinogenic vapor.

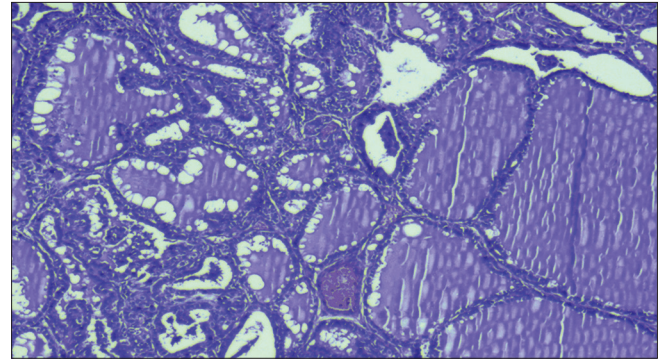


Fig. 8: Histopathological features of thyroid multinodular goiter - new fixative, 12 h. Hematoxylin and eosin ($\times 10$)

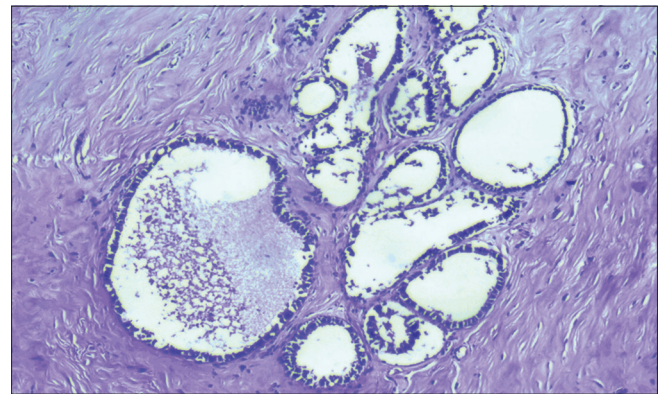


Fig. 9: Histopathological features of breast fibrocystic changes - new fixative, 12 h. Hematoxylin and eosin ($\times 10$)

DNA and RNA glycogen defined preservation, the disadvantages are tissues that have faint color, variability of tissue staining, hardening, artifact pigment deposition in bloody specimens, partial or complete lysis of erythrocytes, and increased flammability compared with 10% NBF. Other alternatives include PAGA, ZBF, Z7, and cell block which show faint color and tissues are soft with slippery consistency and difficult for processing [26].

The current study showed that the new fixative had light blue color with good consistency, had significantly less irritant odor; besides, it is easily processed and suitable for light microscopical examination. The two fixatives showed no significant differences at 8 and 12 h and both are acceptable for nuclear and cytoplasmic preservation, by reducing the formalin concentration from 10 to 7, the exposure will be reduced, furthermore, alcohol acts by eliminating water molecule from tissues which lead to cell contraction [27], to tolerate this, the hypotonic saline is added, good and acceptable fixative will be obtained.

CONCLUSION

The present study demonstrates that reduced formalin fixative can easily be prepared and replaced the 10% NBF for routine histopathological laboratory work with easy and less toxic side effects. Further studies involving this new fixative in histochemical and immunohistochemical tissue procedures will be recommended.

ACKNOWLEDGMENT

The authors are especially grateful to the laboratory assistants who have helped to complete this research.

AUTHORS' CONTRIBUTIONS

Dr. Nawal and Dr. Sawsan contributed to the collection of the tissue samples and preparing the slides for examination; Dr. Nawal

and Dr. Nada were involved in manuscript writing, editing, and finalization.

CONFLICTS OF INTEREST

The authors declare that they have no conflicts of interest.

REFERENCES

- Titford ME, Horenstein MG. Histomorphologic assessment of formalin substitute fixatives for diagnostic surgical pathology. *Arch Pathol Lab Med* 2005;129:502-6.
- Vincek V, Nassiri M, Nadji M, Morales AR. A tissue fixative that protects macromolecules (DNA, RNA, and protein) and histomorphology in clinical samples. *Lab Invest* 2003;83:1427-35.
- Moelans CB, ter Hoeve N, van Ginkel JW, ten Kate FJ, van Diest PJ. Formaldehyde substitute fixatives. Analysis of macroscopy, morphologic analysis, and immunohistochemical analysis. *Am J Clin Pathol* 2011;136:548-56.
- Zhang L, Tang X, Rothman N, Vermeulen R, Ji Z, Shen M, et al. Occupational exposure to formaldehyde, hematotoxicity, and leukemia-specific chromosome changes in cultured myeloid progenitor cells. *Cancer Epidemiol Biomarkers Prev* 2010;19:80-8.
- Gardner MJ, Pannett B, Winter PD, Cruddas AM. A cohort study of workers exposed to formaldehyde in the British chemical industry: An update. *Br J Ind Med* 1993;50:827-34.
- Akbar-Khanzadeh F, Mlynek JS. Changes in respiratory function after one and three hours of exposure to formaldehyde in non-smoking subjects. *Occup Environ Med* 1997;54:296-300.
- Kulle TJ, Sauder LR, Hebel JR, Green DJ, Chatham MD. Formaldehyde dose-response in healthy nonsmokers. *JAPCA* 1987;37:919-924.
- Lang I, Bruckner T, Triebig G. Formaldehyde and chemosensory irritation in humans: A controlled human exposure study. *Regul Toxicol Pharmacol* 2008;50:23-36.
- Porter JA. Letter: Acute respiratory distress following formalin inhalation. *Lancet* 1975;2:603-4.
- Rager JE, Smeester L, Jaspers I, Sexton KG, Fry RC. Epigenetic changes induced by air toxics: Formaldehyde exposure alters miRNA expression profiles in human lung cells. *Environ Health Perspect* 2011;119:494-500.
- Kim KH, Jahan SA, Lee JT. Exposure to formaldehyde and its potential human health hazards. *J Environ Sci Health C Environ Carcinog Ecotoxicol Rev* 2011;29:277-99.
- Costa S, Coelho P, Costa C, Silva S, Mayan O, Santos LS, et al. Genotoxic damage in pathology anatomy laboratory workers exposed to formaldehyde. *Toxicology* 2008;252:40-8.
- Binetti R, Costamagna FM, Marcello I. Development of carcinogenicity classifications and evaluations: The case of formaldehyde. *Ann Ist Super Sanita* 2006;42:132-43.
- International Agency for Research on Cancer. Overall Evaluations of Carcinogenicity. IARC Monographs on the Evaluation of Carcinogenic Risk of Chemicals to Humans. Lyon, France: International Agency for Research on Cancer; 1987. p. 440.
- Schwilk E, Zhang L, Smith MT, Smith AH, Steinmaus C. Formaldehyde and leukemia: An updated meta-analysis and evaluation of bias. *J Occup Environ Med* 2010;52:878-86.
- Hauptmann M, Stewart PA, Lubin JH, Freeman LE, Hornung RW, Herrick RF, et al. Mortality from lymphohematopoietic malignancies and brain cancer among embalmers exposed to formaldehyde. *J Natl Cancer Inst* 2009;101:1696-708.
- IARC Monographs on the Evaluation of Carcinogenic Risks to Humans Volume 100F: A Review of Human Carcinogens: Chemical Agents and Related Occupations. In Formaldehyde; 2012. Available from: <http://www.monographs.iarc.fr/ENG/Monographs/vol100F/mono100F-29.pdf>.
- Code of Federal Regulations. Occupational safety and health administration code of federal regulations: Toxic and hazardous substances. In: Formaldehyde. USA: Code of Federal Regulations; 2007. p. 1910-1048.
- International Agency for Research on Cancer. Formaldehyde, 2-butoxyethanol, and 1-tert-butoxy-2-propanol: IARC Monographs on the Evaluation of Carcinogenic Risks to Human. Geneva, Switzerland: International Agency for Research on Cancer; 2006. p. 88.
- Cogliano VJ, Grosse Y, Baan RA, Straif K, Secretan MB, El Ghissassi F. Meeting report: Summary of IARC monographs on formaldehyde, 2-butoxyethanol, and 1-tert-butoxy-2-propanol. *Environ Health Perspect* 2005;113:1205-8.
- Acton A, Harvey T, Grow MW. An examination of non-formalin-based fixation methods for *Xenopus* embryos. *Dev Dyn* 2005;233:1464-9.
- Buesa RJ. Histology without formalin? *Ann Diagn Pathol* 2008;12:387-96.
- Balbi T, Cicognani A, Esposti PD, Pierini G. Microwave processing and ethanol-based fixation in forensic pathology: An addendum of further scanning electron microscope observations. *Am J Forensic Med Pathol* 2009;30:242-5.
- Warmington AR, Wilkinson JM, Riley CB. Evaluation of ethanol-based fixatives as a substitute for formalin in diagnostic clinical laboratories. *J Histotechnol* 2000;23:299-308.
- Zanini C, Gerbaudo E, Ercole E, Vendramin A, Forni M. Evaluation of two commercial and three home-made fixatives for the substitution of formalin: A formaldehyde-free laboratory is possible. *Environ Health* 2012;11:59.
- Masir N, Ghoddoosi M, Mansor S, Abdul-Rahman F, Florence CS, Mohamed-Ismail NA, et al. RCL2, a potential formalin substitute for tissue fixation in routine pathological specimens. *Histopathology* 2012;60:804-15.
- Griesemer RA. Report of the federal panel on formaldehyde. *Environ Health Perspect* 1982;43:139-68.

Author Query???

AQ1:Kindly review the sentence as it seems to be incomplete.