

## **A STUDY OF TOXIC EFFECT OF SODIUM BENZOATE, VIT. C ALONE AND THEIR COMBINATION ON REPRODUCTIVE FUNCTIONS OF ADULT MALE RABBITS**

Shahid M., Nawras A. Alwan and Eman Aboud Al-Masoudi

Department of Physiology, Pharmacology and Chemistry. College of Veterinary Medicine, University Basrah, Basrah, Iraq.

**Key words:** Sodium benzoate, Vitamin C, Testosterone.

*Corresponding Author: hind\_abdelah@yahoo.com*

### **ABSTRACT**

The present study was designed to determine the adverse effect of sodium benzoate (SB), vitamin C (Vit.C) alone and of their combination on reproductive functions in rabbits. Thirty-six adult male rabbits were divided randomly into six equal groups. Group 1 (Control group) received orally distilled water, group 2: Vit.C (200mg/kg BW/day) received orally, group 3: received orally SB (60 mg/kg BW/day), group 4: received orally SB (120 mg/kg BW/day). Group 5: received orally SB+Vit.C (60+200 mg/ kg BW/day) and group 6: received orally SB+Vit.C (120+200 mg/ kg BW/day). The result revealed a significant decrease in serum testosterone concentrations in all treated groups as compared with Vit.C and control group. Significant differences were observed in sperm concentration, viability, abnormality and significant decrease in sperm motility in groups treated with combination of SB and Vit.C as compared with control. A significant improvement in sperm concentration, sperm motility, viability and abnormality in G2 (Vit.C) group compared with all-treated groups. Histopathological changes in testicular tissues in groups treated with SB+Vit.C showed marked vacuolation and degeneration of seminiferous tubules, with arresting of spermatogenesis.

### **INTRODUCTION**

Sodium benzoate is a salt of benzoic acid has chemical formula  $C_7H_5NaO_2$  it is white in colour, odorless crystalline and found as Powder or grain. This compound is

easily dissolved in water and hardly dissolved in ethanol. Its molecular weight is 114.11. Its solubility is enhanced by increasing water temperature. Its harmlessness was confirmed first in 1909 by the department of agriculture in America, during three separate investigations (1 & 2).

Sodium benzoate is regarded as preservative, food additive, and it has the E number E211, It is bacteriostatic and fungi static under acidic conditions. This compound has been reported to cause detrimental adverse effect in the body, when is indirectly consumed by the human population as food additives (3). In the United States, benzoic acid and sodium benzoate are on the Food and Drug Administration (FDA) list of substances that are generally recognized as safe (GRAS). Both may be used as antimicrobial agents, flavor in agents and as adjuvant with a current maximum level of 0.1% in food. The FDA did not determine whether significantly different conditions of use would be GRAS.

Ascorbic acid (Vit.C) is considered as a potent antioxidant, which eliminates reactive oxygen and nitrogen. Vit.C helps some of our most important body systems. It helps the immune system to fight the foreign invaders and carcinogenic cells. Vit.C also supports the cardiovascular system by facilitating fat metabolism and protecting tissues from free radical damage, it assists the nervous system by converting certain amino acids into neurotransmitters. In addition to its antioxidant functions, As it is a water –soluble antioxidant, vitamin C is in a unique position to "Scavenge" aqueous peroxy radicals before these destructive substances have a chance to damage the lipids. It works along with vitamin E, a fat-soluble antioxidant and the enzyme glutathione peroxidase to stop free radical chain reactions (4, 5 and 6) .

## MATERIALS AND METHODS

**Animals and housing:** Thirty six adult male rabbits were used in this study. All rabbits were weighed about (205.00±19.00). They were kept in animal house under constant environmental condition for 2 weeks to acclimatize before that beginning of the experiment. Food and drinking water were provided *ad libitum* throughout the experiment.

**Experimental Design:** adult male rabbits were divided randomly into six equal groups as follows:

**Group 1 (control):** six adult male rabbits orally administered distilled water (4 ml/animal) by gavage daily for 30 days.

**Group 2:** six adult male rabbits were orally administered Vit.C (100 mg/kg BW) (6) dissolved in 4 ml distilled water by gavage daily for 30 days.

**Group 3:** six adult male rabbits were orally administered sodium benzoate (60 mg/Kg BW) (7) dissolved in 4 ml distilled water by gavage daily for 30 days.

**Group 4:** six adult male rabbits were orally administered sodium benzoate (120 mg/Kg BW) (7) dissolved in 4 ml distilled water by gavage daily for 30 days.

**Group 5:** six adult male rabbits were orally administered sodium benzoate (60 mg/Kg BW) combination with Vit.C (100 mg/kg BW) dissolved in 4 ml distilled water by gavage daily for 30 days.

**Group 6:** six adult male rabbits were orally administered sodium benzoate (120 mg/Kg BW) combination with Vit.C (100 mg/kg BW) dissolved in 4 ml distilled water by gavage daily for 30 days.

#### **Epididymal sperm concentration:**

The sperms were counted according to the method of Robb *et al.* (8) by using Neubauer hemocytometer chamber which uses for RBC and WBC count.

#### **Procedure**

- 1- The epididymis were put in a Petri dish contained 5 ml of 0.9 % normal saline.
- 2- The epididymis was cut into 6 – 10 pieces by using sharp scalpel.
- 3- The suspension resulted from the previous step was filtered by a clean piece of gauze into a test tube.
- 4- One drop from the filtrate was dropped on the Neubauer chamber which covered previously with cover slid.
- 5- The sperms found on the five squares that use for counting the RBCs by using the objective lens (40 X).
- 6- The sperms were calculated in one mm<sup>3</sup> as follows

$$\text{Sperms/cm} = n * X 10000 \quad *n = \text{number of sperm in 5 squares.}$$

#### **Sperm motility percentage:**

The individual motility of epididymal sperms was measured depending upon the graduation basis that was suggested by Chemineau *et al.* (9) as follows:

- 1- Drop of diluted epididymal sperm was dropped into a warm, clean slide at 37°C and covered with cover slide.
- 2- Sperm were examined under microscope using 40X power.

Depending upon the progressive, forward sperm's movement , the strength and speed of their motion are converted into the percentage.

**Table (1): The percentage sperm's movement and the strength and speed of their motion (9):**

<i>Type of motion</i>	<i>Degree</i>	<i>Percentage</i>
Sperms move rapidly and straightly.	5	90 – 100
Sperms are rapid, move fast and some of them move in a circle.	4	75 – 85
Sperms go on a straight slope, without a shivering motion.	3	45 – 65
Simple irregular shivering motion, some of them move.	2	20 – 40
Movement is very slow, sperms shiver with swinging tail.	1	10
No movement.	0	0

### **Sperm abnormality:**

The percentage of abnormal spermatozoa were counted in the same slide that used for measurement of the viability of epididymal sperm using account 200 sperms under a light microscope using 100X power (10).

1. Diluted semen was dropped into a warm, clean slide.
  2. Warm eosin – nigrosine stain was dropped on the semen and mixed together carefully by use of a glass rod. A smear was done by using a clean slide which was put angularly on the semen slide and was dragged horizontally.
  3. The slide was left to dry.
  4. The slide was examined under the light microscope using 40X power. Live sperms appeared in white color and the dead sperms appeared in red color.
- Live sperms appeared in white color and the dead sperms appeared in red color.

**Biochemical Measurements:** the biochemical measurement was done on the serum after separation by using special enzymatic kits as follow:

**Testosterone ELISA Kit:** The quantitative determination of total testosterone concentration in serum or plasma by a microplate enzyme immunoassay (11).

## **RESULTS**

Effect of SB, Vit.C alone and of their combination on serum testosterone concentration of the treated adult male rabbits showed in table (2) after 30 days of treatment, the results appeared that there is significant decrease ( $P<0.05$ ) of sperm concentration, viability of sperm and sperm motility in all groups except group 2 while the more significant decrease was in the G5 and G6 as compared with control group and other groups. While the abnormality of the sperm appeared to be increased in all groups but the most significantly ( $p<0.05$ ) increase in G5 and G6 (those with combination of SB. and Vit.C) as compared with other groups. Regarding the level of serum testosterone the results revealed that, there was significant decrease ( $p<0.05$ ) in G5 and G6 as compared with other groups.

**Table (2): Effect of SB, Vit.C alone and their combination on testosterone hormone and epididymal sperm characteristics in adult male rabbits:**

parameters Groups (n=6)	Sperm Concentration ( $\times 10^6$ / ml)	Sperm motility (%)	Viability (%)	Abnormality (%)	Testosterone ng/ml
G1	84.00 $\pm$ 4.42 <sup>B</sup>	88.66 $\pm$ 2.0 <sup>A</sup>	89.83 $\pm$ 2.40 <sup>A</sup>	11.66 $\pm$ 1.63 <sup>f</sup>	9.31 $\pm$ 0.34 <sup>A</sup>
G2	97.83 $\pm$ 1.94 <sup>A</sup>	81.00 $\pm$ 2.52 <sup>B</sup>	83.00 $\pm$ 2.82 <sup>B</sup>	15.33 $\pm$ 1.36 <sup>E</sup>	8.51 $\pm$ 0.46 <sup>B</sup>
G3	63.50 $\pm$ 3.39 <sup>C</sup>	63.16 $\pm$ 2.92 <sup>c</sup>	61.16 $\pm$ 1.16 <sup>C</sup>	25.50 $\pm$ 2.66 <sup>D</sup>	8.06 $\pm$ 0.43 <sup>B</sup>
G4	54.50 $\pm$ 3.27 <sup>D</sup>	59.33 $\pm$ 2.16 <sup>D</sup>	58.33 $\pm$ 1.36 <sup>D</sup>	29.33 $\pm$ 1.96 <sup>c</sup>	7.22 $\pm$ 0.15 <sup>C</sup>
G5	30.33 $\pm$ 4.27 <sup>E</sup>	28.83 $\pm$ 2.78 <sup>E</sup>	27.50 $\pm$ 2.42 <sup>E</sup>	42.83 $\pm$ 1.94 <sup>B</sup>	6.49 $\pm$ 0.48 <sup>D</sup>
G6	28.66 $\pm$ 2.58 <sup>E</sup>	21.66 $\pm$ 2.16 <sup>F</sup>	19.83 $\pm$ 1.60 <sup>F</sup>	56.56 $\pm$ 3.16 <sup>A</sup>	4.88 $\pm$ 0.64 <sup>E</sup>
LSD	6.61	7.16	2.83	3.66	0.733

Values expressed in capital letters mean significant differences at (p< 0.05) levels (M $\pm$ SD).

### **Histological examination:**

The figure (1) of testes of normal control group (1) showed normal seminiferous tubules with normal spermatogenesis. In figure (2) testes of group 2 showed normal architecture of seminiferous tubules. While in figure (3) the testes of group 3 (60 mg SB) showed moderate vacuolation (V) of seminiferous tubules with complete suppression of spermatogenesis. Figure (4) histological section of testes in group 4 rabbits (120 mg SB)

showed severe vacuolation of seminiferous tubules with complete suppression of spermatogenesis, while in figure (5) the testes of group 5 (60mg SB+Vit.C) showed marked vacuolation of seminiferous tubules with arresting of spermatogenesis lastly in the histological section of testes in group 6 (120mg SB +Vit.C) showed moderate vacuolation of spermatogenesis with suppression of the spermatogenesis.



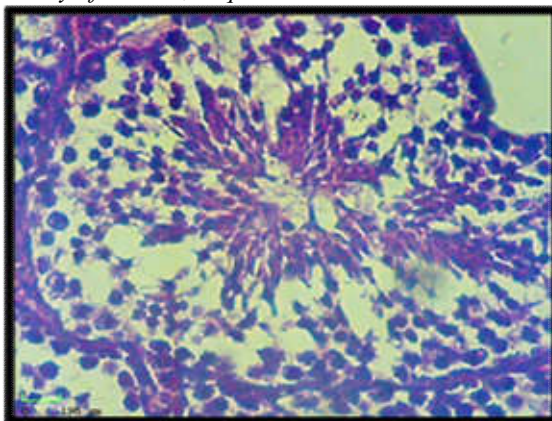


Fig (1) Histological section of testes of group1 (Control group) showed normal architecture of seminiferous tubules (H&E stain 400X).

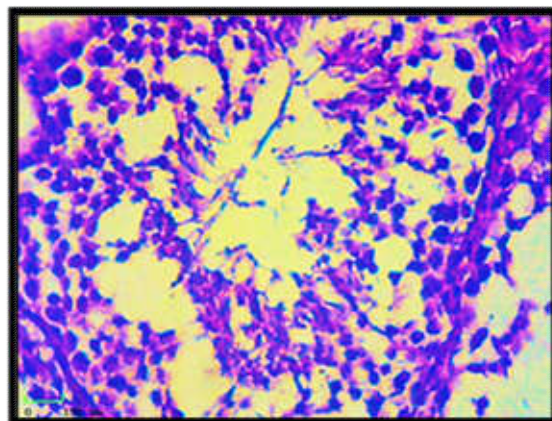


Fig. (2) Histological section of testes of group 2 (Vit.C) showed normal architecture of seminiferous tubules. (H&E stain 400X).

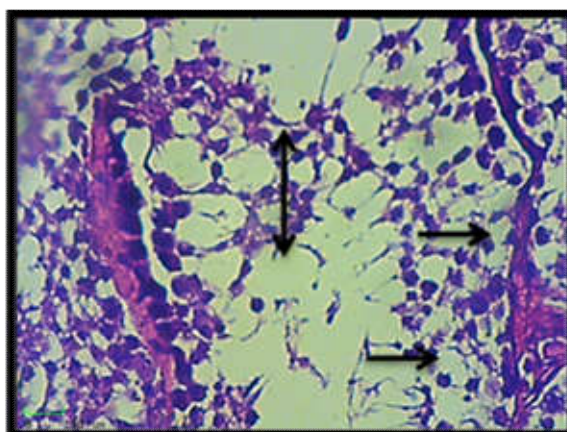


Fig. (3) Histological section of testes of group 3 (60 mg SB) showed moderate vacuolation of seminiferous tubules ( → ) also there's complete suppression of spermatogenesis ( ↔ ) (H&E stain 400X).

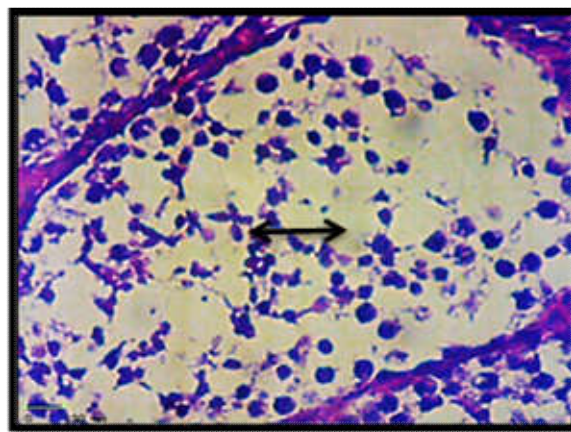


Fig. (4) Histological section of testes of group 4 (120 mg SB) showed sever vacuolation of seminiferous tubules (V) with complete suppression of spermatogenesis( ↔ ) (H&E stain 400X)

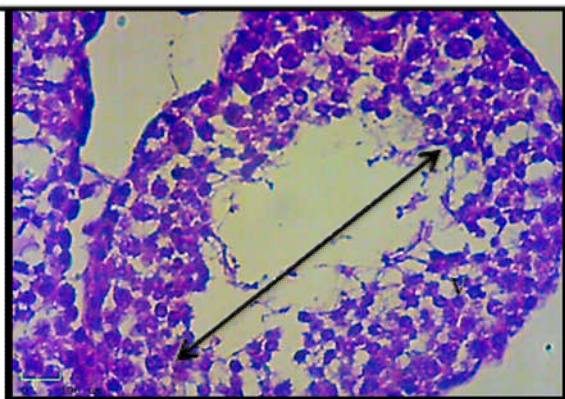


Fig (4-9) Histological section in testes group 5 (60mg SB+Vit.C) showed marked vacuolation of seminiferous tubules (V), with arresting of spermatogenesis( ↔ ) (H&E stain 400X).

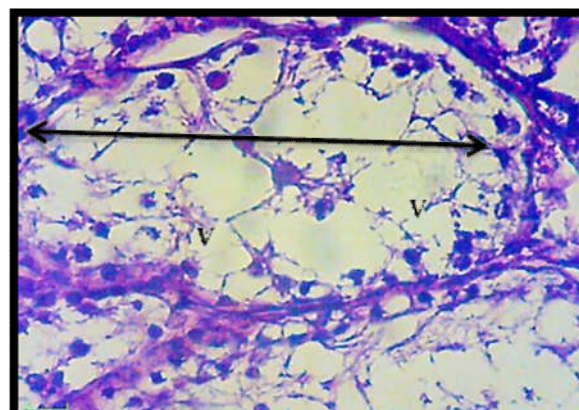


Fig (6) Histological section of testes of group 6 (120mg SB +V it.C) showed moderate vacuolation of seminiferous tubules (V) also there's suppression of spermatogenesis ( ↔ ) (H&E stain. 400X).



## **DISCUSSION**

Effect of SB and Vit.C alone and their combination on epididymal sperm characteristics and testosterone hormone, after 30 day of treatment, the result showed that significant decrease in all groups expect groups 1 and 2 while the more significant decrease in group 5 and 6 as compared the control group and the other groups. These results may be due to the adverse effect of combination of SB with Vit.C, these combination form benzene, benzene can be form when benzoate is decarboxylated in the presence of ascorbic acid and transition metals such as Cu +2 and Fe +3 and can be accelerated by light and heat (12). Dieter *et al.* (13) showed that benzene has further toxic effects after its metabolism in the liver by the cytochrome p450 E1 enzyme system.

These result are in agreement with 14. Ashamnu *et al.* (14) who found that Vit.C treatment of lead acetate intoxicated male mice resulted in significant improvement in sperm count and sperm abnormality compared with lead acetate group but still significantly lower than those of control. Similarly showed that swimming stress causes significant reduction in sperm count, sperm motility and sperm viability while administration of Vit.C in doses of 200 mg/kg can causes elevation of above parameter in a dose dependent manner compared with stress group but still significantly lower compared with control (15).

The reduction of sperm count and elevation in sperm abnormalities in animal stranded with pesticides (causes stress oxidation) so the reduction sperm count may be due to the interaction of ROS with sperm cell membrane the improvement of those parameter in Vit.C treated group be occurred due to the antioxidant effect of Vit.C which and neutralize the free radicals that generated from the oxidation stress. The histological section of testes in present study revealed histopathological changes in testes in groups treated with combination SB+Vit.C which showed marked vacuolation of seminiferous tubules (V), with arresting of spermatogenesis. These results agreed with previous studies have shown that administration of SB could altered the histological architecture of testis which appeared disruption of spermatogenic process and seminiferous tubules (16; 17).

Kehinde *et al.* (17) reported that the histological section of testes of group given SB and Vit.C appeared alter in sperm quality and function, the histological section of testes in

group treated with SB showed distorted spermatogenic cells and seminiferous tubules, deleterious basement membrane with lumen vacuolation while the group treated with combination of SB and Vit.C appeared disrupted of basement membrane, hyperplasia of Sertoli cells, deleterious lumen, degeneration of interstitium and disruption of spermatogenic cells while in group treated with Vit.C only showed normal testicular tissues with hyperplasia of Sertoli cells.

## REFERENCES

1. **Jay, J.M.; loessner, M.J. and Golden, D.A. (2005).** Modern food microbiology. 7<sup>th</sup> ed., *New York, Springer Sci.*; Pp.: 303-305.
2. **Makwana, S.; Choudhary, R.; Dogra, N.; Kohli, P. and Haddock, J. (2014).** Nano encapsulation and immobilization of cinnamaldehyde for developing antimicrobial food packaging material. *LWT-Food Sci. Technol.*; 57(2):470–6.
3. **Kubota, K. and Ishizaki, T. (1991).** Dose dependent pharmacokinetics of benzoic acid following oral administration of sodium benzoate to human. *Eur. J. and clin. Pharm.*; 41:363-368.
4. **Quadros, L.; Brandao, I. and Longhi, R. (2016).** Ascorbic acid and performance: A review. *Vitam. Miner.*; 5(1): 136-140.
5. **Li, S.; Tan, H.; Wang, N.; Zhang, Z.; Lao, L.; Wong, C. and Feng, Y. (2015).** The Role of Oxidative Stress and Antioxidants in Liver Diseases. *Int J Mol Sci.*; 16(11): 26087–26124.
6. **Pacier, C. and Martirosyan, D.M. (2015).** Vitamin C: optimal dosages, supplementation and use in disease prevention. *Funct. Foods in Heal. and Dis.*; 5(3): 89-107
7. **Ibekwe, S.E.; Uwakwe, A.A. and Monnv, M.O. (2007).** Effect oral intake of sodium benzoate on some hematological parameter of Wister albino rats. *Sci. Res. Essays.*; 2:006-009.
8. **Robb, G.; Amann, R. and Killian, G. (1978).** Daily sperm production and epididymal reserves of pubertal and adult rats. *J. Reprod. Fertil.*; 54:103-107.

9. **Chemineau, P.; Eagine, Y.; Orguer, P. and Nalet, J.C. (1991).** Training manual on artificial insemination in sheep and goat in animal production and health. *F. Ao. Roma*; pp.:83.
10. **Luna, L.G. (1968).** Manual of; histologic staining methods of the armed forces institute of pathology. 3<sup>rd</sup> ed. *McGraw-Hill, New York, NY*.
11. **Evans, G. and Maxwell, W.M.C. (1987).** Salamon's artificial insemination of Sheep and Goats. *Butterworths, Sydney, Australia*. Pp.: 40-42.
12. **Nyman, P.J.; Warner, W.J; Begleg, T.H.; Diachenko, G.W. and Perfetti, G.A. (2016).** Evaluation of accelerated UV and thermal testing for benzene formation in beverages containing benzout and ascorbic acid. *J. of Food Sci.*; 75: c263-c267.
13. **Dieter, S.; Orzechowski, A.; Schwarz, L.R.; Snyder, R.; Burchell, B.; Ingelman-Sundberg, M. and Bock, K.W. (1996).** Phase 11 Metabolism of Benzene. *Envir. Heal. Persp.*104(6):1183-1188.
14. **Ashamnu, E.A.; Salawu, E.O. and Oyewo, O.O. (2013).** Efficacy of vitamin c and ethanolic extract of sesamum in dicum in promoting fertility in male Wister rats. *Hum. Reporded. Sci.*; 3(1):11-14.
15. **Vi Jayprasad, S.; Ghongane, B.B.; and Nayak, B.B. (2014).** Effect of Vit.c on male fertility in rats subjected to forced swimming stress *J. Clin. Diagn. Res.*; 8(7):Hco5-08.
16. **Sohrabi, D.; Alipour, M. and Reza, M. (2008).** The effect of sodium benzoate on testicular gonadotropins and thyroid hormones level in adult (Balb/C) mice. *Feyz.*; 12:7-11.
17. **Kehinde, O.S.; Christianh, O.I. and Oyetunji, O.A. (2018).** Ascorbic acid and sodium benzoate synergistically aggravates testicular dysfunction in adult Wistar rats. *Int. J. Physiol. Pathophysiol. Pharmacol.*; 10(1): 39046.