

ACRYLAMIDE, MELATONIN, VITAMIN C AND COMBINATION OF ITS EFFECT ON ADRENAL GLAND FUNCTIONS IN MATURE MALE RATS

Nawras A. Alwan

Department of Physiology, Pharmacology and Chemistry, College of Veterinary Medicine, University of Basrah, Iraq.
e-mail : hind_abdelah@yahoo.com, <https://orcid.org/0000-0001-8101-2545>

(Received 30 October 2019, Revised 15 January 2020, Accepted 4 February 2020)

ABSTRACT : The aim of this study was to determine the ameliorative effect of Mel, Vit. C and/orit combination on acrylamide toxicities of Wistar rats (that ACR induced adrenal disfunctions) by biochemical and histological changes. This study was designed contain sixty male rats were divided into two periods, two groups in first period GA (control group): 20 male rats given 5ml of distal water and GII (ACR group): fourty male rats given ACR (0.5µg/kg BW/day) for 45 days. After 45 days the groups in the first period divided into six group: GA (normal control): give distal water orally, GB (positive control) give melatonin orally (5mg/kg BW/day), GC: ACR rats given distal water orally, GD: ACR rats given Mel (5mg/kg BW/day), GE: rats of ACR given Vit. C (200 mg/kg BW/day), GF: ACR rats given Mel+Vit. C (5+200 mg/kg BW/day) for 21 days. The result of this study revealed that significant differences in serum adrenocorticosteroid hormone levels were recorded in all treated groups compared with ACR-non treated group and still significantly higher compared with control. The adrenal histological sectioningroup treated with Mel showing the normal adrenal gland with normal cells of zona glomerulosa, zona fasciculata and zona reticularus with vacuolation and the adrenal gland of ACR-Vit.C group shows clear enlargement of its cells with the clear vacuolation and enlarged nuclei that compared these results with section of ACR treated group which stillshowing destructed cortex with distorted cells of large pyknotic nuclei and vacuolation. The adrenal gland of GF treated by doses of melatonin combination with vitamin C appeared clear capsule and normal cellular nuclei with the enlarged and vacuolated glomeruloza cells in adrenal histological section.

Key words : Acrylamide, melatonin, vitamin C, adrenal gland.

INTRODUCTION

Acrylamide defined as polyacrylamide of vinyl monomer for α , β -unsaturated and have a chemical formula ($\text{CH}_2\text{CH}-\text{CONH}_2$), it is a water soluble substance (Asha *et al*, 2008; Schwend *et al*, 2009). In foods, it is formed when cooked in high temperature, the acrylamide levels have been reported as 3500 µg/kg in potato chips and French fries. In April of 2002, it was detected firstly in foods and the results of toxicity studies on animals indicate that carcinogenicity of acrylamide, toxic effects in rodent caused on the nervous systems and reproductive while in the human causes only neurotoxicity, for metabolism, two ways of acrylamide occurs either by conjugation with glutathione or oxidation to glycidamide (Arvanitoyannis and Dionisopoulou, 2014).

Melatonin hormone is secretion in all types of bodily fluid (such as: saliva, cerebrospinal fluid, aqueous humor of the anterior chamber, breast milk and follicular fluid) and in blood. Receptors for the melatonin are distributed in all organs, tissues and in the brain (including the SCN): also present in the retina, spinal cord, thymus, adrenal

gland, pituitary gland, spleen, lungs, liver, kidney, testes, ovaries, heart, blood vessel and lymphocytes osteoblasts (Ishii *et al*, 2009 and Ikegami *et al*, 2009). The most effective lipophilic antioxidant of melatonin has been proven to be twice as active as vitamin C and E (it differs from other classic antioxidants), it has proved to be better protected against mitochondrial oxidative stress and amphiphilic properties (Lowe *et al*, 2013). Melatonin have stimulator actions on the another important antioxidant intracellular synthesis such as glutathione (Winiarska *et al*, 2006) and also its protection against oxidative damage of antioxidative enzyme (Mayo *et al*, 2005).

MATERIALS AND METHODS

Animals house : Sixty adult male rats were used in this study. They were kept in animal house under constant environmental condition for 2 weeks to acclimatization before beginning of the experiment. Food and drinking water were provided *ad libitum* throughout the experiment.

Design of experimental : In the first period, 60 adult male rats were divided into two groups as follows:

1-Cont G (n = 20) : Adult male rats administered distilled water daily by gavage for 45 days.

2-ACR G(n = 40) : Adult male rats administrated ACR (5mg/kg BW/day) for 45 days by gavage.

At the end of experimental period the animals of each group were divided into the following subgroups: The control group was divided into two equal groups:

- 1- **GA (-ve cont.):** mature male rats (n=10) orally administrated distal water by gavage for 21 days.
- 2- **GB (+ve cont.):** Mature male rats (n=10) orally administrated (5 mg/kg BW/day) orally for 21 days by gavage.

The ACR group (n=40) divided into four equal subgroups:

- 3- **GC (DW) :** Male rats (n=10) orally administrated distal water 2 ml by gavage for 21 days.
- 4- **GD (Mel) :** Male rats (n=10) orally administrated Mel 5mg/kg BW/day dissolved in 2ml distal water by gavage for 21 days.
- 5- **GE (Vit. C) :** Male rats (n=10) orally administrated Vit. C (200 mg/kg BW/day) dissolved in 2ml distal water by gavage for 21 days.
- 6- **GF (Mel & Vit. C) :** Male rats (n=10) orally administrated both Mel and Vit.C (5 mg/kg BW/day) dissolved in 2ml distal water by gavage for 21 days.

Anesthized the animals at the end of treated period (by using diethyl ether) and sacrificed. By cardiac puncture the blood samples were collected directly into disposable test tube to separate serum and stored at (-20°C). Excised the adrenal glands directly and fixed in 10% of neutral buffered formalin for histological study (Luna, 1968).

Biochemical measurements : These measurements were done on the separation serum by the following:

Serum corticosterone concentration estimation (ng/ml) : By use the corticosterone rat/mouse ELISA kit, the principle of this kit consists from a solid phase enzyme-linked immunosorbent assay (ELISA) depends on competitive binding principle (Garrido *et al*, 2010).

The procedure : Sufficient number of microplate wells prepared to calibrators and also duplicates the samples. 10µl Dispensed of each control, calibrator and samples into microplate wells. Incubation buffer (100µl) dispensed into each well. Then enzyme conjugate (50 µl) added into each well. Incubated microplate for 2 hours

on microplate mixer at room temperature. Discarded the content of the wells and 4 times rinse the wells with diluted wash solution and remove the wash solution as possible by microplate heating on absorbent paper. About 200µl substrate solution to each well was added. The microplate was incubated without shaking for 3 min. in dark place at room temperature. 50µl of stop solution adding for the reaction stopped. Last step the absorbance of wells read at 450nm. within 15 min.

RESULTS

Acrylamide, Melatonin, Vitamin C and their combination effect on concentrations of serum corticosterone in adult male rats

Twenty one days after treatment for, serum corticosterone concentrations revealed no significant differences between ACR-Mel and ACR-Mel+Vit. C treated groups compared with control while a significant (p<0.05) increased in serum corticosterone concentrations were recorded in control+Mel treated, ACR-DW and ACR-Vit. C treated groups compared with control and other treated groups and the high significant (p<0.05) value of corticosterone was recorded in ACR-non treated group compared with control and other treated groups.

Histological study of adrenal gland

Fig. 1 of adrenal gland section in the control group showed normal architecture with normal layers. In Fig. 2 showed section of adrenal gland in the group treated with ACR were destructed of cortex and destroyed cells of large pyknotic nuclei and vacuolation. Fig. 3 section of the normal adrenal gland in group treated with Mel showing normal cells of zona glomerulosa, zona fasciculata and zona reticularis with vacuolation. Adrenal gland of ACR-DW group appears destructed zona glomerulosa cells with large pyknotic nuclei and vacuolation in Fig. 4. While in Fig. 5, the adrenal gland of Mel treated group showing thick capsule, enlarged of cellular nuclei and

Table 1 : Acrylamide, Melatonin, Vitamin C and its combination effect on serum corticosterone concentrations in adult male rats (M±SD).

Parameters Groups	Corticosterone (ng/ml)
GA (Cont.)	74.12± 5.32 ^c
G B (Cont+Mel)	77.90± 5.91 ^b
GC (DW)	103.98± 4.78 ^a
GD(Mel)	70.33± 5.67 ^c
GE(Vit.C)	85.39± 5.32 ^b
GF (Mel+Vit.C)	77.96± 5.11 ^b
LSD	6.03

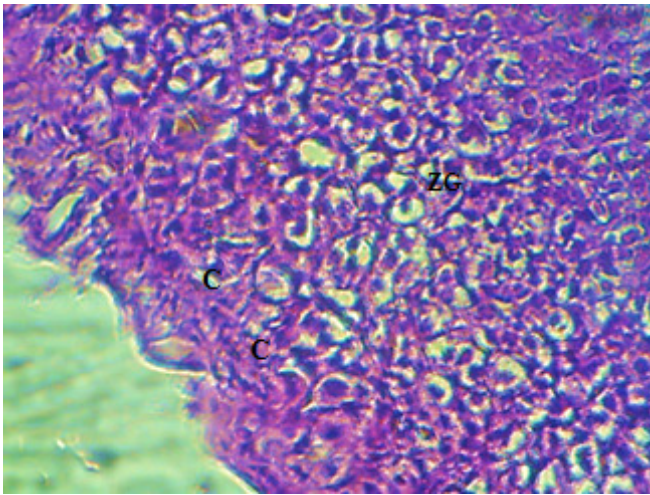


Fig. 1 : Section of adrenal gland in control group showed normal capsule (C) with normal zona glomerulosa cells (ZG), which arranged in irregular groups and cords like structures (H and E stain 400X).

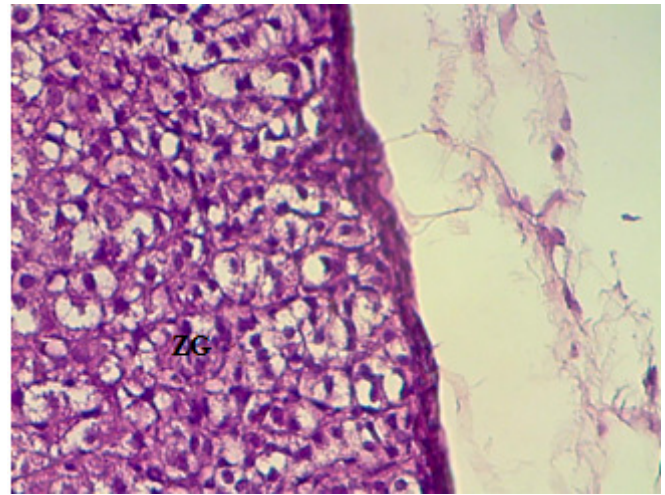


Fig. 4 : Adrenal gland of DW group showing destroyed ZG cells with large pyknotic nuclei and vacuolation (H and E stain 400X).

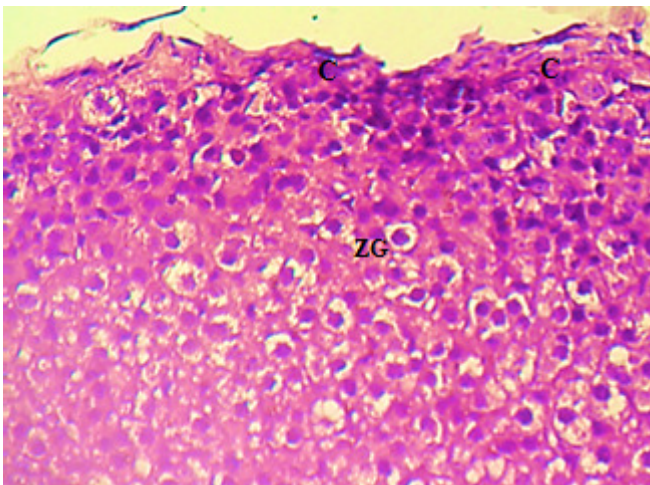


Fig. 2 : Adrenal gland of ACR group showing thick capsule (C) with distorted cells (ZG) of large pyknotic nuclei and vacuolation (H & E stain 400X).

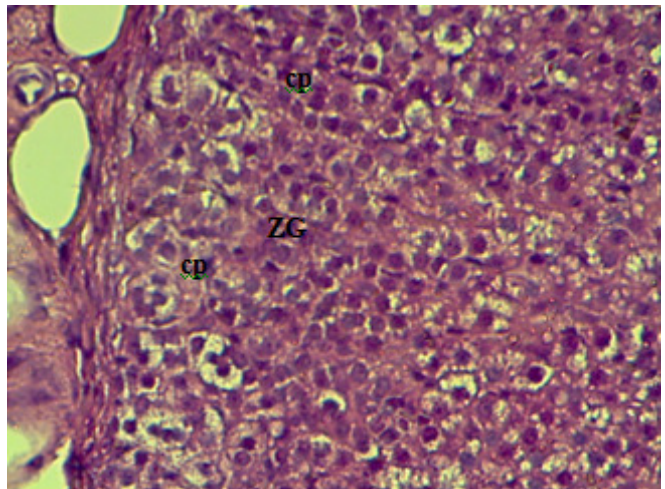


Fig. 5 : Adrenal gland of Mel treated group showing thick capsule (cp) and enlarged cellular nuclei and vacuolation of ZG cells (H and E stain 400X).

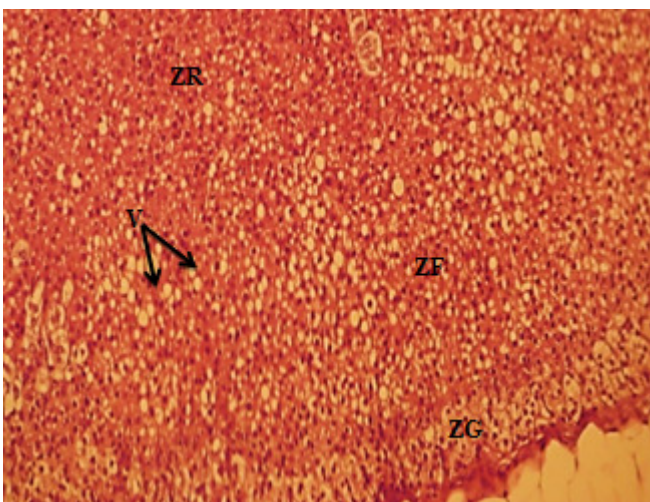


Fig. 3 : Adrenal gland of control+Mel male rats showing normal cells of ZG, ZF and ZR with vacuolation (V), (stain H & E 100X).

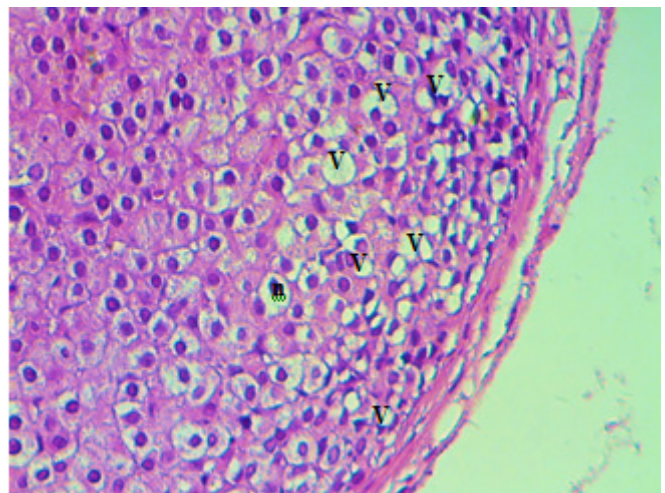


Fig. 6 : Adrenal gland of Vit.C group shows clear enlargement of its cells with the clear vacuolation (V) and enlarged nuclei (n) (H and E stain 400X).

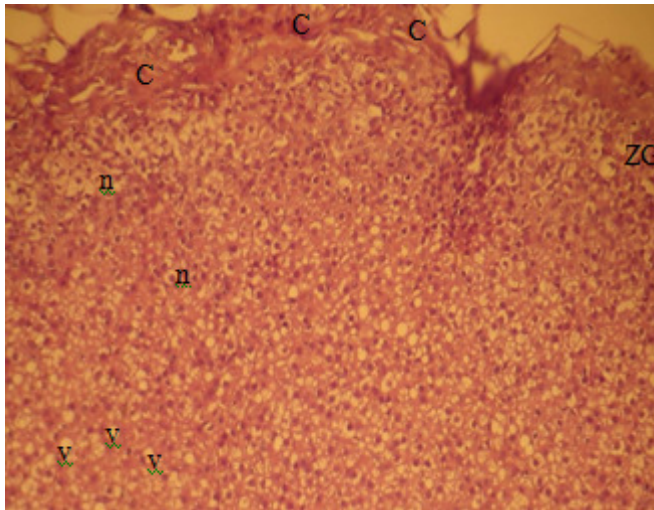


Fig. 7 : Section of adrenal gland in Mel+Vit. C, clear capsule (C) and normal cellular nuclei (n) with the enlarged and vacuolated glomerulosa cells (v) (H and E stain 100X).

vacuolation of zona glomerulosa cells and Fig. 6 section of the adrenal gland in Vit. C group clear enlargement of its cells shows with the enlarge nuclei and clear vacuolation. The adrenal gland of Mel + Vit. C appeared clear normal capsule and cellular nuclei with the enlarged cells and vacuolated glomerulosa cells (Fig. 7).

DISCUSSION

In the recent years, Acr is widely formation in the foods especially in food badly preservative and also in smaller doses the Acr uses in pharmaceutical and cosmetics industries as additive synthetically. Acr have many disadvantages effects as chemical products formation in foods by causes many damages for cells that healthy threatening human and animal. The results revealed a significant increase in corticosterone in group 2 treated with (5 mg/kg BW) of ACR showed in Table 1, this result disagreement with study of Manna *et al* (2006) who indicated that ACR administration causes significant decrement in serum corticosterone, which suggesting that the adrenal cortex undergoes sever effects and the ACR causes disturbances in hypothalamus-pituitary-adrenal relationships.

Acrylamide causes stress factors after 45 day for male rats, which can reverses by melatonin treatment which causes decrease in all stress factors. ACR increase the serum corticosterone concentrations in rats with respect to farm animals. The physiological stress response results in release of glucocorticoid hormones such as corticosterone. Whereas short-term activation of this response helps animals cope with environmental stressors. However, sustained high levels of corticosterone due to frequent or prolonged stressors can result in a number of stress-related pathologies including

suppression of reproduction and the immune system, metabolic dysregulation and cognitive impairment (de Kloet *et al*, 2005 and Martin, 2009).

Direct scavenger roles of melatonin for free radical oxygen and nitrogen species (OH, O₂ and NO) (Pohanka, 2011) and therefore uses Mel as anti-stressor for Acr disadvantage effects. These result agreed with Yamada (1990), who study the effect of melatonin treatment for 10 days on function of adrenal gland in male rats, showed decreased in the weight of adrenal gland treatments with melatonin in the highest dose (30 mg/kg, s.c once daily for 10 days) and also significantly decreased in corticosterone levels in serum while the lower doses (1, 5 and 15 mg/kg) had no effect. Successive treatments with ACTH that increase of corticosterone levels in adrenal gland were suppressed by simultaneous injections of melatonin. On the other hand, melatonin treatment suppressed the increase in corticosterone levels induced by ACTH. Stress led to involution of the thymus and hypertrophy of the adrenal glands in active and especially in passive animals receiving physiological saline. Melatonin partially or completely prevented involution of the thymus under stress conditions. Stress had effect on the histological section of the adrenal glands in ACR-treated rats. The rats receiving melatonin in doses of 0.5mg/kg decreased corticosteroid level and enhance tissue of adrenal gland after stress exposure. Our results suggest that melatonin modulates the hemodynamics and function of stress marker organs. These results agreed with the results of Pertsov (2006) studied the effects of acute stress and exogenous melatonin on stress marker organs when melatonin administration under normal conditions for male rats that increased the relative weights of the thymus (active rats) and adrenal glands (active and passive rats) receiving melatonin in doses of 0.5 and 1 mg/kg decreased after stress exposure. And results suggest that melatonin modulates the hemodynamics and function of stress marker organs and repair the changes in the histology of adrenal tissues.

Vitamin C (ascorbic acid) storage in large amounts in the adrenal cortex by an active transport mechanism which is concentrated in the adrenal cortex to 100-1000 times than concentration it in the serum. About 1% of the total body stores of the vitamin C contains in the adrenal. The reason for these stores in the adrenal cortex is not known; it is perhaps relevant that the one of the adrenal medulla enzymes (dopamine \rightarrow hydroxylase) involved in catecholamine synthesis requires Vit. C. Vit. C is released from the adrenal cortex to response for ACTH (Brandt and Shibberu, 2013).

A histological examination of the adrenal gland section

of male rats treated with ACR showed different pathological changes as show in Fig. 2. These results are accorded with study by Karacaoglu *et al* (2012) showed that furan administration (substance that form in diet similar to the acrylamide formation) caused some histopathological changes in the adrenal cortex such as infiltration of mononuclear cell,hyperplasia and fibrosis. Influence of Adrenal injury may on the activity of adrenal cortex hormones such as changes in level of serum corticosterone. In study of both sexes of mice (administered 2, 4 and 8 mg kg/day of furan for 2 years), that reported furan caused elevation benign pheochromocytomas of the adrenal gland and this was evidence of the carcinogenic activity of furan.

In the present study, the result revealed that melatonin significantly restores the morphology of adrenal cortex distorted by ACR, which induced stress and oxidative damage in male rats. Therefore, it can play a promising role in reducing stress-induced damage (Stress is the one basic factor in the etiology of many diseases). It can stimulate numerous pathways leading to an increased production of the oxidants adding to the oxidant burden associated with normal aerobic metabolism and its consequent damage to protein, DNA and lipid. For helping an organism to preserve its stability during stress are hypothalamic-pituitary-adrenocortical (HPA) and sympathoadrenomedullary system, both having adrenal glands as terminal effectors (Petrovic-Kosanovic *et al*, 2012). In our study, melatonin could not restore the body weight of the Streptozotocin (STZ) administered rats. Similar findings have been observed by some of the previous studies performed (Anisimov *et al*, 2001 and Bartness *et al*, 2002). It is believed that the sympathetic nervous system is responsible for this mechanism by enhancing its effects on both the brown andwhite adipose tissues, leading to their mobilization and dissipation of energy (Mahar *et al*, 2012). It was also observed that melatonin could not restore the levels of serum glucose in group C, but it was able to restore the morphology and reduce hypertrophy of the cells of adrenal cortex. Enlargement of the adrenal cortex has been reported after several typesof chronic stress. Both adrenal hypertrophy and hyperplasia have been reported during STZ induced diabetes (Mahar *et al*, 2012). Repeated exposure to elevated plasma ACTH during chemical stress may stimulatezonafasciculata growth and cause zona glomerulosa atrophy (Mansouri *et al*, 2001). Melatonin significantly reduced the levels of serum ACTH in group C, which were markedly elevated by STZ in group B. This could be because melatonin reduces nitric oxide generation within mitochondria, leading to decreased

corticosteroid biosynthesis in rat adrenal cells (Mahar *et al*, 2015).

Ascorbic acid (Vitamin C) is a powerful antioxidant; it is water-soluble substances, which are having a biological antioxidant, lowering the oxidative properties of lethal substances. Vit. C has the ability to scavenge free radicals and form a strong defense line in contradiction of the reactive oxygen species (ROS) that induce cellular damage. These histopathological and ultrastructure changes in zona fasciculata cells due to nicotine exposure were reduced by vitamin C supplementation. In conclusion, this study provided evidence that the harmful histological and ultrastructure changes of nicotine on zona fasciculata in rats were ameliorated by vitamin C intake (Abdel-Hamid, 2018).

In conclusion, Acr consumed for long-period (45 days) has an adverse effect represented by inducing toxicity damage that affecting adrenal gland. Therefore, Acr formation by processed food irregular consuming should be deeper studies and the effect of the Mel and Vit. C uses in the treated the effect of Acr attempted alone each or its combination to find safer and/or natural food additive for maintaining human and animal's health status.

ACKNOWLEDGMENT

We extend our appreciation to the technical staff of the Biochemistry laboratory and College of Veterinary Medicine, University of Basra for technical assistance.

REFERENCES

- Abdel-Hamid GA (2018) Ameliorative effect of vitamin C on nicotine-induced histological and ultrastructural changes in zona fasciculata in albino rats. *MOJ. Anat. Physi.* **5**(2), 120-125.
- Anisimov V N, Zavarzina N Y, Zabezinski MA, Popovich I G, Zimina O A and Shtylick A V (2001) Melatonin increases bothlife span and tumor incidence in female CBA mice. *J. Gerontol. A Biol. Sci. Med. Sci.* **56**, B311-323.
- Arvanitoyannis I S and Dionisopoulou N (2014) Acrylamide: Formation, Occurrence in Food Products, Detection Methods, and Legislation. *Crit. Revi. Food Sci. Nut.* **54**(6), 708-733.
- Asha S, Renu S and Jyotsna J (2008) Biochemical changes in the liver of swiss Albino mice orally exposed to acrylamide. *Mj. Int. J. Sci. Tech.* **2**(03), 542-550.
- Bartness T J, Demas G E and Song C K (2002) Seasonal changes in adiposity: the roles of the photoperiod, melatonin andother hormones, and sympathetic nervous system. *Exp. Biol. Med.* **227**, 363-376.
- Brandt M E and Shibberu Y (2013) Problem-Based Interdisciplinary Learning in an Undergraduate Computational Biochemistry Course. *21st Annual International Conference on Intelligent Systems for Molecular Biology*, Berlin, Germany.
- de Kloet E R, Joëls M and Holsboer F (2005) Stress and the brain: from adaptation to disease. *Nat. Rev. Neurosci.* **6**, 463-475.

- Garrido P, de Blas M, Del Arco A, Segovia G and Mora F (2010) Aging increased basal but not stress induced levels of corticosterone in the brain of a wake rat. *Neurobiol. Aging* p. 1-9.
- Ikegami T, Azuma K, Nakamura M, Suzuki N, Hattori A and Ando H (2009) Diurnal expressions of four subtypes of melatonin receptor genes in the optic tectum and retina of goldfish. *Comp. Biochem. Physiol. A* **152**, 219-224.
- Ishii H, Tanaka N, Kobayashi M, Kate M and Shakuma Y (2009) Gene structures, biochemical characterization and distribution of rat melatonin receptors. *J. Physiol. Sci.* **59**, 37-47.
- Karacaoglu E, Selmanoglu G and Kili C A (2012) Histopathological effects of the food contaminant furan on some endocrine glands of prepubertal male rats. *Turk. J. Med. Sci.* **42** (Sup.1), 1207-1213.
- Lowes D A, Webster N R, Murphy M P and Galley H F (2013) Antioxidants that protect mitochondria reduce interleukin-6 and oxidative stress, improve mitochondria function and reduce biochemical markers of organ dysfunction in a rat model of acute sepsis. *Br. J. Anaesth.* **110**(3), 472-480.
- Luna L G (1968) *Manual of histologic staining methods of the armed forces institute of pathology*. 3rd ed. McGraw-Hill, New York, NY.
- Mahar Y, Shoro A A and Hidayat M (2015) Effect of Melatonin on the Morphology of Adrenal Cortex altered by Streptozotocin. *P. J. M. H. S.* **9**(4), 1213-1216.
- Mahar Y, Shoro A A and Naqvi A (2012) The effect of L-arginine and insulin on histological changes in STZ treated rat adrenal gland. *PJMHS* **6**(19), 843-846.
- Manna F, Abdel-Wahhab M A, Ahmed H H and Park M H (2006) Protective role of Panax ginseng extract standardized with ginsenoside Rg3 against acrylamide-induced neurotoxicity in rats. *J. Appl. Toxicol.* **26**(3), 198-206.
- Mansouri A, Demeilliers C, Amsellem S, Pessayre D and Fromenty B (2001) Acute Ethanol Administration Oxidatively Damages and Depletes Mitochondrial DNA in Mouse Liver, Brain, Heart, and Skeletal Muscles: Protective Effects of Antioxidants. *JPET* **298**(2), 737-743.
- Martin L B (2009) Stress and immunity in wild vertebrates: timing is everything. *Gen. Comp. Endocrinol.* **163**, 70-76.
- Mayo Sainz R, Tan D, Hardeland R, Leon J, Rodriguez C and Reiter R (2005) Anti-inflammatory action of melatonin and its metabolites, N'-acetyl-5-methoxykynuramine (AFMK) and N-acetyl-1-5-methoxykynuramine (AMK) in macrophages. *J. Neuroimmunol.* **165**, 139-149.
- Pertsov S S (2006) Effect of melatonin on the thymus, adrenal glands, and spleen in rats during acute stress. *Bull Exp. Biol. Med.* **141**(3), 292-295.
- Petrovic-Kosanovic D, Ksenija Velickovic K, Koko V, Jasnic N, Cvijic G and Milošević M C (2012) Effect of acute heat stress on rat adrenal cortex - a morphological and ultrastructural study. *Cent. Eur. J. Biol.* **7**(4), 611-619.
- Pohanka M (2011) Alzheimer's disease and related neurodegenerative disorders: Implication and counteracting of melatonin. *J. of Appl. Biomed.* **9**(4), 185-196.
- Schwend T, Möller M, Schabacker J, Ruppert T and Wink M (2009) Alkylation of adenosine deaminase and thioredoxin by acrylamide in human cell cultures. *Z. Naturf. C.* **64**(5-6), 447-453.
- Winiarska K, Fraczyk T, Malinska D, Drozak J and Bryla J (2006) Melatonin attenuates diabetes-induced oxidative stress in rabbits. *J. Pineal Res.* **40**, 168-176.
- Yamada K (1990) Effects of melatonin on adrenal function in male rats. *Res. Commun. Chem. Pathol. Pharmacol.* **69**(2), 241-244.