

STUDY THE HISTOLOGICAL STRUCTURES OF SKIN AFFECTED WITH N-ACETYLCYSTEINE IN THE RABBITS

Hiba M. Abd Alrahma¹, Ashraff Waleed Abdulraza², Dhuha Adel Kareem³

^{1,3}Department of anatomy and histology, College of Veterinary, University of Basrah, Iraq.

²Department of Surgery and Medicine Obstetric, College of Veterinary University of Basrah, Iraq.

ABSTRACT

The project of this research was study the histological structures of rabbits skin that effected with N-acetyl-cysteine. Ten rabbits in both sex was used in this study and divided into two groups, the control group and treated group with 0.3% N-acetyl-cysteine ointment (NAC). Histological finding show the skin of rabbit was formed from dermis layer that separated into many layers of cells (stratum corneum, stratum granulosum, stratum spinosum and stratum basal. the second layer was dermis which contain papillary layer with the papillary projection and reticular layer that fill a largest field of the dermis. The epithelization, keratinization, granulation tissue and angiogenesis was more in the treated group than control group, while the fibrosis was more in the control group in compared with other group.

Keywords: Histology, N-acetyl-cysteine and rabbit skin.

I. INTRODUCTION

The skin consists of an epidermis and dermis joined to underlying structures such as muscle and bone by the subcutis (1).

Wound healing involves a complex series of interactions between different cell types, cytokine mediators, and the extracellular matrix (ECM). In general, there are three or four major stages of wound healing: inflammation, proliferation, matrix deposition and remodeling (2,3)

N-acetylcysteine (NAC) is a drug that supplies bioavailable cysteine for glutathione replenishment and prevents oxidative damage as well as inflammation. It also leads to glutathione (GSH) formation in the body. Besides fostering angiogenesis, it is used to scavenge free radicals. NAC has a number of functions in the stages of repair process, including cell proliferation, migration, and scratch wound healing. Moreover, NAC has also been reported to promote wound healing in diabetic rats (4)

During the process of wound healing, various inflammatory cells such as neutrophils, macrophages, endothelial cells and fibroblasts produce reactive oxygen species (ROS) (5)

N-acetyl-cysteine is soluble in water and alcohol, and practically insoluble in chloroform and ether (6)

The oral administration of this drug, reaction of deacetylation of NAC happens, while passage it through the small intestine as well as liver, thus its 4-10% decreased in bioavailability by NAC which stimulates biosynthesis of glutathione, directly acts as a free radicals scavenger and also promotes detoxification. It acts as powerful antioxidant and a potential treatment option to the diseases (in the diseases when the generation of free radicals) (7)

So this study was aimed to evaluate the effect of N-acetylcysteine on the histological structures of the skin in the rabbits.

II. MATERIALS AND METHODS

The samples of this study were obtained from the skin of ten rabbits of both sex, the weight was (2.5-3 kg) and divided into two groups each group was contain five animals (control group and treated group). The animals were

given a mixture of ketamine HCl 50 mg/kg B.W (Alfasan Company) and xylazine Hcl 10 mg/kg B.W (Alfasan Company) as anesthetic agents by intra muscular injection

the skin was prepared under aseptic technique, the incision was done on the back of the animals to avoid the pollution in the environment of animals and it is difficult for the animal to reach it. The hair of area was a sheaved and made incision 2-Cm in the depth of skin, the skin closed by suturing technique. Control group was remained untreated other group was treated with NAC cream 0.3% .The collected sample of skin was put into 10% neutral formalin, processed via a serial step of histologic technique, and then embedded in paraffin. The blocks were used to obtain 5- μ m serial sections, and the histological appearance of the tissues was estimated by staining the sections with heamatoxylin-eosin stain(8). The slides were examined using a light microscope. And photographed with digital camera.

Result

The histological structures of the skin was consisted of epidermis, the epithelium of dermis was keratinized stratified squamous epithelium, the dermis contain many cells, single layer of low columnar cells(stratum basale), a few rows of polygonal cells above the stratum basale was (stratum sponiosum and stratum granulosum and which blend above more elongated non cornified cells of stratum corneum **Fig 1**. the dermal epithelium appeared more epithelization and keratinization with group that treated with NAC in compare with control group **Fig 2**. The histological structure of other layer of skin was the epidermis and consisted of superficial papillary layer composed of a fine fibro dense irregular connective tissue with papillary projection into the basal epidermis, the underlying tissue is the reticular layer that comprises the bulk of the dermis and consisted of heavy dense irregular connective tissue **Fig3**.The inflammation and fibrosis was more remarkable in this layers of control group in compared with NAC treated group **Fig 4**.

Other accessory structures of the skin were hair follicle(primary hair follicle and secondary hair follicle), sebaceous gland, serous gland and erector muscle. **Fig5**

The granulation tissue and angiogenesis(newly blood vessels formation) were more distributed in treated group with NAC than control group **Fig6**.

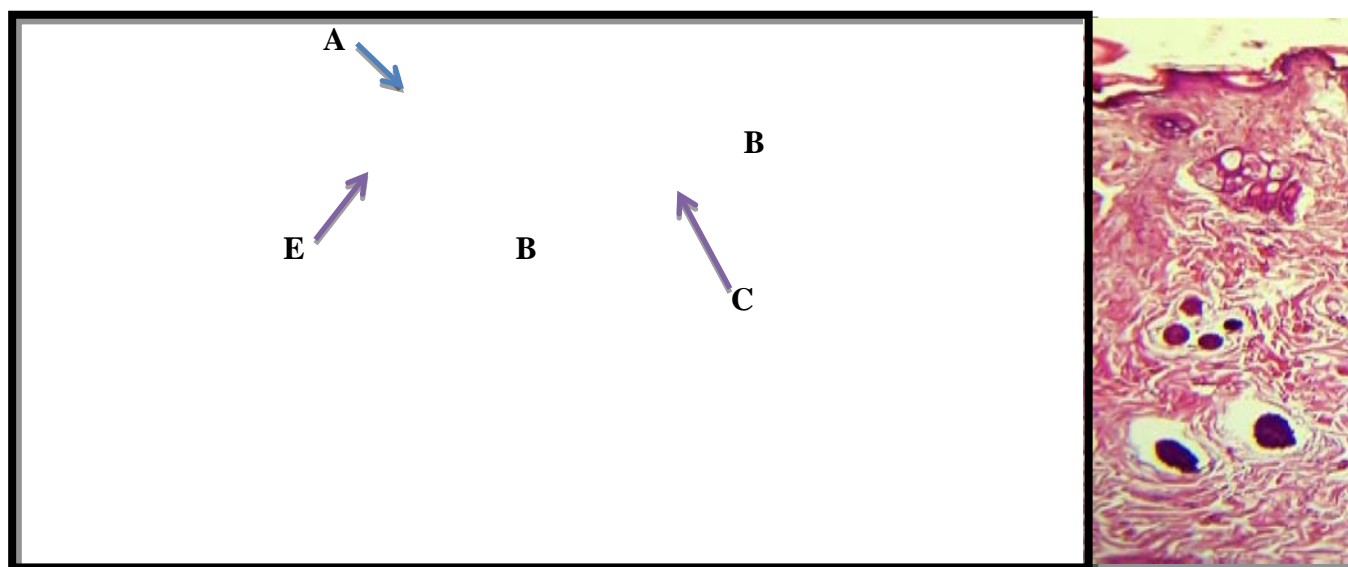


Figure 1: Histological structure of skin in rabbit: A- Epidermis B- Dermis C- Hair follicle, E- Sebaceous gland. H&E stain, 10X

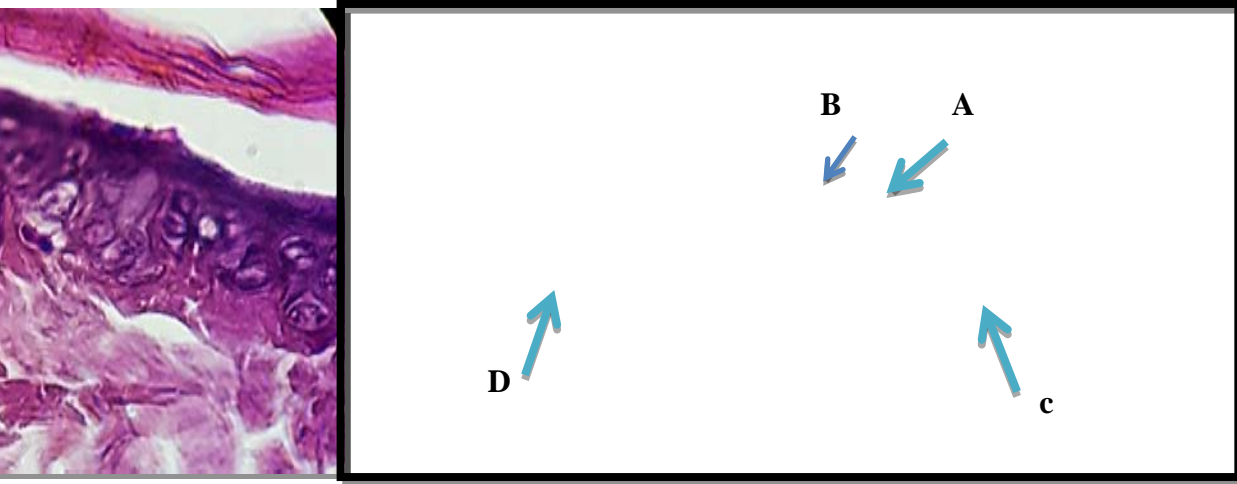


Figure 2: Histological structure of epidermis of skin in rabbit: A- Stratum corneum
B- Stratum granulosum.C- Stratum spinosum D- Stratum basale. H&E stain, 100X

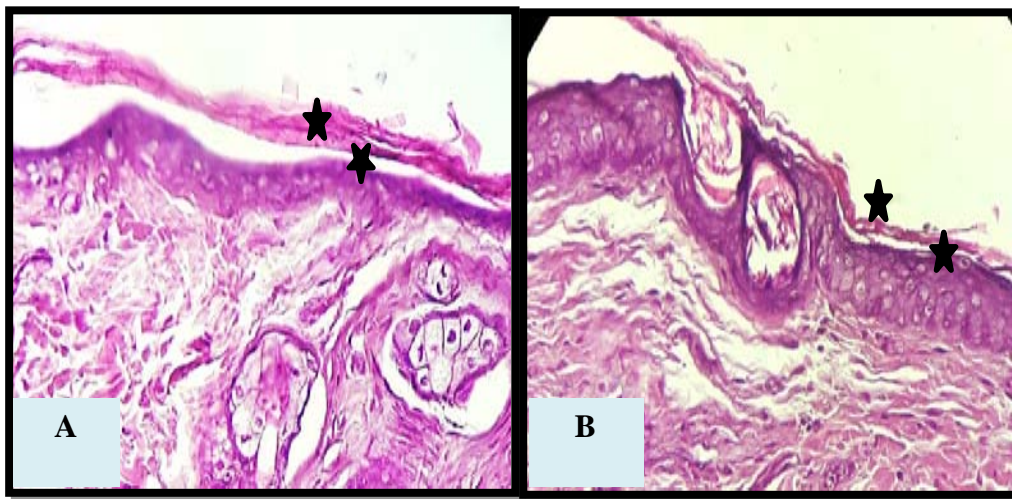


Figure 3: Histological section of the skin in rabbit show more epithelization and keratinization in NAC treated group* (B
40X than control group (A)*10X, H&E stain.

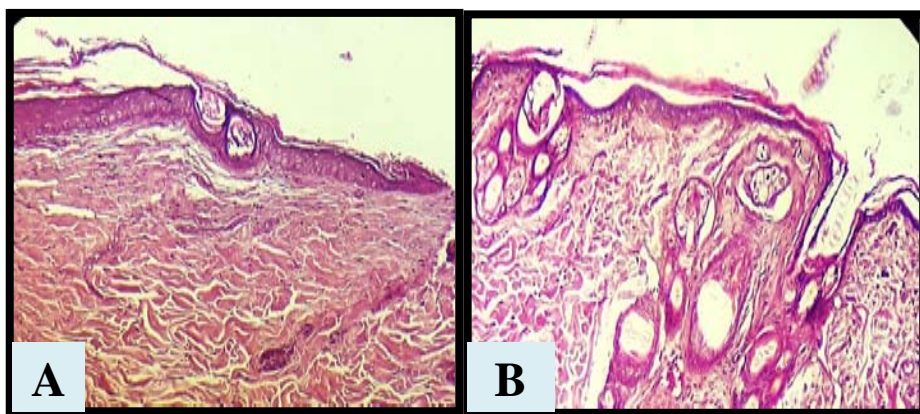


Figure 4: Histological section in the skin of rabbit show the distribution of fibrosis in control group than NAC treated group
.H&E stain,20X.

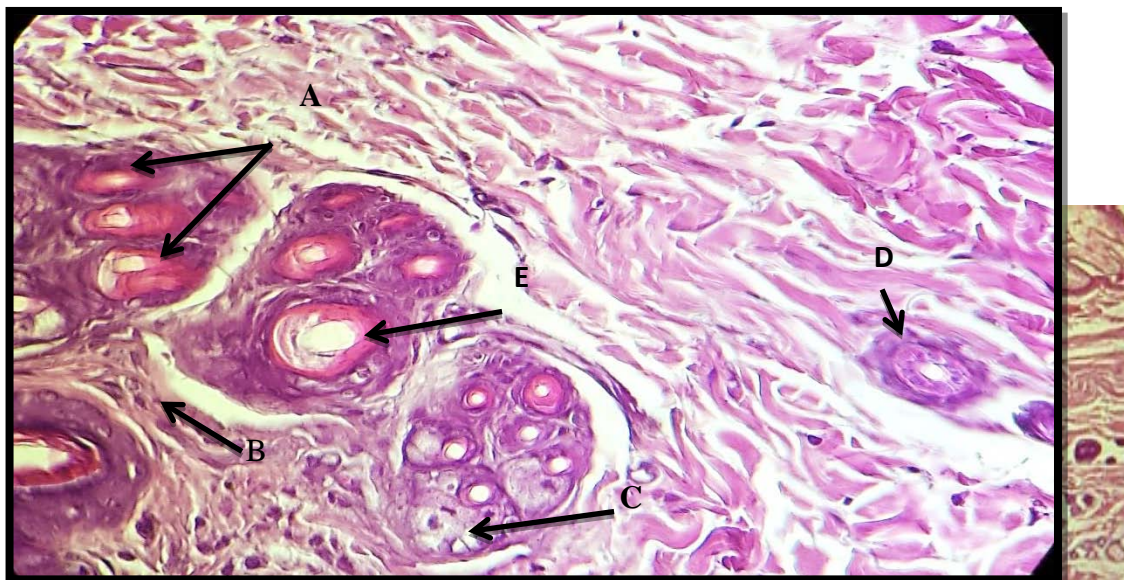


Figure 5: histological structure of skin show :A- Primary hair follicle, B- Duct of sweat glands, E- Erector pili muscle, D- Sebaceous gland.

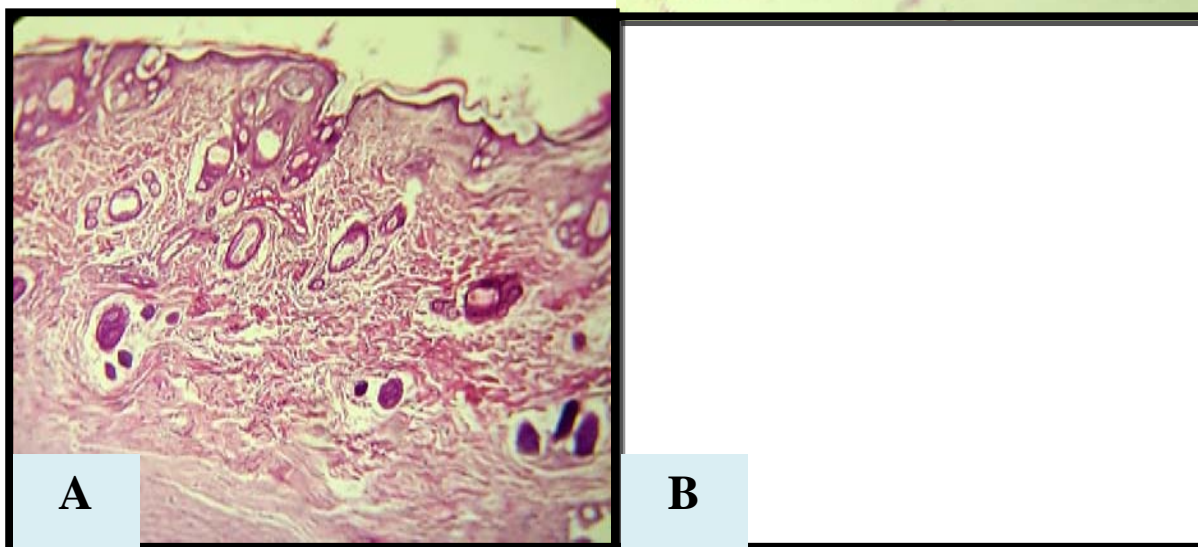


Figure 6: section of skin show: Granulation tissue and Angiogenesis in the NAC treated group more than control group. H&E stain, 20X

III. DISCUSSION

The healthy and normal skin was important in the process of body hemostasis activity and improved the healing of the wound and it is the first defense line against the organisms (9,10). Histologically, the skin in the rabbit shows two main layers, the epidermis and dermis. The epidermis was consisted of keratinized stratified squamous epithelium with four layers of cells: stratum basale, stratum spinosum, stratum granulosum and stratum corneum. This finding is similar to the (11, 12, 13, 14) in sheep, the White New Zealand and Angora rabbits and wild rabbits respectively, the stratum lucidum was absent in this study and in agreement with (14) but variance with (15). The dermis is composed of a papillary layer located under the basal membrane of the epidermis and a reticular layer that blends together without a clear line between them. This resembles the finding in (16). Other structures in the dermis include hair follicles, which are compound in type and in disagreement with (17) that recorded the hair follicles as simple in type in domestic animals, sebaceous glands, sweat glands, and the blood vessels with erector pili muscles that are present in all skin of animals. Angiogenesis was

The histological structure of the skin of animals that were treated with NAC shows more epithelialization and keratinization in the epidermis compared to the control group due to NAC having an active effect on the proliferation of fibroblasts and fibroplasia, thus enhancing the wound healing and this is similar to the (16).

The fibrosis was appeared less in treated group with NAC than control group which widely distributed this similar to the (18) and variance in (19). Angiogenesis and granulation tissue were showed in the NAC treated group than the control group and this similar to the (18) and (19) due to the effect of NAC may be related to its antioxidant properties. (20)

IV. CONCLUSION

This study was showed the normal structures of skin in the rabbits, that consisted of two layers epidermis and dermis. The N-acetylcystein affected on histological picture of the skin. Epithilization, keratinization, granulation and angiogenesis was more in NAC treated group in compare with control group in which the fibrosis appeared more than other group.

REFERENCES

1. Moore GPM, Jackson N, Isaacs K, Brown G, (1998). Pattern and morphogenesis in skin. *J Theo Biol*, 191, 8794.
2. Werner, S.; Grose, R. Regulation of wound healing by growth factors and cytokines. *Physiol. Rev.* 2003, 83, 835–870.
3. Singer, A.J.; Clark, R.A. Cutaneous wound healing. *N. Engl. J. Med.* 1999, 341, 738–746.
4. Aktunc E, Ozacmak VH, Ozacmak HS, Barut F, Buyukates M, Kandemir O and Demircan N. (2010). N-acetyl cysteine promotes angiogenesis and clearance of free oxygen radicals, thus improving wound healing in an alloxan-induced diabetic mouse model of incisional wound. *Clin. Exp. Dermatol.* 35(8):902-9.
5. Parihar, A.; Parihar, M.S.; Milner, S.; Bhat, S. Oxidative stress and anti-oxidative mobilization in burn injury. *Burns* 2008, 34, 6–17.
6. [N-Acetyl-L-cysteine | C5H9NO3S - PubChem](#). Archived from the original on 16 August 2016. Retrieved 22 July 2016.
7. Youssef, G.; Meguid, Ali, A.; Alaa, N.; Makin, B.; Waly, M. and AbouSetta, A. (2006). N-acetyl-cysteine in ovulatory women: the impact of postcoital test. *Middle East Fertil. Soc. J.*; 11: 109-112.
8. Bancroft, J. D.; Suvarna, S. K. And Layton, C. (2013). *Bancroft's Theory and Practice of Histological Techniques*. 7th Ed. Churchill livingstone Elsevier. Edinburgh. London. Melbourne and New York. Pp106-118.
9. Guo S, Dipietro LA. Factors affecting wound healing. *J Dent Res.* 2010;89(3):219–229.
10. M.B. Hole, N.S. Bhosle and P.J. Kapadnis. 2008. Histological study of skin epidermis in red kandhari cows. *Indian J. Anim. Res.*, 42 (1) : 69-70.
11. H.M. Carleton and A.B. Drury. 1957. *Histological technique for normal and pathological tissues and the identification of parasite* 3ed. London oxford university press, New York Toronto. Wakuri, H., K. Mutoh, H. Ichikawa and B. Llu. 1995. *Microscopic Anatomy of the Equine Skin with Special Referenceto the Dermis*. *Okajimas Folia Anat. Jpn.*, 72(2-3): 177-184.
12. Oznurlu Y, Çelik I, Sur E, Telatar T, Ozparlak H, (2009). Comparative skin histology of the White New Zealand and Angora rabbits: Histometrical and immunohistochemical evaluations. *JAVA*, 8, 1694- 1701.
13. Abbasi, M.; Ghazi, A.; Karmi, H. and Khosoravinia, H. (2008). Effects of sex on histological characteristics of various area of skin in an Iranian native breed of sheep. *J. Anim. Vet. Adv.* 4(13): 321-343.
14. Ibrahim, R.S.; Hussein, A. A. and Jabbar, A. I. (2017). Comparative microscopically study of the skin in local and wild rabbits. *Kufa Journal For Veterinary Medical Sciences* Vol. (8) No. (1) pp.151-156.
15. Mohammed, A.S.; Ali, T. Jand Moussa, Z. S. (2014). Some Histological Observation and Morphometric Measurements of the Millivora Capensis Epidermis. Volume 11, No. 3 (Serial No. 95) pp. 139-143.
16. Oznurlu Y, Çelik I, Sur E, Ozaydin T. (2011). Histological examination of the skin and AgNOR parameters of matrix pili cells in the chinchilla. *Eurasian J Vet Sci*, 27, 1, 39-43.
17. Atlee, A.B.; Stannard, A. and Flower, E.M. (1997). *The histology of normal llama skin*. In *Veterinary Dermatology*. Blackwell. Synergy-Vet. Dermatol. 8(3): 7.
18. Oguz, A.; Uslukaya, O.; Alabalik, U.; Turkoglu, A.; Kapan, M. and Bozdog, Z. (2016). Topical N-Acetylcysteine Improves Wound Healing Comparable to Dexpanthenol: An Experimental Study. *Int Surg*. 100(4): 656–661. DOI: 10.9738/INTSURG-D-14-00227.1
19. Ozkaya, H.; Omma, O.; Murat Bag, Y.; Uzunoglu, K.; Isildak, M.; Duymus, M.E.; Kisme, K.; Senes, M.; Fidanci, V.; Celepli, P.; Hucumenoglu, S.; and Aral, Y. (2019). Topical and Systemic Effects of N-acetyl Cysteine on Wound Healing in a Diabetic Rat Model. *WOUNDS A Compendium of Clinical Research and Practice* 31(4).
20. Abdulrazaq, A. W.; Alwan, N.A. and Alrahman, H. M.A and Khutair, Z. (2020). study the n - acetylcysteine effects on gastrectomy and some biochemical parameters in dogs. *Bas.J. Vet. Res.* 19(1). pp169-182.
21. Qasim, M. T., & Al-Mayali, H. K. (2019). Investigate the relation between Baicalin effect and Gene expression of LH, FSH, Testosterone in male rats treated with Gemcitabine drug. *Research Journal of Pharmacy and Technology*, 12(9), 4135-4141.
22. Qasim, M. T., & Al-Mayali, H. K. (2019). The immunological and protective role of Baicalin in male rats treated with chemotherapy (Gemcitabine). In *Journal of Physics: Conference Series* (Vol. 1234, No. 1, p. 012065). IOP Publishing.
23. Tahmasebi, S., Qasim, M. T., Krivenkova, M. V., Zekiy, A. O., Thangavelu, L., Aravindhan, S., ... & Roshangar, L. (2021). The effects of Oxygen-Ozone therapy on regulatory T-cell responses in multiple sclerosis patients. *Cell biology international*.
24. Zainab I. Mohammed, Maytham T. Qasim. (2021). Correlation of AMH and LH Levels in PCOS Patients with Pregnancy Rate. *Annals of the Romanian Society for Cell Biology*, 945–951. Retrieved from <http://annalsofrscb.ro/index.php/journal/article/view/2524>.
25. Mousa, H. M., & Qasim, M. T. (2015). Microbial Infection and IL-6 Urine Levels for Pregnant women in Thi-Qar Province. *World J. Pharma. Res.* 4(05), 358-365.
26. Gowhari Shabgah, A., Qasim, M. T., Mojtaba Mostafavi, S., Olegovna Zekiy, A., Ezzatifar, F., Ahmadi, M., Mohammadian Haftcheshmeh, S. and Gholizadeh Navashenaq, J. (2021) "CXCL chemokine ligand 16: a Swiss army knife chemokine in cancer." *Expert Reviews in Molecular Medicine*. Cambridge University Press, 23, p. e4. doi: 10.1017/erm.2021.7.
27. Ahmed Jassem AL-Naely, Maytham T. Qasim, Hussein Abbas Al-Hamadawi. (2021). Transfusion of Blood Components in the Newborn Service of the Hospital. *Annals of the Romanian Society for Cell Biology*, 952–958. Retrieved from <http://annalsofrscb.ro/index.php/journal/article/view/2525>.