

HISTOPATHOLOGICAL CHANGES IN THE LIVER AND KIDNEY IN RABBITS EXPOSED TO OVERDOSE OF OLANZAPINE DRUG

Mustafa S. Ghaji, Dhuha Adel Kareem and Majdy F. Majeed

Department of Anatomy and Histology, College of Veterinary Medicine, University of Basra, Iraq.

email: mostafasaddam@gmail.com

(Received 11 January 2021, Revised 27 February 2021, Accepted 17 March 2021)

ABSTRACT : The present study carried out to determine the histopathological effects for the overdose of (Olanzapine) drug on the liver and kidney of rabbit. The animals were used eight male rabbits which divided into three groups; low dose treated group (5mg/ml), high dose treated group (10 mg/ml), and control group. It took therapy by oral administration, which was one daily for two weeks and the clinical signs was appear such as depressing, weakness, anorexia. The histopathological change appeared on the examined organs (liver and kidney), which contain of the low treated group, lymphocytes and vaculation, while In the high treated group, the changes were more prominent with hypertrophy hepatocytes large of sinusoid while. Kidney of the both treated group show degeneration cells, necrosis with increased intracellular space in the tubules lumen. The incidences of changes and severity were more in the high dose group. All these results were compared to the control group which don, it appears any structural changes. However, the exposure to the high dose of Olanzapine may be histologically toxic and associated with various pathological conditions such as liver fibrosis and renal dysfunction.

Key words : Olanzapine, kidney, liver and histopathological.

How to cite : Mustafa S. Ghaji, Dhuha Adel Kareem and Majdy F. Majeed (2021) Histopathological changes in the liver and kidney in rabbits exposed to overdose of Olanzapine drug. *Biochem. Cell. Arch.* **21**, 1853-1857. DocID: <https://connectjournals.com/03896.2021.21.1853>

INTRODUCTION

Olanzapine, newer atypical antipsychotics are highly effective and safe in the treatment of psychosis. Antipsychotic drugs have been grouped according to both patterns of clinical activity and mechanism of action. The original antipsychotic drugs such as chlorpromazine and haloperidol have been called typical or first generation. They cause both antipsychotic actions and many side effects (extra pyramidal and hormonal) that are ascribed to their high affinity dopamine D2 receptor antagonism. An antipsychotic drug is a tranquilizing psychiatric medication primarily used to manage psychosis (including delusions or hallucinations, as well as disorders of thought), particularly in schizophrenia and bipolar disorder. Antipsychotics might also be used to counter psychosis associated with a wide range of other disorders, such as psychotic depression (Richard *et al*, 2008). The cytotoxic properties of the typical antipsychotic drugs are well known. Chlorpromazine, fluphenazine, trifluoperazine, and related drugs have been reported to inhibit proliferation in a variety of cell lines

and to alter cell morphology. Similarly, haloperidol, another typical antipsychotic agent, has been shown to be hepato (Durham *et al*, 1990) and nephrotoxic (EL-Abanhawy *et al*, 1993) in rats, especially at high doses. Olanzapine is structurally and functionally similar to clozapine and both are classified as thienobenzodiazepines.

Opioids are used as analgesics and considered effective for the treatment of acute cancer and non-cancer found that its antispasmodic effects on isolated intestinal Muscle were half as powerful as that of atropine. They found that in small doses the parasympatholytic effects were accompanied by mild depression of central nervous system and in large doses by excitement. Although, the side effects of benzhexol Hcl used in the treatment of parkinsonism have been recognized for a number of years.

In spite of its high therapeutic index there are side effects in the course of treatment with benzhexol, including occasional psychotic Manifestations (Stephenes, *et al*, 1967). There are many associated metabolic abnormalities with clinical drug notably ketoacidosis, the

progressive development of disease capillaries of the kidney and liver, damage to the peripheral nerves and excessive arteriosclerosis (WHO, 1990).

The benzhexol HCl, no or very few toxicological studies have been carried out to evaluate the acute and chronic toxicity effects on the laboratory animal. The benzhexol HCl is well recorded after uptake via the oral (Vining, 1980).

Hayrettin *et al* (2006) confined that the drug may be cause of oxidative stress, which play an important role in the pathogenesis of toxic liver and kidney diseases and the alteration Including obstruction of bike flow. On the other hand, several drug, have been associated with liver damage (Lapeyre-Mestre *et al*, 2006).

Therefore, the present study aimed to determine the histopathological effects of on liver and kidney of rabbit.

MATERIALS AND METHODS

Seven rabbits weight between 1-3kg, they were housed in clean cages and they were fed with clean water and food. after that the animals divided into three groups; control, which include one rabbit administrated orally with distal water only, low dose group consists of 2 rabbits were exposed to 5mg/ml olanzapine administrated with distill water and high dose group consists of 2 rabbits were exposed to 10 mg/ml olanzapine administrated with distill water. All these groups administrated twice daily for 2 weeks. They were administrated at same time in the morning (10-11)am and (11-12)pm for evening administration. After the duration of administration (2 weeks) all groups will injected with ketamin 0.5+xylazin (to avoid suffering during killing). Kidney and liver were taken out after killing they were fixing in 10%formalin for histological analysis.

Histological analysis

The liver and kidney were processed and embedded in paraffin wax 6um thick sections were obtained and stained Hematoxiline and Eosin stain and examined by light microscope for determinate of any histopathological change in liver and kidney (Luna, 1968).

RESULTS

Effect of olanzapine on liver histology

Histological, the control liver tissue indicated the presence of normal hepatocytes which are polyhedral in shape with defined cell lining, nuclei are distinctly rounded, with one or two prominent nucleoli. The results of histopathological changes in the liver were recorded by light microscopic, the treatment rabbits by a higher dose showed that bleeding, degeneration cells, vaculation of hepatocytes (Fig. 1), also appeared of accumulation of

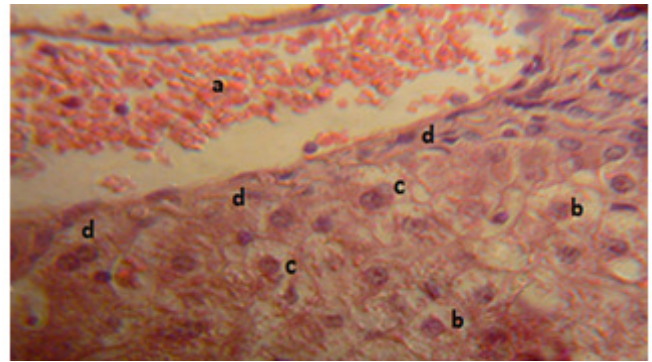


Fig. 1 : Section of the liver of a rabbit treated with 20mg/kg olanzapine drug for 2 weeks showing bleeding (a) degeneration cells (b) vaculation (c) fibrosis (d). (H and E X200).

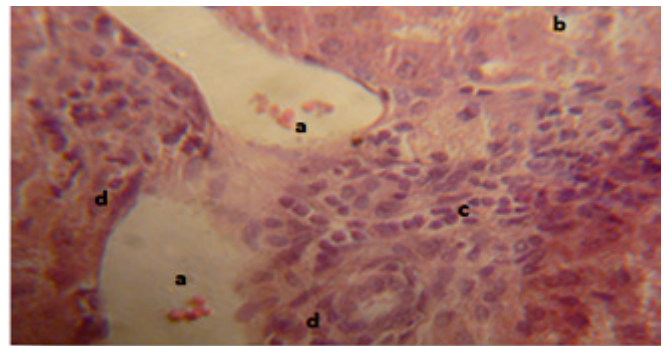


Fig. 2 : Section of the liver of a rabbit treated with 20mg/kg olanzapine drug for 2 weeks showing bleeding (a) degeneration cells (b) lymphocytes (c) fibrosis (d). (H and E X200).

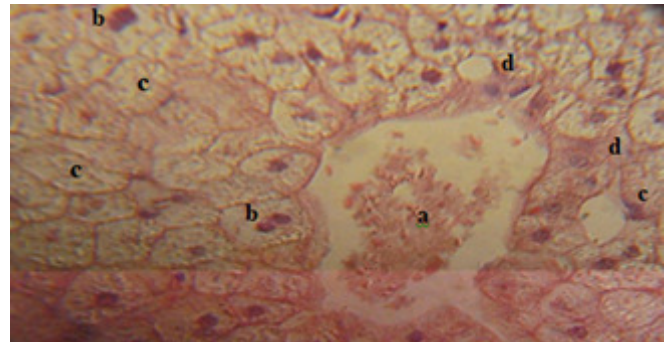


Fig. 3 : Section of the liver of a rabbit treated with 20mg/kg olanzapine drug for 2 weeks showing congestions(a) degeneration cells (b) vacuolation of cytoplasmis (c)necrosis (d).

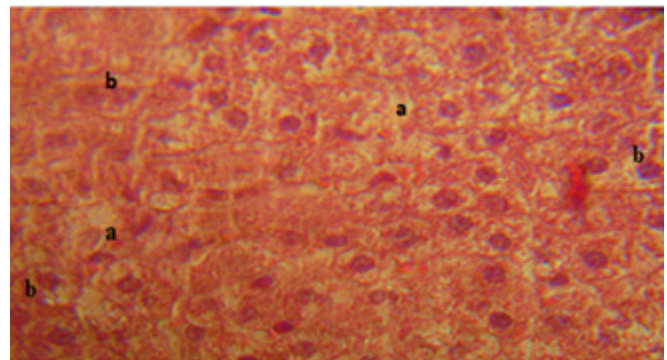


Fig. 4 : Section of the liver of a rabbit treated with 10 mg/kg olanzapine drug for 2 weeks showing necrosis (a) degeneration cells (b) . (H and E X 200).

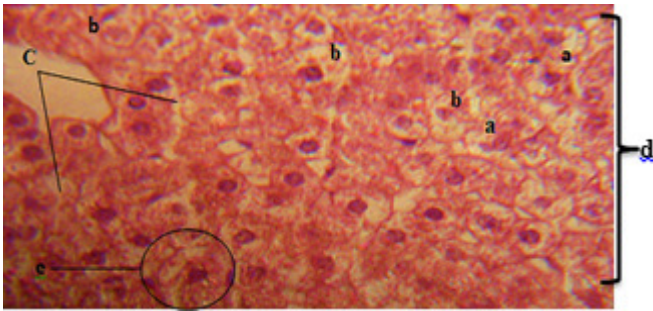


Fig. 5 : Section of the liver of a rabbit treated with 10 mg/kg olanzapine drug for 2 weeks showing necrosis (a) degeneration cells (b) large of sinusoid (c) lose the typical shape (d) hypertrophy of hepatocytes (e). (H and E X200).

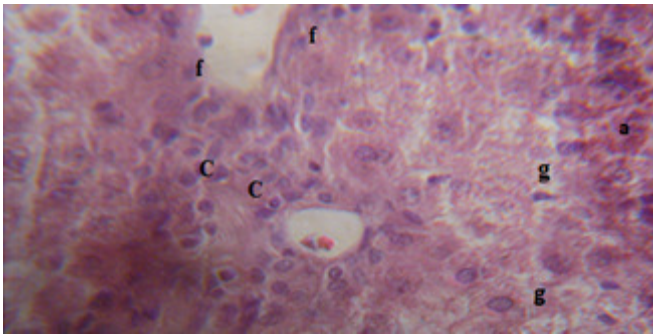


Fig. 6 : Section of the liver of a rabbit treated with 10 mg/kg olanzapine drug for 2 weeks showing bleeding (a) degeneration cells (b) lymphocytes (c) lose the typical shape (d) hypertrophy of hepatocytes (e) fibrosis (f) necrosis (g). (H and E X200).

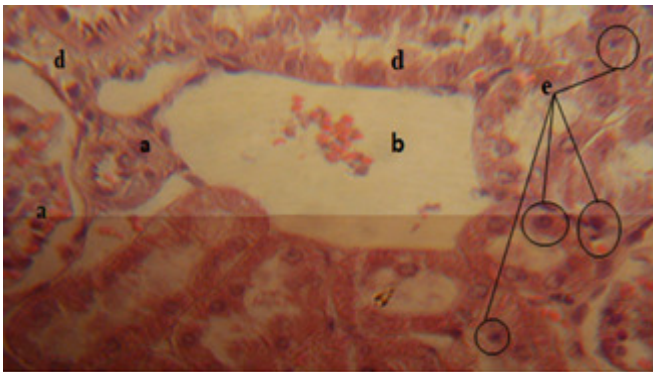


Fig. 7 : Section of the kidney of a rabbit treated with 20mg/kg olanzapine drug for 2 weeks showing a hyperplasia of proximal convoluted tubule (a) absence of glomerulosa (b) Degeneration cells (d) pyknosis (e). (H and E X200).

lymphocytes and fibrosis (Fig. 2) vacuolation of cells and congestion of portal vein (Fig. 3).

While, a low dose showed that, bleeding and degeneration cells (Fig. 4), also noticed large of sinusoid, loss of typical shape, vacuolation and hypertrophy of hepatocytes (Fig. 5) infiltration of lymphocytes, fibrosis and necrosis (Fig. 6).

Effect of olanzapine on kidney histology

Histologically, the control kidney tissue indicated the presence of normal cuboidal shaped cell with defined

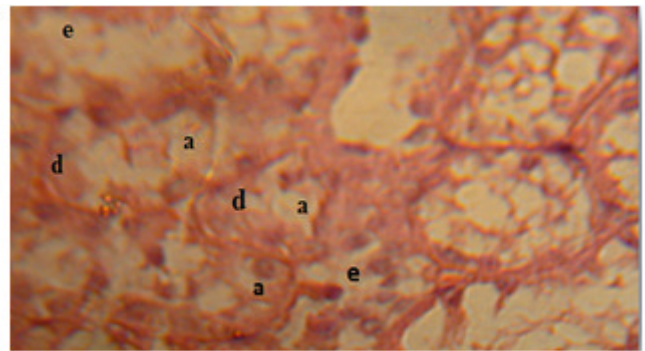


Fig. 8 : Section of the kidney of a rabbit treated with 20mg/kg olanzapine drug for 2 weeks showing a vacuolation of cells (a) degeneration cells (d) necrosis (e). (H and E X200).

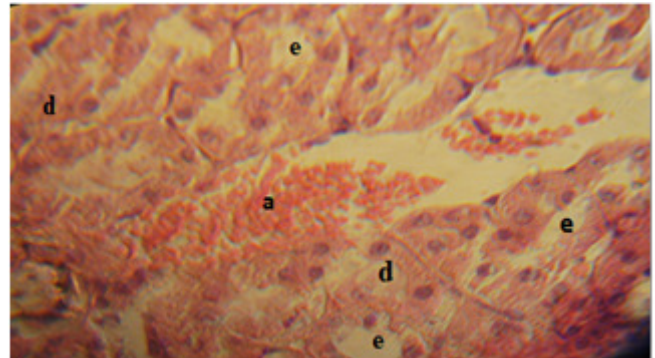


Fig. 9 : Section of the kidney of a rabbit treated with 20mg/kg olanzapine drug for 2 weeks showing bleeding (a) degeneration cells (d) necrosis (e). (H and E X200).

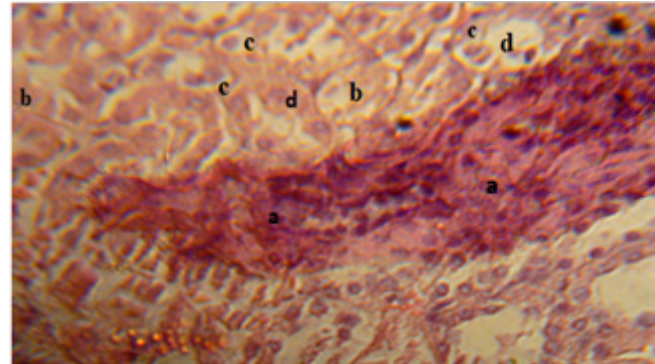


Fig. 10 : Section of the kidney of a rabbit treated with 10mg/kg olanzapine drug for 2 weeks showing a hyper pigment (a) degeneration cells (b) necrosis (c) hypertrophied cells and human tubules diminished (d). (H and E X200).

epithelial cell lining. In the treatment groups by high dose of parkinsol drug showed that absence of glomerulosa and pyknosis (Fig. 7) also state of vacuolation of hepatocytes, degeneration and necrosis (Fig. 8) as well as bleeding and necrosis (Fig. 9). While, a low dose groups was recorded the many of histopathological changes in kidney such as of hyperpigment, necrosis, degeneration of hepatocytes (Fig. 10), also showed infiltration of lymphocytes, shrinkage of glomerulus and expansion of space inside the Bowman's capsule (Fig. 12).

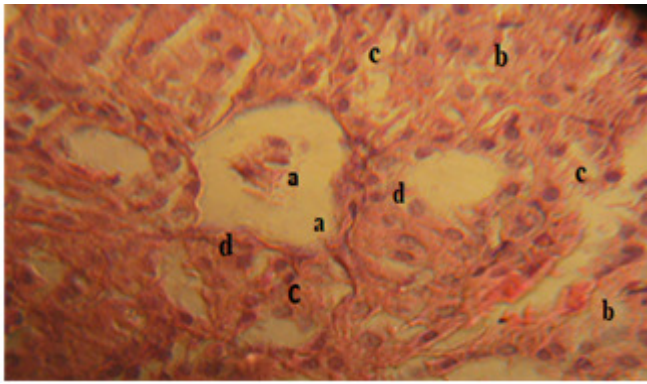


Fig. 11 : Section of the kidney of a rabbit treated with 10mg/kg olanzapine drug for 2 weeks showing shrinkage of glomerulus and expansion of space inside the Bowman's capsule (a) degeneration cells (b) necrosis (c) lymphocytes (d). (H and E X200).

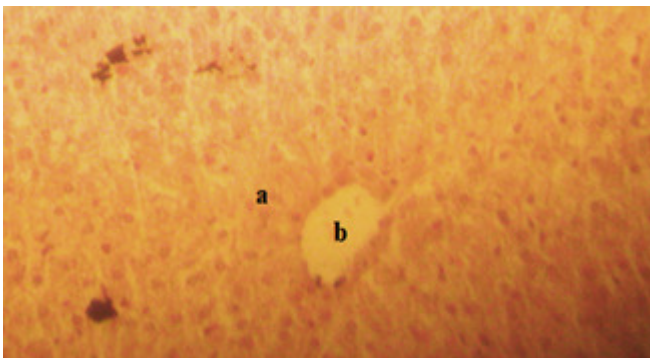


Fig. 12 : Section of the liver of a rabbit Control indicated the presence of normal hepatocytes (a) which are polyhedral in shape with defined cell lining, nuclei are distinctly rounded, with one or two prominent nucleoli, central vein (b) (H and E X200).

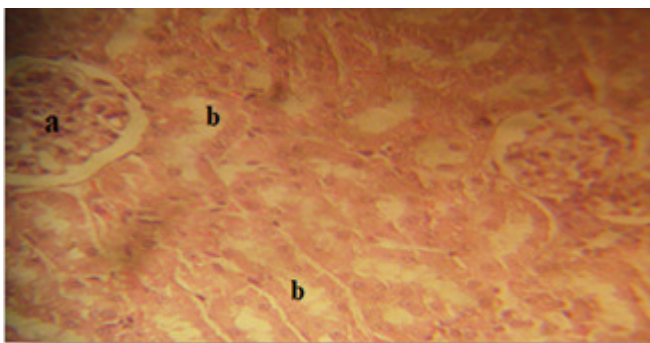


Fig. 13 : Section of the kidney of a rabbit control indicated the presence of normal cuboidal shaped cell with defined epithelial cell lining and glomerulus (a) with normal tubules (b). (H and E X200).

DISCUSSION

In this study, the effect of olanzapine on liver and kidney was dose depended. There increase effects with doses level administration. A drug concentration in the blood is affected by capillary constriction leading to a decrease in glomerular filtration of that drug which minimizes its effect and protects the tubular cells (Stevens, 1997). This may affect the shrinkage and atrophy of the

glomeruli. The tubular lesion observed in the present study was accompanied by invasion of inflammatory cells to the inter tubular tissue in a trial to minimize the injury. Some of these external stressors apparently caused the tubular lesion. The necrosis and degeneration of cells in the proximal and distal convoluted tubules may be due to a decrease re-absorption of glomerular filtrate which counteracts the toxicity of the drug (Jackson *et al*, 1978). Many researchers have reported marked alteration in the fine structure of the cellular component of the proximal convoluted tubules as a result of the treatment with different toxic substance (Trump and Bulger, 1968; Al-Thani, 1993). May be the Benzhexol act to induce hepatic injury as in the present study, which caused a pathological changes may lead to impaired liver function. Abrahams *et al* (1970) suggested that the cytoplasmic vacuolation is mainly a consequence of considerable disturbance in lipid inclusions and fat metabolism occurring during pathological changes. Also vacuolar degeneration has been regarded by Durham *et al* (1990) to be an alteration produced to collect the injurious substance in the cells. Vacuolation and damage of liver cells was noted by other investigators following treatment with different agents (El-Banhawy *et al*, 1993 and Amer *et al*, 1998). Results also showed a remarkable cellular infiltration in the hepatic tissue. This supports by EL-Banhawy *et al* (1993) whose studies suggested that abundance of leucocytes, in general and lymphocytes in particle are a prominent response of body tissues facing any injurious impacts.

REFERENCES

- Abrahams C and Levinson E (1970) Ultrastructures of renal papilla in experimentally induce analgesic nephritis in rat. *S. Afr. Med. H.* **44**(30), 63 – 65.
- AL-Thani A S (1993) The side effects of chloramphenicol on some histological, histochemical and ultra- structure aspewcts of the liver and kidney of the white rat. *Ph.D. Thesis*, Faculty of Science Ain Sams University, Cario Egypt.
- Amer M A, Elewa F H, EL-Shershaby A M and Abdel-Azia A M (1998) Histopathological and histochemical effects of eimerian infection on the host tissues: liver of rabbit. *Egypt J. Zool.* **31**, 1 - 43 .
- Cunningham R W (1949) The pharmacology of 3-(N-piperidyl)-1-phenyl-1-Cyclohexyl-1-prppanol HCl (artane) and related compounds. *Pharmacol. Exp. Ther.* **96**, 151.
- Durham S K, Brouwer A and Barelds R J (1990) Comparative endotoxin - induced hepatic injury in young and aged rat. *J. Pathol.* **162**, 341 – 349.
- EL–Abanhawy MA, Sanad S M, Sakr S A, EL–Elaimy J A and Mahran H A (1993) Histopathology studies on the effect of the anticoagulant rodenticide on the liver of rat. *J. Egypt Ger. Soc. Zool.* **12**(C), 185 – 227.
- Hayrettin O, Halil E, Hulya O and Huseyin B (2006) Effect of dexamethasone on small bowel and kidney oxidative stress and histological altera in bile duct – ligated rats. *Pediatric Surg. Int.*

22, 709-718.

- Jaekson B and Lawrence R J (1973) Renal papillary necrosis associated with indomethacin and phenylbutazone treated rheumatoid arthritis. *Aus. NZJ Med.* **8**(2), 165 – 167.
- Lapeyer-Mestre M, Castro A M, Bareille M P, Del-Pozo J G, Requeejo A A, Arias L M, Montastrue J L and Carvajal A (2006) Non-steroidal anti- inflammatory drug related hepatic damage in France and Spain: Analysis from national spontaneous reporting system. *Fundam. Clin. Pharmacol.* **20**(4), 391 – 395.
- Luna L C (1968) Manual of histological staining methods of the armed forces institute of pathology. McGRAW-Hill Book Company USA.
- Stephenes D A (1967) Toxic psychosis induced by benzhexol hydrochloric. *Brit. J. Psychiat.* **113**, 213.
- Stevens A L (1997) Histology. Gower Medical publishing. London. New York
- Trump H F and Bulger R E (1968) The trophology of kidney: the structure basis of renal diseases, Harper and Row- Hoeber. Medical Division, New York.
- Vining L C (1980) *Economic Microbiology*. Vol. **5**, Academic Prees, London, pp: 523.
- World Health Organization (WHO) (1990) Environmental health criteria 63: Organophosphorous insecticide: a general introduction, WHO, Geneva.