

## **EPIZOOTIC LYMPHANGITIS IN DROUGHT HORSE OF BASRAH PROVINCE, ((A CASE REPORT ))**

Kamal M.Alsaad Mohammed A.Y.AL-Amery Rahman K.Muhsen.

Department of internal and preventive medicine, College of Veterinary Medicine,  
University of Basrah, Basrah, Iraq.

(Received 7 September 2015, Accepted 12 November 2015)

**Keywords:** dermatitis, lymphangitis, conjunctiva.

### **INTRODUCTION**

Epizootic lymphangitis is a chronic ,contagious, disease of horses, donkeys and mules which can infect humans, characterized clinically by a pyogenic , ulcerative, and generalized spreading pyogranulomatous, multifocal dermatitis with lymphadenitis , and a cord like appearance of the subcutaneous lymphatic vessels (lymphangitis) were detected (1). It was seen commonly in the extremities along front and hind legs , chest wall ,belly and the neck, Moreover , it can also be detected as an ulcerating conjunctivitis of the palpebral conjunctiva with excessive ocular serious discharge , or rarely as a multifocal pneumonia(2) . The organism might also invade open fresh or non fresh lesions including ruptured strangles abscesses and male castrated wounds(3).The disease were also been called pseudofarcy or pseudoglanders, Moreover another synonym is Equine Histoplasmosis, Histoplasmosis Farciminosi, African Farcy, Equine Blastomycosis, and Equine Cryptococcosis. which may be a more accurate name for the disease (2).

The disease were results from infection by a dimorphic fungus, *Histoplasma capsulatum* var. *farciminosum*. Which were also know as *Cryptococcus farciminosi*, *Zymonema farciminosi* and *Saccharomyces farciminosus*.(1) The organism exists as a yeast in animal tissues and a saprophytic mycelium in the environment , In addition the disease were also reported in camels, cattle and dogs, Furthermore experimental infections have been established in mice, guinea pigs and rabbits (2).

The mode of transmission of the disease is not well established Nevertheless, Direct contact with infective materials through injured skin or through cutaneous abrasions is the most common mode of infection However, the injured skin is either infected directly by contaminated pus, nasal or ocular discharge or indirectly by soil or contaminated harnesses, grooming instruments, feeding and watering utensils, wound dressings or flies(4). It is also believed that ticks may play a good role in the

transmission of this agent (2).The conjunctival form of the disease is thought to be spread by flies of the *Musca* or *Stomoxys* spp.(1).

The disease is more common in the tropics and subtropics regions, than in temperate areas (2).It have been shown that warm, moist conditions always allow the organism to survive in the soil for months , Furthermore , the disease were mostly sporadic, However The incidence will become high only when large numbers of animals population were collected together such as seen in military situations or congregation for racing, in addition mortalities were low(4).The purpose of this paper were to describe a clinical case of Epizootic lymphangitis in drought horse in Basrah, Iraq .

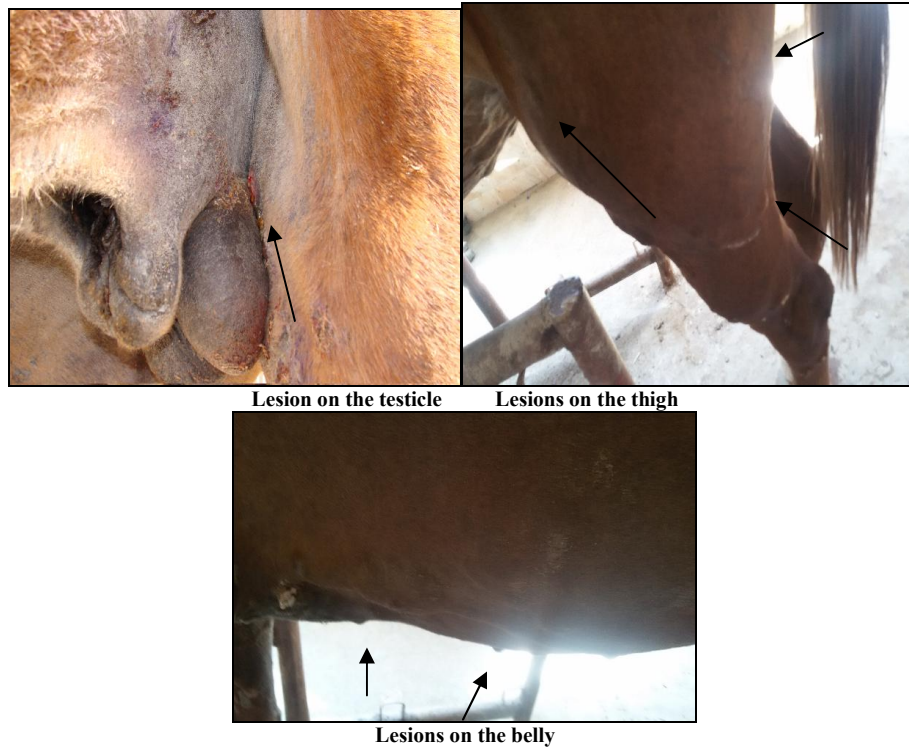### **MATERIALS AND METHODS**

A seven years old male drought horse were brought to the Consultant Veterinary hospital / College of Veterinary Medicine / University of Basrah with a clinical manifestations of generalized ulcerating pyogranulomatous dermatitis distributed on ,chest and neck ,Moreover it were seen also on the animal belly ,along front and hind legs and face with a pearl neckless arrangement, lymphangitis and conjunctivitis,with serious ocular discharge with a signs of pneumonia.

Carful clinical examination have been carried out for the diseased horse and swab were taken from the infected open lesion .Swab were spread carefully on glass side ,fixed with 70% methanol for five minutes and stained with Gimsa stain ,Moreover For cultivation of the infected yeast Sabouraud's dextrose agar were used According to (5).

### **RESULTS**

The most important clinical signs which were detected on the disease horse are open granulomatous wound along the course of a lymphatic vessel, with ulcerated lesions discharging creamy like pus . Lesions were distributed most commonly on the fore limbs, medial and lateral aspect of thighs, chest wall, belly, testicles, neck and the left part of the face . The lesions have different sizes 2-4 cm in diameter and irregular nodules form. The skin over the nodules may be fixed with the underlying tissues

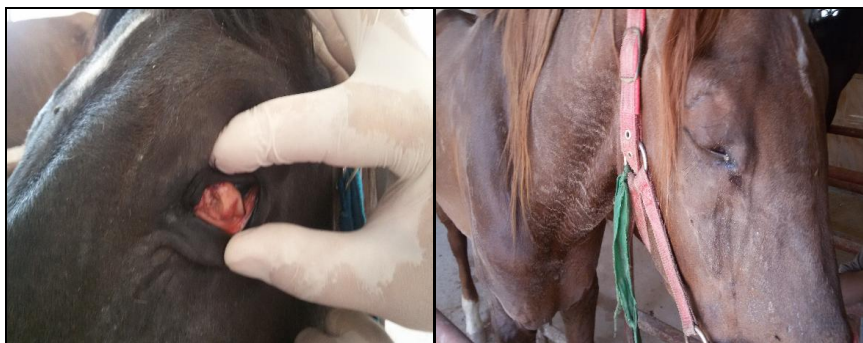

Lesion on the testicle

Lesions on the thigh

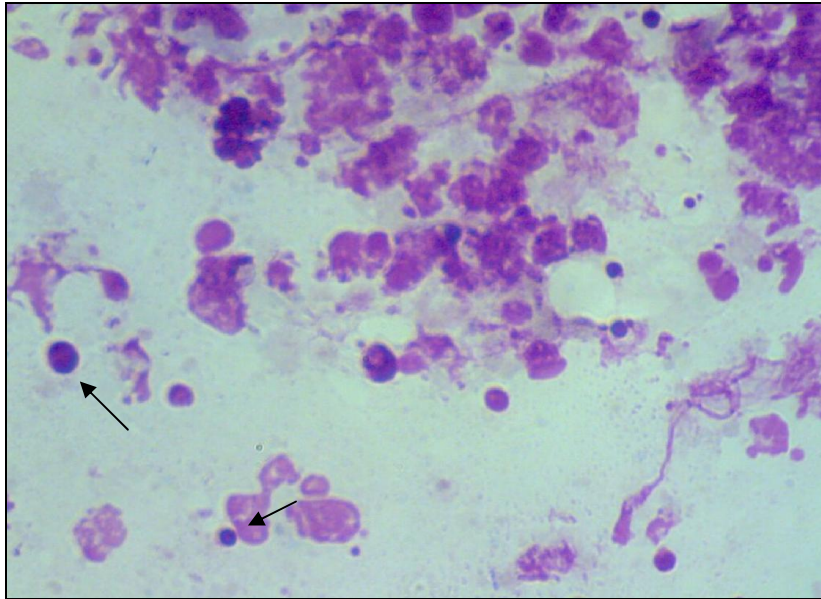
Lesions on the belly

Diseased drought horse show signs of, debility, severe conjunctival hyperemia, serous ocular secretions, restless and anxiety, However flies were detected around the eyes, which become slight edematous, furthermore animal show photophobia and blepharospasm. No fever were detected in infected animals, However there were Dyspnea on inspecting the chest and dry rales and tachycardia were detected on lung and heart auscultation.



Severe conjunctival hyperemia and Serous ocular secretions

On Gimsa stained smear, organism appears in pus as Gram-positive like, pleomorphic, ovoid to globose structures, double-contoured approximately 2–5  $\mu\text{m}$  in diameter, They may occur singly or in groups, A halo around the organisms (unstained capsule) is frequently observed. Colonies appear within approximately eight weeks as dry, grey-white, granular, wrinkled mycelia, However they become brown with aging. Aerial forms occur, but are rare.



*Histoplasma capsulatum var. farciminosum*

## DISCUSSION

Epizootic lymphangitis is a chronic disease. Many mildly affected horses might recover, those that do might become immune for life a belief that has led to a premium being placed in endemic areas on horses with characteristic scars. In most areas of the world, However, this is a reportable disease, Since treatment of clinical cases is not permitted, and destruction of affected horses is usually advised. In most areas, epizootic lymphangitis has been eradicated by a strict policy of culling or slaughter of infected animals, Although rare cases of human infection have been reported, they have not been proved by pert identification of the causative organism(6).

The skin form of the disease may be confused with the skin form of glanders, which is caused by *Burkholderia mallei*, ulcerative lymphangitis, which is caused by *Corynebacterium pseudotuberculosis*, indolent ulcers a caused by *Rhodococcus equi*, sporotrichosis caused by *Sporothrix schenckii*, strangles and cutaneous lymphosarcomas(7).

Strict hygienic precautions are essential to prevent spread of epizootic lymphangitis, Moreover great care should be taken to prevent spread by grooming or harness equipment, as contaminated bedding should be burned, Since The organism may persist in the environment for long time.

Successful treatment with intravenous administration of sodium iodide, oral administration of potassium iodide, and surgical excision of lesions are limited, since

recurrences of clinical signs months later is possible ,Furthermore, In vitro sensitivity of the organism to amphotericin B, nystatin, and clotrimazole has been reported, However ,In most areas, Epizootic lymphangitis is a notifiable disease, and treatment is not allowed , thereby, diseased animals must be forsaking (8,9).

### **REFERENCES**

- 1-Al-Ani, FK. (1999). Epizootic lymphangitis in horses:a review of the literature. Rev. sci. tech. Off. int. Epiz., 1999,18 (3), 691.
- 2-Radostitis, OM., Gay,CC., Constable,PD. and Hinchliff, KW.(2007). Veterinary Medicine. A text book of the diseases of cattle, sheep, goats and horses.10<sup>th</sup> ed, WB Saunders Co.
- 3-Ameni, G.(2006). Preliminary trial on the reproducibility of epizootic lymphangitis through experimental infection of two horses. Vet J. 172(3):553-5.
- 4-Gilbert, RO.(1998).Epizootic lymphangitis. In: Foreign animal diseases. Richmond, VA: United States Animal Health Association; pp: 251-255.
- 5-Selim, SA., Soliman, R., Osman, K., Padhye, AA., Ajello, L.(1985). Studies on histoplasmosis farciminosi (epizootic lymphangitis) in Egypt. Isolation of Histoplasma farciminosum from cases of histoplasmosis farciminosi in horses and its morphological characteristics. Eur J Epidemiol. 1(2):84-9.
- 6-World Organization for Animal Health.(2008). Epizootic lymphangitis. Manual of diagnostic tests and vaccines for terrestrial animals [online]. Paris.
- 7-Kahn, CM., Line, S.(2006). Epizootic lymphangitis .The Merck veterinary manual ,Whitehouse Station, NJ: Merck and Co.
- 8-Al-Ani FK., Ali, HA. and Banna, HB. (1998). Histoplasma farciminosum infection of horses in Iraq. Vet. Arhiv.68:101-107.
- 9-Ameni, G and Terefe, W.(2004).A cross-sectional study of epizootic lymphangitis in cart-mules in western Ethiopia. Prev Vet Med. 66(1-4):93-9.