



Therapeutic effect of infrared, static magnetic field and infrared-static magnetic field to treat diabetes type2 in rabbits

Ibrahim M. H. Alrashid ^{1*}, Jinan Abdul Aziz Bannai ¹, Zainab B. Abdulkareem ¹, Nawras A. Alwan ²

¹ University of Basrah, College of Veterinary Medicine, Department of Surgery and Obstetrics, IRAQ

² University of Basrah, College of Veterinary Medicine, Department of Physiology, Pharmacology and Biochemistry, IRAQ

*Corresponding author: Ibrahim M. H. Alrashid

Abstract

The present study were showed the effect of physical irradiation on pancreas, infrared irradiant on pancreas involve area of stomach, liver, intestine and spleen as well as pancreas as a target organ but the effect in limited area of abdomen, in spite of limitation effect but there are significant results compare with control and other groups values of blood parameters and liver enzymes. The magnetic field involves all body, but varies depending on the distance between the organs and the core center of magnetic coil, the magnetic field effect in general showed effects on blood parameters, glucose level and liver enzymes that significant results. The combination infrared-magnetic field to major effect on the pancreas and The whole body, magnetic field showed on blood. The strong effect of the magnetic field of blood and body generates the idea of stimulation of polypotent stem cells from bone marrow, mesenteric, liver and adipose tissues in the body, this idea will more study in the future to treat other defect.

In conclusion the effect of magnetic field on whole body stimulates polypotent stem cells and infrared stimulates pancreas Langerhans island to regenerate the new Langerhans island.

Keywords: pancreas, infrared, magnetic, irradiation

Alrashid IMH, Bannai JAA, Abdulkareem ZB, Alwan NA (2020) Therapeutic effect of infrared, static magnetic field and infrared-static magnetic field to treat diabetes type2 in rabbits. Eurasia J Biosci 14: 5995-6003.

© 2020 Alrashid et al.

This is an open-access article distributed under the terms of the Creative Commons Attribution License.

INTRODUCTION

The problem of diabetes is a wide in human and small animals due to dietary system, diseases and ages (Garvey and Zawie 1984). The diabetic diseases two types; diabetes undependable on insulin called diabetes type 1 and diabetes dependable insulin or diabetes type 2 (Bloch et. al. 2000). Insulin is a polypeptide hormone that secret from specific cells in the pancreas called β -cells or island of Langerhans (Batt et. al.1991). Insulin hormone response on the utilize of glucose in blood stream at intracellular processing with mitochondria by a biochemical process to liberate energy (Ohtsubok et. al. 2005). Pancreas is organ have two type function; excretion function which excrete digestion enzymes such as lipase, protease, amylase and cholecystokinin-pancreozymin (Steiner and William 1997), and endocrine function by special cells such as α -cells that secret glucagon hormone which response to increase glucose in blood (hyperglycemia), β -cells which response to decrease glucose level in blood (hypoglycemia), δ -cells which secret somatostatin hormone that inhibits the release of numerous hormones

in the body (O'Malley 2005). Pancreas organ verity regards to animal species, therefore there are highly recognized in some species such as dog, cat and horses, in rat, mice and rabbits are attaching to stomach and unrecognized capsule (Prentki et. al. 2002). Rabbits pancreas also has the same function, but rarely recorded diabetes normally, most articles reveals the diabetes in rabbits by inducing chemical agents (Hashemi et. al. 2009). Induce diabetic status in rabbits by injection alloxan or Streptozotocin (Pagliara et. al. 1975, Silva et. al. 2003). Most articles reveal the dose of alloxan 100mg /kg.bw (Jorns et.al.1999), and other reveal study of alloxan is 350mg/kg.bw (Etuk et.al.2010). There are many regimes to treat diabetes type2, drugs such as Glucophage and vitamin E (control fat absorption in the gut), medical insulin hormone injected subcutaneously (Hsu et.al.2017, Suksomboon et.al.2017, Bellinger et.al.2006). Experimentally,

Received: June 2019

Accepted: March 2020

Printed: December 2020

Table 1.

24 rabbits			
1 st group	2 nd group	3 rd group	4 th group
6 rabbits Control	6 rabbits infrared treated	6 rabbits magnetically treated	6 rabbits infrared- magnetically treated
Injected by alloxan 350 mg/kg bw leave without treatment	Injected by alloxan 350 mg/kg bw treated by infrared 10-20 J/cm ²	Injected by alloxan 350 mg/kg bw treated by 200 G magnetic tension	Injected by alloxan 350 mg/kg bw treated by infrared 10-20 J and magnetic tension
	J= joule (energy unit)	G= gauss (magnetic field unit)	

researchers used stem cells therapy direct injection into pancreas (Wang et.al. 2018). Some researchers record the some effect of physical agent on pancreas either increase or decrease blood glucose level, such as infrared irradiation or heat, massage, but all these therapies only experiments (Andrade et.al.2017). Infrared laser, is a type has same the characteristic of photon light, physically define is an invisible photon product by a diode, sold materials and gases carried energy depends on wavelength and tension (Monici et.al.2018). Medical uses of infrared (IR) in skeletomuscular contraction, skin wound, fatigue (Junior et.al.2008). Infrared irradiation penetrates to internal organs according to wavelength and stimulate local inflammation due to absorption of infrared energy (Aiyegbusi et al.2016). Infrared wavelength, tension, time of duration and nature of tissues are a factor to detect the severity of infrared activity, therefore infrared used in nerve injury or tendon rupture are different from infrared in muscle relaxation (Gade and Rothbart 2006). Infrared can effect on the pancreas and stimulate β-cells and cause hypoglycemia in normal animals but the effect disappear after irradiation (Enwemka, 2001). Static magnetic field is the invisible wave has an effect on ferrous particles, it has more application, one of application in medicine, it is use in bone fracture, tendon injury, liver regeneration and activation, muscle fatigue..ect (Sadegh et.al.2015, Drochon et.al.2016, Houpl et.al.2003, Morris and Skalac 2007). These static magnetic wave is highly penetrative to body organs and cause stimulation of endocrine gland, bone marrow, liver, mesenteric stem cells, pancreas activity, nerve activity (Farahana et.al.2014, Carter et.al.2020). The important aspect in the effect of static magnetic field on the body is a stimulation of polypotent stem cells in bone marrow, mesentery, liver and adipose tissue (Han et.al.2019). The change of blood smear morphology before and after exposure of static magnetic field (Amara et.al.2006).

MATERIALS AND METHOD

Materials

Twenty four mature rabbits were used in the present study, randomly divided into four group: 1st groups



Fig. 1. Infrared irradiation laser (980nm, 10-20 J)




Fig. 2. 1-power supply 2-ammeter 3-compass 4-magnetic coil 5-bed

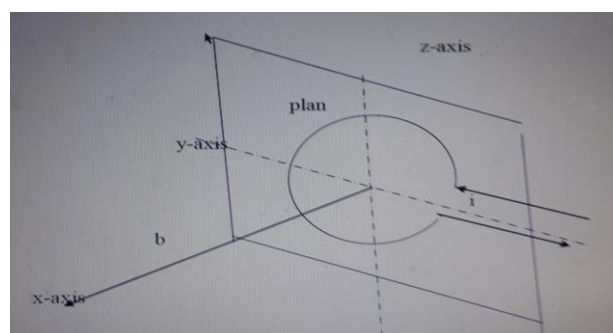


Fig. 3. i= current, x=axis, plan(x,y,z,) plan of magnetic coil, b= axial distance from perpendicular to turn plan

control (alloxan group), 2nd group infrared treated (treated1), 3rd group magnetic group (treated 2), 4th group infrared-magnetic treated (treated 3). 1st, 2nd, 3rd and 4th groups were injected by alloxan solution 350mg single dose via ear of rabbits and take sugar solution for 3 days to develop diabetes (Ighodaro et.al.2017) as experimental design

All rabbits were left in the same condition (25-27)° C feed with dry bread, same tap water, in 1st three days all rabbits were taking water with sugar.

Infrared irradiation laser (980nm, 10-20 J) **Fig. 1.**

Magnetic field generates by magnetic coil **Fig. 2** and measure magnetic field by magnetic equation:

$$\beta = \frac{\mu^o}{2} \cdot \frac{ina^2}{(a^2+b^2)^{2/3}}$$

β=magnetic dose(flux), μ=12.57*10-7 Weber/amp.m, i= current through turn, a=radius of turn, b=axial distance from perpendicular to turn (Du et.al.2019) plan **Fig. 3.**

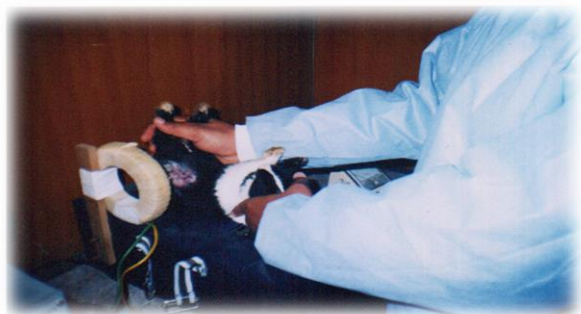

Fig. 4. Magnetic field therapy (magnetotherapy)

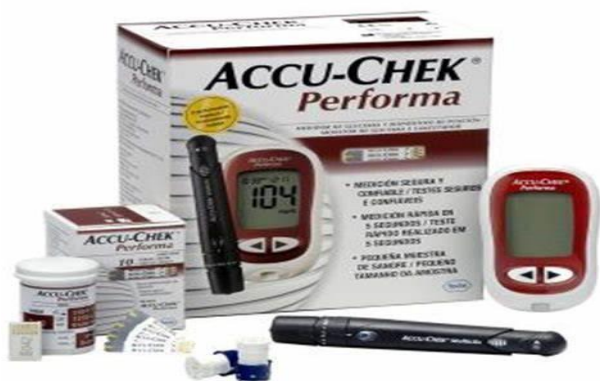

Fig. 5. ACCU-CHEK

Table 2.

Glucose level					
Group/ day	Control Mean ±SD	Infrared Mean ±SD	Magnetic Mean ±SD	Infrared-magnetic Mean ±SD	Sig.
0	76±3.89	74.66±8.64	76±3.89	76.33±7.71	.00
1	157.66±6.34	108.5±10.15	147.66±3.77	113.16±12.98	.777
2	156.6±5.35	107.83±15.43	124.16±42.45	97.83±7.90	.00
3	157±12.28	100.83±13.7	97.66±23.33	85±32.28	.00
4	154.3±12.7	93.3±12.46	65.± 10.23	94.83±20.08	.00
5	159±12.6	90.66±12.73	63.33±11.48	91.66±21.36	.755
Sig.	.00	.00	.00	.784	
Mean ±SD, P value ≤ 0.05					

Methods

After 3 days of alloxan injection, 2nd, 3rd and 4th groups were treated as the position Fig. 4. 2nd group with infrared irradiation 10 minutes for 5 days, 3rd group with static magnetic irradiation 10 minutes for 5 days and 4th group with infrared-magnetic irradiation 5 minutes for inferred and 5 minutes for magnetic field

Daily the glucose level was measure by ACCU-CHEK by ear vein puncture (Fig. 5).

After 7 days CBC were analysis and histopathology do after 7 days of treatment from one rabbit each group

RESULTS

1- Clinical symptoms all groups were showed increase water consumption in 5 days after alloxan injection and gradually decrease water

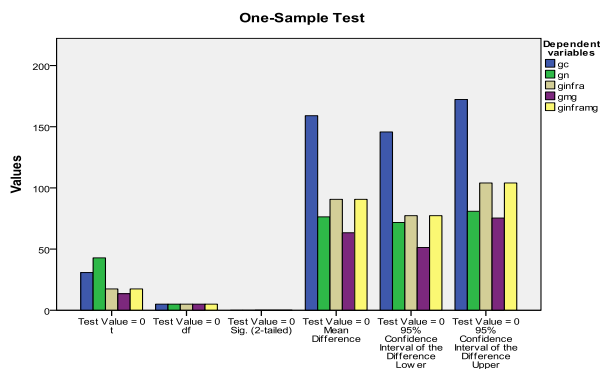


Fig. 6. All treated groups no significant with normal group at P value ≤ 0.05

Table 3.

Blood parameter					
Group/ parameter	Control Mean ±SD	Infrared Mean ±SD	Magnetic Mean ±SD	Infrared-magnetic Mean ±SD	Sig.
HP g/dl	11.15±.34	11.38±.28	7.36±.216	7.25±.38	.745
RBC 10 ⁶ ul	6.26±.273	5.69±.22	3.41±.07	3.44±.12	.00
HCT%	35.9±.37	36.4±.51	23.26±.17	22.98±.74	.00
MCV fl	57.83±.20	62.65±.37	67.1±.35	65.68±3.34	.498
MCH pg	18.23±.44	19.03±.36	21.16±.55	20.65±1.36	.818
MCHC g/dl	31.11±.30	30.28±.13	31.05±.55	30.91±.51	.00
PLT 10 ³ ul	62.66±2.16	543.66±23.61	21.23±1.17	11.16±1.16	.00
WBC 10 ³	4.45±4.45	8.36±8.36	2.58±2.58	4.56±4.56	.974
Mean ±SD, P value ≤ 0.05					
HP is variable significant among group at P value ≤ 0.05					

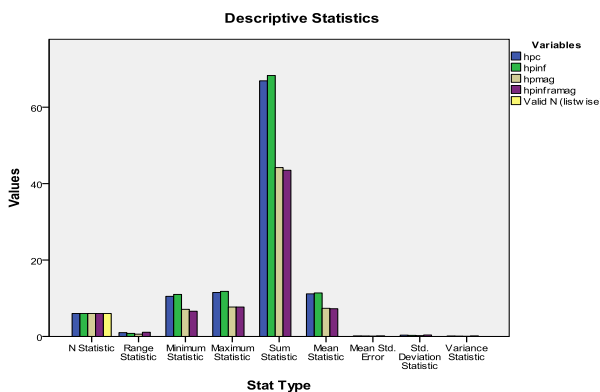


Fig. 7. HP is variable significant among group at P value ≤ 0.05

consumption in 2nd, 3rd and 4th groups, no other clinical symptoms.

- 2- Blood glucose levels
- 3- Blood parameters
- 4- Histopathology

A-Pancreas histopathology after 7 days of treatment

B-liver histopathology after 7 days of treatment

The data were collected and analyzed by used Microsoft excel 2007 and SPSS 17.00. Data were expressed as mean+ standard deviation (SD), one way

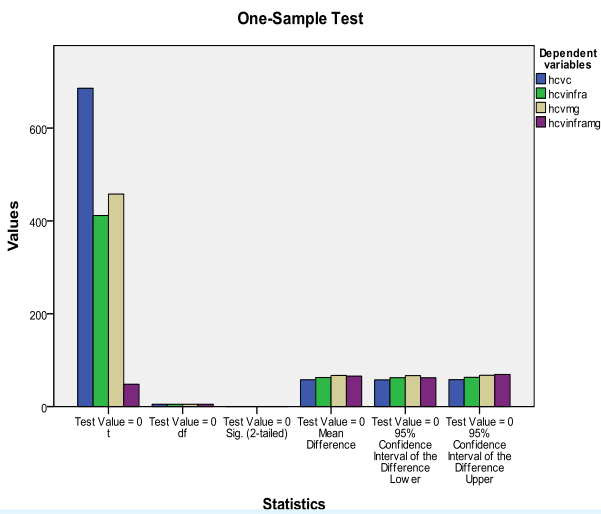


Fig. 8. HTCH is variable significant among group at P value ≤ 0.05

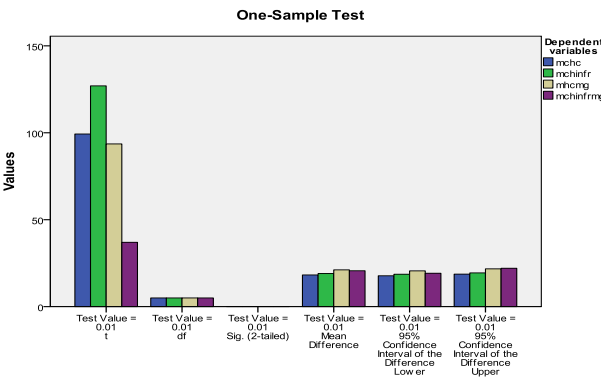


Fig. 9. MCH is variable significant among group at P value ≤ 0.05

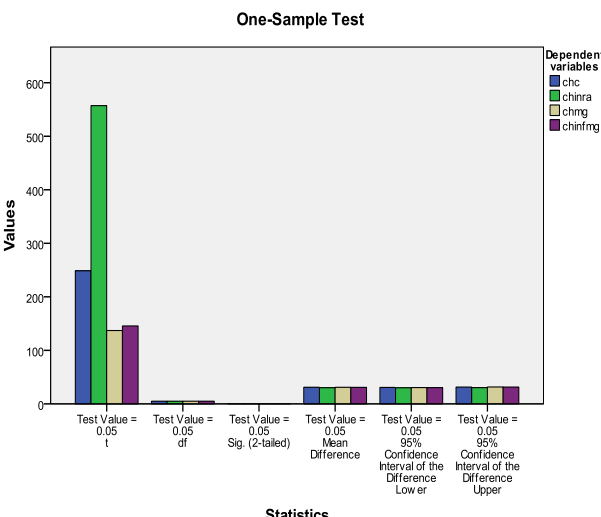


Fig. 10. MCH is variable significant among group at P value ≤ 0.05

ANOVA test was used to compare means among the different groups, significant values at $P \leq 0.05$.

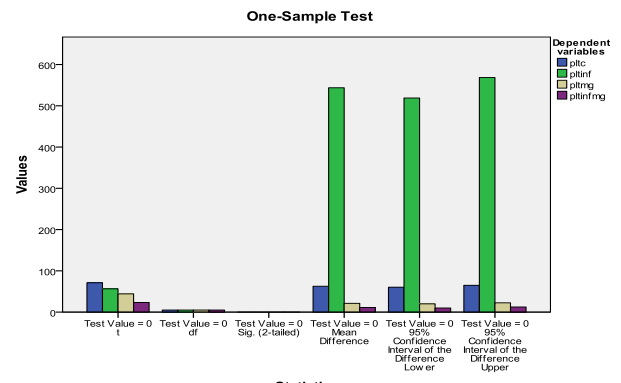


Fig. 11. Platelets in infrared is highly significant among group at P value ≤ 0.05

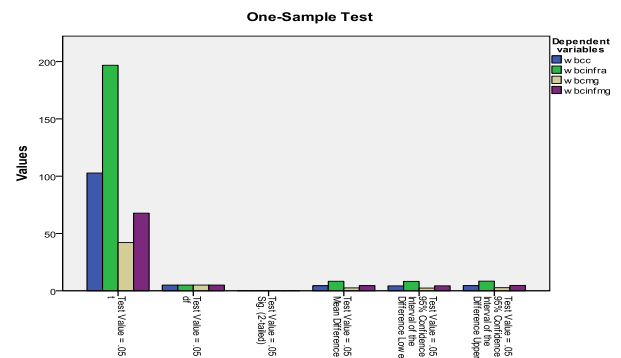


Fig. 12. WBCs in infrared group is significant among group at P value ≤ 0.05

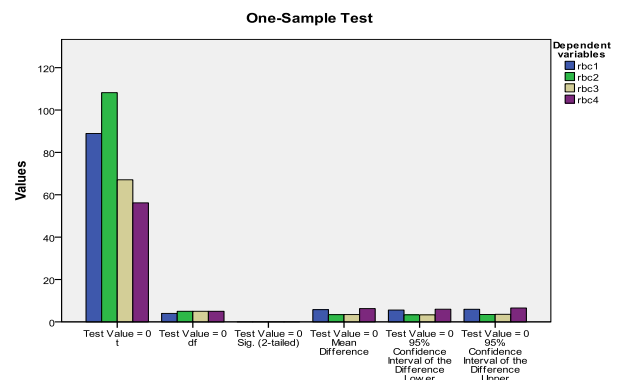


Fig. 13. RBCs in magnetic group is significant among group at P value ≤ 0.05

Table 4.

Group/ liver enzymes	Blood parameter					Sig.
	Control Mean \pm SD	Normal Mean \pm SD	Infrared Mean \pm SD	Magnetic Mean \pm SD	Infrared- magnetic Mean \pm SD	
ALT	173.33 \pm 9.26	138.33 \pm 3.77	67.33 \pm 6.18	143.5 \pm 30.33	237.5 \pm 8.3	.00
AST	118 \pm 8.6	73.16 \pm 2.8	141 \pm 5.76	58.33 \pm 2.16	499.6 \pm 41.7	.00
AKP	67 \pm 1.89	27.8 \pm 2.13	98.83 \pm 4.53	95.16 \pm 3.06	124.16 \pm 3.43	.834

Mean \pm SD,, ALT and AST are no significant at P value ≤ 0.05 ALK is significant at P value ≤ 0.05

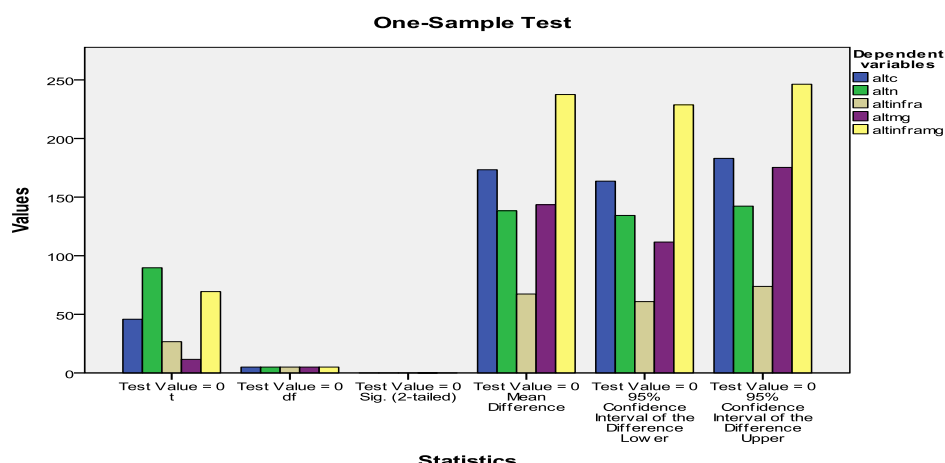


Fig. 14.

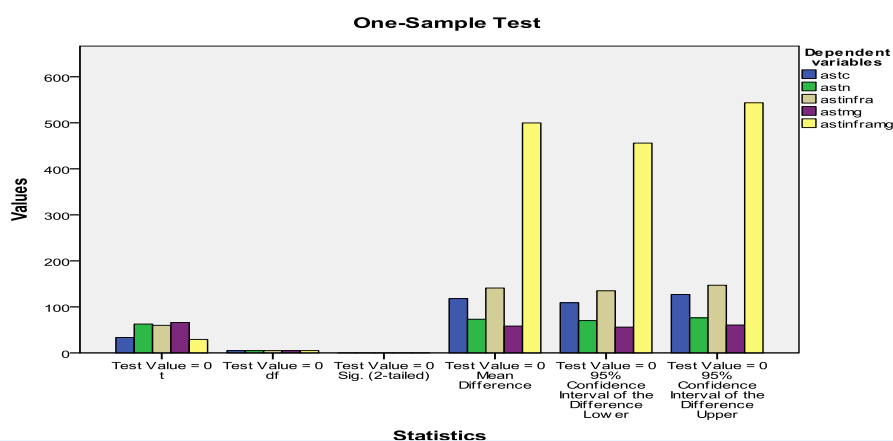


Fig. 15.

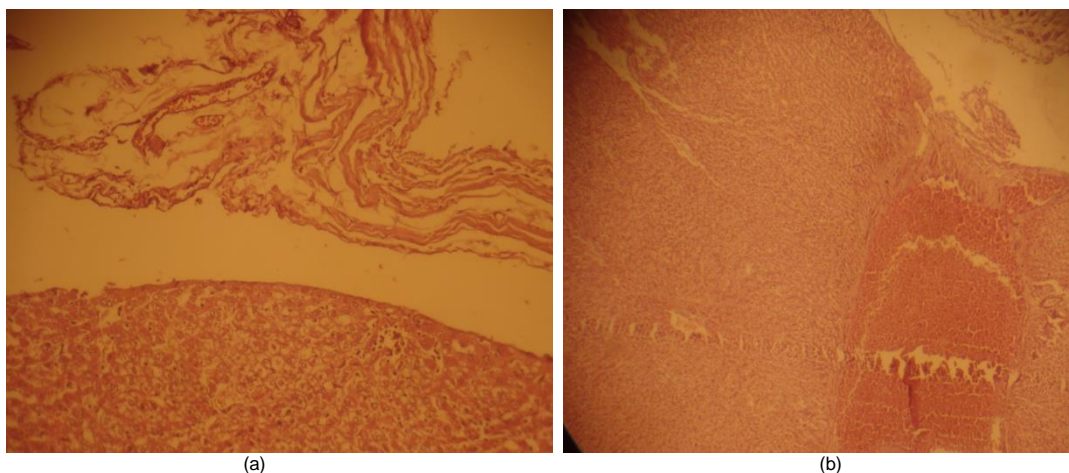


Fig. 16. a) Control group Pancreas section explains loss of pancreatic gland and replacement by necrotic material. Pathological changes after 7ays alloxan injection H&E X 400 b) Infrared group show spot Langerhans island and necrosis after 7 day of treatment H&E X 400

DISCUSSION

The regulation of glucose level in the body by insulin controlling and glucagon hormones either hyperglycemia or hypoglycemia due to β -cells

destruction and persistence use insulin and lipid regulators have an adverse effect, therefore should be find alternative therapy more effective and less adverse effect. Infrared have photons energy and penetrate to abdominal depth and stimulate island of Langerhans,

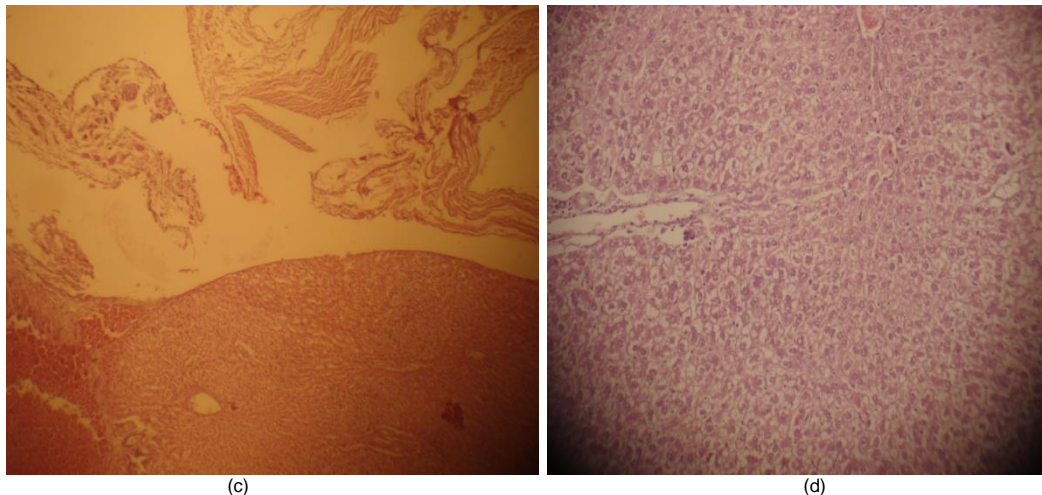


Fig. 16 (continued). c) Magnetic group Pancreas section explains loss of pancreatic gland and replacement by necrotic material. Show Langerhans island after 7 day of treatment H&E X 400 d) Infrared-magnetic group show spot Langerhans island and necrosis vacuoles after 7 day of treatment H&E X 100

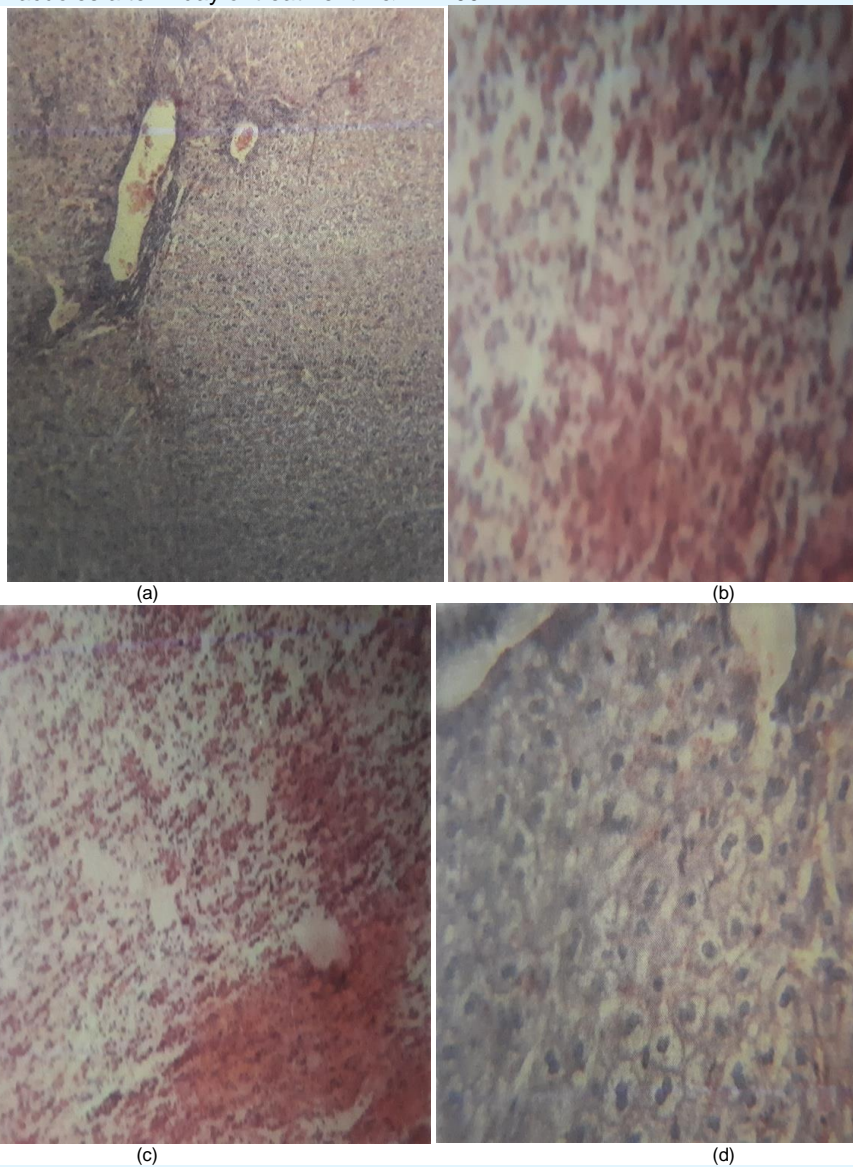


Fig. 17. a) Control group Sub-capsular hemorrhage with pericapsular congestion, fibrosis (H&E stain X40) b) Infrared group Centrally lobular vacuolation of hepatocytes (H&E stain X40) c) Magnetic field group Minimal vacuolation of hepatocytes and general congestion (H&E stain X40) d) Infrared-magnetic group Portal triad bile duct proliferation(H&E stain X40)

the mechanism of infrared irradiation in area surrounding pancreas (liver, stomach, mesentery and spleen) by infrared photodynamic, the effect of infrared on pancreas by stimulation of all cells involving β -cells cause increase insulin hormone, in this study were showed significant hypoglycemia of infrared group compare with normal and alloxan groups that indicate the infrared photodynamic is highly effect on pancreas anatomically there aren't interstitial mesenchymal tissue in pancreas, therefore the potency of regenerate new β -cells is nonexistent (Oryan et.al. 2017), therefore, should be inter stem cells form out pancreas to rebuild the destroyed β -cells. Liver hepatocytes stimulate by infrared photodynamic, hepatocytes play role to glycogen metabolism, release enzymes and antioxidant materials, in present study there are significant results of infrared group compare with normal and alloxan groups these results reveal to high effect of infrared irradiation on function activity of liver, this similar agree with (Assis et. al.2012), but he uses normal pancreas in his study(Barolet et.al.2015). In other studies, they record the influence of infrared irradiation on stomach, intestine and spleen and cause stimulation of their functions that lead to increase fresh blood in stream and increase nutritional element to blood flow (Strieth et.al. 2008) also there are effect of infrared on adipose tissue to liberate free mesenchymal stem cells (Han et.al.2019). Magnetic field effect in body organs within its circle ring, in present study there are low significant influence on glucose level compare with normal and alloxan groups, while some studies indicate no effect on magnetic field on pancreas activity conflict present study due to may be indirect influence of magnetic field on other organs assist the

pancreas to activation such as the effect of magnetic field on liver, spleen, thyroid gland and intestine, these activities lead to release mesenchymal stem cells. In present study there are highly effect of static magnetic field on blood parameters, in spite of the negative effect of magnetic field on bone marrow conflict(Alrashid, 2012) he has positive effect of magnetic field on bone marrow, may be negative effect due to blood viscosity because of increase glucose level as well as lipid profile but when return the glucose to normal and subnormal there are positive effect on magnetic field in present study this agree with (Edner et.al.2014, Farahana et.al.2014). Other studies were recorded the effect of static magnetic field on adipose tissue, mesenteric tissue, liver and other organs, it play a role in liberation mesenchymal stem cells agree with (Barolet et.al.2016, Kim et.al.2015), there is no similar study to ensure present study. The combination two effect of infrared and static magnetic field give more influence or intensive influence in island of Langerhans function in present study there are high significant effect on infrared-magnetic field compare with control and normal values groups and approximate to values of infrared group and magnetic field group except some parameters are significant with two groups, there are no similar study to compare with our study

CONCLUSION

The combination of infrared-static magnetic field has good results but with caution of adverse effect of irradiation due to free radicals which generate when boy expose of physical irradiation.

REFERENCES

- Aiyegbusi A I, Aturu AJ, Adegoke and kinfeye A M (2016). A comparative study of the effects of infrared radiation and warm-up exercises in the management of DOMS. *J. Clin.. Sci.* 77-81.
- Alrashid I M, Naeem R N, Khalaf S K and Emshary C A(2012). The Study of Effect of Static Magnetic Field on The Liver Function Pre- and Post Partial Hepatotomy In Rabbits. *J Basrah Res.*38(3): 89-94.
- Amara S, Abdelmelek H, Salem M, Abidi R and Sakly M (2006). Effects of Static Magnetic Field Exposure on Hematological and Biochemical Parameters in Rats. *BRAZ. ARCHIVES BIO. AND TECH.* 49 (6): 889-895
- Andrade L M, Bossini P S, Souza A L, Sanchez A D, and Partizotto N A (2017). Effect of photobiomodulation therapy (808nm) in the control of neuropathic pain in mice. *Lasers Med. Sci.* 39(10): 797-802.
- Assis L, Moretti A, Thalita B. A, Vivian C, Souza, Michael R. Hamblin, and Nivaldo A. P (2012). Low-Level Laser Therapy (808 nm) Reduces Inflammatory Response and Oxidative Stress in Rat Tibialis Anterior Muscle After Cryolesion. *Lasers Surg Med.:* 44(9): 726–735.
- Barolet D, Christiaens F, and Hamblin M R (2014). Infrared and Skin: Friend or Foe. *J Photochem Photobiol B:* 155: 78–85.
- Batt R M, Horadgoda N U, and Simpson K W (1991). Role of pancreas in the absorption and malabsorption of cobalamin (vitamin B12) in dogs. *J Nutr.* 121: 575-576.
- Bellinger D A, Merricks EP, and Nichols T C (2006). Swine models of type2 diabetes mellitus: Insulin resistance, glucose tolerance and cardiovascular complication. *I L A RJ.* 47(3): 243-58.
- Bloch K O, Zemel R, Bloch O V, Grief H and Vardi A (2000). Streptozotocin and alloxan based selection improve toxin resistance of insulin producing RINm cells. *Int. Exper. Daib. Res.* 1:211-219.

- Carter C, Huang S, Searby C C, Spitz D, Abel E and Sheffield V (2020). Exposure to static magnetic and electrical field trust type2 diabetes. *Cell Metabo.* 32(4): 561-574.
- Drochon A, Robin V, Fokapu O, and Abdullah D (2016). Stationary flow of blood in rigid vessel in presence of external magnetic field: consideration about the forces and wall shear stress. *App. Math.* 7: 130-136.
- Du Z, Guoliang Z, Haoyang C and Shijiao S (2019). Analytical calculation method of free static magnetic field point in magnetic signal measurement. *J Phys. Conf.* 1176.
- Enwemka S (2001). Attenuation and penetration of visible 632.8 and invisible infrared 904nm light in soft tissues. *Laser therapy.* 13: 95-101.
- Etuk U K (2010). Animals models for studying diabetes mellitus. *Agric.Biol.J.N.Am.*1(2): 130-134.
- Farahana M, Omer M, Garadnobi M A, Alganim A A, Abdelkareem and Bushara Y (2014). Effect of the static magnetic field on brain, lung, liver, pancreas and blood electrolytes of rat. *J. Exp. Clin. Med.* 31:124-134.
- Gade G D and Rothbart P J (2006). Infrared therapy for chronic low back pain: A randomized, controlled trial. *Pain Res. Mange.* 11(3): 193-196.
- Garvey M S and Zawie (1984). Feline pancreatic disease. *Vet. Clin. North Am. Small animal Pract.* 14: 1231.
- Han Y, Xie H, Liu Y, GaoP, Yang X, and Shen Z (2019). Effect of metformin on all-cause and cardiovascular mortality in patients with coronary artery diseases: a systematic review and an updated meta-analysis. *Cardiovasc Diabetol:* 18(1):96.
- Hashemi H, Dostar Y, Rohani S R, Azizi R and Bayat M (2009). Influence of alloxanes on the apoptosis of pancreas β -cells of rabbits. *World J. Med. Sci.* 4(2): 70-73.
- Houpl T A, Pittaman D W, Barronco J M, Brooks and Smith J C (2003). Behavioral effect of high strength static magnetic field on rats. *J. Neur. Sci.* 23(4): 1498-1505.
- Hsu WH, Hsiao PJ, Li P C, Chen S C, Lee M Y and Shin S J (2017). Effect of metformin on kidney function in patient with types2 diabetes mellitus and moderate chronic kidney disease. *Onco Target.* 9(4): 5416-5423.
- Ighodaro O M, Adeosun AM and Akinloye O A (2017). Alloxan-induced diabetes, a common model for evaluating the glycemic-control potential of therapeutic compounds and plants extracts in experimental studies. *Medicina* 53: 365–374.
- Jorns AM, Tiedge E, and Lenzen E (1999). Effect of superoxide dismutase, catalase, chelating agents and free radicals scavengers on the toxicity of alloxan to isolated pancreatic islet in vitro. *Free Rad Med.* 26: 1300-4.
- Junior E C, Martins R A, Baroni A A, Marchi D G, and Bjordal V V (2008). Effect of 830nm low level laser therapy in exercise in the management of DOMS. *J. Clinc. Sci.* 13(2) 232-245.
- Kim E C, Leesungbok R, Lee S W, Lee H W, Park S H, Mah S M, Ahn S J(2015). Effects of moderate intensity static magnetic fields on human bone marrow-derived mesenchymal stem cells. *Bioelectromagnetics:* 36(4):267-76
- Monici M, Gnerucci A, Falconi T, Bani D, Cialdia F, Fusi F and Romano G (2018). Laser therapy penetration depth: a near infrared study on horses tendon model. *Mus. Lig. Ten. J.* 8(2): 222-228.
- Morris C E, and Skalak T C (2007). Chronic static magnetic field exposure alters microvessel enlargement resulting from surgical intervention. *J Appl. Physiol.* 105: 629-636.
- O'Malley B (2005). *Clinical anatomy and physiology of exotic species: structure and function of mammal, bired, reptile and amphibian.* London, UK: Elsevier Saunders: 14-18.
- Ohtsubok K, Takamatsu S, Minowa M, Yoshida A and Takenchi M (2005). Dietary and genetic control glucose transporter 2 glycosylation promotes insulin secretion in suppressing diabetes cells 123: 1207-1321.
- Oryan A, Kamil A, Moshiri A, and Eslaminejad (2017). Role of mesenchymal stem cells in bone regenerative medicine: what is the evidence? *Cells Tissues Organs:*204:59-83.
- Pagliara A S, Stilling S N, Haymond H, Hover B A and Hatschinsky F M (1975). Insulin and glucose as modulators of aminoacid induced glucagon release in the isolate pancreas of alloxan and streptozotocin in diabetic rats. *J Clin Inves.* 55: 244-255.
- Prentki M, Joly E, Elassaad W, and Roduit R (2002). Malonl-Co A. singling lipid partitioning and glucolipototoxicity in beta cells adaptation and failure in etiology of diabetes. *Diabetes* (51): 5406-5415.
- Sadegh A B, Ghasemi S, Karimi I, Mirshokaei K N and Oryan A (2015). Tendon healing with allogenic fibroblast and static magnetic field in rabbit model. *I J.V.S:* 10(2): 11-19.
- Silva R C, Parsons M, Robonson T, Lincoln J and Burrostock G (2003). P2X and P2Y purinoceptor expression in pancreas from streptozocin diabetic rat. *Molecular Cell Endocr.* 204:141-154.

- Steiner J M and William D A(1997). Feline exocrine pancreatic disorders: insufficiency, neoplasia and uncommon condition. *Con. ED. For. Proct.*19:836-841.
- Strieth S, Strelczyk D, Eichhorn M E, Dellian E, Luedemann M, Griebel L, Bellemann M, Berghaus A and Brix G (2008). Static magnetic fields induce blood flow decrease and platelet adherence in tumor microvessels. *Cancer Biology and Therapy* 7:6, 814-819.
- Suksomboon N, Poolsup N and Sinpraset B (2011). Effect vitamin E supplementation on glycaemic control in type2 diabetes: review of randomized control trials. *J Clinc. Pharm. Therap.* 36(1): 53-63.
- Wang M, Song L, Strang C, Dong X and Wang H (2018). Therapeutic effect of adipose stem cells from diabetes mice for the treatment of type2 diabetes. *Mol. Therap.* 26(8): 1921-1930.

www.ejobios.org