

LAITH A. JAWAD¹, JASSIM M. ABED²,
PER G. FJELLDAL³, ATHEER HUSSAIN ALI², TAQI ABDULKAREEM ABDULLAH²

¹ Flat Bush, Manukau, Auckland 2016, New Zealand

² Department of Fisheries and Marine Resources,
College of Agriculture, University of Basrah, Basrah, Iraq

³ Institute of Marine Research, Matre Research Station, 5984 Matredal, Norway
Corresponding author laith_jawad@hotmail.com

LACKING THE FLOOR OF THE MOUTH: A CASE STUDY ON *COPTODON ZILLII* (CICHLIDAE) FROM SHATT AL-ARAB RIVER, BASRAH, IRAQ

SUMMARY

A single case of double mouth monstrosity was observed and examined in the cichlid fish *Coptodon zillii* collected from Shatt Al-Arab River, Basrah, Iraq on 15 May 2018. The floor of the mouth was ruptured, creating an extra mouth opening beneath the normal mouth. An injury may have caused this condition. Morphological examination indicates that the fish had lived with the abnormality for some time.

SHORT NOTE

The floor of the mouth is the U-shaped area in the oral cavity beneath the tongue. In fish, the floor of the mouth is important for a functional anatomy during respiration and feeding. The largest muscle in this compartment is *musculus protractor hyoidei* that interconnects the lower jaw and the hyoid arch. This muscle helps to move water through the buccal cavity, and its anterior part contracts during expiration while the posterior part contracts during inspiration. Injury of *musculus protractor hyoidei* or a hole through the floor of the mouth will clearly impact negatively on respiration. Moreover, in Cichlidae, many species are mouthbrooders, and *Coptodon zillii* mainly use the buccal cavity for transportation of fertilized eggs from the spawning substrate to small tunnels (BEVERIDGE and McANDREW, 2012). Hence, *C. zillii* most likely depends on an anatomical functional floor of the mouth in order to cope and reproduce in a natural habitat.

However, there are several reports of fish lacking the floor of the mouth,

resulting in a special phenotype with an extra abnormal mouth opening ventrally to the normal mouth (RISSO, 1810; 1826; GUDGER, 1930; LÖNNBERG, 1917; SWAN, 1968; DAWSON, 1964; 1966; 1971; DAWSON and HEAL, 1976; COBCROFT *et al.* 2001; 2004). Indeed, in fish, bacterial infections like myxobacteriosis can occur in the mouth (KENT and POPPE, 2002), and can involve severe erosion and disintegration of the floor of the mouth.

The present study describes an adult *C. zillii* (Cichlidae) (14.5 cm) with a ruptured *musculus protractor hyoidei* and lacking the floor of the mouth, collected from Shatt al-Arab River, Basrah, Iraq on 15 May 2018.

The specimen was measured to the nearest mm, weighed to the nearest g, and radiographed. The fish was captured using line and hook at 2.5 m depth. Body and fins were examined carefully for external parasites, malformations, amputations and any other morphological anomalies. The specimen was deposited in the fish collection of the Department of Fisheries and Marine Resources, College of Agriculture, University of Basrah, Basrah, Iraq.

The examined fish (145 mm TL, 110 mm SL) lacked the floor of the mouth, creating a ventral abnormal extra mouth opening (Fig. 1). The fish had normal body condition and was not emaciated. Skin pigmentation was normal with lateral vertical dark bands (Fig. 1). The vertical gape of the normal mouth and extra mouth were 14.7 and 19.5 mm, respectively, and the width of the mouth openings 12.1 and 15.6 mm, respectively. Both mouths lead to the oesophagus.

The normal mouth had normal morphology and could be closed, while



Figure 1. *Coptodon zillii*, 145 mm TL collected from Shatt Al-Arab River, Basrah, Iraq.

the extra mouth was unable to close but had bilateral symmetry. Underneath the tongue, skin was absent, and flesh was visible at the rims of the extra mouth (Figs. 2A, B). This flesh did not show signs of recent injury or inflammation and was covered by epithelia. The flesh was the anterior end of

musculus protractor hyoidei, and this muscle was completely ruptured. The surface of the tongue was pigmented (Figs. 2A, B). Glossohyale was curved downward (Figures 2A,B, Figure 3). The fish had a normal swim bladder and vertebral column (Fig. 3).




Figure 2. *Coptodon zillii*, a, 145 mm TL showing front view of the mouth; b, *Coptodon zillii*, 145 mm TL showing enlarge view of the head. CH, ceratohyals; HH, hypohyals; LP, lingual plate; MD, mandible; PM, premaxilla.

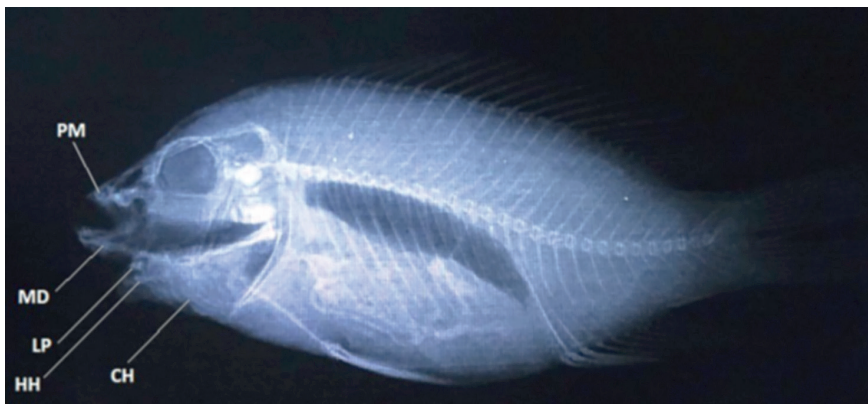


Figure 3. Radiograph of *Coptodon zillii*, 145 mm TL showing the bones of the mouth and hypobranchial areas. CH, ceratohyals; HH, hypohyals; LP, lingual plate; MD, mandible; PM, premaxilla.

The presently condition most likely had a big impact on respiration and feeding. However, the anomaly seemed stable without any signs of resent-

ing an injury, and the fish was not emaciated and in good condition. Hence, the fish apparently had coped with the anomaly in its natural habitat for a prolonged period.

With the ruptured *musculus protractor hyoidei* and lacking floor of the mouth the glossohyale had clearly curved downward. This downward curving must have developed over time and not acute, further supporting the notion that the fish lived and coped with the extra mouth opening for a long period of time. The reason for the downward curvature is not clear, but contraction of remaining surrounding normal intact musculature can have been involved. Further, pigmentation of the inner edges of the skin, the tongue and the anterior parts of the attached gill-arches indicates exposure to sun light of these parts. On contrary, pigmentation was not found inside the normal mouth. This also indicates that the fish have lived with the anomaly for some time. Similar pigmentations were observed on the tongue in the second mouth of *Perca flavescens* described by GUDGER (1930).

The presently examined cichlid was hooked in the extra lower mouth, indicating that the fish used this mouth for feeding activities. The fish may have learnt to use the projecting tongue as a "tool" with which to dislodge small plants from stones or from the silt in which they tend to lie buried. Opercular suction could draw prey towards the pharynx to be swallowed (GUDGER, 1930).

The extra mouth opening may have developed following an injury (GUDGER, 1930), entrapment of air bubbles in the floor of the mouth (SWAN, 1968), or bacterial infections (KENT and POPPE, 2002). The presently studied cichlid had a normal swim bladder and was without signs of infection.

REFERENCES

- BEVERIDGE M.C., MCANDREW B., eds., 2012 - *Tilapias: biology and exploitation* (Vol. 25). Springer Science & Business Media.
- COBCROFT J.M., PANKHURST P.M., POORTENAAR C., HICKMAN B., TAIT M., 2004 - Jaw malformation in cultured yellowtail kingfish (*Seriola lalandi*) larvae. *New Zealand Journal of Marine and Freshwater Research*, **38**: 67-71.
- COBCROFT J.M., PANKHURST P.M., SADLER J., HART P.R., 2001 - Jaw development and malformation in cultured striped trumpeter *Latris lineata*. *Aquaculture*, **199**: 267-282.
- DAWSON C.E., 1964 - A bibliography of anomalies of fishes. *Gulf and Caribbean Research*, **1**: 308-399.
- DAWSON C.E., 1966 - A bibliography of anomalies of fishes, supplement 1. *Gulf and Caribbean Research*, **2**: 169-176.
- DAWSON C.E., 1971 - A bibliography of anomalies of fishes, supplement 2. *Gulf and Caribbean Research*, **3**: 215-239.
- DAWSON C.E., HEAL E., 1976 - A bibliography of anomalies of fishes: Supplement 3. *Gulf and Caribbean Research*, **5**: 35-41.

- GUDGER E.W., 1930 - Fishes with two mouths. *American Museum Novitate*, **444**: 1-11.
- KENT M.L., POPPE T.T., 2002 - Infectious diseases of coldwater fish in marine and brackish water. In: *Diseases and disorders of finfish in cage culture*, pp. 61-105.
- LÖNNBERG A.J.E., 1917 - *En Laxoring [trout] med Tva Munner*. Svensk Fiskeri-Tidskrift, Upsala, **XXVI**, pp. 17-20.
- RISSE A., 1810 - *Ichthyologie de Nice ou Histoire Naturelle des Poissons du, Departement des Alpes Maritimes*. Paris, p. 49.
- RISSE A., 1826 - *Histoire Naturelle des Principales Productions de l'Europe Méridionale et Particulièrement de Celles des Environs de Nice et des Alpes Maritimes*. Paris and Strasbourg, **III**, p. 171.
- SWAN M.A., 1968. Double-mouth deformity in a trout (*Salmo trutta*) and its cause. *Journal of Zoology*, **156**: 449-455.