

**A COMPARATIVE STUDY BETWEEN THE SPINAL CORD INJURY IN THE
DOGS AND RATS (CLINICAL AND HISTOPATHOLOGICAL STUDY)**

ABDULBARI A SAHI*
SALEH KADHIM MAJEED**
AMMAR MAATOQ HASHIM*

*Department of Surgery, Veterinary Medicine College, University of Basrah, Iraq
**Department of pathology, Veterinary Medicine College, University of Basrah, Iraq

Abstract

Objective: To study (clinical and histopathological study) of the spinal cord injury in dogs and rats . **Materials and Methods:** adults dogs and rats, were divided into two groups and subjected to induce injury in spinal cord in both groups. The first group include rats and the second group include dogs. **Results:** The present study in macroscopic examination, in Rats group showed mild congested in site of injury but in dogs' group appearance sever hemorrhage in site of injury. The clinical assessments revealed evidence difficult in gait and walking, and present of pain, weight loss, arching of back in the both groups. The histological assessments at day 60 (2 month) after injury of spinal cord of first group(Rats group) showed evidence of degenerative vacuolated of nerve fiber in the white matter and present of oligodendrocyte but in second group (dogs group)showed high number of degenerative vacuolated of nerve fiber. **Conclusion:** the rats more resistant than dogs to the injury of spinal cord.

Keywords: Spinal Cord Injury, Pathology and Surgery of Spinal Cord

Introduction

Worldwide, approximately 90 million people suffer from spinal cord injury (SCI), the incidence in developed countries vary from one to five persons per 100.000, the main causes are motor vehicle accidents, fall, violence and sports injuries, the median age is approximately 30 years, and the males to females ratio is 4:1(1).

The pathology varies with the force of spinal cord compression, the duration of compression, the displacement of the spinal cord, the acceleration of the impacting forces, and the kinetic energy absorbed at the time of spinal cord impact. The majority of spinal cord injuries do not comprise a spinal cord transection (2). There are three phases of SCI response that occur after injury (3);(4).

Upon primary injury, there is immediate mechanical damage to neural and other soft tissues, including endothelial cells of vasculature, this phase is associated with hemorrhage, localized edema, loss of microcirculation by thrombosis, vasospasm and mechanical damage, and loss of vasculature autoregulation, all of which further exacerbate the neural injury (3) .

In the secondary phase (which occurs over a time course of minutes to weeks) the devastating effect of ischemic cellular death, ionic shifts, and edema continue from the acute phase, inflammatory cells invade the spinal cord parenchyma. Apoptosis occurs and involves reactive gliosis that includes the increased expression of glial fibrillary acidic protein (GFAP) and astrocytic proliferation. Finally, in the chronic phase, which occurs over a time course of days to years, apoptosis continues, together with scarring, demyelination and cyst formation (5).

Materials and Methods

Preparation of Animals to Surgery:

One day before the operation, the site of operation were clipped and shaved carefully. The animals were fasted for 12 hrs and the water withdrawn 2 hrs before operation.

Surgical Procedure:

All surgical techniques were performed under aseptic conditions. Animals were anaesthetized before operation by intramuscular injection of a mixture of 50 mg /kg B.W ketamine hydrochloride and 10 mg/kg B.W xylazine in rats, but in dogs used intramuscular injection of anesthesia, a mixture of 15mg/kg B.W Ketamine hydrochloride and 5mg/kg B.W.

Removal of the Soft Tissue:

A dorsal incision was made in the mid-thoracic region of the anaesthetized rats muscle retracted in the (Thoracic-T10-Lumbar-L1) to expose the vertebral bone plate which was still intact (6).

Laminectomy:

The vertebra was approached as described above and the vertebral bone of the L1 segment was removed bilaterally to expose the dura-mater, which was left intact (7).

Results

Clinical assessment :-

1-Rats group:-

There was marked paraplegia after operation in one leg of hind limb due to severe damage to the spinal cord in some animals in (Image 3), the clinical assessment of the animals of this group as follows :-

Post- operation Marked symptoms may occur immediately after an injury and the animals showed weight loss. Difficulty with balance and walking and severe pain occur post operation, weakness and exaggerated reflexes or muscle spasms and sensitivity to stimuli.

2-Dogs Group:

Like in Rats group there is marked the clinical assessment for this group was as following: Weight loss, motor and sensory dysfunction of the hind limbs post operation and do not occur the paraplegia in this group depend on the damage to the spinal cord . Also showed defect in walking and balance post operation in (Image 4). There were also marked weight losses in all animals.

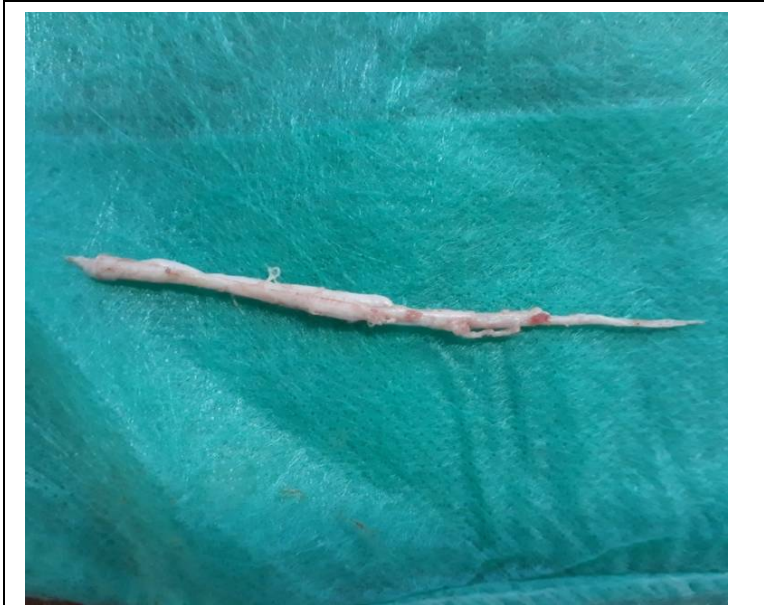MICROSCOPIC FINDINGS :-

1-Rats Group :

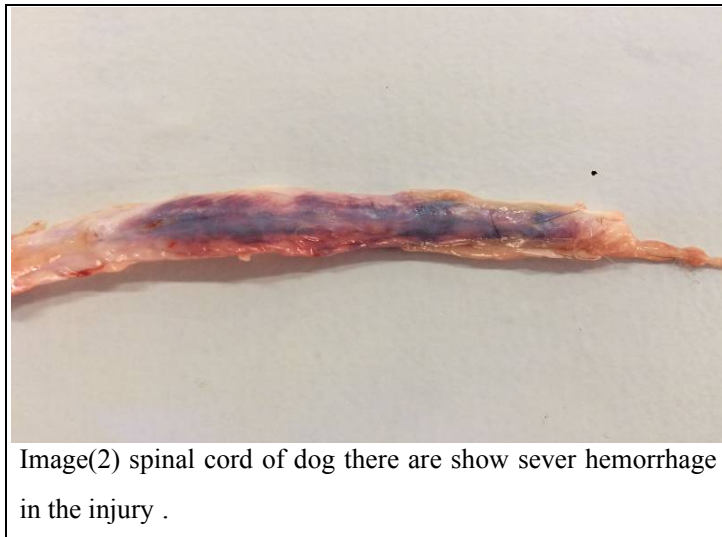In the eight week histopathological study of the spinal cord revealed marked vacuolated in the white matter which indicate the degeneration of the nerve fibers and some of them appear oedematous. In the gray matter there were some atrophied neurons and others appear necrotized, minimal proliferation oligodendrocytes in the site of injury was apparent (Images 5,6,7,8,9,10).

2-Dogs Group :

After eight weeks, histopathological study of the spinal cord revealed that there were high number of vacuolated degenerate nerve fibers, some of them appear oedematous at the site of injury. There were some of oligodendrocytes (Images.11,12,13,14).



Image(1)spinal cord of rat there are show mild congested in the site of injury.



Image(2) spinal cord of dog there are show sever hemorrhage in the injury .

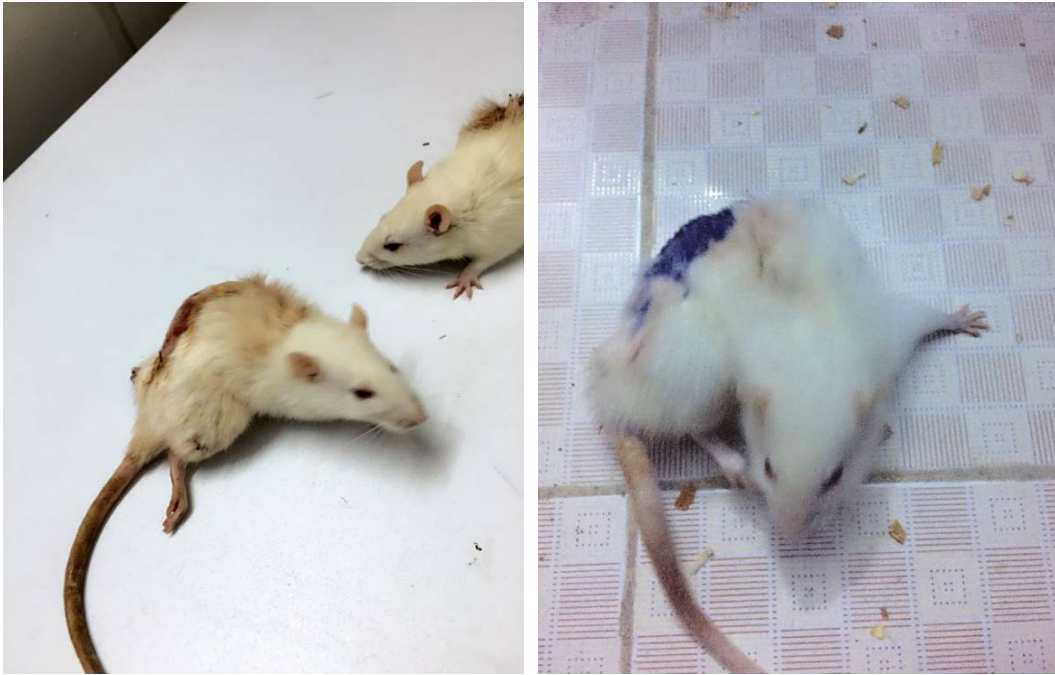
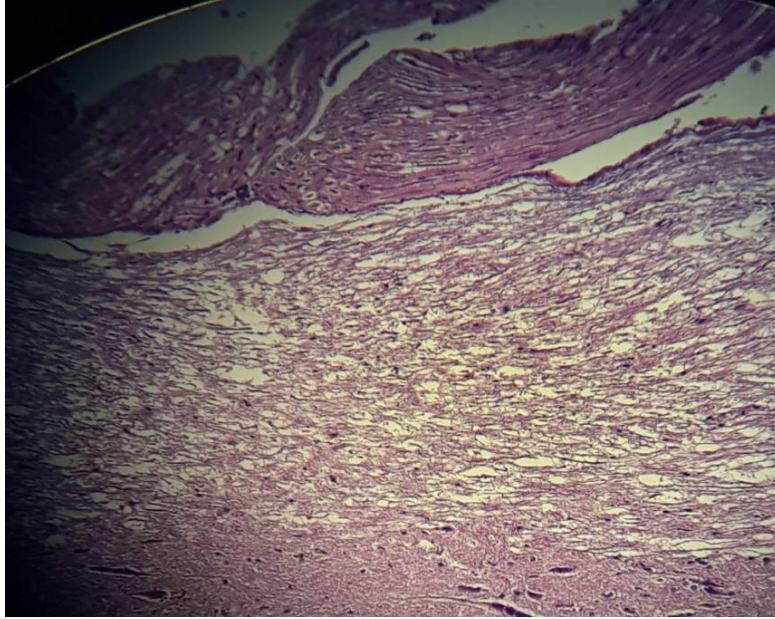


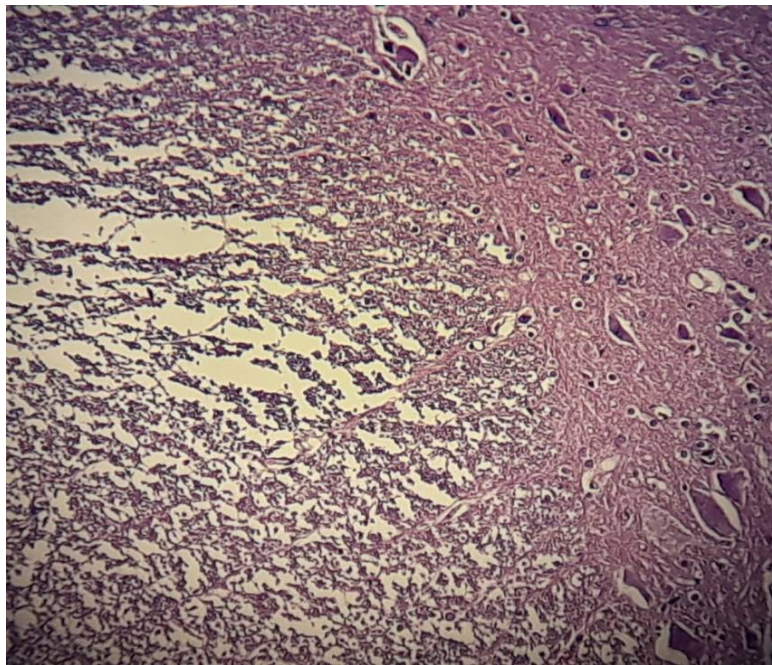
Image (3) show the rats post-operation.



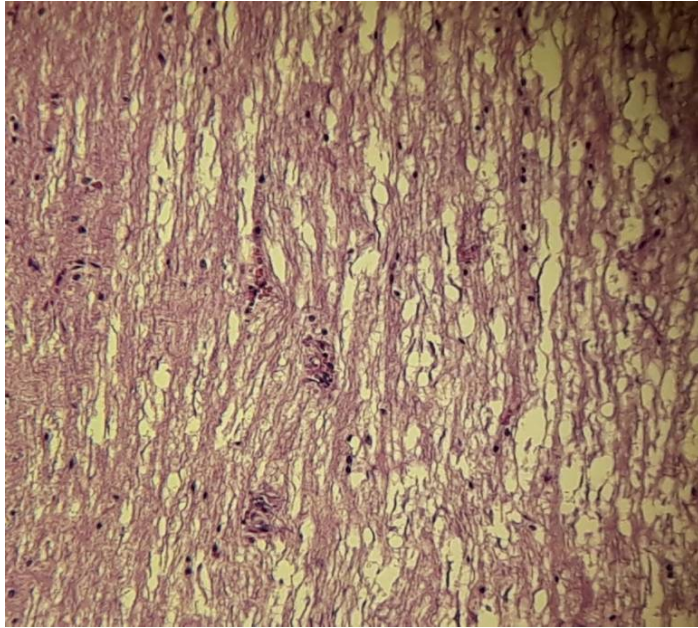
Image (4) show the dogs post-operation.



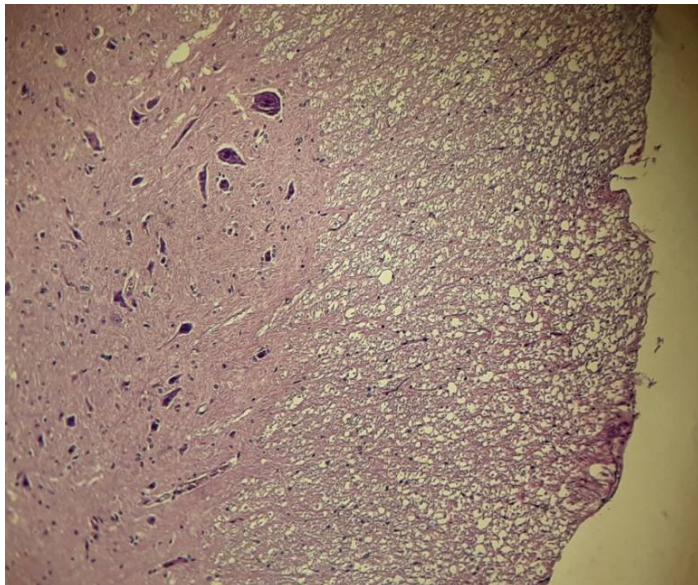
Image(5) longitudinal section of rats(2 month) present number of degenerative vacuolated nerve fibers in the white matter.X10.



Image(6)Transverse section of spinal cord in rat(2 month) show high number of degenerative vacuolated nerve fiber in the white matter and occasional oligodendrocyte. X10



Image(7) Longitudinal section of spinal cord in rat(2 month) show number of oligodendrocyte and degenerative vacuolated nerve fibers. X10



Image(8) Transverse section of spinal cord in rat(2 month) show white matter and grey matter and oligodendrocyte and degenerative nerve fibers in white matter. X10

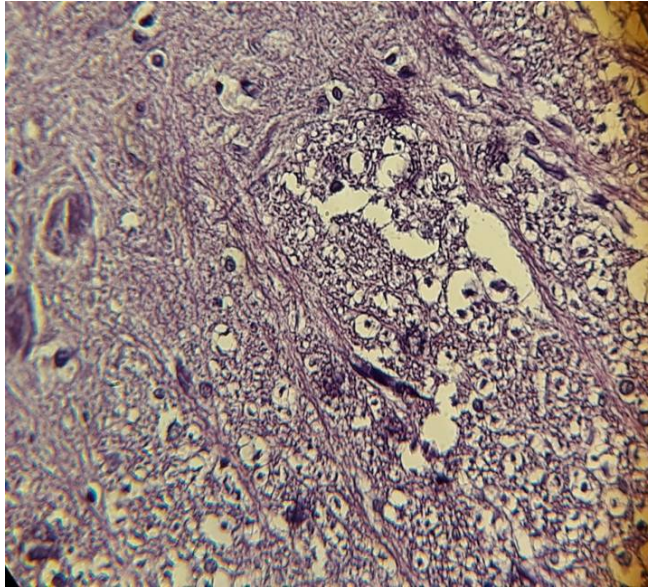
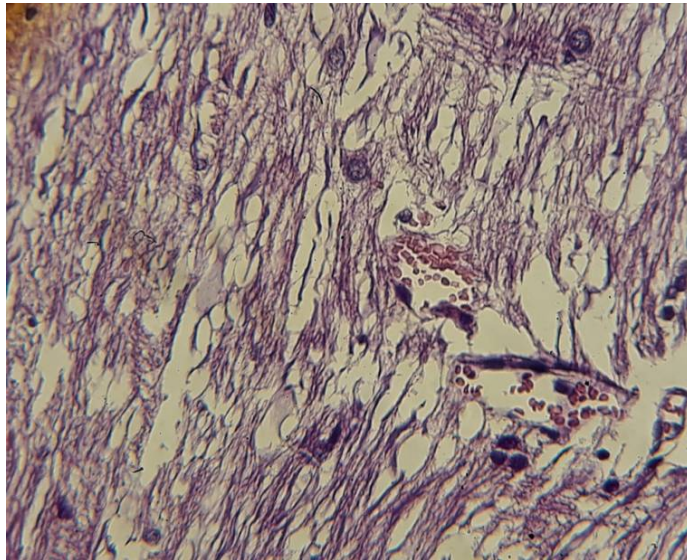
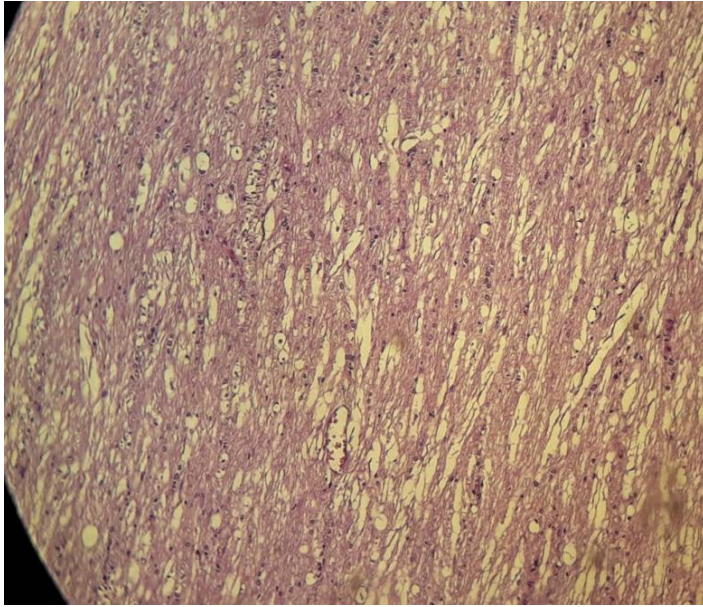


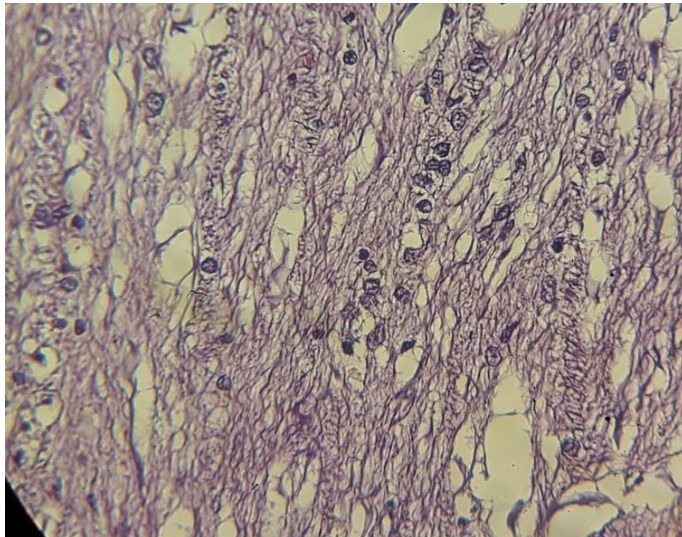
Image (9) Transverse section of spinal cord in rat (2 month) show oligodendrocytes and degenerative vacuolated of nerve fibers in white matter. X40



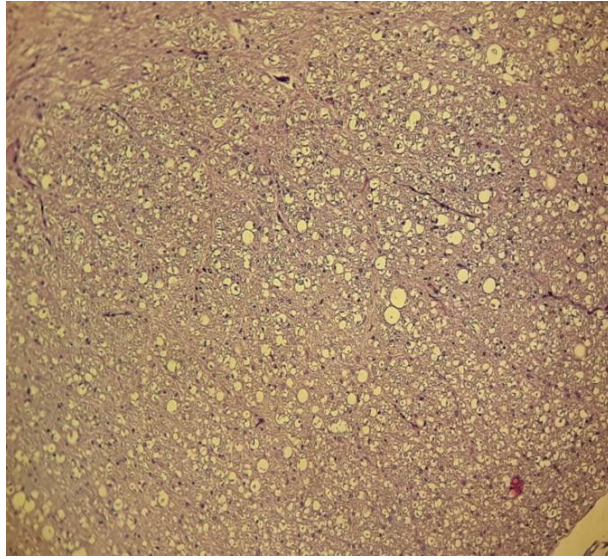
Image(10) Longitudinal section of spinal cord in rats(2 month) show congestion blood vessels and degenerative vacuolated of nerve fibers.X40



Image(11)Longitudinal section of spinal cord in dog(2 month) show several degenerative vacuolated nerve fiber in white matter. X10



Image(12)Longitudinal section of spinal cord in dog(2 month) show number of oligodendrocytes. X40



Image(13) Transverse section of spinal cord in dog(2 month) show several degenerative vacuolated nerve fiber in white matter. X10

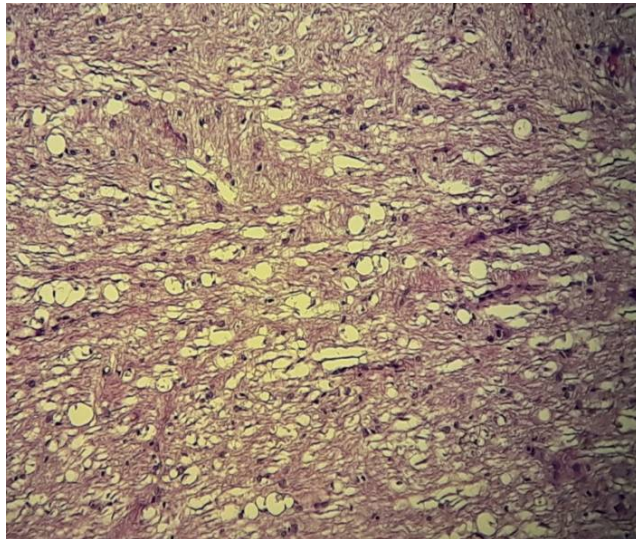


Image (14) Longitudinal section of spinal cord in dog(2 month) show several degeneration vacuolated of nerve fibers in white matter and present number of oligodendrocytes in varying degree . X10

Discussion

The neuro-histopathological inspection of the spinal cord in longitudinal section in the both groups revealed vacuolated of the nerve fibers in the white matter this attributed by key pro-inflammatory cytokines which lead to the secondary cascades of events that occur after several hours to days of spinal cord injury which include the mitochondrial dysfunction which lead to failure of aerobic energy metabolism and finally lead to production of free oxygen radicals which cause lipid peroxidation and lead to increase vascular permeability, local ischemia, and intraneuronal edema. Fiber deformation and local demyelination which refer to degenerate axons this agreed with (8).and this what called Wallerian degeneration which results from separation of axons and their myelin sheath from the neuronal cell body this agreed with (9).

The vacuolation in the gray matter result from degenerated and necrotized neurons in both groups, the neuronal cell necrosis result from ischemia which occur after spinal cord injury. Ischemia result from inadequate blood supply to the tissue lead to hypoxia and reduction in perivascular PH from accumulation of acid metabolites such as lactate this tissue perfusion may increase cellular damage by promoting the influx of free radicals and other toxic byproducts, this agreed with (10).

The present study revealed that in the both groups, there were vacuolated degenerate nerve fibers in the white matter after eight weeks post operation, in the gray matter the neurons appear slightly atrophied, also presence of cells with foamy cytoplasm which may be the oligodendrocytes which engulf the degenerate myelin also proliferation of new regenerate blood vessels were supported by (9).

The presence of glial scar is very important in the site of injury because it is act as a guide for crossing of new regenerated axons from one side of transaction or injury to the other and improves the conduction of nerve impulse and this agreed with (11).

The prominent changes which were noticed in the both groups of research may give indication about the effects of inflammation and responsible about the production of edema and degeneration, as a result the pain which result from tissue injury, this support the suggestion of this study.

Rapid signaling in neurons requires fast voltage sensitive mechanisms for closing and opening ions channels, anything that interferes with membrane voltage can alter channel

gaiting and comparatively small changes in the gaiting properties of channels can have profound effects(12) .

The most devastating thing which was increase damage of spinal cord after injury is the inflammation and many of the key players and the complex interrelationships involved in the secondary cascades of events occurring during the first minutes, hours, days after SCI (13).

Microglia are the first responders to the CNS trauma, being activated within minutes to hours of injury (14);(15);(16). The stimuli which activate microglia within the spinal cord have not been definitively elucidated but believed to change oxygen tension, alter the level of extracellular metabolites (e.g., glutamate), and cytokines/ chemokines secreting by neighboring cells (endothelia, neurons, glia) specially (Interleukin 1, Interleukin 6, Tumor necrosis factor - α), upon activation of microglia alter their phenotype and secretory properties and have rounded phagocytic morphology and secrete proinflammatory cytokines in rounded milieu (17); (18).

Exaggerated production of microglial TNF α in the brain is highly neurotoxic and cause cell death (19).

References

1. Amar, A. P. (2007). Pathogenesis of acute spinal cord injury and theoretical bases of neurological recovery. Chaptr 1. 1 – 8.
2. Bartholdi, D. and Schwab, M. S. (1995). Methylprednisolone inhibits early inflammatory processes but not ischemic cell death after experimental spinal cord lesion in the rat. *Brain Res.* 672: 177 - 186.
3. Becerra, J. L.; Puckett, W. R.; Hiester, E. D.; Quencer, R. M.; Marcillo, A . E.; Post, M. J.; and Bunge, R. P. (1995). MR pathologic comparisons of wallerian degeneration in spinal cord injury. *AM. J. neuroradiol* 16: 125 – 133.
4. Bunge, R. P.; Puckett, W. R.; Becerra, J. L. (1993). Observations on the pathology of human spinal cord injury. A review and classification of 22 new cases with details from a case of chronic cord compression with extensive focal demyelination. *Adv. Neurol.*, 59: 75–89.
5. Davies, S. J.; Fitch, M. T.; Memberg, S. P.; Hall, A. K.; Raisman, G. and Silver, J. (1997). Regeneration of adult axons in white matter tracts of the central nervous system. *Nature.* 390: 3 – 680.
6. Del – Bel, E. A.; Borges, C. A.; Defino, H. L.; Guimaraes, F. S. (2000). Induction of fos protien immunoreactivity by spinal cord contusion. *Brazilian J. Med Biol Res.* 33: 521- 528.
7. Giglio, C. A.; Defino, H. L. A.; Da-Silva, C. A.; De-Souza, A. S. and Del Bel, E. A. (2006). Behavioral and physiological methods for early quantitative assessment of spinal cord injury and prognosis in rats. *Brazilian J. Med. Biol. Res.* 39: 1613 – 1623.
8. Hall, E. D. and Springer, J. E. (2004). Neuroprotection and spinal cord injury: A Reappraisal, *The American society for experimental neurotherapies. Inc.* 1: 80- 100.
9. Holtz, A. and Levi, R. (2006). Effect of methylprednisolone in compression trauma to the feline spinal cord. *J. Neurosurg.* 55: 200 – 208.
10. Hulsebosch, C. E. (2000). Recent advances in pathophysiology and treatment of spinal cord injury. *Adv. physiol. Edu.* 26: 238 – 255.

11. Kim, J. V. and Dustin, M. L. (2006). Innate response to focal necrotic injury inside the blood-brain barrier. *J. Immunol.* 177: 5269 – 5277.
12. Kreutzberg, G. W. (1996). Microglia: A sensor for pathological events in the CNS. *Trends in Neurosciences.* 19: 312 – 318.
13. Nadeau, S. and Rivest, S. (2003). Glucocorticoids play a fundamental role in protecting the brain during innate immunity response. *J. Neurosci.* 23(13): 5536 – 5544.
14. Nimmerjahn, A.; Kirchhoff, F. and Helmchen, F. (2005). Resting microglial cells are highly dynamic surveillants of brain parenchyma in vivo. *Science.* 308: 1314 – 1318.
15. Pozzi, D.; Grimaldi, S.; Ledda, M.; De Carlow, F.; Modesti, A.; Scarpa, S.; Fclett, A. and List, A. (2007). Effect of 50 HZ magnetic field exposure on neuroblastoma morphology. *International J. Integrative Biol.* 1 (1): 12 – 17.
16. Sroga, J. M.; Jones, T. B.; Kigerl, K. A.; McGaughy, V. M. and Popovich, P. G. (2003). Rats and mice exhibit distinct inflammatory reactions after spinal cord injury. *J Comb Neurol.* 462: 223 – 240.
17. Tator, C. H. (1998). Biology on neurological recovery and functional restoration after spinal cord injury. *Neurosurg.* 42: 696 – 708.
18. Tator, C. H. and Koyanagi, I. (1997). Vascular mechanisms in the pathophysiology of human spinal cord injury. *J. Neurosurg.* 86: 483 – 492.
19. Tsai, M. C.; Shen, L. F.; Kuo, H. S.; Cheng, H.; Chak, K. F. (2008). Involvement of aFGF in spinal cord injury repair process revealed by a proteomic approach. *The American Society for Biochemistry and Molecular Biology, Inc.* 1 – 61.