

Study of neuropathological effect of Triortho Cresyl Phosphate in Midbrain of Hen

Methaq A. Abd Alsamad^{1*}, Batool Salim Hamza², Salma Saeed Abbas³, Mohammed A. Hasan⁴

^{1,2} Department of Pathology & Poultry Diseases, College Veterinary Medicine, University of Basrah, Iraq.

³ Department of Biology, Coleege of Education for Pure Science, University of Basrah, Iraq.

⁴ Department of Biology science, Collage of Education for Girls, University of Thi-Qar, Iraq.

*Corresponding author: lotfabadih97@gmail.com

ABSTRACT

The objective of our study was to investigate the neuropathological effects in hens after administration of triortho cresyl phosphate. The experiment was summarized as the following: one hundred eighty hens were divided into 2 main groups, the first group was acute neurotoxicity done on 60 hen divided equally into control and treatment which received single dose 600mg/kg orally for 18 days. The second group was sub chronic toxicity done on 120 chicken that in turn divided equally into 4 subgroups, these are (untreated control, 2, 4 and 8 mg/kg daily) for 100 days. Neurotoxicity of triortho cresyl phosphate in hen of midbrain in acute and one hundred days. Sub chronic studies showed mainly changes in the synapses characterized by disorganization, the presence of dark, degenerated mitochondria stained in synapses and ramifications. In some occasion's myelinated nerve, fibers showed evidence of degenerate myelin with vacuolation and spheroid body formation. In addition, myelin changes were characterized formation of laminated bodies, also auto phagocytosis of degenerate myelin. Furthermore, presence of degenerate mitochondria in axoplasm of axon and in cytoplasm of neurons. The degeneration of mitochondria characterized by loss of formation of laminated bodies in severe cases even deposits of calcium materials in the lamellated degenerate mitochondria. In conclusion the presence of degenerated lamellate calcified mitochondria could be a strong indication that triortho-cresyl phosphate, does not cause only degenerated myelin sheath of axon but also cause degeneration of mitochondria.

Keywords: Microscopy, Neuropathology, Midbrain and Hen.

Correspondence:

Methaq A. Abd Alsamad

^{1,2} Department of Pathology & Poultry Diseases, College Veterinary Medicine, University of Basrah, Iraq.

Email: lotfabadih97@gmail.com

INTRODUCTION

The discovery of the usefulness of organic phosphorus compounds as pesticides in the late 1930s has unfortunately led to the identification of some of the most toxic compounds synthesized by humans, including tapon, suman, sarin, cyclosarin, VR, and VX, which will collectively become known as nerve agents [1,2] Organic phosphorus agents (OPs) irreversibly prevent acolinstrase (AChE) causing large Colingea syndrome". [3] Outbreak of tri orothrospheric phosphate poisoning in Durban. [4]. There is general agreement that the patent program is much more toxic than TMCP or TPCP). The central and peripheral nervous system is particularly sensitive to tri-ortho-cresyl phosphate toxicity. [5] The government's response to the report was not to be taken into account. The cause of neuropathy can be attributed to tri-crisstophosphate (TCP) which was present as a

pollutant in gengili oil, and contamination is assumed to have occurred during the transport of oil in containers previously used to store mineral oils. [6] the dying back process. Common denominator is many natural and toxic neurological disorders. Late neuropathy caused by organic phosphorus is a neurological disorder characterized by a lack of voluntary coordination of muscle movement with cosy and associated axonotic and peripheral axonopathy [7]. [8] studied the neuropathy can delay due to some organophosphorus ester: mechanism and challenge. [9] studied the importance of the return process in experimental and human neurological disease. [11] explained the neurotoxicity of tri-calendar chrysili phosphate of adult

spinal cord causes a near-chronic delay in ninety days of chicken delay through oral gaatage. [12] studied a microscopic study of the electron showed the acute neurotoxicity of triorthotic crispy phosphate of the sciatic nerve in the adult hen [13] Morphological and neurotoxic analysis of neurotoxicity evidenced by tri-krisnil phosphate poisoning in the chick.[14] studied the neurotoxicity of tricresylphosphate (TCP) in slowloris (nycticebus coucang).[15] the tri-ocresyl phosphate studied intoxication and termination of sensory nerves of slow loris.[16] Delayed neurotoxicity caused by the organic phosphorus compound in wild malard ducks.[17] A study of the neurotoxicity produced by the long-term low-level local application of the leptophos to the hen comb.

MATERIALS AND METHODS

The study was included two experiments carried out on one hindered twenty hens, the first one was acute neurotoxic of triortho-cresyl phosphate included 60 hens divided equally into 2 groups, control and treated which administered single dose 600mg/kg orally for 18 days. The second experiment was sub chronic neurotoxicity study was done 120 hens divided into 4sub groups 30 hens each,these groups were untreated control , 2, 4 and then 8 mg/kg daily for 100 days. At the final period of the study, hens were sacrificed, the middle of the brain fixed in the glutaraldehyde,samples were taken and made cut by ultra-microtome. Thin sections 1ugfor histological orination and stained with toluidine blue for selection areas for electron microscope,

then the copper grids were made and stained with uranyl acetate and Lead citrate.

RESULTS

The toxic neurotoxic study of the aheal showed a 18-day semi-chronic 100-day neurotoxic study of tocp electron microscopy changes characterized by the presence of dark colored bodies suggesting the degenerated mitochondria in synapses that showed in fig. (1,2,6,9 and 10) also on some occasion 1 myelin that presented in fig.(3,4 and 5) also in fig. (7, 8) showed swollen of mitochondria with dark stained degenerate mitochondria.

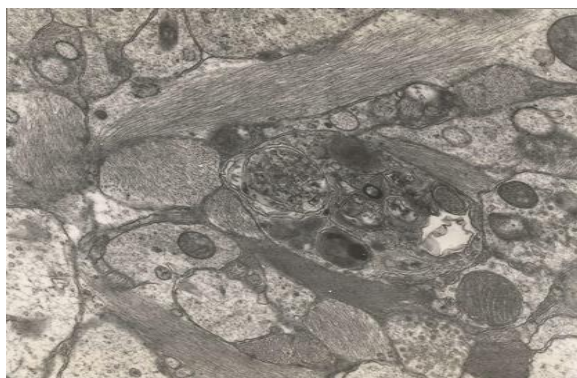

Fig 1. midbrain, medulla oblongata with conglomerate of degenerate buttons with lamellation and stained deposit (EM 20000X)

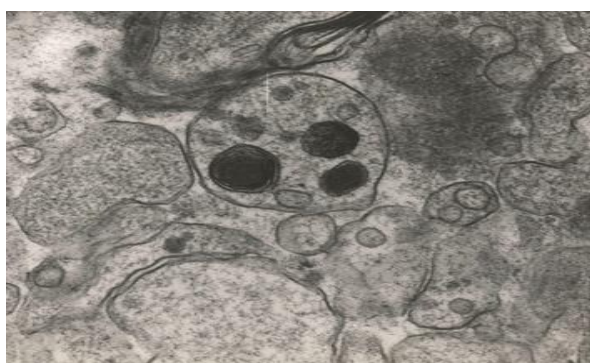


Fig 2. midbrain, synapses with dark stained degenerate lamellated mitochondria. (EM 30000X)

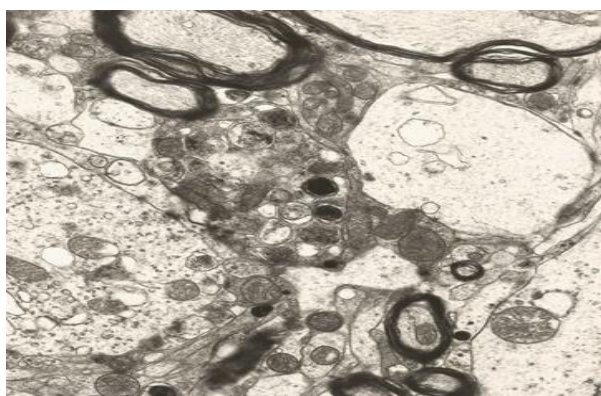


Fig 3. midbrain, nerve fibers with demyelination and synapses with degenerate dark stained mitochondria (EM 15000X)

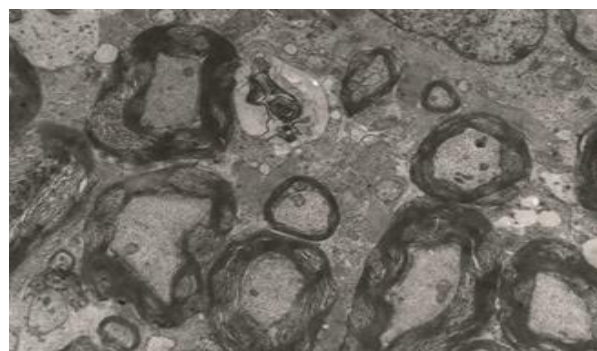


Fig 4. midbrain, synapses with degenerate mitochondria (EM 20000X)

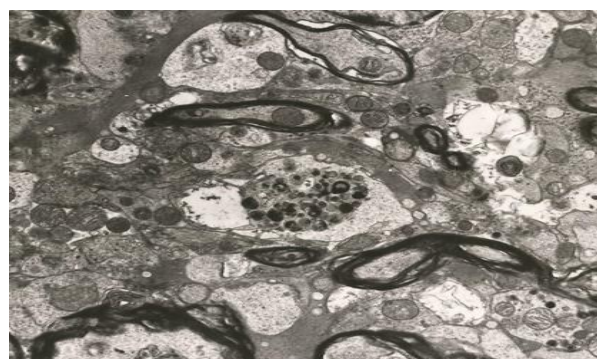

Fig 5. midbrain, in synapses some with degenerate lamellated mitochondria (EM 20000X)

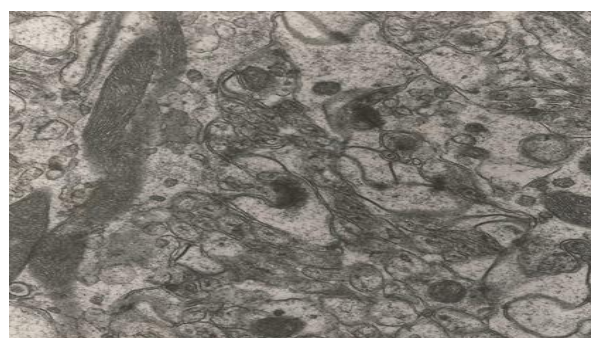

Fig 6. midbrain, synapses with dark stained degenerate mitochondria (EM 20000X)



Fig 7. midbrain synapses some with swollen mitochondria, other with dark stained degenerate mitochondria (EM 20000X)

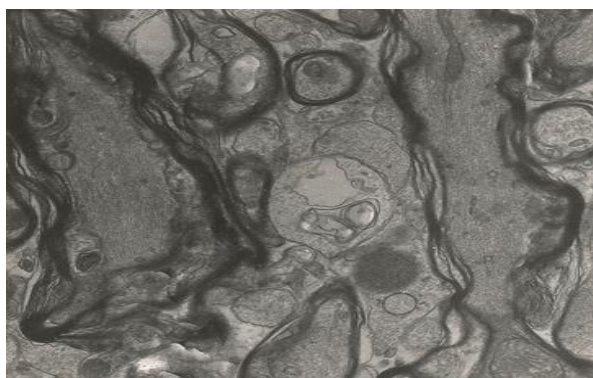


Fig 8. Midbrain, synapses with degenerate mitochondria (EM 30000X)

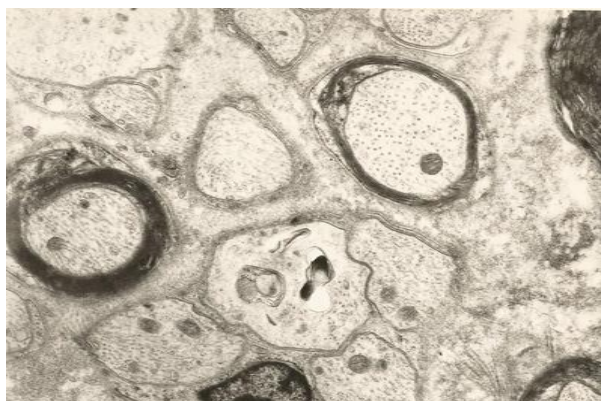

Fig 9. midbrain, synapses with degenerate dark stained mitochondria (EM 30000X)

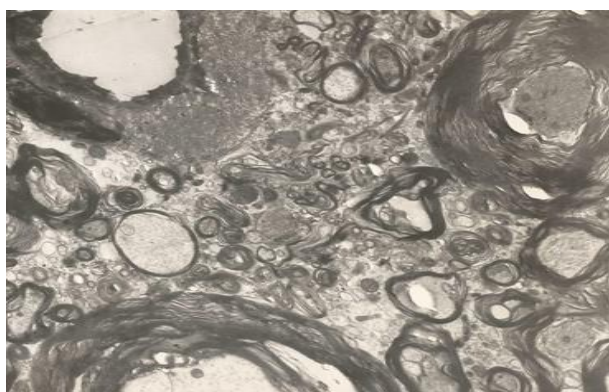


Fig 10. midbrain, synapses with degenerate dark stained mitochondria (EM 30000X)

DISCUSSION

The present electron microscopic finding in midbrain related to treatment with tri-ortho-cresyl phosphate was supported with the study done by [1] of intoxication of organophosphorus with reported ultrastructural changes in the midbrain due to neurotoxicity of tri-ortho-cresyl phosphate and that was in support of the finding of [2] which showed inhibition of choline esterase. [3] studied outbreak of tri-ortho-cresyl phosphate poisoning with reported changes due to neurotoxicity. The present study did electron microscopic analysis and found neurotoxic changes which support the finding [3]. The present investigated the ultrastructural changes which

were quite positive for the effect of organophosphorus and supported by the finding of [4]. The present study showed changes induced by neurotoxicity of organophosphorus in electron microscopic and that was supported by [5] who studied the histopathology induced by neurotoxic compound. The present study showed neurotoxic effect of organophosphorus on base of ultrastructural changes and those findings were supported by [6] who studied the toxic neuropathy of organophosphorus. The present study found conversing evidence of treatment related neurotoxicity by organophosphorus and the above was supported by [7] who explained the mechanism and action of neurotoxic compound such as organophosphorus. The present study showed the changes in midbrain due to neurotoxicity of organophosphorus in electron microscopic and that was supported by [8] which he studied the mechanism neurotoxicity of organophosphorus. [9] reported the significant changes induced by organophosphorus in man and animals. The present study supports the above finding as there was electron microscopic changes due to neurotoxicity of organophosphorus. The electron microscopic study of midbrain showed evidence of neurotoxic activity on nerve fibers induced by tri-ortho-cresyl phosphate and that was supported by [10] which he did neurotoxicity study and reported anticholinergic activity. [11] Evidence of recovery from peripheral neuropathy of the sciatic nerve, which was very prominent in the case of a single acute dose of neurotoxicity to tri-ortho-cresyl phosphate and while peripheral neuropathy of the sciatic nerve was reduced there was a gradual increase in the severity of the neuropathy of the central nervous system of the marrow Spinal with an increase in injury and the number of nerve fibers that show dissolved cavities associated with lumps of degenerative myelin in contrast to a single sharp dose of delayed neurotoxicity that was tightened by central neuropathy in the spinal cord was significantly lower than peripheral neuropathy of the sweat of the patterns. This study focused on electronic microscopy changes in mitochondria caused by the neurotoxicity of triortho-cresyl phosphate. [12] The result of the electron microscope of the sciatic nerve showed the degeneration of malin in the spinal nerve fibers characterized by the grafting of malin, a conglomerate of malin, the formation of the spherical body of the malin, the non-depressor of the malin elongated, and the alien also showed the current increase of the nerve of colored darkness Degenerative mitochondria. The current study focused on electronic microscopy changes in mitochondria in the central nervous system caused by the neurotoxicity of TOCP in adult chickens.

CONCLUSION

The present study gave details of electronic microscopic changes in the midbrain and pointed out that tri-orthocresyl phosphate potentially to neurotoxicity in adult hens by giving it for ninety days. Further researches are needed to throw more clarification of mechanisms associated with these valuable effects.

REFERENCES

1. Tucker, J. B. (2007). *War of nerves: chemical warfare from World War I to Al-Qaeda*. Anchor, pp 24-41, Pantheon Books, New York, 2006.

2. Masson, P., & Nachon, F. (2017). Cholinesterase reactivators and bioscavengers for pre-and post-exposure treatments of organophosphorus poisoning. *Journal of Neurochemistry*, 142, 26-40.
<https://doi.org/10.1111/jnc.14026>
3. Susser, M., & Stein, Z. (1957). An outbreak of tri-ortho-cresyl phosphate (TOCP) poisoning in Durban. *British journal of industrial medicine*, 14(2), 111.
<https://dx.doi.org/10.1136%2Foem.14.2.111>
4. Nanda, S., & Tapaswi, P. K. (1995). Biochemical, neuropathological and behavioral studies in hens induced by acute exposure of tri-ortho-cresyl phosphate. *International Journal of Neuroscience*, 82(3-4), 243-254.
<https://doi.org/10.3109/00207459508999804>
5. NIMAL, S., & SENANAYAKE, N. (1981). TRI-CRESYL PHOSPHATE NEUROPATHY IN SRI LANKA: A CLINICAL AND NEUROPHYSIOLOGICAL STUDY WITH A THREE YEAR FOLLOW UP.
6. Cavanagh, J. B. (1979). The 'dying back' process. A common denominator in many naturally occurring and toxic neuropathies. *Archives of pathology & laboratory medicine*, 103(13), 659.
7. Emerick, G. L., DeOliveira, G. H., dos Santos, A. C., & Ehrich, M. (2012). Mechanisms for consideration for intervention in the development of organophosphorus-induced delayed neuropathy. *Chemico-biological interactions*, 199(3), 177-184.
<https://doi.org/10.1016/j.cbi.2012.07.002>
8. Johnson, M. K., & Henschler, D. (1975). The delayed neuropathy caused by some organophosphorus esters: mechanism and challenge. *CRC Critical Reviews in toxicology*, 3(3), 289-316.
<https://doi.org/10.3109/10408447509079861>
9. Cavanagh, J. B. (1964). The significance of the "dying back" process in experimental and human neurological disease. *Int Rev Exp Pathol*, 3, 219.
10. Abd Alsamad, M. A., Hamza, B. S., Abbas, S. S., & Hasan, M. A. (2020). Study of neuropathological effect of Triortho Cresyl Phosphate in Midbrain of Hen. *Systematic Reviews in Pharmacy*, 11(2), 774-778.
11. AL-sereah, B. A., & SK, M. (2014). Sub chronic ninety days delayed neurotoxicity of tri ortho cresyl phosphate (TOCP) of spinal cord adult hen by oral gavage. *Journal of international academic research for multidisciplinary*, 2(9), 90-97.
12. AL-MOSAWI, O. F. ELECTRON MICROSCOPIC STUDY OF ACUTE NEUROTOXICITY OF TOCP (TRI ORTHO CRESYL PHOSPHATE) OF SCIATIC NERVE IN ADULT HEN MAJEED SALEH. K* AL-SEREAH BAHAA. A.3(4):488-495.
13. Glees, P. (1966). A morphological and neurological analysis of neurotoxicity illustrated by tricresyl phosphate intoxication in the chick. In *Proceedings of the European Society for the study of drug toxicity. VIII, Neurotoxicity of drugs* (pp. 136-148).
14. Ahmed, M. M., & Glees, P. (1971). Neurotoxicity of tricresylphosphate (TCP) in slow loris. *Acta neuropathologica*, 19(2), 94-98.
<https://doi.org/10.1007/BF00688487>
15. Vij, S., & Kanagasuntheram, R. (1972). Effect of tri-ortho-cresyl phosphate (TOCP) poisoning on sensory nerve terminations of slow loris. *Acta neuropathologica*, 20(2), 150-159.
<https://doi.org/10.1007/BF00691131>
16. Herin, R. A., Komeil, A. A., Graham, D. G., Curley, A., & Abou-Donia, M. B. (1978). Delayed neurotoxicity induced by organophosphorus compounds in the wild mallard duckling: Effect of leptophos. *Toxicology Letters*, 1(5-6), 253-259.
[https://doi.org/10.1016/03784274\(78\)90003-6](https://doi.org/10.1016/03784274(78)90003-6)
17. Abou-Donia, M. B., & Graham, D. G. (1978). Neurotoxicity produced by long-term low-level topical application of leptophos to the comb of hens. *Toxicol. Appl. Pharmacol.*, 46, 199-213.