

A Panoramic Study of the Morphology of Mandibular Condyle in a Sample of Population from Basrah City

Estudio Panorámico de la Morfología del Cóndilo Mandibular
en una Muestra de Población de la Ciudad de Basora

Aqeel Ibrahim Lazim Al-Saedi¹; Riad AL-Taee¹; Nada Hashim AL-Jasim² & Bahaa AL-Bakhakh¹

AQEEL AL-SAEDI, I. L.; AL-TAEE, R; AL-JASIM, N. H. & AL-BAKHAKH, B. A panoramic study of the morphology of mandibular condyle in a sample of population from Basrah city. *Int. J. Morphol.*, 38(6):1707-1712, 20202.

SUMMARY: The study aims to evaluate the morphological variation of mandibular condyle This analysis was composed of 450 digital orthopantomograms taken for routine investigation to assess the morphology of 900 condylar heads. Condylar morphology was classified into four types (oval, bird beak, diamond and crooked finger). Most common occurring shape were evaluated, symmetry of condylar shape and most common combinations of the condylar shapes present in population were assessed. Out of 900 mandibular condyle, type 1(oval) of condyle was the most commonly appearing shape (56 %), followed by type 3 (diamond), type 2(bird beak) and finally type 4 (crooked finger). Symmetry was seen in 74.2 % of the total sample with the oval-oval was the most commonly occurring. Routine use of orthopantomography can assist dentist in assessment of condylar morphology alterations. Oval shape was the most common in all age groups in males and females. More studies on Iraqi population evaluating mandibular condyle are needed to provide standardized values for mandibular anatomical parts.

KEY WORDS: Condyle, Orthopantomograph (OPG), Panoramic and temporomandibular joint(TMJ).

INTRODUCTION

Temporomandibular joint (TMJ) is one of the most complex human body structures and is a vital part of the masticatory system that helps in numerous functions including speaking, chewing and swallowing. The main components of TMJ are: condylar process, glenoid fossa, articular disc (which is positioned between condyle and glenoid fossa) and also the articular eminence (Ulhuq, 2008).

The condylar process is the key anatomic part of mandible that is responsible for growth of mandibular bone in both vertical and sagittal directions (Yavan *et al.*, 2019).

Radiographic examination of TMJ structures is necessary for evaluating the abnormalities and bony changes that affect the this joint (Al-koshab *et al.*, 2015).

The increasing incidence of TM disorders in recent years make it essential to have a thorough knowledge with understanding the anatomy and morphology of the TMJ for distinguishing normal variant from pathological conditions (Maqbool *et al.*, 2018).

As a part of the TMJ, Mandibular condyles may undergo changes in morphology throughout the life in response to functional loading. Changes in morphology of mandibular condyle may be caused by various causes as: infections, trauma , tumors, condylar hyperplasia and ankyloses (Anisuzzaman *et al.*, 2019).

Many studies have evaluated the morphology of the mandibular condyle and reported variation in the shape of condyle. Most of morphologic changes were detected in elderly people due to joint degenerative changes (Park *et al.*, 2014).

The complex structure of the TMJ makes radiographic examination difficult, and accurate diagnosis requires several types of radiographic images (Tassoker *et al.*, 2017).

Morphologic changes of mandibular condyle occur due to developmental variations, remodeling, different diseases, trauma, endocrine disturbances and radiotherapy. Among

¹ College of Dentistry ,University of Basrah, Iraq.

² Human Anatomy, Al-Zahraa College of medicine, University of Basrah, Iraq.

variable imaging techniques used for imaging of TMJ, panoramic radiographs are still considered as the main screening modality for TMJ abnormalities.

Panoramic radiography is the most common radiographic technique that was prescribed and interpreted by dental specialists (Sonal *et al.*, 2016). It is a routine imaging modality prescribed by dentists to get information about the teeth, maxilla, mandible, and adjacent parts of the jaw. It also has an accepted cost benefit relationship and when compared to computed tomography, the radiation exposure dose is relatively low (Habets *et al.*, 1989).

Honda *et al.* (1994) has reported that panoramic radiography was useful for detecting TM disorders, in particular in patients with osseous changes or flattening.

The present study aims to evaluate variation in morphology of mandibular condyle among people of Basrah city in southern Iraq as seen on orthopantomographs (OPGs).

MATERIAL AND METHOD

The present study was approved by Ethical Review Committee at College of Dentistry, university of Basrah. In this study, 900 mandibular condyles were included. The sample evaluated was 535 patients, only 450 patients (179 male vs 231 female) were included (85 were excluded). The average age of the included individuals was 37.4 years, with an age range between 18-66 years. Patients attending the oral diagnosis clinic at AL-Jazaer private dental center in Basrah city in southern Iraq between (1/6/2018-1/12/2019), OPGs included various clinical indications such as orthodontics, oral surgery and periodontics. All OPGs was conducted by a specialist oral radiologist with more than 10 years' experience using Vatech PaX-400C digital panoramic

x-ray machine (South Korea) operating at 10 mA, 90 Kv and 18 seconds exposure time. Patient positioning was conducted according to manufacturer instructions with obligation to dose reduction ALARA principle. Images were examined by an oral radiologist, a maxillofacial surgeon and a human anatomist concomitantly on hp-17 inches LED screen in a dark room using easy dent software built in Vatech PaX-400C-panoramic machine.

A second check for 15 % of the total sample was conducted randomly within 15 days after the first check to assess intra-observer reliability.

The exclusion criteria included: History of trauma in the maxillofacial region, edentulous patients (fully edentulous or partially edentulous in posterior area), patient with history of TM disorders, history of orthodontic treatment, presence of bony lesion in maxilla or mandible and radiographic technique error affecting imaging of mandibular condyle.

Morphology of mandibular condyles was classified according to what was identified by Chaudhary *et al.* (2015) into four shapes (Figs. 1 to 4):

Type I: Oval; Type II: Bird beak; Type III: Diamond and Type IV: Crooked finger (Fig. 1).

Statistical analysis Statistical evaluation of the data was performed by using IBM SPSS Statistics ver. 22.0 for Windows (IBM Co., Armonk, NY, USA) to evaluate morphology of mandibular condyle on both side. Pearson chi-square test was used to evaluate the correlation between males and females, and between age groups. Symmetry of condyle shapes and most common appearing combination of condylar shapes was evaluated. P values less than 0.05 were considered statistically significant while P values less than 0.001 was considered as a highly significant.

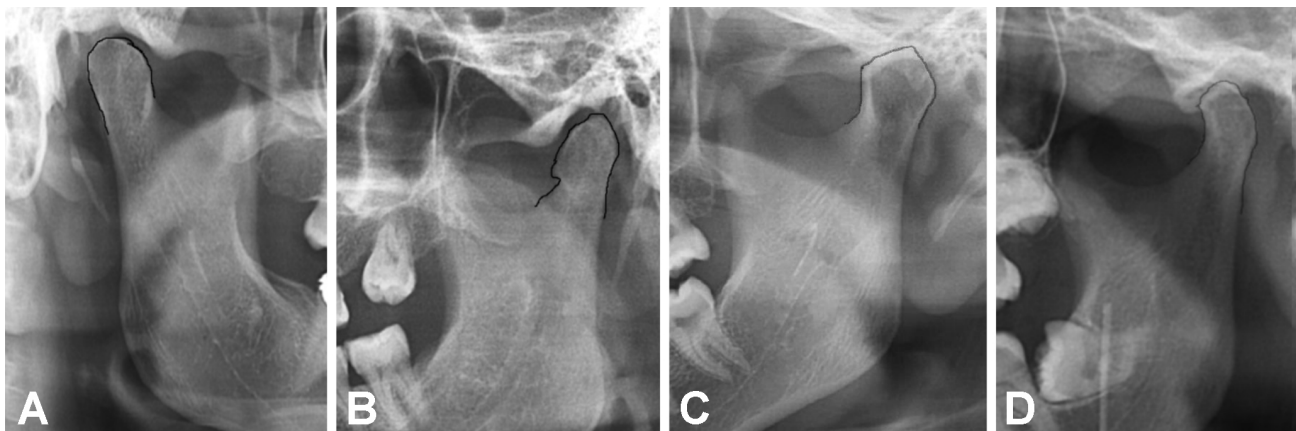


Fig.1. Types of mandibular condyle shapes, A. type 1: Oval, B. type 2: Bird beak, C. type 3: Diamond, D. type 4: Crooked finger..

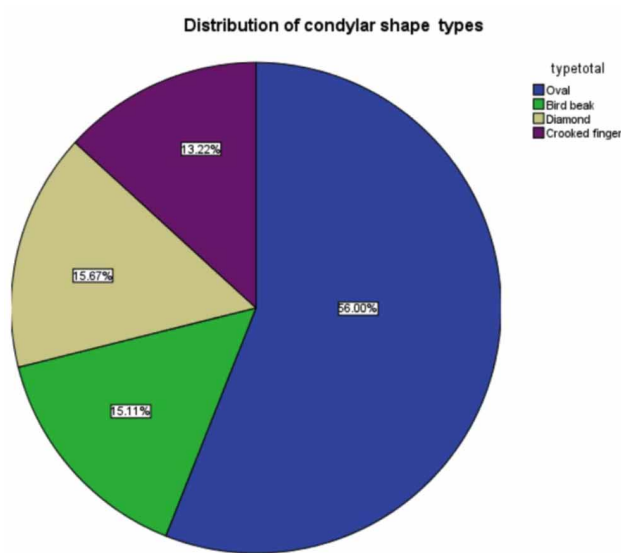


Fig. 2. Distribution of condylar shape types Condylar shape types.

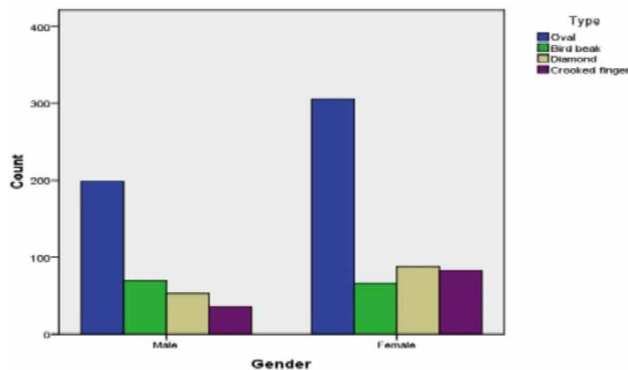


Fig. 3. Distribution of condylar shape types according to sex.

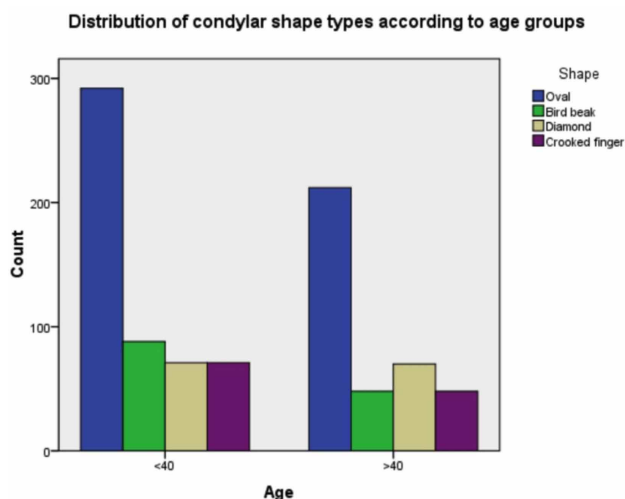


Fig. 4. Distribution of condylar shape types according to age group.

RESULTS

Digital OPGs for 450 patients (179 male vs 271 female) was included in the present study, with age range between 18-66 years and average age of 37.4 years.

Type 1 (oval) was the most predominant appearing shape which occurred in 501 out of 900 condyle (56 %); it appeared in approximate proportion in male and females (55.6 % vs 56.3 % respectively). Type 3 (diamond) was noticed in 15.7 % (14.8 % in males vs 16.2 % in females) while type 2 (bird beak) occurred in 15.1 % of the total sample (15.6 % in males vs 12.2 % in females), finally type 4 (crooked finger) appeared in 13.2 % of the total sample (10 % in males vs 15.3 % in females). Pearson Chi-Square test showed highly significant difference between right and left sides in males and females and there was also a significant difference between the two sexes (Table I).

Oval shape was the most common occurring type of condylar shape in both age groups, it was seen in 56 % in the two age groups. Bird beak shape was noticed in 16.8 % in group1 (<40) and 12.7 % in group 2 (>40), Diamond shape was reported in 13.6 % and 18.6 % in group1 and group 2 respectively, while crooked finger shape was the least appearing shape which occurred in 13.6 % in group 1 versus 12.7 % in group 2. Pearson Chi-Square test showed Non-Significant difference between the two agegroups (Table II).

Symmetrical condylar shape occurred in 334 out of 450 OPGs representing 74.2 % of the total sample.

Most common type combination on both sides of the mandible was val-oval that occurred in 207 out of 450 OPGs (46 %), followed by crooked finger-crooked finger combination which appeared in 47 radiographs (10.4 %), then diamond-diamond and bird beak- bird beak diagnosed in 38 radiographs (8.4 %) (Table III).

Cohen kappa test was performed to evaluate intra-observer reliability, Cohen kappa test value was found to be 0.88 indicating almost perfect reliability.

DISCUSSION

TMJ has many features both anatomically and functionally which make it unique among other human body joints (Mathew *et al.*, 2011).

Many studies have to evaluated the appearance of

Table I. Distribution of condylar shape types according to gender and side.

Sex	Side/Type	Type 1 Oval	Type 2 Bird beak	Type 3 Diamond	Type 4 Crooked finger	Total	<i>p-Value*</i>
Male	Right	101 56.4 %	26 14.5 %	32 17.9 %	20 11.2 %	179	<.001 Highly significant
	Left	98 55.6 %	44 15.6 %	21 14.8 %	16 10 %	179	358
	Total	199	70	53	36		
Female	Right	164 60.5 %	20 7.4 %	40 14.8 %	47 17.3 %	271	<.001 Highly significant
	Left	141 52 %	46 17 %	48 17.7 %	36 13.3 %	271	.006 highly significant
	Total	305	66	88	83	542	
Total		504 56%	136 15.1 %	141 15.7 %	119 13.2 %	900	

* Pearson Chi square.

Table II. Distribution of condylar shape types according to age group.

Age	Side/TYPE	TYPE 1 1 Oval	TYPE 2 2 Bird beak	TYPE 3 Diamond	TYPE4 Crooked finger	Total	<i>P-Value*</i>
<40	Right	153 58.6 %	30 11.5 %	38 14.6 %	40 15.3 %	261	.110 Non-Significant
	Left	139 53.3 %	58 22.2 %	33 12.6 %	31 11.9 %	261	
	Total	292	88	71	71	522	
>40	Right	112 59.2 %	16 8.5 %	34 18 %	27 14.3 %	189	
	Left	100 52.9 %	32 16.9 %	36 19.1 %	21 11.1 %	189	
	Total	212	48	70	48	378	
		56 %	12.7 %	18.6 %	12.7 %		

*Pearson Chi-Square.

Table (III). Distribution of most common combinations of condylar shapes.

Right/left	TYPE 1 Oval	TYPE 2 Bird beak	TYPE 3 Diamond	TYPE4 Crooked finger	Total
TYPE 1	207	31	22	5	265
Oval	46 %	6.9 %	4.9 %	1.1 %	
TYPE 2	3	38	5	0	46
Bird beak	0.7 %	8.4 %	1.1 %	0 %	
TYPE 3	20	14	38	0	72
Diamond	4.4 %	3.2 %	8.4 %	0 %	
TYPE4	9	7	4	47	67
Crooked finger	2 %	1.6 %	0.9 %	10.4 %	
Total	239	90	69	52	450

the human condyles and coronoid process and sigmoid notch (Sahithi *et al.*, 2016).

Various classifications were produced for condylar morphology. Many studies have classified condyle into

round, angle, convex and flat (Sahithi *et al.*; Nagaraj *et al.*, 2017; Tassoker *et al.*; Derwich *et al.*, 2020), most of these studies have used CBCT. Other studies used a nearly similar classification to the previous one, where condyle was classified into round, angle, pointed and flat (Oliveira *et al.*,

2009). The present study classified condylar shape into oval, bird beak, diamond and crooked finger, such a classification was used by some previous studies using panoramic radiographs in their studies (Sonal *et al.*; Anisuzzaman *et al.*).

In the present study performed on a sample of southern Iraqi population from Basrah city, the most common appearing shape of mandibular condyle was oval shape followed by bird beak shape, then diamond and crooked finger shapes; this finding supports the results of many previous studies; Anisuzzaman *et al.* study have reported that the oval was the most common shape 69 % followed by bird beak 20 % with less common being crooked finger. Sonal *et al.* in their study in Indian population also found that the most common shape was oval (60 %), which was followed by bird beak (29 %), diamond (9 %), and the least appearing shape was also crooked finger (2 %). Round (oval) shape was also reported to be the most common shape in a study achieved by Sahithi *et al.* Although crooked finger shape appears more commonly in the present study when compared to results of other studies; it is still the least noticed shape.

In our study, there was a highly significant difference in condylar shape between right and left sides of mandible in males and females and also between sexes (Table I), such finding was also reported by Maqbool *et al.* study and also by Gindha *et al.* (2017), study on dry skulls.

There was no significant difference between age groups in the present study (Table II), this finding goes in line with the results reported by several previous studies (Sahithi *et al.*; Nagaraj *et al.*; Ashwinirani *et al.*, 2018; Anisuzzaman *et al.*).

As was noticed in this study, in most of the patients, condylar shape was symmetrical on both sides of mandible (74.2 %). Such finding is similar to what was stated by Anisuzzaman *et al.* who reported that 69 % of their sample showed symmetrical condyles. Olivera's Brazilian study also reported that that nearly 2/3 of their sample showed identical condylar shape for the same patient (Oliveira *et al.*).

Regarding most commonly appearing combination of condylar shape, we have found that oval-oval combination have appeared in 45.7 % of the cases, it was followed by crooked finger-Crooked finger combination in 10.8 % then diamond-diamond combination that occurred in 8.8 % of the sample (Table III), this in general supports results of Anisuzzaman *et al.* study which found that oval/oval is the most commonly noticed combination (66 %) followed by oval/bird beak that occurs in 25 % of the sample with a less occurrence of crooked finger/ crooked finger combination (1 %) such results was also reported by other studies on samples of different ethnicities (Sonal *et al.*).

The results of the present study on Iraqi population were approximately similar to the results of studies conducted on further populations.

CONCLUSION

The present study was conducted to explore the most prevalent radiographic shapes of the mandibular condyle on the OPG. Oval shape was observed to be the most common in both genders with the condyle shape being symmetrical in about three quarters of the studied sample. Oval-oval was the most occurring combination. Further studies on Iraqi patients is needed especially using CBCT.

AQEEL AL-SAEEDI, I. L.; AL-TAEE, R.; AL-JASIM, N. H. & AL-BAKHAKH, B. Estudio panorámico de la morfología del cóndilo mandibular en una muestra de población de la ciudad de Basora. *Int. J. Morphol.*, 38(6):1707-1712, 2020.

RESUMEN: El objetivo del presente estudio fue evaluar la variación morfológica del cóndilo mandibular. El análisis se realizó en 450 ortopantomogramas digitales en una investigación de rutina para evaluar la morfología de 900 cabezas condilares. La morfología condilar se clasificó en cuatro tipos (ovalada, pico de pájaro, diamante y dedo torcido). Se evaluó la forma más común de ocurrencia, la simetría de la forma condilar y las combinaciones más comunes en la población. De 900 cóndilos mandibulares, el tipo 1 (ovalado) de cóndilo apareció con mayor frecuencia (56 %), seguido del tipo 3 (diamante), el tipo 2 (pico de pájaro) y finalmente el tipo 4 (dedo torcido). Se observó simetría en el 74,2 % de la muestra total, siendo el óvalo-óvalo el que se presentó con mayor frecuencia. El uso rutinario de la ortopantomografía puede ayudar al dentista a evaluar las alteraciones de la morfología condilar. La forma ovalada fue la más común en todos los grupos etarios en hombres y mujeres. Se necesitan más estudios sobre la población iraquí que evalúen el cóndilo mandibular para proporcionar valores estandarizados para evaluar la anatomía mandibular.

PALABRAS CLAVE: Cóndilo; Ortopantomografía (OPG); Radiografía Panorámica; Articulación temporomandibular (ATM).

REFERENCES

- Al-koshab, M.; Nambiar, P. & John, J. Assessment of condyle and glenoid fossa morphology using CBCT in South-East Asians. *PLoS One*, 10(3):e0121682, 2015.
- Anisuzzaman, M.; Khan, S. R.; Khan, M. T. I.; Abdullah, K. & Afrin, A. Evaluation of mandibular condylar morphology by orthopantomogram in Bangladeshi population. *Update Dent. Coll. J.*, 9(1):29-31, 2019.

- Ashwinirani, S. R.; Patil, S. T.; Nair, B.; Rajmane, Y. & Kamala, K. A. Morphological variations of condylar process and sigmoid notch using Orthopantomograms in Western part of Maharashtra population. *Int. J. Appl. Dent. Sci.*, 4(1):160-3, 2018.
- Chaudhary, S.; Srivastava, D.; Jaetli, V. & Tirth, A. Evaluation of condylar morphology using panoramic radiography in normal adult population. *Int. J. Sci. Stud.*, 164-8, 2015.
- Derwich, M.; Mitus-Kenig, M. & Pawlowska, E. Morphology of the temporomandibular joints regarding the presence of osteoarthritic changes. *Int. J. Environ. Res. Public Health*, 17(8):2923, 2020.
- Gindha, G. S.; Singh, T. P.; Sood, K. S. & Maharana, S. S. Amorphometric study of condyloid process of dry human mandible for sexing from its shape. *MOJ Anat. Physiol.*, 3(2):58-62, 2017.
- Habets, L. L.; Bezuur, J. N.; Jimenez Lopez, V. & Hansson, T. L. The OPG: an aid in TMJ diagnostics. III. A comparison between lateral tomography and dental rotational panoramic radiography (Orthopantomography). *J. Oral Rehabil.*, 16(4):401-6, 1989.
- Honda, E.; Yoshino, N. & Sasaki, T. Condylar appearance in panoramic radiograms of asymptomatic subjects and patients with temporomandibular disorders. *Oral Radiol.*, 10:43-53, 1994.
- Maqbool, S.; Wani, B. A.; Chalkoo, A. H. & Sharma, P. Morphological assessment of variations of condylar head and sigmoid notch on orthopantomograms of kashmiri population. *Int. J. Recent Sci. Res.*, 9(10):29162-5, 2018.
- Mathew, A. L.; Sholapurkar, A. A. & Pai, K. M. Condylar changes and its association with age, TMD, and dentition status: a cross-sectional study. *Int. J. Dent.*, 2011:413639, 2011.
- Nagaraj, T.; Nigam, H.; Santosh, H. N.; Gogula, S.; Sumana, C. K. & Sahu, P. Morphological variations of the coronoid process, condyle and sigmoid notch as an adjunct in personal identification. *J. Med. Radiol. Pathol. Surg.*, 4(2):1-5, 2017.
- Oliveira-Santos, C.; Bernardo, R. T. & Capelozza, A. L. A. Mandibular condyle morphology on panoramic radiographs of asymptomatic temporomandibular joints. *IJD Int. J. Dent. (Recife)*, 8(3):114-8, 2009.
- Park, I. Y.; Kim, J. H. & Park, Y. H. Three-dimensional cone-beam computed tomography based comparison of condylar position and morphology according to the vertical skeletal pattern. *Korean J. Orthod.*, 45(2):66-73, 2014.
- Sahithi, D.; Reddy, S.; Divya Teja, D. V.; Koneru, J.; Sai Praveen, K. N. & Sruthi, R. Reveal the concealed – Morphological variations of the coronoid process, condyle and sigmoid notch in personal identification. *Egypt. J. Forensic Sci.*, 6(2):108-13, 2016.
- Sonal, V.; Sandeep, P.; Kapil, G. & Christine, R. Evaluation of condylar morphology using panoramic radiography. *J. Adv. Clin. Res. Insights*, 3:5-8, 2016.
- Tassoker, M.; Kabakci, A. D. A.; Akin, D. & Sener, S. Evaluation of mandibular notch, coronoid process, and mandibular condyle configurations with cone beam computed tomography. *Biomed. Res. (India)*, 28(19):8327-35, 2017.
- Ulhuq, A. Management of temporomandibular disorders and occlusion (6th edition). *Br. Dent. J.*, 204:535, 2008.
- Yavan, M. A.; Isman, E. & Kocahan, S. Evaluation of condylar structures on panoramic radiographs in adolescent patients with coeliac disease. *Folia Morphol. (Warsz.)*, 78(1):191-4, 2019.

Corresponding author:

Aqeel Ibrahim Lazim Al-Saedi B.D.S, M.Sc.

Lecturer

College of Dentistry

University of Basrah

IRAQ

Email: Aqeel.lazim@uobasrah.edu.iq

Received: 19-06-2020

Accepted: 10-08-2020