Veterinary Sciences and Medicine

RESEARCH ARTICLE

Efficacy of Nucleo CMP Forte after Induce Spinal Cord Injury in Rats

Abdulbari A. Alfaris[1]* Zainab Hashim Radha[2] & Batool S. Hamza[2]

[1]Department of Surgery & Obstetric, College of Veterinary Medicine University of Basrah. Iraq.
[2]Department of poultry disease &pathology, College of Veterinary Medicine, University of Basrah. Iraq.

Abstract

This study was carried out to evaluate the efficacy of Nucleo CMP Forte therapy as a single therapy on the regeneration of spinal cord injury in laboratory rats. Twenty adult white rats were used in this study , divided into two groups, each group consists of ten animals control group and Nucleo CMP forte treated group Spinal cord had been transected in all animals of experiment control group and . Nucleo CMP Forte (30 mg/kg) was given intramuscularly in Nucleo CMP immediately after spinal cord transection in CMP treated group. In the group of Nucleo CMP, The group of which administered CMP. Animals of each group sacrificed on two periods of time after 6, 12 weeks, clinical assessment for the motor and sensory functions were done throughout the time of experiment, macroscopic and microscopic examination of the spinal cord were done after sacrificing of the animals.

Results indicate that the axonal regeneration. In Nucleo CMP Forte the results showed that the improvement of motor and sensory functions, degree of spinal cord cooptation and the glial scar formation and axonal regeneration were less than that Nucleo CMP Forte, this being more obvious in respect to the macroscopic findings in which the degree of spinal cord cooptation was better than the other group, microscopic findings also showed massive glial scar formation and axonal regeneration in the same group.

Keywords: Nerve, Nucleo CMP Forte, rats, regeneration.

Abbreviations: SCI: Spinal cord injury; CMP: cytosine monophosphate.

Introduction

Spinal cord injury (SCI), a devastating condition affecting the central nervous system, is associated with sensory, motor and visceral function impairment as well as chronic pain [1]

In spinal cord injury (SCI), complete or partial loss of autonomic, sensory, and motor functions is caused by interruption of neural signal conduction along the axonal tracts. There is generally poor recovery of these functions because of the difficulty of tissue regeneration in the central nervous system. Thus, SCI patients are left with serious residual disabilities, such as paralysis, respiratory difficulty, chronic pain, urinary problems, and neurologic decline, leading to considerable decrease in quality of life. Various strategies have been examined for repair of SCI in animal models, including blockage of the endogenous growth inhibitory factors [2]. Infusion of neurotropic factors, transplantation of growth promoting cells [3].

Nucleo cytosine monophosphate (CMP) is mainly used for peripheral neurological disorders like trigeminal neuralgia, diabetic neuropathy and lumbosciaticalgia , but its central roles remain to be elucidated, Nucleo CMP improve neural growth and nerve repair, regeneration of militated nerve fiber, delay spinal pain transmission , enhance spinal density and acceleration of hippocampal dependent working memory in animal model study also, Nucleo CMP contains uridine monophosphate, uridine diphosphate and uridine triphosphate, which together with cysteine monophosphate induce biosynthesis of neuronal glycolipid, phospholipids. Nucleo CMP crosses the blood brain barrier and then phosphorylated into uridine triphosphate that lead to the triggering of neurotransmitter modulation [4].

A clinical trial on the combination of CMP and UTP have resulted in an efficacy of this treatment on the pain as well as on the sensory conduction velocity in poly-neuropathies [5].The combination of CMP and UTP has demonstrated its efficacy on sensory disorders as well as on the intensity of the pain in diabetic neuropathy. It is increased in sensory conduction velocity. It was well tolerated clinically and biologically [6].

An important assist in the rehabilitation process can improve muscle strength and provide enhanced layout in general, Cytidine-5-monophosphate disodium (CMP) is a nucleotide that effectively interfere in the metabolism of the nervous

Correspondence to: Abdulbari A. Alfaris, College of Veterinary Medicine, university of Basra, Basra, Iraq Tel: (00964)780-4077140, Email: vetedu2013[AT]gmail[DOT]com

Received: May 10, 2018; **Accepted:** May 12, 2018; **Published:** May 15, 2018

system by taking part as a co-enzyme of the enzyme systems involved in the synthesis of phospholipids and glycolipids. These fundamental lipid substances for the operation and normal activity of the nervous system are subject to a constant process of degradation and synthesis, (CMP) whose action for glycolipid synthesis is completed by uridine-5'-triphosphate (UTP), it becomes a coenzyme factor completely necessary for the conservation and regeneration of nervous structures, especially as regards the myelin sheath. The aim of the study to evaluate the efficacy to evaluate the effect of Nucleo CMP Forte on the regeneration of central nervous system.

Material & Methods

Twenty laboratory rats (Rattus norvegicus) weighing 200±50 gm, were used. Animals accommodated in same laboratory condition by keeping them in special cages (4 animals per cage) for about 15 days before the operation for anti-microbial, anti-parasitic drug administration and acclimatization. Animals were weighed immediately after buying them and weighed again before the beginning of the experiment, and then they were weighted weekly for one month after surgical intervention to induce spinal cord injury, then every two weeks till the end of experiment.

Control group the spinal cord of the animals was transected and the animal receives no treatment specific for the spinal cord injury. The data were recorded daily for four weeks then weekly till the end of the experiment at 12 weeks.

Nucleo CMP Treated Group After incomplete transection of the spinal cord and after a surgical intervention the animals. Animals were anaesthetized before operation by intramuscular injection of a mixture of 50 mg /kg B.W ketamine hydrochloride and 10 mg/kg B.W xylazine. Adorsal incision was made in the mid-lumbar region of the anaesthetized rats muscle retracted in the (Lumbar L2- L3) to expose the vertebral bone plate which was still intact [7]. Laminectomy the vertebra was approached as described above and the vertebral bone of the L3 segment was removed bilaterally to expose the dear mater, which was left intact (Figure 1) [8].

Results

Following spinal cord transected the symptoms which appeared below the level of injury include loss of movement in hind limb, loss of sensation and loss of bowel and bladder control. Control group: Which is known as transected untreated? The clinical assessment of the animals of this group showed. In the First week post-operation: Marked paralysis of the hind limb and the sensation was lost where there was no response to the pricking of the hind limbs and the animals showed weight loss and there is sever autonomic dysfunction (bladder and bowel functions-Second week post-operation: Loss of weight has been marked during this week, Animals of this group also developed stiffness of hind limb, joints. These clinical observations extend to the end of experiment where there is no improvement and the animals still paralyzed up to 12 weeks.

Nucleo CMP Forte treated group: Like in other group, there was partial paralysis after operation. The clinical assessment of the animals in this group was as the following: First week post-operation: there was marked loss of motor and sensory function in hind limb with marked weight loss. These clinical signs extend from the first week to the sixth week except the weight and autonomic functions in which the animals appeared improvement in autonomic function in third week and regain weight in fifth week. Sixth week post-operation. The first onset of the hind limb movement was observed in four animals and in the seventh week in one animal only but still there is no obvious sensation Eighth week post-operation: Most animals developed their movement and appear moderate muscular contraction. Ninth week post-operation three animals showed obvious sensation in the hind limb. Tenth week post-operation. The animals developed moderate ability to stand on their hock joints; the sensation being noticeable in which the animals showed a clear reflex to the hind limb pricking Twelfth week post-operation: the animals had a moderate muscular contraction and they depend more in their movement on hock joint and did not use their paws and still there was a mild reflex to the pricking of the hind limb.

In the sixth week histopathology Control Group of the spinal cord revealed marked vacculation in the white matter which indicate the degeneration of the nerve fibers and some of them appear oedematous. In the gray matter there were some atrophied neurons and others appear necrotized, minimal proliferation of astrocytes and oligodendrocytes in the site of transaction were apparent (Figure 2 & 3). In the twelfth

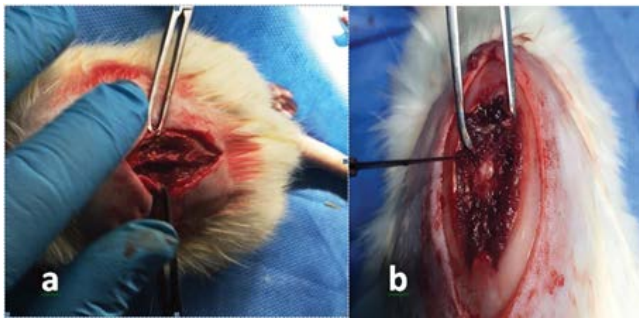

Figure 1: Lamioctomy **a:** Reveal of vertebral colomn **b:** Exposure of the spinal cord after laminectomy

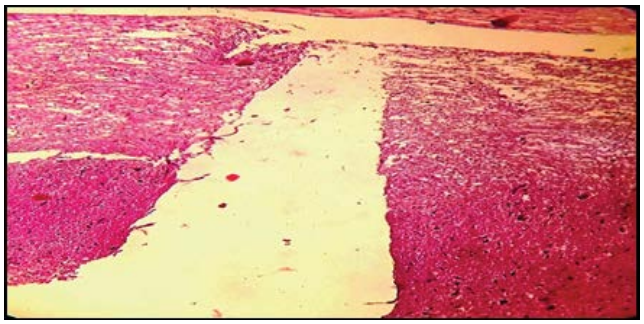

Figure 2: Spinal cord of control group after 6 weeks reveals a little proliferation of astrocytes in the site of transection (arrows) but still there is a gap between two sides of transection. H&E 100X

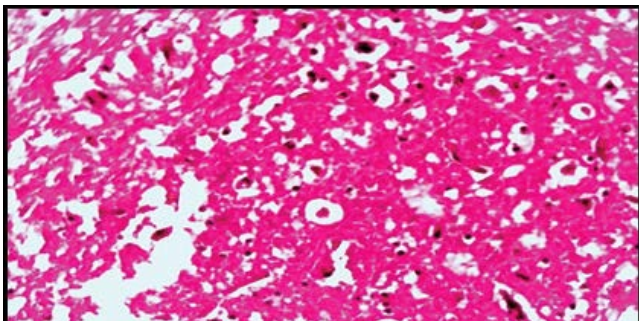

Figure 3: control group reveals absence of neurons in the gray matter with severe vacculation (arrows). H&E 400x

week there were also marked vacculation in the white matter due to degeneration of the nerve fibers, some of them appear oedematous. In the gray matter some neurons appeared atrophied and others showed complete absence at the site of transection. There was minimal glial scar formation due to proliferation of reactive astrocytes and still there is a gap between pre and post transection area (Figure 4-7).

Nucleo CMP Forte Treated Group In the group of six weeks, the Histopathological findings of the spinal cord showed there were massive vacuolated degenerated nerve fibers in the white matter Glial scar formation with minimal regenerated axons was appeared in the site of transection (Figure 8), in the gray matter there were numerous degenerated neurons (Figure 9).

The group of twelve weeks revealed that there were moderate number of regenerated axons in the site of transection with proliferation of astrocytes and oligodendrocytes. Also this area showed heavy cellularity; some of these cells appear with foamy cytoplasm that could be oligodendrocytes which phagocytosis the fat of degenerated myelin (Figure 10), also some vacuolated degenerate nerve fibers in the white matter (Figure 11). In the gray matter there were some atrophied neurons. There was also increase in the oligodendrocytes in the white matter (Figure12).

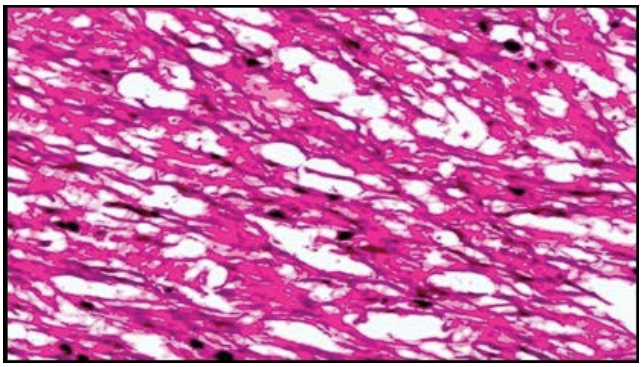

Figure 4: control group after 12 weeks shows a) vacuolated degenerated nerve fibers b) presence of few glia in white matter. H&E 400X

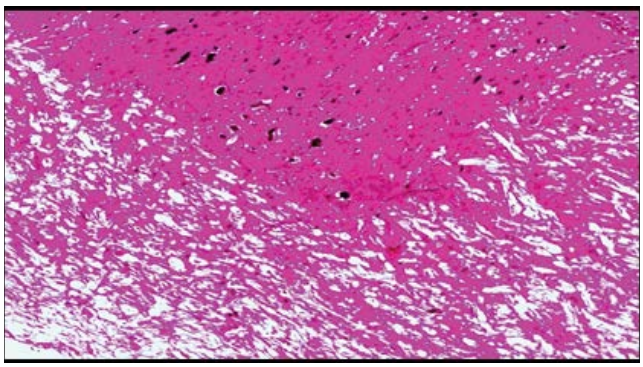

Figure 5: controls group after 12 weeks, show Spinal cord of reveals the area of white and gray matter. H&E 100X

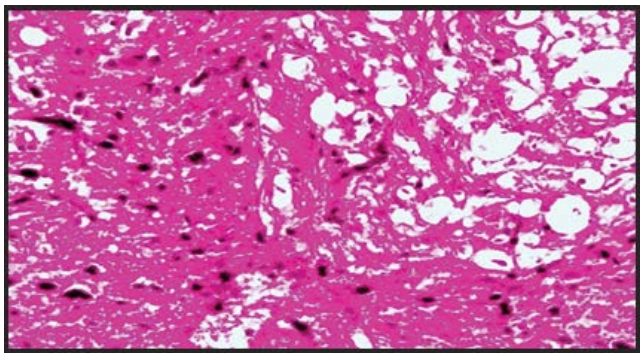

Figure 6: control group after 12 weeks which show the area of gray and white matter (arrows). H&E 400X

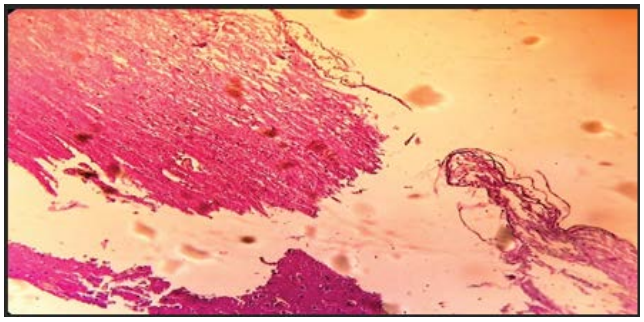

Figure 7: Spinal cord of control group after 12 weeks reveals the proliferation of astrocytes in the site of transection (arrows) but still there is a gap between two sides of transection. H&E 100x

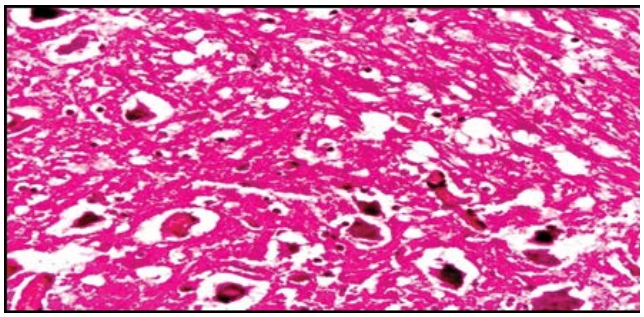

Figure 8: Spinal cord of CMP at 6 weeks shows atrophied neurons in gray matter b) vaculated degenerated nerve fibers in white matter. H&E 400x

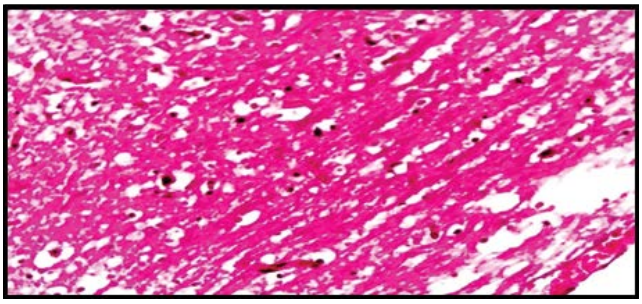

Figure 9: CMP white matter of 6 weeks shows several vaculated degenerated nerve fibers with a few glia (astrocyte with oligodendrocytes) (arrows). H&E 400X

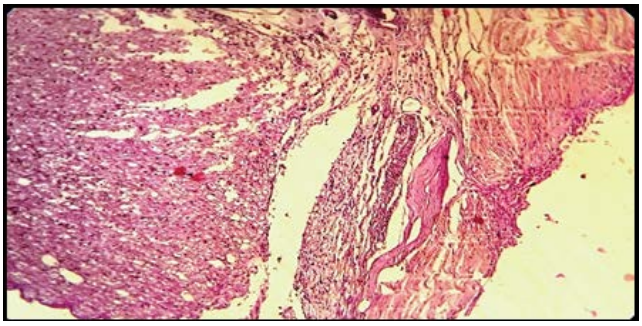

Figure 10: CMP area of transection at 12 weeks shows a) Axonal regeneration b) Glial scar formation (astrocytes and oligodendrocytes) (arrows). H&E 400X

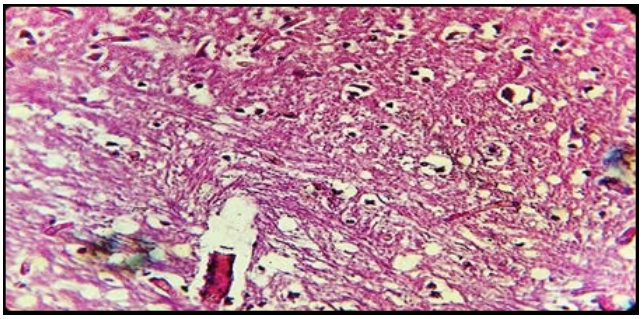

Figure 11: Spinal cord of CMP at 12 weeks, gray matter shows a) some degenerated neurons b) gliosis (arrows). H&E 400X

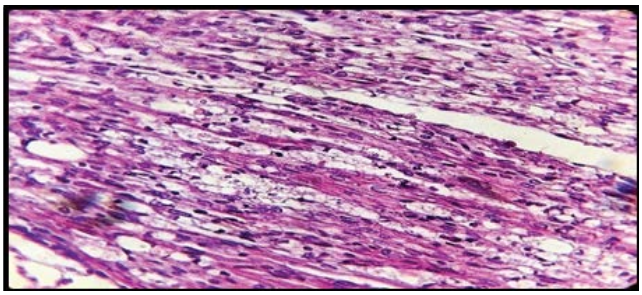

Figure 12: CMP, white matter of 12 weeks shows a) Moderate regenerate nerve fibers b) Presence of vacuolated degenerate axons some appear edematous (arrows). H&E 400X

Discussion

Currently, there is no treatment available to restore motor and sensory function after debilitating SCI. However, progress is being made in research; numerous treatment strategies are being investigated to repair damaged axons after SCI in rats [10].

Thigh muscle atrophy was noticed in all animals of control and treated groups with variable degrees of severity , in control group, it was very severe because of disuse atrophy which is usually related to the spinal cord transection and this agreed with [9], it seems that the muscle mass and muscle force contraction were related to the development of motor function in which the muscle mass developed to nearly normal in the group of combination treatment after development of motor function and more than the other treated groups.

The neuro-histopathological inspection of the spinal cord in longitudinal section in the control group revealed sever vacculation of the nerve fibers in the white matter this attributed by key pro-inflammatory cytokines which lead to the secondary cascades of events that accurse after several hours to days of spinal cord injury which include the mitochondrial dysfunction which lead to failure of aerobic energy metabolism and finally lead to production of free oxygen radicals which cause lipid peroxidation and lead to increase vascular permeability, local ischemia, and intraneuronal edema. Fiber deformation and local demyelination which refer to degenerate axons this agreed with [11].and this what called Wallisian degeneration which results from separation of axons and their myelin sheath from the neuronal cell body this agreed with [12].

The vacculation in the gray matter result from degenerated and necrotized neurons in both subgroups of 6th and 12th week, the neuronal cell necrosis result from ischemia which occur after spinal cord secondary injury. Ischemia result from inadequate blood supply to the tissue lead to hypoxia and reduction in perivascular PH from accumulation of acid metabolites such as lactate this tissue perfusion may increase cellular damage by promoting the influx of free radicals and other toxic byproducts, this agreed with [13].

The present study revealed that the laser group were vacuolated degenerate nerve fibers in the white matter after six weeks post operation , in the gray matter the neurons appear slightly atrophied , in the area of transection there were moderate axonal regeneration, this changes being prominent in the subgroup of 12th week in which the regenerate axons being more massive as well as presence of glial scar (proliferation of astrocytes and oligodendrocytes) also presence of cells with foamy cytoplasm which may be the oligodendrocytes which engulf the degenerate myelin also proliferation of new regenerate blood vessels , the proliferation of astrocytes in the site of transection and the presence of cells with foamy cytoplasm were supported by [12].

The stimuli which activate microglia within the spinal cord have not been definitively elucidated but believed to change oxygen tension, alter the level of extracellular metabolites

(e.g., glutamate), and cytokines/ chemokine's secreting by neighboring cells (endothelia, neurons, glia) specially (Interleukin 1, Interleukin 6, Tumor necrosis factor-α), upon activation of microglia alter their phenotype and secretary properties and have rounded phagocytic morphology and secrete proinflammatory cytokines in rounded milieu [14]. The conclusion of this study was enhanced the regeneration spinal cord injury.

Inspite of the ability of CMP to induce neuro-protection after SCI, the present study showed that the animals of laser group developed the onset of hind limb movement earlier than animals of CMP group, in which the rats in laser group showed the onset of hind limb movement in 4th week, It is possible that this early recovery is due to local sprouting, enhanced compensation or sparing of white matter induced by laser irradiation penetrated to the depth of the injured spinal cord and promoted axonal regeneration and functional recovery [15].

Whereas the animals of CMP group showed the onset of hind limb movement in the 6th week post-operation .we didn't find any previous study of Nucleo CMP Forte on treatment of spinal cord injury but its improve the important role in peripheral nervous system, studies in vivo have shown that the addition of these nucleotides favors the regeneration of militated nerve fibers following crush injury to the sciatic nerve of the rat, thus accelerating the process of nerve repair [16].

While in the animals of group of combination were very earlier in which they showed the onset of hind limbs movement in the 3rd week, this may give indication about the synergistic effect of both treatment methodologies which the two have the ability on axon regeneration that may be attributed in this early recovery, but we didn't find any previous study used Laser and Nucleo CMP forte as a combination therapy to treat spinal cord injury.

The onset of sensation in the current study had been developed in the group of combination earlier than the other groups of Laser and CMP in which 60% of the animals showed the onset of sensation in the 7th week and the full number developed the onset of sensation in the 8th week while in the Laser group all animals showed the onset of sensation in the 8th week and 30% of CMP showed the onset of sensation in the 9th week and the complete number of the animals showed the onset of sensation in the 10th week, the development of motor function being earlier than the development of the sensory function this agree with other investigators [17].

The regeneration of axons in the site of transection appeared in the CMP less than that appeared in Laser and this may give indication about the bio stimulatory neuroprotective effect of Laser. In the group of combination therapy the glial scar formation and axonal regeneration at the site of transection being more prominent than the groups of either Laser or CMP as a single therapy, these changes noticed on both subgroups of the 6th and 12th weeks, also the cells of foamy cytoplasm were present in this group which indicate the macrophage which engulf the degenerated myelin which resulted from degenerated axons, white matter of this group showed marked reduction in the number of swollen vacuolated nerve fibers and prominent presence of regenerate axons , in the gray matter there was marked reduction in the number of atrophied neurons with gliosis this support the synergistic effect of both therapies. The presence of glial scar is very important in the site of transection because it is act as a guide for crossing of new regenerated axons from one side of transection to the other and improves the conduction of nerve impulse and this agreed with [18].

The most devastating thing which was increase damage of spinal cord after injury is the inflammation and many of the key players and the complex interrelationships involved in the secondary cascades of events occurring during the first minutes, hours, days after [19]. Previous studies showed that due to a disrupted blood-spinal cord barrier, clusters of peripheral macrophages infiltrate into the lesion site post-injury [20]. Microglias are the first responders to the CNS trauma, being activated within minutes to hours of injury [21].

Nucleo CMP Forte have been prescribed to patients with lumbosciatalgia, alcoholic and diabetic polyneuropathies or trigeminal neuralgia, although their mechanism of action remains to be established , Little is known about the beneficial effects of nucleotides on the central nervous system. Oral administration of UMP alone or in combination with unsaturated fatty acids increases spine density and the synthesis of synaptic proteins and ameliorates the impairment of hippocampal dependent memory in impoverished rats, which provides a rationale for testing these compounds in the search for a way to treat neurological diseases characterized by synaptic loss [22].

Moreover, UTP administration to rats protects against cerebral ischemia riper-fusion injury by reducing the infarct zone , Nucleo CMP forte is useful in the regeneration of nerve cells by stimulating the synthesis of phospholipids and sphingolipids (the major components of neuronal cell membranes and myelin sheath), Furthermore, Nucleo CMP forte has an essential role in the activation of Schwann cells [23].

References

1. Hagg T, Oudega M (2006) Degenerative and spontaneous regenerative processes after spinal cord injury. *J Neurotrauma* 23: 264-280. [View Article]
2. Atalay M, Anafarta N, Sarvan F (2007) "Antibodies neutralizing Nogo-A increase pancadherin expression and motor recovery following spinal cord injury in rats," Spinal Cord. 45: 780-786. [View Article]
3. Tsuji O (2010) "Therapeutic potential of appropriately evaluated safe induced pluripotent stem cells for spinal cord injury". *Proc Natl Acad Sci*, USA, 107: 12704-12709. [View Article]
4. Flierl U, Nero T, L Lim, B Arthur, JF Yao, et al. (2015) Phosphorothioate backbone modifications of nucleotide-based drugs are potent platelet activators. *J Exp Med* 212:129-137. [View Article]

5. Lavi R, Sheinberg A, Friedmann H, Shneyvays V, Rickover O, et al. (2003) Low energy visible light induces reactive oxygen species generation and stimulates an increase of intracellular calcium concentration in cardiac cells. *J Biol Chem* 278: 40917-40922. [View Article]

6. Lala B, Anna B, El Hachim C, Demba D, Kamadore T (2015) Efficacy and tolerance of combination of Cytosine 5 ' monophosphate (CMP) and Uridine-5 ' Triphosphate Trisodium (UTP) in patients with diabetic neuropathy: results of a study conducted in Dakar-Senegal. *Int Scholar J* 5: 284-287. [View Article]

7. Del-Bel E, A Borges, CA Defino, HL Guimaraes, (2000) Induction of foes protein immunoreactivity by spinal cord contusion. *Brazilian J Med Biol Res* 33: 521- 528. [View Article]

8. Giglio CA, Defino HL, A Da-Silva, CA De-Souza, AS (2006) Behavioral and physiological methods for early quantitative assessment of spinal cord injury and prognosis in rats. *Braz J Med Biol Res* 39: 1613-1623. [View Article]

9. Talmadge RJ, Roy RR, Caiozzo VJ, Edgerton R (2002) Mechanical properties of rat soleus following long-term spinal cord transection. *J Appl physiol* 10: 1-40. [View Article]

10. Nash HH, Bork R C, Anders JJ (2002) Ensheathing cells and methylprednisolone promote axonal regeneration and functional recovery in the lesioned adult rat spinal cord. *J Neurosci* 22: 7111-7120. [View Article]

11. Tsai MC, Shen LF, Kuo HS, Cheng H, Chak KF (2008) Involvement of a FGF in spinal cord injury repair process revealed by a proteomic approach. The American Society for Biochemistry and Molecular Biology, Inc. 7: 1668-1687. [View Article]

12. Becerra JL, Puckett WR, Hiester ED, Quencer RM, Marcillo AE, et al. (1995) MR pathologic comparisons wallerian degeneration in spinal cord injury. *AM J neuroradiol* 16: 125-133. [View Article]

13. Amar A P (2007) Pathogenesis of acute spinal cord injury and theoretical bases of neurological recovery. Chapter 1. 1-8. [View Article]

14. Gordon S, Martinez FO (2010) Alternative activation of macrophages: mechanism and functions. Immunity 32: 593-604. [View Article]

15. Byrnes KR, Waynant RW, Ilev IK, Wu X, Barna L, et al. (2005) Light promotes regeneration and functional recovery and alters the immune response after spinal cord injury. *Laser Surg Med* 36: 171-185.[View Article]

16. Wattig B, Schalow G, Madauss M, Heydenreich F, Warzok R, et al. (1992) Acceleration of nerve and muscle regeneration by administration of nucleotides-electro neurophysiological and morphometrical investigations. *Acta Histochem Suppl* 42: 333-339. [View Article]

17. Braken M B, Shepard M J, Holford TR (1998) Methylprednisolone or trilazad mesylate administration after acute spinal cord injury:1-year follow up. Results of the third National Acute Spinal Cord Injury randomized controlled trial. *J Neurosurg* 89: 699-706. [View Article]

18. Davies SJ, Fitch M T, Memberg SP, Hall AK, Raisman G, et al. (1997) Regeneration of adult axons in white matter tracts of the central nervous system. *Nature* 390: 3-680. [View Article]

19. Trivedi A, Olivas AD, Noble-Haeussien L J (2006) Inflammation and Spinal Cord Injury: Infiltrating Leukocytes as Determinants of Injury and Repair Processes. *Clin Neurosci Res* 6: 283-292. [View Article]

20. Norenberg M D, Smith J, Marcillo A (2004) The pathology of human spinal cord injury: Defining the problems. *J Neurotrauma* 21: 429-440. [View Article]

21. Kim CM, Eng JJ, Whittaker MW (2004) Level walking and ambulatory capacity in persons with incomplete spinal cord injury: relationship with muscle strength. Spinal cord, 42: 156-162. [View Article]

22. Gella A, Ponce J, Cuss R, Durany N (2008) "Effect of the Nucleotides Cmp and Ump on Exhaustion in Exercise Rats". *J Physiol Biochem* 64: 9-17. [View Article]

23. Martianez T, Carrascal M, Lamarca A, Segura M, Durany, N, et al. (2012) UTP affects the Schwannoma cell line proteome through P2Y receptors leading to cytoskeletal reorganisation. Proteomics. 12: 145-156. [View Article]

Citation: Alfaris AA, Radha ZH, Hamza BS (2018) Efficacy of Nucleo CMP Forte after Induce Spinal Cord Injury in Rats. Vet Sci Med 1: 001-006.