

Isolated Tuberculous Epididymo-orchitis: Case Report from Iraq

Murtadha Almusfer*

Professor and Consultant of Urology, College of Medicine, University of Basrah, Basrah, Iraq

***Corresponding Author:** Murtadha Almusfer, Professor and Consultant of Urology, College of Medicine, University of Basrah, Basrah, Iraq.

Received: April 05, 2020; **Published:** April 22, 2020

Abstract

An isolated extrapulmonary tuberculosis still representing diagnostic and therapeutic challenges. A case of 30-year old male reported as having an isolated tuberculous epididymo-orchitis in the absence of concomitant respiratory tuberculosis. He was on broad spectrum antibiotics for one month.

Keywords: *Tuberculous; Epididymo-Orchitis; Orchidectomy*

Introduction

Although tuberculosis (TB) is commonly a respiratory disease transmitted by coughed aerosol, it can infect any other organ in the body after pulmonary infection. Immunosuppression plays an important role in the reactivation of the disease with unusual presentation [1,2].

An isolated extrapulmonary TB still representing diagnostic and therapeutic challenges [3].

Tuberculous involvement of scrotal contents usually occurred by retrograde extension from the prostate and seminal vesicle or through a hematogenic route. It usually affect epididymis first and if left untreated it will spread to involve testicle [4].

In developed countries, genitourinary TB is uncommon. The estimated incidence of extrapulmonary TB is 20 - 25% with only 4% of genitourinary type [5].

It is difficult to definitely diagnose an isolated TB epididymitis because of the usual absence of concomitant active pulmonary TB at the time of presentation [6], therefore a high index of suspicion is required to pick up the diagnosis and the purpose of this case report is to shed a light on the condition and consider it as a possibility during managing a patient with non-resolved scrotal swelling of infective origin.

Case Report

A 30- year old male patient presented with one month history of left- sided scrotal swelling with feeling of heaviness on the affected side. He has low grade night fever with no sweating. There is no significant weight loss, nor cough or sputum. On examination: general and

chest examination were not significant. No palpable organs on abdominal examination nor tenderness. Scrotal examination revealed a slightly tender firm mass of approximately 3 x 3 Cm at the head of epididymis with no palpable line of cleavage from the ipsilateral testicle and it is felt as if matted together. The vas was normal and the contralateral testicle and epididymis were also normal.

Investigations include Complete blood count which revealed no significant finding with normal ESR, tumor markers were normal (AFP 3.53 ng/ml, beta HCG 0.2 ng/l, LDH 170 U/l). Urinalysis was normal, and 24 hour urine for AFB was negative. Chest X-ray showed no abnormality. Tuberculin skin test (TST) was negative. Abdominal ultrasound was normal. Scrotal ultrasound revealed infiltrative lobulated hypoechoic mass at the head of epididymis with no hydrocele. Magnetic resonance imaging (MRI) of the scrotum revealed solid enhancing mass at the head of epididymis with suggestion of adenomatoid tumor or malignancy. No inguinal or pelvic lymphadenopathy (Figure 1 and 2).

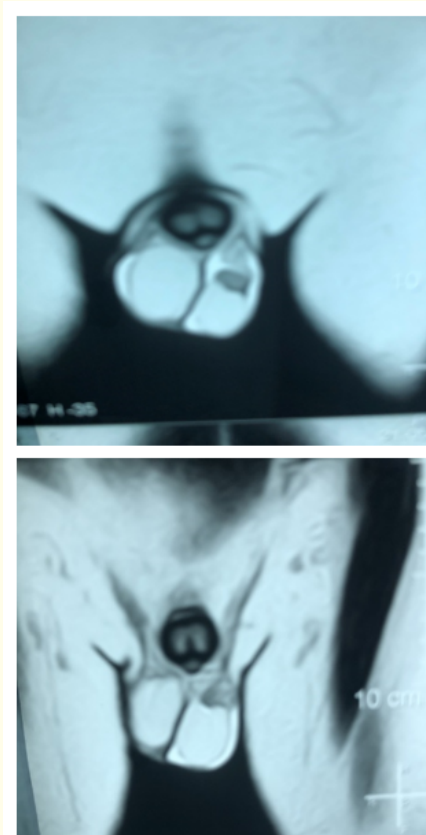


Figure 1 and 2: (MRI Scrotum) apparent solid enhancing mass at the head of epididymis with visible demarcation between left testicle and epididymis except for small indentation at the upper pole of the testicle. A suggestion of adenomatoid tumor or malignancy was proposed by radiologist. No inguinal or pelvic lymphadenopathy was noted.

Shared decision between the patient and surgeon with the fear of malignancy by the patient pushes toward the option of left orchidectomy after taking a full consent. Histopathological examination revealed severe chronic inflammation with multiple caseating granuloma and Langhan's giant cells involving testicle and epididymis.

Discussion

Isolated TB epididymitis and epididymo-orchitis is not easily diagnosed on clinical basis and may need surgical confirmation to establish the final diagnosis. This may be explained by the absence of synchronization with active pulmonary TB and the variability of the results of many tests, therefore a high index of suspicion is needed to propose the disease in a patient with scrotal swelling which is not responding to the usual broad spectrum antibiotics [7].

Many cases were reported in the Asia and shown in table below.

Authors	Age (Years)	Location	Presentation	Imaging	Lab. Tests	Surgery	Medical treatment
Liu., <i>et al.</i> [7]	79	Bilateral	Scrotal pain	MRI	Urine culture, PCR	No	Isoniazid, rifampin and ethambutol for 6 months
Kho and Chan [8]	20	Right	Painless	Sonography	Pathology	Orchidectomy	Isoniazid, rifampicin, ethambutol, and pyrazinamide for 6 months
Yu-Hung Lai., <i>et al.</i> [9]	78	Right	Painless	Sonography	Urine AFB Pathology	Orchidectomy	Isoniazid, rifampicin, and ethambutol for 9 months
Shao-Ming Chen [10]	65	Left	Mild tenderness	Sonography MRI	Urine AFB, urine culture, PCR	No	Isoniazid, rifampicin, and ethambutol for 6 months
This case	39	Left	Mild pain and tenderness	Sonography, MRI	Urine AFB, TST	Orchidectomy	Starting anti TB drugs

Table: Comparison of the cases of isolated tuberculous epididymitis.

Although it is reported that the disease started at the tail of epididymis because it is the first portion involved by retrograde urine reflux or may be due to high blood supply [4,11,12], this finding is not consistent with what we found in this patient who had the lesion at the head of epididymis and extended to involve the testicle itself with no clear explanation for that.

Regarding the extent of disease in this patient, there was a bad correlation between imaging finding and histopathological examination of orchidectomy specimen. The testicle was relatively spared from the disease on imaging while it was clearly involved by the disease process on histopathology with no much gap between imaging and surgery (one week only). The surgical finding supports the matted feeling of left testicle and epididymis on clinical examination.

It is also clear from the previously reported cases that the disease can usually be treated medically, but the long period needed to complete the treatment is a challenging issue bearing in mind the fear of malignancy with no definite diagnosis.

Kim., *et al.* [11] and Drudi., *et al.* [4] demonstrated a preferential involvement of the tail of the epididymis which was not seen in this patient, nor in the series of Chung., *et al* [12].

Kim., *et al.* [11] suggested heterogeneous enlargement of epididymis. This finding had also been confirmed in the series of Chung., *et al.* This heterogeneity may be explained by various pathologic stages of the disease, which include caseation necrosis, the presence of granulomas, and fibrosis [11,12]. These findings are similar to those seen in this patient.

Conclusion

Finally, the suspicion of TB epididymitis should be considered in any patient with non resolving scrotal swelling despite the use of broad spectrum antibiotics even in the absence of negative laboratory results.

Bibliography

1. Elliott AM., *et al.* "Impact of HIV on tuberculosis in Zambia: A cross sectional study". *British Medical Journal* 301.6749 (1990): 412-415.
2. Raviglione MC., *et al.* "HIV-associated tuberculosis in developing countries: Clinical features, diagnosis, and treatment". *Bulletin of the World Health Organization* 70.4 (1992): 515-526.
3. Hopewell PC. "A clinical view of tuberculosis". *Radiologic Clinics of North America* 33.4 (1995): 641-653.
4. Drudi FM., *et al.* "Tubercular epididymitis and orchitis: US patterns". *European Radiology* 7.7 (1997): 1076-1078.
5. Singh JP., *et al.* "Genito-urinary tuberculosis revisited - 13 years' experience of a single centre". *Indian Journal of Tuberculosis* 60.1 (2013): 15-22.
6. Lee IK., *et al.* "Scrotal tuberculosis in adult patients: A 10-year clinical experience". *American Journal of Tropical Medicine and Hygiene* 77.4 (2007): 714-718.
7. Liu HY., *et al.* "Tuberculous epididymitis: A case report and literature review". *Asian Journal of Andrology* 7.3 (2005): 329-332.
8. Kho VK and Chan PH. "Isolated tuberculous epididymitis presenting as a painless scrotal tumor". *Journal of the Chinese Medical Association* 75.6 (2012): 292-295.
9. Yu-Hung Lai A., *et al.* "Tuberculous epididymitis presenting as huge scrotal tumor". *Urology* 73.5 (2009): 1163.e5-7.
10. Shao-Ming Chen. "Isolated tuberculous epididymitis". *Formosan Journal of Surgery* 50.2 (2019): 74-76.
11. Kim SH., *et al.* "Tuberculous epididymitis and epididymoorchitis: sonographic findings". *Journal of Urology* 150.1 (1993): 81-84.
12. Chung JJ., *et al.* "Sonographic findings in tuberculous epididymitis and epididymo-orchitis". *Journal of Clinical Ultrasound* 25.7 (1997): 390-394.

Volume 4 Issue 5 May 2020

© All rights reserved by Murtadha Almusafar.