

Brain Histopathological Changes Study Induced By Subcutaneous Administration of Toluene on Rabbits Brain Tissue

Wasfi Dahir Abid Ali¹, Luay Abdulwahid Shihab^{2*}, Abdulkareem Salman Khudhair³¹Department of Basic Sciences College of Nursing -University of Iraq –Ph.D in Physiology²Department of Basic Sciences College of Nursing -University of Iraq Master in Computer Science³Department of Basics of Nursing College of Nursing -University of Iraq Master in Adult NursingDOI: [10.36347/sjams.2020.v08i02.024](https://doi.org/10.36347/sjams.2020.v08i02.024)

| Received: 05.02.2020 | Accepted: 12.02.2020 | Published: 14.02.2020

*Corresponding author: Luay Abdulwahid Shihab

Abstract

Original Research Article

The recent study conducted in university of Basrah – nursing college , the brain have been investigated in this study using rabbit brain via histopathological examination, Ten adult rabbits from local market divided into two group caged in plastic cages. Five rabbits caged as control group) received normal saline (NaCl 0.9%), The rabbits in group II (treated with 0.3 cm of toluene 97% S/c for 6 weeks, toluene-administration group were distinctly structurally damaged compared to the control group. As well as cytoplasm of the cortex cell showed inflammatory reactivity in the experimental group.

Keywords: Toluene, brain, rabbits.

Copyright © 2020: This is an open-access article distributed under the terms of the Creative Commons Attribution license which permits unrestricted use, distribution, and reproduction in any medium for non-commercial use (NonCommercial, or CC-BY-NC) provided the original author and source are credited.

INTRODUCTION

In nature toluene is found in tolu trees and crude oil and transpired through the separation of gasoline and other fuels from crude oil and burning of coke (ATSDR 2006) [1], (ATSDR 2007) [2]. Chemically toluene is a hydrocarbon that is rapidly absorbed through the respiratory and gastrointestinal tracts and, to a lesser extent, through the skin [3]. Toluene is most found in refineries, around gas stations and areas with heavy traffic. In addition, smokers are exposed to 80–100 µg of toluene within a cigarette [4]. Paints, paint thinners, varnish, shellac, rust preventers, glues, solvent based cleaners, and some cleaning products Baydas [5]. The main target of toluene is the Central Nervous System (CNS). Symptoms that may arise are fatigue, easy drowsiness, headaches, and nausea [6]. Toluene lipophilic nature of toluene that lead to alters the lipid structure of the cell wall and interacts with proteins [7]. Toluene causes cerebellar and pyramidal dysfunctions, peripheral neuropathy, optic atrophy, neurologic hearing loss, and temporary and/or permanent damage including cognitive functions [8]. It has been reported that toluene also damages the peripheral nerves [9].

Mehmet Demir *et al.*, [10] found that the acute phase effects of toluene on the brain have been investigated in this study using rabbit brain via

histopathological, immunohistochemical, and biochemical methods. Histologically they found areas of focal vacuolar degeneration (abscess formation), gliosis, and perivascular demyelination, many pyknotic cells and necrosis were observed. In the toluene-administration group compared to the control group, distinct excessive expansions of the blood vessels and severe degeneration in the structure of cells and also dispersed cell borders were observed. Furthermore, abnormal malformations of the nuclei structure of the oligodendrocyte cells were seen. Bodies of the sequential neurons of the hippocampus in the toluene-administration group were distinctly structurally damaged compared to the control group. In addition, cytoplasm of the cortex cell showed serious immune reactivity in the experimental group.

MATERIAL AND METHODS

Ten adult male rabbits were purchased from a local market and housed in individual cages (360, 200, 190 mm), weighing 950- 1200 g, were allotted in two experimental groups. The animals were available add libitum food and tap water for both groups , the first group take normal saline 0.9% Na CL while the second group received 0.3 ml of toluene(97%)/Kg B.W subcutaneously daily for 6 weeks. At the end of the experiment, after anesthetized by intramuscular injection of mixture xylazine 2% (Alfasan- Holland)

and ketamine 10% (Kepro -Holland), at the end of the experiment animals were sacrificed. The brain tissues were removed from the cranium. Random samples of the brain tissue from each group were fixed in 10% formalin for 3–6 h, dehydrated, embedded in paraffin, sectioned at 5 μ m, and subsequently stained with hematoxylin/eosin. Done by Iraq biotech laboratory in Basrah- Iraq.

RESULTS AND DISCUSSION

Toluene as a chemical often used by industry has effects that are harmful to the human body. One known effect was neurotoxic. Abdul Rohim *et al.*, [11] their research on rabbits showed that toluene caused damage and apoptosis in brain cells with toluene exposure for 3 hours [12] toluene exposure can also

cause dementia, cerebellar ataxia, corticospinal tract dysfunction, and cranial neuropathies [13].

Histological examination of stained slides of brain tissue of this study, showed that brain tissues of the control group were observed in normal structure (Figure-1). While areas of focal vacuolar degeneration, gliosis, perivascular demyelination, and many pyknotic cells and necrosis were detected in the brain cortexes of the toluene-administered rabbits, remarkable excessive expansion of the blood vessels, severe degeneration of the compensation in the cells, and almost dispersed cell borders were observed, abnormal malformations of the nuclei structure of the oligodendrocyte cells were seen in (Figure-2).

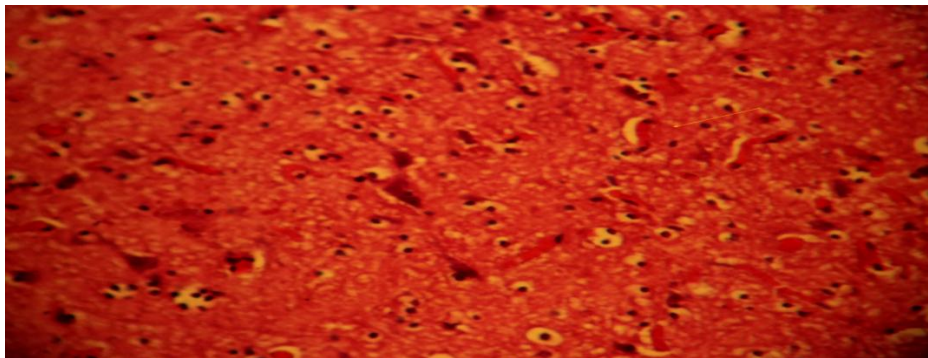


Fig-1: Rabbit brain of control group showed normal white matter stained with hematoxylin and eosin x100

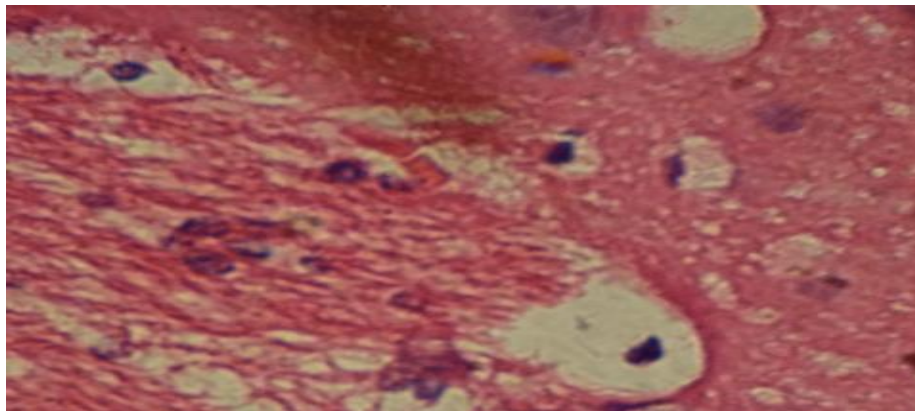


Fig-2: Cross section on rabbit brain after administration of toluene degeneration in white matter, stained with hematoxylin and eosin x100

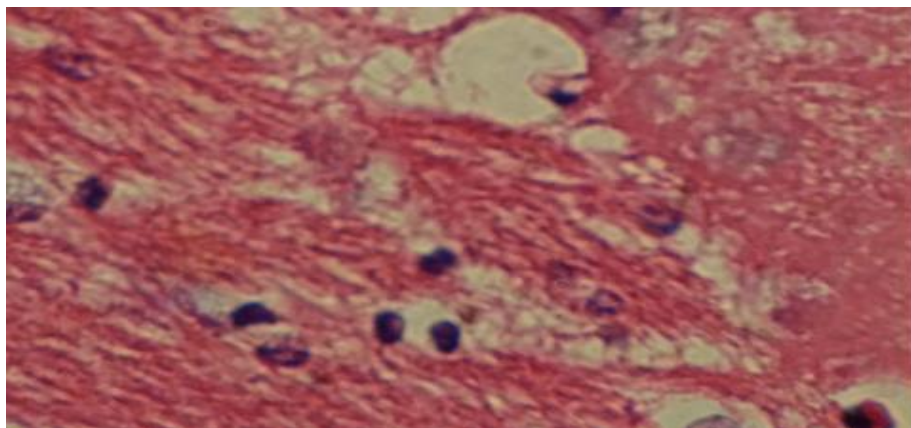


Fig-3: Cross section on rabbit brain after administration of toluene degeneration in white matter, stained with hematoxylin and eosin x100

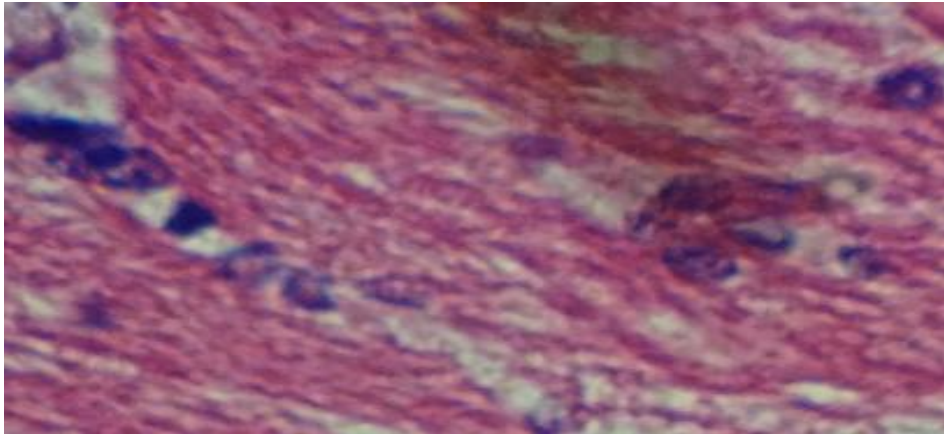


Fig-4: Cross section on rabbit brain after administration of toluene show congestion and abnormal malformations of the nuclei structure, (H&E) x100

In the recent study the examination of stained slides were, showed that brain tissues of the control group were observed in normal structure Figure-1. Areas of focal vacuolar degeneration and many pyknotic cells and necrosis were detected in the brain cortexes of the toluene-administered rabbits, remarkable excessive expansion of the blood vessels, severe degeneration of the compensation in the cells, and almost dispersed cell borders were observed, abnormal malformations of the nuclei structure of the oligodendrocyte cells were seen Figure 2 & 3.

HPA, 2007 [4] reported that toluene after absorption can be found in small amounts in fat tissue (white and brown fat tissue), stomach, liver, kidney, bone marrow, brain, and lymph tissue Five hours after toluene is inhaled, toluene will reach the maximum level in adipose tissue. High levels of Toluene can be found in the liver and brain in people with death from toluene inhalation [14].

Ladefoged *et al.*, [15] pointed that toluene leads to apoptotic neurodegeneration in the cerebellum and hippocampus. Chronic toluene addiction is known to cause atrophy in the substantia alba and is associated with clinical outcomes of atrophy [16].

The present study through the cross section on rabbit brain after administration of toluene showed degeneration in white matter Figure 2 & 3, congestion and abnormal malformations of the nuclei structure Figure-4, compared to the control group Figure-1. Mahmet *et al.*, [10] found distinct excessive expansions of the blood vessels and severe degeneration in the structure of cells and also dispersed cell borders were observed and concluded that the main damage of toluene, which is astrocyte activation and gliosis, has been distinctly observed by making benefit of biochemical and histopathological methods. High levels of the proapoptotic proteins, Bax and caspase-3, in the brain cortex, hippocampal area, entorhinal cortex, and substantia nigra tissues of the toluene-administered

rabbits showed that toluene may trigger apoptosis even in about 3 hours.

Several theories mention that toluene shows a neurotoxic effect by increasing the activity of cholinergic bonds on the gamma-aminobutyric acid receptor (GABA) and shows noncompetitive antagonistic effects on N-methyl-D-aspartate (NMDA) receptors [17, 18]. Reports from several researchers showed that toluene causes tissue damage by increasing the oxygen radicals [19, 20].

The primary target of toluene is thought to be the CNS and both acute and chronic effects are recognized. The chronic encephalopathy associated with long-term toluene abuse is particularly important because it appears to be a permanent and disabling disorder related to white matter damage in the brain. Clinical, neuropsychological, and MRI studies in toluene abusers have shown relatively specific damage to white matter and a consistent profile of neurological and neurobehavioral impairment [21]. Research on rabbits showed damage and apoptosis in brain cells with toluene exposure for 3 hours [10].

CONCLUSION

The study conclude that toluene for six week of subcutaneous administration caused histopathological changes in rabbits brain tissue compared with control group.

ACKNOWLEDGEMENT

My sincere gratefulness and thanks to Mr. Luaa A Shehab from nursing college and extend my thanks and gratitude to. Prof. Dr. Ali Abid Allateef College of Education for pure sciences - university of Basrah

REFERENCES

1. Agency for Toxic Substances and Disease Registry (ATSDR). Case Studies in Environmental. 2006.

2. Agency for Toxic Substances and Disease Registry (ATSDR) CSEM Toluene Toxicity: Environmental Medicine Case Study. Atlanta, Ga, USA. 2007.
3. Campagna D, Stengel B, Mergler D, Limasset JC, Diebold F, Michard D, Huel G. Color vision and occupational toluene exposure. *Neurotoxicology and teratology*. 2001 Sep 1;23(5):473-80.
4. Health Protection Agency (HPA). Toluene Toxicological Overview., *Medicine*. Toluene Toxicity. 2007.
5. Baydas G, Gursu MF, Yilmaz S, Canpolat S, Yasar A, Cikim G, Canatan H. Daily rhythm of glutathione peroxidase activity, lipid peroxidation and glutathione levels in tissues of pinealectomized rats. *Neuroscience letters*. 2002 May 3;323(3):195-8.
6. ATSDR. Toxicological Profile for Toluene [Internet]. United States: US Department. 2015.
7. Calderon-Guzman D, Espitia-Vazquez I, López-Domínguez A, Hernández-García E, Huerta-Gertrudis B, Coballase-Urritia E, Juárez-Olguín H, García-Fernández B. Effect of toluene and nutritional status on serotonin, lipid peroxidation levels and Na⁺/K⁺-ATPase in adult rat brain. *Neurochemical research*. 2005 May 1;30(5):619-24.
8. Coskun Ö, Yüncü M, Kanter M, Büyükbas S. Ebselen protects against oxidative and morphological effects of high concentration chronic toluene exposure on rat sciatic nerves. *European Journal of General Medicine*. 2006 Jan 1;3(2):64-72.
9. Coskun O, Oter S, Korkmaz A, Armutcu F, Kanter M. The oxidative and morphological effects of high concentration chronic toluene exposure on rat sciatic nerves. *Neurochemical research*. 2005 Jan 1;30(1):33-8.
10. Demir M, Cicek M, Eser N, Yoldaş A, Sisman T. Effects of acute toluene toxicity on different regions of rabbit brain. *Analytical Cellular Pathology*. 2017;2017.
11. Abdul RT, Dwi AW, Bahrul IA, Pudji R. Association Between Toluene Inhalation Exposure and Demography Towards Risk of Neurotoxic: A Cross-Sectional Study at Plastic Sack Industry Workers in Indonesia *Global Journal of Health Science*; 2019; 11(2).
12. Demir M, Cicek M, Eser N, Yoldaş A, Sisman T. Effects of acute toluene toxicity on different regions of rabbit brain. *Analytical Cellular Pathology*. 2017;2017.
13. Filley CM, Halliday W, Kleinschmidt-DeMasters BK. The effects of toluene on the central nervous system. *Journal of Neuropathology & Experimental Neurology*. 2004 Jan 1;63(1):1-2.
14. Eisenberg ME, Neumark-Sztainer D, Story M. Associations of weight-based teasing and emotional well-being among adolescents. *Archives of pediatrics & adolescent medicine*. 2003 Aug 1;157(8):733-8.
15. Ladefoged O, Hougaard KS, Hass U, Sørensen IK, Lund SP, Svendsen GW, Lam HR. Effects of combined prenatal stress and toluene exposure on apoptotic neurodegeneration in cerebellum and hippocampus of rats. *Basic & clinical pharmacology & toxicology*. 2004 Apr;94(4):169-76.
16. Aydin K, Sencer S, Demir T, Ogel K, Tunaci A, Minareci O. Cranial MR findings in chronic toluene abuse by inhalation. *American Journal of Neuroradiology*. 2002 Aug 1;23(7):1173-9.
17. Sakai T, Honda S, Kuzuhara S. Encephalomyelopathy demonstrated on MRI in a case of chronic toluene intoxication. *Rinsho shinkeigaku= Clinical neurology*. 2000 Jun;40(6):571-5.
18. Thetkathuek A, Jaidee W, Saowakhontha S, Ekburanawat W. Neuropsychological symptoms among workers exposed to toluene and xylene in two paint manufacturing factories in eastern Thailand. *Advances in preventive medicine*. 2015;2015.
19. Friedlander RM. Apoptosis and caspases in neurodegenerative diseases. *New England Journal of Medicine*. 2003; 348(14):1365-1375.
20. Karabulut I, Balkanci ZD, Pehlivanoglu B, Erdem A, Fadillioğlu E. Effect of toluene on erythrocyte membrane stability under in vivo and in vitro conditions with assessment of oxidant/antioxidant status. *Toxicology and Industrial Health*. 2009;25(8):545–550.
21. Filley CM, Kleinschmidt-DeMasters BK. Toxic leukoencephalopathy. *New England Journal of Medicine*. 2001 Aug 9;345(6):425-32.