

See discussions, stats, and author profiles for this publication at: <https://www.researchgate.net/publication/331413846>

EFFECT OF INTRATESTICULAR INJECTION OF ETHANOL ON TESTICULAR HISTOLOGY, TESTOSTERONE LEVEL AND SOME SPERM CHARACTERISTICS IN Local RAMS

Article · March 2015

CITATIONS

0

READS

774

1 author:



Ihsan Habeb

University of Basrah

5 PUBLICATIONS 0 CITATIONS

SEE PROFILE

Some of the authors of this publication are also working on these related projects:



DIRECT EFFECT OF RED LASER IRRADIATION ON TESTICULAR AND EPIDIDYMIS TISSUE FUNCTION IN MALE RABBITS [View project](#)



COMPARATIVE STUDY BETWEEN THREE MEDIA IN VITRO MATURATION AND Fertilization RATE OF LOCAL BUFFALO OOCYTES [View project](#)

EFFECT OF INTRATESTICULAR INJECTION OF ETHANOL ON TESTICULAR HISTOLOGY, TESTOSTERONE LEVEL AND SOME SPERM CHARACTERISTICS IN Local RAMS

Ihsan Ali Habeeb

Department of Surgery and Obstetrics , College of veterinary Medicine, Universty of Basrah, Basrah , Iraq

(Received 24December 2014 ,Accepted 9March 2015)

Keywords; Sterilization, Ethanol solution,Aspermia.

ABSTACT

This study was performed to evaluate the effect of chemical sterilization by intratesticular injection of chemicals to induce castration in rams. 5 adult local rams (20-25 kg bw) which their health and reproductive performance had been evaluated by clinical examination and evaluating of the seminal ejaculate volume , sperm concentration and testosterone levels before treatment .The animals had been intratesticular injected with 95% ethanol solution with dose 10 ml each testis . This group had aroused apparent clinical signs during the first three days after treatment which represented by swelling and severe pain. Semen ejaculated volume , sperm concentration and testosterone levels had been evaluated on the 10th,20th &30th day after treatment. All animals had showed aspermia in the 20th day after the injection while hormonal levels revealed a significant reduction .The testicles were removed with the open surgical technique after 30 days for histopathology evaluation of testicular changes. The histopathological study demonstrated, necrosis in seminiferous tubules, edema, complete suppression of spermatogenesis.

It was concluded that intra-testicular injections method by ethanol may be accepted as a suitable alternative method to the open surgical technique for castration in rams.

INTRODUCTION

Castration means removal of the testes and associated structures such as epididymis and part of the spermatic cord (1,2) .there are many method used to castrated large animals such as (closed and open) surgery , to avoid such complication of open surgery, the inexpensive and suitable methods for large scale sterilizing programs in both domestic and wild animals intra-testicular injection has been investigated as a method of inducing aspermatogenic (3,5). Moreover, there are very few reports available in the literature related to the chemical sterilization of ram. Intra-seminiferous tubules injection of a 10% solution of formalin resulted in azoospermia or severe oligospermia in awassi lambs (6), intratesticular injection of Zinc gluconate versus surgical castration to sterilize male in the dog (7) , transient scrotal swelling and pain persisted for up to 2 weeks following intra-testicular injection of calcium chloride solution in bull(3).. The purpose of the present study was to determine the efficacy of intratesticular injection of ethanol as chemosterilization outcome of the rams.

MATERIALS AND METHODS

The study included (5) adult rams ranged between (12-14 months), and weights ranged between (20-25 kg) . The animals were trained for (40) days to collected semen by artificial vagina twice a week during the period of September to mid October by the using of ewe in estrus. The collected semen was evaluated by measurement of the ejaculated volume, sperm concentration measuring , serum testosterone level and histopathological studies on the testes.

Experimental Design

1- semen collection:

semen was collected by an artificial vagina, using ewe in estrus induced by intramuscularly injection of (5) mg estradiol. semen samples and blood were collected from all rams used in the present study before treatment and considered as control (zero time). After treatment, semen and blood were collected during (10, 20 and 30) days to evaluat the ejaculated volume, sperm concentration and serum testosterone level .

The volume were recorded immediately after collection from rams by graduated tube and sperms placed in water bath at 37°C (1,8).

Semen concentration was determined in the regular manner with the blood counting chamber, by means of which the number of spermatozoa was counted. Semen was pulled by the absorbent pipette which is usually used for RBCs count to the point (0.5) then diluted to the point (101). After that, diluted semen pipette containing was moved as number 8. The first five drops were neglected. We dropped the diluted semen on the slid and covered by cover slid. Then examined under microscope degree (X40) (1,8).

2 - Preparation for surgery:

The animals were fasted for (12) hours before treatment. The testes was cleaned by soap and water. The hair of the scrotum was shaved and the animal were given sedative as xylazine dose (0.2) mg / kg BW, and then tied on a surgery table and is slanted so that the head low and tail high. The testicles were wrapped with iodine tenicture(1). Finally ethanol was injected intra testicular with dosage (10) ml at (95%) concentration in each testes.

After the treatment by ethanol during (10, 20 and 30) days, the collected semen was evaluated by measurement of the ejaculated volume, sperm concentration measuring, serum testosterone level. Open surgical technique for castration was carried out to study the histopathological changes.

3-Histopathological studies

Each testes from each animal was fixed in (10%) Formalin and embedded in paraffin wax. A section 5 µm thick was cut from the middle portion of each testis, stained with hematoxylin-eosin and examined under light microscopy at (400X) magnifications.

RESULTS

clinical signs

The animals treated with ethanol showed swelling in the site of the injection in the testis and the swelling lasted to 3 days, The animals also showed anorexia for 1 day after the treatment, The swelling started to reduce gradually after the 3rd days of treatment till reaching the almost the normal testis size but with abnormal morphology.

The animal treated with administering IM 5 ml oxytetracyclin (10%) and 5 ml metalgin once daily for 5 days.

Seminal examination

1- Ejaculate Volume

As shown in table (1), there was a significant decrease ($P < 0.01$) in the ejaculate volume in all treated animals compared with pre-treatment for animals of the all groups. The ejaculate volume before injection as the volume (1.4000 ± 17) ml to reach the average (0.9200 ± 11), (0.6600 ± 08), (0.5400 ± 05) ml respectively in the periods (10, 20 and 30) after the treatment .

2- Sperm concentration:

The results showed that the mean values semen concentrations by intratesticular ethanolic injection , it shown in table (1) there was a significant decrease ($p < 0.01$) in all treated animals after 10, 20 and 30 days of treatment The averages before the injection with ethanol were (1646.0000 ± 76.19) to become (443.0000 ± 62.12) (0.00000 ± 0.00) (0.00000 ± 0.00) ml respectively, as there was no sperm in the day (20) after the injections in the all groups .

3-Testosterone concentration evaluation:

The results of the present study showed that Testosterone concentration before injecting with ethanol was (5.2300 ± 41) while after injection the concentrations were (1.7800 ± 20), (0.8320 ± 08), (0.2460 ± 091) ng/ml in the days (10, 20 and 30) respectively in table (1).

4-Histopathological studies on the testes

The microscopic examination related with the injected testis with ethanol showed, Sertoli cell, Spermatogenic cell and the disappearance of the primary and the secondary spermatogonia , suppression of spermatogenesis (Fig..1) microssi in the seminiferous tubules in addition to presence of an infiltrations of polynuclear inflammatory cells, hemorrhage and infiltrations of edematous within the testicular tissue (Fig.. 2). There was also a fibrosis of testicular tissue and inflammatory cells disappearance of the primary and the secondary spermatogonia with vacuolated (Fig..3).

5- Statistical analysis:

The statistical analysis that used in this study was depend on SPSS statistical program, and by used a one way ANOVA.

Parameter	Period			
	0 pretreatment	1. (days)	2. (days)	3. (days)
Ejaculation volume (ml)	1.4000±17 A	0.9200±11 B	0.6600±08 c	0.5400±05 c
Testostérone concentration (ng/ml)	5.2300±41 A	1.7800±.20 B	0.8320±.08 c	0.2460±09 c
Sperm concentrationn (...×10/ml)	1646.0000±76.19 A	443.0000±62.12 B	0.0000±0.00 c	0.0000±0.00 c

The small litter referred to significant at($p < 0.01$)

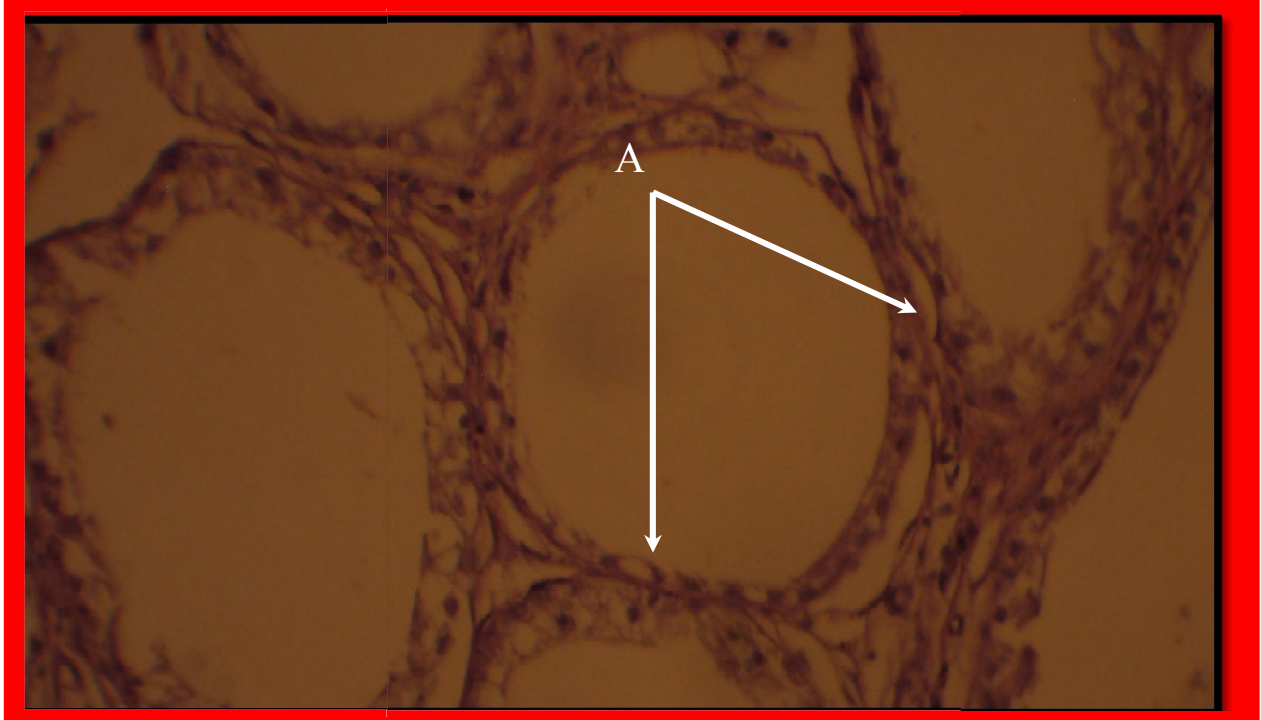


Fig. (1) Testis of ram treated with an ethanol after 30 days of treatment show Sertoli cell, Spermatogenic cell and the disappearance of the primary and the secondary spermatogonia (H &E X400)

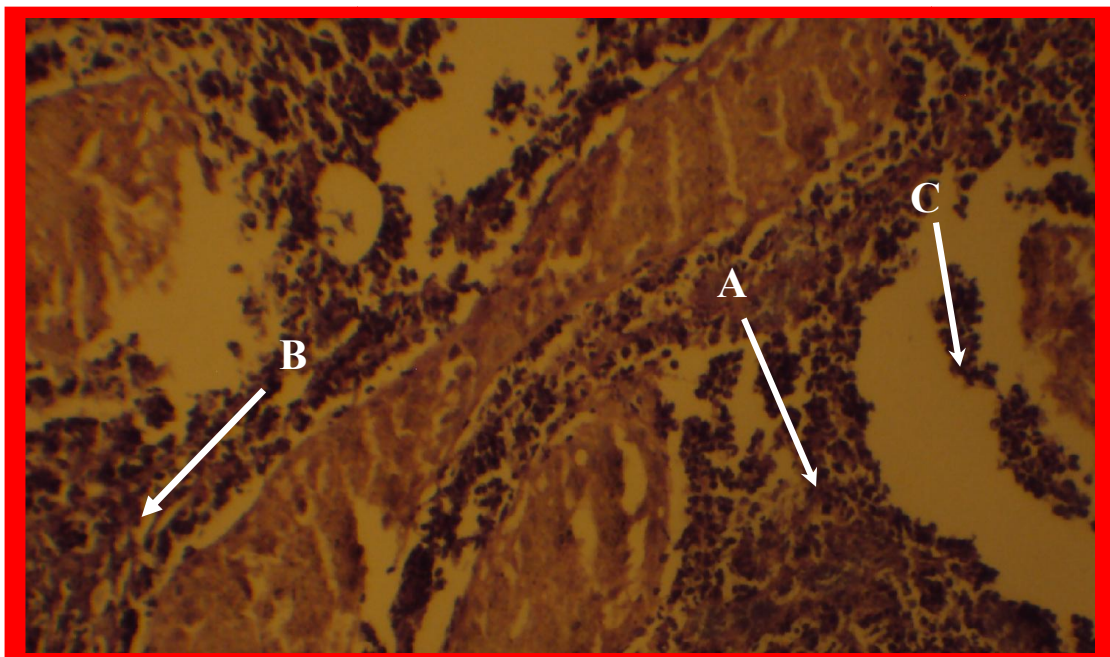


Fig. (2) Testis of ram treated with an ethanol after 30 days of treatment show A- There was also a real necrosis in the seminiferous tubules B-presence of an infiltrations of polynuclear inflammatory cells hemorrhage c- infiltrations of edematous within the testicular tissue (H &E X400)

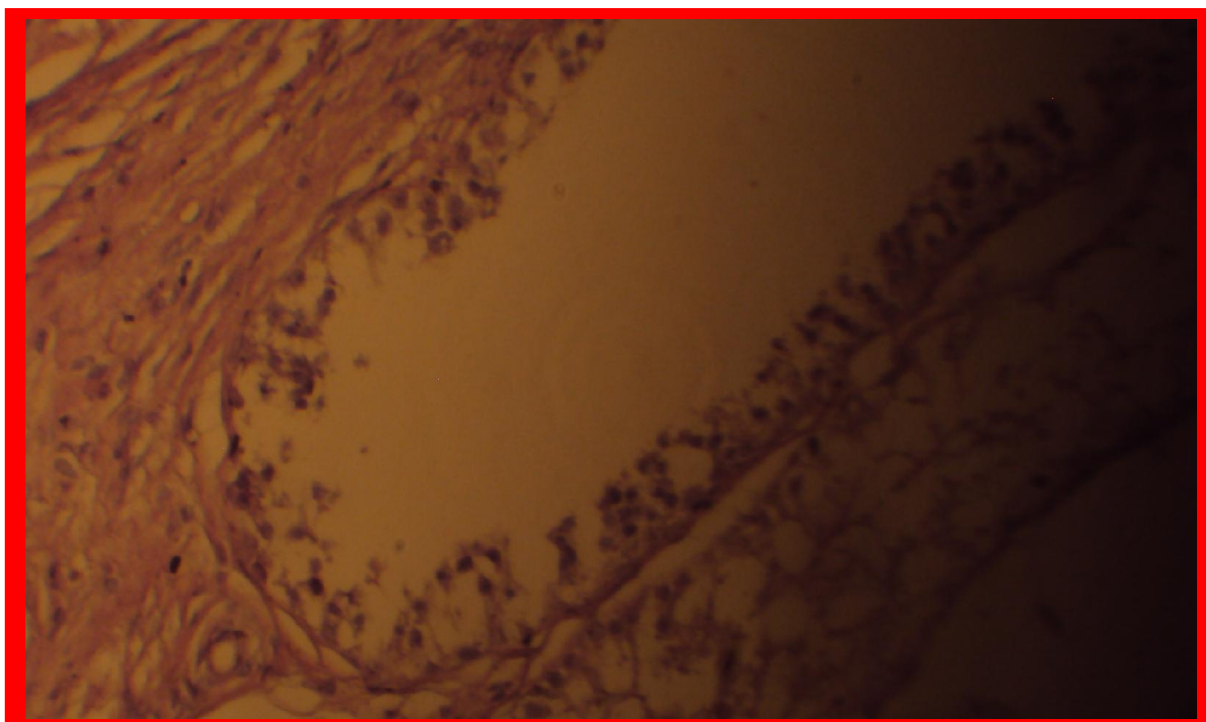


Fig. (3) Testis of ram treated with an ethanol after 30 days of treatment show A-There was also a fibrosis of testicular tissue and inflammatory cells B- disappearance of the primary and the secondary spermatogonia with vacuolated (H &E X400)

DISCUSSION

Clinical signs

The animals group that were injected with ethanol showed testicular swelling in day 1 and continuous of the swelling for 3 days. The days after injection that is in Who mentioned occurrence of testicular tissue accordance with the results of (9) damage that leads to edema formation with presence of testicular pain when touch in addition to the animals shows anorexia, also the occurrence of pain in the animal of the present study is in agreement with the result of (1) and (6) , who mentioned that the pain is attributed to the pressure of testicular edema on the nerve endings. the abnormal testicular morphology is attributed to the drainage of the formed edema that decreases the pressure on the nerve endings or can be attributed to the inflammation which is initiated by the injection of the chemical that developed to severe stages which led to formation of a fibrous tissue that led to change the size and morphology of the testis which is in agreement with the results that are mentioned by (10).

Seminal examination

1-Ejaculate Volume

The animals that were injected with ethanol in their testis showed decreased in ejaculate volume. This can be attributed the harm effect of ethanol on the testis

specially the accessory glands which was caused by the injection of the chemicals. This result was in consistent with that of (6&9) who confirmed that the reduction in ejaculate volume is attributed to the damage of the accessory glands due to the infiltration of the injected chemicals to the accessory glands which are responsible of secreting the seminal fluids (3).

2-Sperm concentration:

The microscopic examination results showed that there was a significant variation in the characters of the seminal fluid at ($P < .05$) which is represented by reduction in semen concentration. As it was obvious that the injection of the testis with ethanol cause semen concentration to become zero in the day 20. This result is in agreement with that of (6 &3) who confirmed that injection of formalin 10% or ethanol inside testis leads to stop sperm formation due to the damage that affects the spermatogenic cells.

The results of the present study also agreed with that of (4 & 11) who confirmed that injection of zinc arginine or glycerol inside testis leads to reduction or halting spermatogenesis due to the damages that affect the spermatogenic cells and due also to the increasing in the formation of the connective tissues, in addition, due to the necrosis that happens in the testicular tissue.

The results of the present study also agreed with that of (3) who mentioned that the local injection of the absolute ethanol inside the testis leads to stop spermatogenesis due to the damage of the spermatogenic cells in addition to the damage of Sertoli cells which are supporting and nourishing the spermatogenic cells.

The results of the present study are also in accordance with in that of (4 & 6) who mentioned that the injection of formalin testis leads to absence of sperm in the epididmis due to destruction of the seminiferous tubules and the testicular tissue in addition to testicular tissue necrosis and the calcification of the seminiferous tubules same result were mention by (4).

3-Testosterone concentration

The hormonal test results showed a significant decreasing in the testosterone concentration at ($P < .05$) during the fixed periods after the injection of ethanol compared to the concentration before the injection. The decreasing in the testosterone concentration can be attributed to the mass destruction of the testicular tissue specially Laidig cells which are responsible of secreting of the testosterone. This result is in continece with that of (12) who mentioned there is a graduate reduction in the testosterone concentration due to the injection of the absolute ethanol inside the testis that leads to destruction of the cells which are responsible of the secretion of the testosterone.(3) mentioned that testosterone concentration doesn't reduce to zero because 10% of the total concentration is secreted from the adrenal gland.

Histopathological study:

The histopathological test results showed changed in the testicular tissue of the injected animals as there were a necrotic vacuoles in the majority of the cells of the lining of the seminiferous tubules, obvious necrotic changes in the seminiferous tubules, sloughing of the seminiferous tubules lining and spread destruction in the majority of the testicular tissue. This is confirmed by (3) who stated that injection of leads to mass destruction in the testicular tissue and necrosis %⁹⁶ the absolute ethanol in the seminiferous tubules with the presence of inflammatory signs which are

represented by accumulation of a huge number of the monocyte that means the testis responded to the severe harm that affected it. The results of the present study were in accordance with that of (6) who reported that the injection of formalin 10% inside ram testis leads to stop spermatogenesis due to the affection of the spermatogenic cells and Sertoli cells due to the injection of the chemical. The results of the present study also agreed with that of (4) who mentioned that the injection of Zinc argenin inside the testis leads to destruction of the spermatogenic cells with interseminal tubules spread fibrosis.

تأثير حقن الايثانول على النسيج الخصوي ومستوى هرمون الشحمون الخصوي وبعض صفات النطف في الكباش المحلية

أحسان علي حبيب

فرع الجراحة والتوليد، كلية الطب البيطري، جامعة البصرة، البصرة، العراق.

الخلاصة

أجريت هذه الدراسة لمعرفة تقييم كفاءة تأثير حقن المواد الكيميائية داخل الخصية لإحداث الاخفاء الكيميائي في الكباش . استخدم خمسة كباش محليه تراوحت أوزانها (٢٠-٢٥) كغم .تم تقييم صحة هذه الحيوانات ظاهري وكذلك التأكد من سلامة الجهاز التناسلي الذكري عن طريق الفحص السريري . تم قياس حجم أذفقه ، تركيز النطف وتركيز الهرمون الذكري (التستوستيرون) قبل المعاملة .حقنت الحيوانات بمادة الايثانول المطلق بتركيز 95 % وكانت الجرعة المستخدمة 10مل/ خصيه حيث تم الحقن في منتصف الخصية اظهرت هذه الحيوانات علامات سريره واضحه خلال ٣ أيام الأولى من الحقن والتي تمثلت تورم الخصية وألم شديد . قيمت الحيوانات بعد المعاملة من خلال دراسة حجم أذفقه ، تركيز النطف ، قياس مستوى الهرمون الذكري خلال فترات (٣٠, ٢٠, ١٠) يوم بعد المعاملة ، اظهرت جميع الحيوانات انعدام النطف في اليوم ٢٠ بعد الحقن وكذلك لوحظ انخفاض كبير في مستوى تركيز الهرمون الذكري خلال الفترات بعد عمليه الحقن. اجري الاخفاء الجراحي بالطريقة الاعتيادية بعد ٣٠ يوم من المعاملة لتقييم التغيرات المرضية للنسيج الحسوي .حيث اظهر توقف عمليه إنتاج النطف مع تنخر النسيج الحسوي وارتشاح الخلايا الالتهابية مع وجود وذمه . نستنتج من الدراسة أن اخفاء الكباش بطريقة الحقن داخل الخصية بالمواد الكيميائية مقبولة كبديل مناسب لتقنيه الجراحية المفتوحة .

REFERENCES

1. Cheminean, P. and Cagnie, Y. (1991). Cited by: Al-Dahhan, M. R. A. and Amin, A. A. (2002). Comparative study between Vasectomy and Epididymectomy for preparation of teaser Ram and Buck. MSC. Thesis. College of Veterinary Medicine of Baghdad University, Iraq (Arabic)
2. Anderson JR.; (1980) . Muir's textbook, 11th ed. Edward Arnold London,
3. Canpolat GS, Gunay C, Bulut S, Eroksuz H . 2006 ; An evaluation of the outcome of bull castration by intra-testicular injection of ethanol and calcium chloride, Revue Med Vet. 157: 420.

4. 4-Fahim MS, Wang M, Sutcu MF, Fahim Z, Youngquist RS. Sterilization of dogs with intra-epididymal injection of zinc arginine. *Contraception* 1993 Jan;47(1):107-22
5. Jana K, Samanta PK(2011). Clinical evaluation of non-surgical Sterilization of male stray cats with a single intratesticular injection of calcium chloride: *BMC Vet Res*;7:9 .
6. Ijaz-A; Abalkhail-AA; Khamas-WAH (2000). Effect of intra testicular injection of formalin on seminiferous tubules in Awassi lambs. *Pakistan-Veterinary-Journal*. 20: 3, 129-134
7. Lavy JK, Crawford PC, Appel LD, Clifford EL: Comparison of intratesticular injection Zinc gluconate versus surgical castration to sterilize male dogs *Am J Vet Res* 2008, 69:140-143
8. Fahim MS, Fahim Z, Harman JM. Chemical sterilization in the male part I: rats. *Arch Androl* 1982 Nov;9(3) :261-5
9. Dixit VP. and Gupta RS.(2002) . Effects of short term treatment of solasodineon cauda epididymis in dog. *Ind J exper Bio*. 40:162-173
10. Fordyce G, Hodge PB, Beaman NJ, Laing AR, Campero C, Shepherd RK. An evaluation of calf castration by intra-testicular injection of a lactic acid solution. *Aust Vet J* 1989 Sep;66(9):272-6
11. Immegart, H.M. and Threlfall, W.R. (2000). Evaluation of intratesticular injection of glycerol for nonsurgical sterilization of dogs. *Am. J. Vet. Res.*, 61:544-549
12. Giri-SC; Yadav-BPS; Panda-SK Chemical castration in pigs. *Indian-Journal-of-Animal-Sciences*. 2002, 72: 6, 451-453